

Floppy eyelid, an under-diagnosed syndrome: a review of demographics, pathogenesis, and treatment

Alessandra De Gregorio^{ID}, Alberto Cerini, Andrea Scala, Alessandro Lambiase, Emilio Pedrotti and Simonetta Morselli^{ID}

Ther Adv Ophthalmol

2021, Vol. 13: 1–9

DOI: 10.1177/
25158414211059247

© The Author(s), 2021.
Article reuse guidelines:
[sagepub.com/journals-](https://sagepub.com/journals-permissions)
permissions

Abstract: Floppy eyelid syndrome (FES) is a frequent eyelid disorder characterized by eyelid laxity that determines a spontaneous eyelid eversion during sleep associated with chronic papillary conjunctivitis and systemic diseases. FES is an under-diagnosed syndrome for the inaccuracy of definition and the lack of diagnostic criteria. Eyelid laxity can result from a number of involuntal, local, and systemic diseases. Thus, it is pivotal to use the right terminology. When the increased distractibility of the upper or lower eyelid is an isolated condition, it is defined as 'lax eyelid condition' (LAC). When laxity is associated with ocular surface disorder such as papillary conjunctivitis and dry eyes, it can be referred to as 'lax eyelid syndrome' (LES). However, FES is characterized by the finding of a very loose upper eyelid which everts very easily and papillary tarsal conjunctivitis affecting a specific population of patients, typically male, of middle age and overweight. Obesity in middle-aged male is also recognized as the strongest risk factor in obstructive sleep apnea-hypopnea syndrome, (OSAHS). FES has been reported as the most frequent ocular disorder associated with OSAHS. Patients with FES often complain of non-pathognomonic ocular signs and symptoms such as pain, foreign body sensation, redness, photophobia, and lacrimation. Due to these clinical features, FES is often misdiagnosed while an early recognition might be important to avoid its chronic, distressing course and the associated morbidities. This review provides an updated overview on FES by describing the epidemiology, proposed pathogenesis, clinical manifestations, related ocular, and systemic diseases, and treatment options.

Keywords: conjunctivitis, corneal diseases, ectropion, eyelid laxity, floppy eyelid syndrome, obstructive sleep apnea-hypopnea, prostaglandins, surgical techniques

Received: 4 May 2021; revised manuscript accepted: 25 October 2021.

Introduction

Floppy eyelid syndrome (FES) is a frequent and under-diagnosed eyelid syndrome.^{1,2} It mainly involves the upper eyelids that easily distort and turn out with minimal lateral traction and the tarsus appears soft, rubbery, and easily folded. Patients present marked papillary conjunctivitis of the upper tarsus with symptoms of irritation such as photosensitivity, foreign body sensation, mucoid discharge, dryness, eyelid swelling, and blurred vision.³

FES has been first described in 1981 by Culbertson and Ostler,¹ who reported 11 middle-aged and obese men with an easily everted floppy

upper eyelid associated with papillary conjunctivitis. The authors hypothesized that in these patients, the upper eyelid everts during sleep, causing inflammation. Subsequently, different clinical scenarios of eyelid laxity were reported in scientific journals, using the term 'floppy eyelid syndrome' vaguely and inconsistently.

In 1994, Van den Bosch and Lemij⁴ introduced the term 'lax eyelid syndrome' (LES) for patients with chronic papillary conjunctivitis, punctate epithelial keratitis, and ocular discharge, related to upper eyelid laxity with a clear-cut cause. They identified three subgroups: 'paralytic LES' in which eyelid

Correspondence to:
Alessandra De Gregorio
Ophthalmic Unit, San
Bassiano Hospital, Via dei
Lotti 40, 36061 Bassano
del Grappa, Vicenza, Italy.
adegre3@gmail.com

Alberto Cerini
Alessandro Lambiase
Eye Clinic, Department of
Sense Organs, Umberto
I Policlinico, Sapienza
University of Rome, Rome,
Italy

Andrea Scala
Simonetta Morselli
Ophthalmic Unit, San
Bassiano Hospital,
Bassano Del Grappa, Italy

Emilio Pedrotti
Eye Clinic, Department
of Neuroscience,
Biomedicine and
Movement, University of
Verona, Verona, Italy



laxity is associated with loss of tone of the orbicularis muscle (e.g. VII cranial nerve palsy), 'involutionary LES' where laxity is associated with involutinal changes in the tendons of the tarsus and/or the canthus, and 'mechanical LES' in which the ptosis and the disinsertion of the lateral canthal ligament is caused by a mechanical force as in the case of eyelid retraction by a lid speculum during cataract surgery, or in the case of excessive and repeated eyelids rubbing for chronic epiphora or any other ocular surface irritative condition.⁵

Actually, eyelid laxity can result from a number of involutinal, local, and systemic diseases,⁶ thus, it is pivotal to use the right terminology. When the increased distractibility of the upper or lower eyelid is an isolated condition, it is defined as 'lax eyelid condition' (LAC). When laxity is associated with ocular surface diseases (OSD) such as papillary conjunctivitis and dry eyes, it can be referred to as LES.

Instead, FES is characterized by the finding of a very loose upper eyelid and papillary tarsal conjunctivitis affecting a specific population of patients, typically male, of middle age and overweight with a body mass index (BMI) $> 30 \text{ kg/m}^2$ (BMI).¹⁻⁷ Obesity in middle-aged male is recognized as the strongest risk factor in obstructive sleep apnea-hypopnea syndrome (OSAHS), a highly prevalent disorder characterized by repetitive obstruction episodes of the upper airway resulting in oxygen desaturation, arousals from sleep, and daytime symptoms such as excessive sleepiness, poor concentration, and fatigue.^{8,9} Recent data from the United States and Europe suggest that 14–49% of middle-aged men have clinically significant OSAHS.¹⁰ The association between OSAHS and eyelid diseases was first described in 1990 by Woog,¹¹ and later in 1997 by McNab,¹² who diagnosed OSAHS in all eight examined patients with FES and diagnosed FES in three patients out of 20 examined with OSAHS. In a recent cross-sectional cohort study, a total of 431 consecutive patients diagnosed with OSAHS underwent a complete ophthalmic examination to assess the occurrence of different eye diseases. FES was observed to be the most frequent ocular findings occurring in about 50% of patients analyzed.¹³

OSAHS is a significant harbinger of numerous life-threatening disorders^{14,15} and an early diagnosis of FES could be considered an important clinical and easily detectable sign to recognize and prevent severe systemic diseases.

Epidemiology

The prevalence of FES in the general population is difficult to measure because of the inaccuracy of definition and the lack of diagnostic criteria; it varies within a range from 2.3% to 3.8%.¹⁶ Usually it is associated with middle-aged overweight (BMI $> 30 \text{ kg/m}^2$) males, but recently it has been demonstrated that it also affects females (30% of FES cases) and, in a little percentage of cases, the pediatric population.¹⁷⁻²⁰

The prevalence of FES in OSAHS strongly differs among all the studies, going from 2.27% (1/44) to 64.57% (164/254).^{16,21} Such variation may be due to the different definitions of apnea or hypopnea and may depend on different grouping criteria for OSAHS patients. Nevertheless, there is a strong correlation between OSAHS and FES – particularly the higher OSAHS severity – the more likely FES will occur.

Related systemic diseases

Patients with FES are often obese, with a BMI $> 30 \text{ kg/m}^2$,^{1,2} and frequently are affected by OSAHS, a syndrome characterized by repeated partial and/or complete collapse of the upper airway during sleep, resulting in apneas and/or hypopneas.^{12,13} Symptoms are correlated with sleep disorders and arousal, resulting in excessive daytime somnolence, cognitive/psychological dysfunction, and poor quality of life.

OSAHS is correlated to numerous specific disorders, such as cognitive and psychiatric dysfunctions, respiratory complications, metabolic abnormalities, hypertension, myocardial infarction, stroke, sleeping disorders, erectile dysfunction, and microsleeps, possibly leading to death while driving. Currently, overnight polysomnography (PSG) type I is the gold standard for the diagnosis of OSAHS^{14,15} During the exam, performed in hospital (PSG type I) or at home (PSG type II-III), it is possible to measure the Apnoea Hypopnoea Index (AHI) represented by the number of apnea and hypopnea events per hour of sleep. Based on AHI, OSAHS can be classified as mild (AHI 5–15/h), moderate (AHI 15–30/h), and severe (AHI > 30 /h).²²

A recent study reported a higher incidence of anterior and posterior segment ocular diseases in patients with OSAHS with 56% prevalence of eyelid disorders, 27% of corneal disorders, 13% of macular disorders, and 11% of glaucoma.¹³

Thus, pulmonologists and ophthalmologists should be prepared to collaborate in caring for such patients.

A variety of genetic conditions have been described in association with LES, including Down syndrome, congenital cataracts, facial dysmorphism neuropathy, and congenital hyperglycinemia. LES is also present in patients suffering from Ehlers-Danlos and Stickler syndrome with specific genetic mutations related to collagen expression.^{6,23,24}

FES has been described in thyroid-associated orbitopathy and especially in Hashimoto thyroiditis. These patients are particularly exposed to the risk of possible globe subluxations due to the combined presence of lax eyelid and ocular proptosis.²⁵ Several other systemic conditions have already been associated with FES, such as diabetes, hypercholesterolemia, ischemic heart disease, osteoarthritis, asthma, atopy, gastroesophageal reflux disease, chronic renal failure, and schizophrenia.²¹ Patients with FES are often obese but assessing and identifying the eyelid laxity in the non-obese and younger patient might expand the impact of this important clinical finding.

Pathogenesis

The pathogenesis of FES remains undetermined, but several decades of investigation have begun to develop an understanding of the mechanism. Culbertson and Ostler¹ postulated that spontaneous nocturnal eversion was the main pathogenetic factor based on the observation that the signs and symptoms were generally more frequent and/or more severe in the eye on the side where the patient preferred to sleep. They also suggested an X-chromosome-linked inheritance pattern or hormone influence since the high prevalence of FES in male population.

In 1983, Parunovic² observed that corneo-conjunctival lesions were uniformly distributed over the cornea and not limited to the inferior area of the ocular surface. He reported that nocturnal taping caused distinct relief of subjective troubles but the keratitis slightly changed.

Thus, he proposed that the reduced interface between the loose eyelids and the ocular surface would have compromised the distribution of the tear film while producing poor wetting and subsequent widespread ocular disease.

Later, other researchers postulated a genetic predisposition such as anomalies of gene expression of connective tissues. Eyelid laxity was noticed first in patients suffering from Ehlers-Danlos syndrome with mutations in the type V collagen genes COL5A1 and COL5A2. Type V collagen is a form of fibrillar collagen present in connective tissues such as dermis, tendon, and ligament. Mechanisms producing the abnormalities in those tissues were probably associated with altered regulation of collagen fibrillogenesis due to alterations in heterotypic I/V collagen interactions.²⁶

Conversely, Netland *et al.* have shown a reduction of tarsal elastin in the lid structure of patients with FES. Microscope examination of eight fragments taken after lid-shortening surgery for FES revealed chronic conjunctival inflammation, papillary conjunctivitis, and Meibomian gland anomalies. They observed a significant decrease of elastin fiber quantity in tarsal plates compared with the control group while the quantity and quality of tarsal collagen fibers was comparable between groups.²⁷ Even Schlötzer-Schrehardt *et al.* demonstrated a loss of elastin fibers and the overexpression of elastin-degrading enzymes in the tarsal plates with the residual elastic fibers ultrastructurally abnormal. They found high matrix metalloproteinase (MMP-9) levels in areas with elastic depletion in patients with FES in comparison with the control group, concluding that the up-regulation of elastolytic enzymes leads to elastic fiber degradation and subsequently to tarsal laxity and lash ptosis. They hypothesized that these modifications were caused first by a mechanical factor and second by alternating ischemia and reperfusion injury of the tissue with neutrophils infiltrating, principal source of MMP-9.²⁸ Taban *et al.*²⁹ correlated the up-regulation of MMP expression to hyperleptinemia, a condition frequently present in FES patients.

Over the years, researchers have tried to explain OSAHS and FES correlation. OSAHS²² is a condition characterized by recurrent episodes of complete or partial obstruction of the upper airway leading to intermittent hypoxia. It causes oxidative stress and production of reactive oxygen during ischemia-reperfusion injury and inflammation. These factors contribute to the production of high serum levels and activity of MMPs found in patients affected by OSAHS. A common underlying connective tissue disorder has been hypothesized to explain the excess of oropharyngeal tissues found in OSAHS and the laxity of tissue in the tarsal plate of lateral canthal tendons in

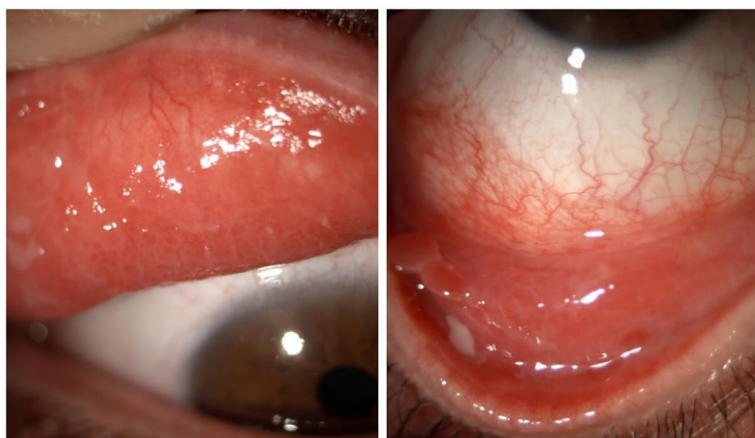

Figure 1. Superior and inferior tarsal papillary conjunctivitis associated with floppy eyelid syndrome.

for developing keratoconus in healthy subjects, as they lead to a reduction in corneal resistance and corneal hysteresis. Furthermore, the recurrence of hypoxic conditions may lead to anaerobic glycolysis and stromal acidosis, and may promote the transcription of pro-inflammatory cytokines, tumor necrosis factor- α , or interleukin-6, leading to corneal thinning.

Clinical ocular features

Patients with FES present with marked papillary conjunctivitis underneath the eyelids (Figure 1) with symptoms of ocular discomfort. The patients usually complain of tearing (70%), redness (44%), photosensitivity, foreign body sensation, mucoid discharge, dryness, eyelid swelling, and decreased vision.⁷ These symptoms are often worse in the morning, depending on the side on which patients prefer to sleep.¹ An easy eversion and increased horizontal laxity of the lid is an important FES examination mark (Figure 2). Corneal punctate erosions, keratitis, and abrasions are often the reasons for the ophthalmological examination, mostly in the emergency room. Dermatochalasis, trichiasis, entropion, ectropion, eyelid and lash ptosis, Meibomian gland dysfunction, and their complications such as the development of recurrent chalazia are common signs (Figure 3).^{12,21}

Patients with FES often complain of nonspecific ocular signs and symptoms such as pain, foreign body sensation, redness, photophobia, and lacrimation. Due to these clinical features, FES is often mistaken for dry eye symptoms; earlier recognition by clinicians could help to prevent the chronic distressing course and comorbidities. Clinicians should include FES on the differential of ocular surface symptoms and screen for the disorder using one of several examination techniques.

Measurement tests

Depending on the complexity of the clinical picture, several parameters should be considered in order to classify FES. First, eyelid laxity, which is the most important feature, should be taken into account. If present, other related clinical signs such as conjunctivitis, dermatochalasis, and ectropion should be considered.

Various methods have been used to quantify upper eyelid laxity, but currently there is not a gold standard for such evaluation. The McNab AA method¹² or ‘vertical lid pull/distraction test’ is the

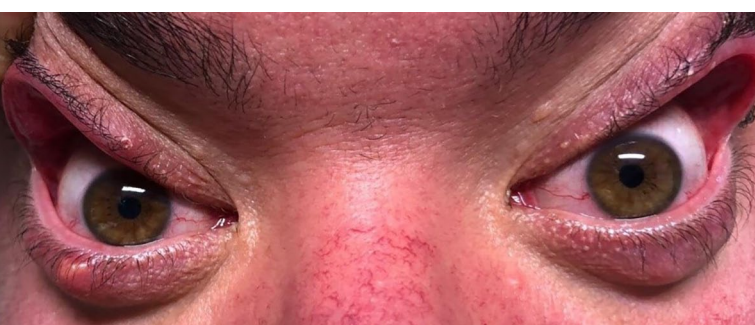

Figure 2. Eyelid laxity in bilateral floppy eyelid syndrome in a 45-year-old man affected by moderate obstructive sleep apnea-hypopnea syndrome.

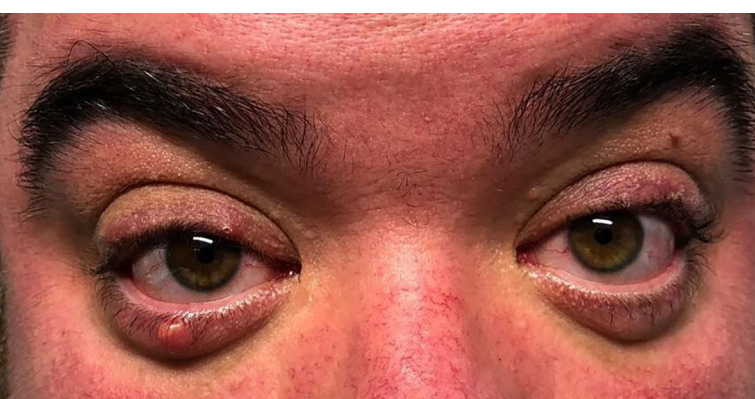

Figure 3. Eyelid/lash ptosis and chalazia associated with floppy eyelid syndrome.

FES. A similar pathogenesis has been postulated for the association between OSAHS and keratoconus.³⁰ It has been suggested that MMPs and proteinase inhibitors may be the causative factors

first and the most reproducible one. The examiner places the thumb on the outer third of the upper eyelid and brings it laterally and superiorly, while the patient is in the primary position of gaze. The excursion is measured during maximal vertical pull using a millimeter ruler. Similarly, the test is performed for the lower lid (Figure 4).

Following Figueira *et al.*'s³¹ study on 'lateralizing eyelid sleep compression' for which they used calipers, Ting *et al.*³² coined the term 'upper eyelid distraction distance (UEDA)'. Following distraction of the upper eyelid with the patient in downgaze, they measured the distance from the posterior margin of the upper lid to the bulbar conjunctiva again using calipers (Figure 5).

Robert *et al.*³³ proposed the 'vertical hyperlaxity' test measuring the maximum distance between the palpebral rim and the center of the pupil following vertical traction of the upper eyelid (Figure 6).

Iyengar and Khan³⁴ described the 'upper horizontal distraction' test using a ruler, which can be used to quantify the distance between the anterior corneal pole and the anterior distracted upper eyelid (Figure 7).

Beis *et al.*³⁵ proposed a 'time evaluation test' to quantify FES severity by recording the duration of eyelid eversion in seconds following manual upper eyelid eversion in downgaze.

Similarly, the 'snapback' test^{6,36} is a diagnostic procedure run to evaluate the eyelid tone and the horizontal laxity severity. This is usually only done for the lower lid. Such a test involves grasping the eyelid, pulling it off the eye, and letting the lid go. If the time required for the lid to return its proper position is higher than 2 seconds or the patient needs to blink, then the lid will be recorded as positive for laxity.

All these tests have a limit due to the subjectivity of the measurement dependent on the force applied by the operator carrying out the eyelid distraction.

To overcome this limitation, Karger *et al.*¹⁶ and Sward³⁶ introduced two devices ('strain gauge device' and 'laxometer') that are able to objectively measure the applied force required for the vertical displacement of the upper eyelid.

These objective tests are more precise and reproducible but are obviously less practical and applicable in normal clinical routine.

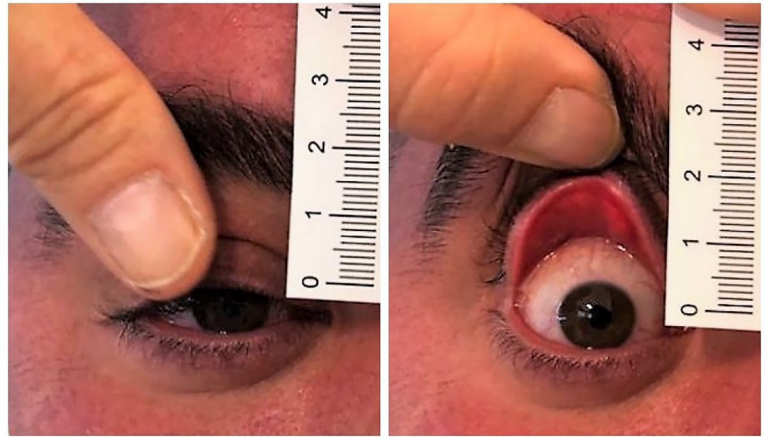


Figure 4. McNab AA method or 'vertical lid pull/distraction' test to measure eyelid excursion using a millimeter ruler (20 mm).

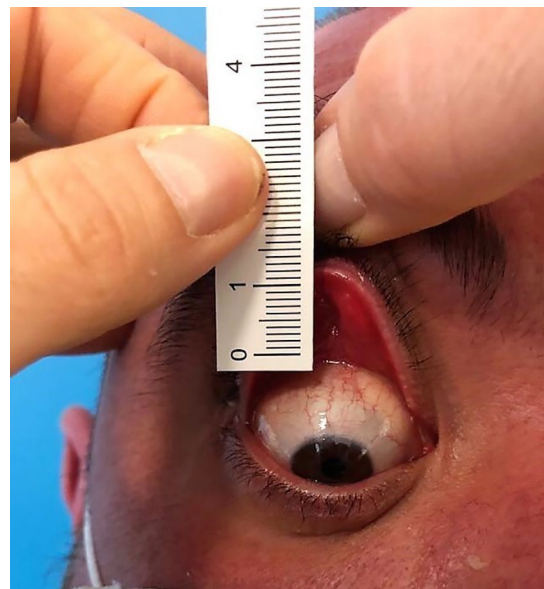

Figure 5. 'Upper eyelid distraction distance (UEDA)' test, measuring the distance from the posterior margin of the upper lid to the bulbar conjunctiva during eyelid distraction with the patient in down gaze position (12 mm).

Grading system

Despite the proposal of several grading systems for FES, they all have lacked construct validity. The gold standard remains a subjective evaluation of the upper lid eversion associated with the presence of other clinical features.

We reported the principal methods to classify FES.

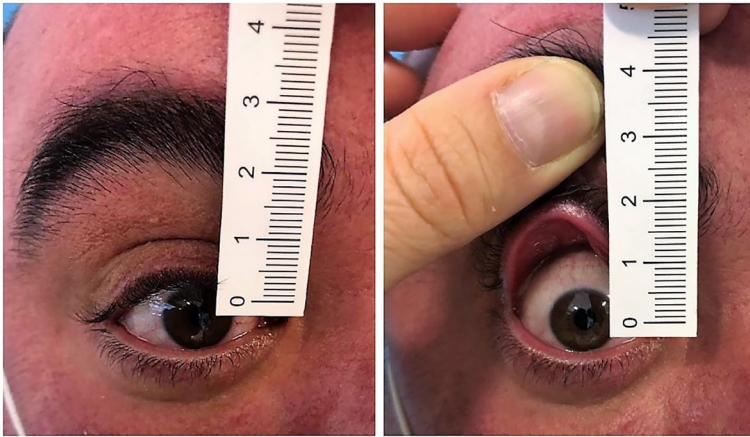

Figure 6. 'Vertical hyperlaxity' test measuring the distance between the palpebral rim and the center of the pupil during vertical traction of the eyelid (19 mm).

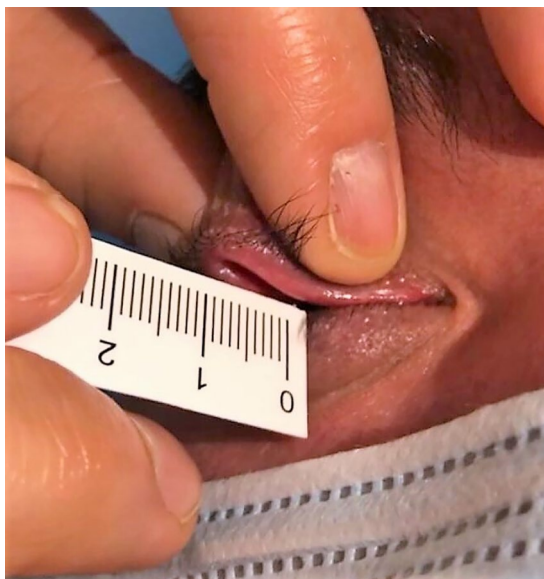

Figure 7. 'Upper horizontal distraction' test, measuring the distance between the anterior corneal pole and the anterior distracted upper eyelid.

Liu *et al.*³⁷ classified FES into three groups based on the amount of the upper tarsal conjunctiva (UTC) visible after eversion of the upper eyelid:

- Group 1 (mild): less than one third of the UTC visible;
- Group 2 (moderate): between one third and one half of the UTC visible;
- Group 3 (severe): more than one half of the UTC visible.

Similarly, Yeung *et al.*³⁸ graded FES into three groups based on the amount of exposed UTC observed on maximal traction of the upper lid and the presence of spontaneous eversion:

- Grade 1 (mild): UTC visible between 1/3 to 1/2;
- Grade 2 (moderate): UTC visible more than 1/2;
- Grade 3 (severe): spontaneous upper lid eversion on minimal lid retraction or on forced lid closure with UTC totally visible.

Beis *et al.*³⁵ staged FES into two groups:

- Group 1: in the presence of easy upper eyelid eversion which remains everted for up to 6 seconds despite the down gaze position of the eye or voluntary orbicularis muscle contraction;
- Group 2: in the presence of spontaneous upper eyelid eversion which remains everted for more than 6 seconds despite the down gaze position of the eye or voluntary orbicularis muscle contraction.

Medel *et al.*³⁹ realized that there was a direct relationship between the frequency of symptoms (foreign body sensation, tearing, irritation, photophobia) and the tarsal papillary reaction. Patients with no papillary reaction or papillae smaller than 0.3 mm were asymptomatic or presented few symptoms. Patients with a papillary reaction between 0.3 and 1 mm experienced frequent (although not constant) symptoms (several episodes per month). Therefore, they classified FES in three grades according to the severity of symptoms and the papillary reaction in the tarsal conjunctiva:

- Grade 0: no symptoms or sporadic symptoms and minimal papillary reaction;
- Grade 1: frequent symptoms, papillary reaction, and occasional keratitis, which were easily controlled with topical humectant treatment;
- Grade 2: included patients with constant symptoms and a considerable papillary reaction with corneal disease.

Dermatochalasis, ectropion/entropion, eyelid/lash ptosis, and OSD should be considered in the staging system but currently there is not a single classification that considers all the clinical features included in the FES.

Therapy

FES is treated with topical medication for related ocular surface diseases and/or with surgical approach. If medical management of FES fails, surgical approach is indicated for both symptomatic relief and preservation of ocular surface integrity. It is also important to treat comorbidities frequently associated both clinically and pathogenetically with FES. All patients with eyelid laxity should be assessed and treated for OSAHS to decrease overall systemic morbidity and mortality, it may also directly improve FES. In 2000 McNab *et al.* described a reversal of FES after treatment of OSAHS with continuous positive airway pressure therapy.⁴⁰

Medical therapy

The treatment involves eye shields, taping the eyelids during the night, topical lubricants or ointments, and the patient should be encouraged not to rub his or her eyelids, as this may exacerbate the lid laxity.^{1,2}

Recently, Vieira *et al.*⁴¹ demonstrated that the CPAP therapy might reverse FES and patients with non-reversible FES appear to have more severe OSAHS and a worse airway access.

However, the medical treatment of FES by lubrication and modulation of ocular surface inflammation is palliative when the pathogenetic causes are not treated.

Recently, 0.03% bimatoprost, a prostaglandin F2 α analogue used for the topical therapy of glaucoma, has been proposed as a possible alternative to surgery in the case of FES. The potential side effect is observed after a long-term therapy with topical bimatoprost, in particular, eyelid retraction/tightening, dermatochalasis involution, and deepening of upper eyelid sulcus could be an advantage in patients affected by FES reducing distractibility and laxity of the eyelid.⁴²

Surgical therapy

Various surgical techniques have been proposed for the correction of the superior eyelid laxity, focusing on the resolution of the upper eyelid spontaneous eversion.

The full-thickness 'wedge excision' and the 'lateral tarsal strip' were the first surgical techniques proposed to restore the normal anatomy of the eyelid.^{43,44} Further studies have proposed some modified surgical techniques introducing the 'medial tarsal strip', 'canthal tendon plication', 'tarsal strip/periosteal flap', 'conchal cartilage graft reinforcement', or simply the 'lateral tarsorrhaphy'.⁴⁵⁻⁵² In 2019, Waldie *et al.*⁵³ proposed the 'FESplasty' in which a periosteal flap based at the inferolateral orbital rim is applied to the anterior surface of the upper tarsal plate combined with an upper eyelid shortening procedure.

In 2010, a long-term study⁵¹ involving 71 patients who had undergone surgery for FES at Moorfields Eye Hospital demonstrated significant recurrence rates varying from 25.6% to 60.6% depending on the procedure used. The research provided strong evidence of better long-term outcomes using the medial/lateral canthal plication and lateral tarsal strip procedures in comparison with the full-thickness wedge excision procedure.

As there are many eyelid disorders associated with OSA and FES, surgeons should consider concurrent correction of eyelid malpositions (ptosis, entropion/ectropion) frequently associated with lid laxity.

Conclusion

FES occurs more frequently than expected because it is often under-diagnosed and misdiagnosed. Due to the frequent association with OSAHS, FES early recognition is important to avoid serious sight-threatening and life-threatening conditions. For these reasons, FES should be included in the diagnostic algorithm of patients with OSD and also in patients with OSAHS, and a multidisciplinary teamwork should be mandatory.

Author contributions

Conceptualization, Methodology, Writing-Review and Editing: ADG. Investigation, Writing Original draft, Software: AC. Formal analysis, Resources, Visualization: AS. Validation, Project administration: AL. Writing- Review and Editing, Conceptualization: EP. Supervision, Validation: SM.

Conflict of interest statement

The authors declared no potential conflicts of interest with respect to the research, authorship, and/or publication of this article.

Funding

The authors received no financial support for the research, authorship, and/or publication of this article.

ORCID iDs

Alessandra De Gregorio  <https://orcid.org/0000-0002-7287-0457>

Simonetta Morselli  <https://orcid.org/0000-0002-9503-6000>

References

1. Culbertson WW and Ostler HB. The floppy eyelid syndrome. *Am J Ophthalmol* 1981; 92: 568–575.
2. Parunovic A. Floppy eyelid syndrome. *Br J Ophthalmol* 1983; 67: 264–266.
3. Brown MD and Potter JW. Floppy eyelid syndrome: a case report and clinical review. *J Am Optom Assoc* 1992; 63: 309–314.
4. Van den Bosch WA and Lemij HG. The lax eyelid syndrome. *Br J Ophthalmol* 1994; 78: 666–670.
5. Ansari Z, Singh R, Alabiad C, *et al.* Prevalence, risk factors, and morbidity of eye lid laxity in a veteran population. *Cornea* 2015; 34: 32–36.
6. Fowler AM and Dutton JJ. Floppy eyelid syndrome as a subset of lax eyelid conditions: relationships and clinical relevance (an ASOPRS thesis). *Ophthalmic Plast Reconstr Surg* 2010; 26: 195–204.
7. Leibovitch I and Selva D. Floppy eyelid syndrome: clinical features and the association with obstructive sleep apnea [Comment in: *Sleep Med* 2006; 7: 97–99]. *Sleep Med* 2006; 7: 117–122.
8. Sleep-related breathing disorders in adults: recommendations for syndrome definition and measurement techniques in clinical research. The Report of an American Academy of Sleep Medicine Task Force. *Sleep* 1999; 22: 667–689.
9. Cho JH, Choi JH, Suh JD, *et al.* Comparison of anthropometric data between Asian and Caucasian patients with obstructive sleep apnea: a meta-analysis. *Clin Exp Otorhinolaryngol* 2016; 9: 1–7.
10. Garvey JF, Pengo MF, Drakatos P, *et al.* Epidemiological aspects of obstructive sleep apnea. *J Thorac Dis* 2015; 7: 920–929.
11. Woog J. Obstructive sleep apnea and the floppy eyelid syndrome. *Am J Ophthalmol* 1990; 110: 314–315.
12. McNab AA. Floppy eyelid syndrome and obstructive sleep apnea. *Ophthalmoplastreconstr Surg* 1997; 13: 98–114.
13. Pedrotti E, Demasi CL and Bruni E. Prevalence and risk factors of eye diseases in adult patients with obstructive sleep apnoea: results from the SLE.E.P.Y cohort study. *BMJ Open* 2017; 7: e016142.
14. Kendzerska T, Gershon AS, Hawker G, *et al.* Obstructive sleep apnea and risk of cardiovascular events and all-cause mortality: a decade-long historical cohort study. *PLoS Med* 2014; 11: e1001599.
15. Hirotsu C, Albuquerque RG, Nogueira H, *et al.* The relationship between sleep apnea, metabolic dysfunction and inflammation: the gender influence. *Brain Behav Immun* 2017; 59: 211–218.
16. Karger RA, White WA, Park WC, *et al.* Prevalence of floppy eyelid syndrome in obstructive sleep apnea-hypopnea syndrome. *Ophthalmology* 2006; 113: 1669–1674.
17. Eiferman RA, Gossman MD, O’Neill K, *et al.* Floppy eyelid syndrome in a child. *Am J Ophthalmol* 1990; 109: 356–357.
18. Gross RH and Mannis MJ. Floppy eyelid syndrome in a child with chronic unilateral conjunctivitis. *Am J Ophthalmol* 1997; 124: 109–110.
19. Paciuc M and Mier ME. A woman with the floppy eyelid syndrome. *Am J Ophthalmol* 1982; 93: 255–256.
20. Rao LG, Bhandary SV, Devi AR, *et al.* Floppy eyelid syndrome in an infant. *Indian J Ophthalmol* 2006; 54: 217–218.
21. Ezra DG, Beaconsfield M, Sira M, *et al.* The associations of floppy eyelid syndrome: a case control study. *Ophthalmology* 2010; 117: 831–838.
22. Maspero C, Giannini L, Galbiati G, *et al.* Obstructive sleep apnea syndrome: a literature review. *Minerva Stomatol* 2015; 64: 97–109. (in English, Italian)
23. Sun SY, Pulido JS, Bartley GB, *et al.* Floppy eyelid syndrome in stickler syndrome. *Am J Ophthalmol Case Rep* 2019; 14: 14–15.

24. Nuruddin M. Management of floppy eyelid associated with Down's syndrome: a case report. *Orbit* 2012; 31: 370–372.
25. Ezra DG, Derriman L, Mellington FE, *et al.* Spontaneous globe luxation associated with shallow orbits and floppy eyelid syndrome. *Orbit* 2008; 27: 55–58.
26. Segev F, Héon E, Cole WG, *et al.* Structural abnormalities of the cornea and lid resulting from collagen V mutations. *Invest Ophthalmol Vis Sci* 2006; 47: 565–573.
27. Netland PA, Sugrue SP, Albert DM, *et al.* Histopathologic features of the floppy eyelid syndrome. Involvement of tarsal elastin. *Ophthalmology* 1994; 101: 174–181.
28. Schlötzer-Schrehardt U, Stojkovic M, Hofmann-Rummelt C, *et al.* The pathogenesis of floppy eyelid syndrome: involvement of matrix metalloproteinases in elastic fiber degradation. *Ophthalmology* 2005; 112: 694–704.
29. Taban M, Taban M and Perry JD. Plasma leptin levels in patients with floppy eyelid syndrome. *Ophthalmic Plast Reconstr Surg* 2006; 22: 375–377.
30. Donnenfeld ED, Perry HD, Gibraltar RP, *et al.* Keratoconus associated with floppy eyelid syndrome. *Ophthalmology* 1991; 98: 1674–1678.
31. Figueira EC, Chen TS, Agar A, *et al.* LESCc: lateralizing eyelid sleep compression study. *Ophthalmic Plast Reconstr Surg* 2014; 30: 473–475.
32. Ting RJE, Singh N, Ling M, *et al.* Assessment of obstructive sleep apnoea and sleeping laterality by evaluating upper eyelid distraction: a prospective, comparative polysomnographic study. *Cureus* 2020; 12: e9566.
33. Robert PY, Adenis JP, Tapie P, *et al.* Eyelid hyperlaxity and obstructive sleep apnea (O.S.A.) syndrome. *Eur J Ophthalmol* 1997; 7: 211–215.
34. Iyengar SS and Khan JA. Quantifying upper eyelid laxity in symptomatic floppy eyelid syndrome by measurement of anterior eyelid distraction. *Ophthalmic Plast Reconstr Surg* 2007; 23: 255.
35. Beis PG, Brozou CG, Gourgoulisian KI, *et al.* The floppy eyelid syndrome: evaluating lid laxity and its correlation to sleep apnea syndrome and body mass index. *ISRN Ophthalmol* 2012; 2012: 650892.
36. Sward M. Lax eyelid syndrome (LES), obstructive sleep apnea (OSA), and ocular surface inflammation. *Ocul Surf* 2018; 16: 331–336.
37. Liu DT, Di Pascuale MA, Sawai J, *et al.* Tear film dynamics in floppy eyelid syndrome. *Invest Ophthalmol Vis Sci* 2005; 46: 1188–1194.
38. Yeung AM, Ashfaq I, Ghosh YK, *et al.* Floppy eyelid syndrome: the coventry experience. *Orbit* 2014; 33: 399–405.
39. Medel R, Alonso T, Vela JL, *et al.* Conjunctival cytology in floppy eyelid syndrome: objective assessment of the outcome of surgery. *Br J Ophthalmol* 2009; 93: 513–517.
40. McNab AA. Reversal of floppy eyelid syndrome with treatment of obstructive sleep apnoea. *Clin Exp Ophthalmol* 2000; 28: 125–126.
41. Vieira MJ, Silva MJ, Lopes N, *et al.* Prospective evaluation of floppy eyelid syndrome at baseline and after CPAP therapy. *Curr Eye Res* 2021; 46: 31–34.
42. De Gregorio A, Pedrotti E, Stevan G, *et al.* Floppy eyelid syndrome and ectropion improvement after 1 month of 0.03% bimatoprost topical therapy. *Am J Ophthalmol Case Rep* 2020; 20: 100938.
43. Gerner EW and Hughes SM. Floppy eyelid with hyperglycinemia. *Am J Ophthalmol* 1984; 98: 614–616.
44. Dutton JJ. Surgical management of floppy eyelid syndrome. *Am J Ophthalmol* 1985; 99: 557–560.
45. Kraissl CJ. The selection of appropriate lines for elective surgical incisions. *Plast Reconstr Surg* 1951; 8: 1–28.
46. Borges AF and Alexander JE. Relaxed skin tension lines, Z-plasties on scars, and fusiform excision of lesions. *Br J Plast Surg* 1962; 15: 242–254.
47. Periman LM and Sires BS. Floppy eyelid syndrome: a modified surgical technique. *Ophthalmic Plast Reconstr Surg* 2002; 18: 370–372.
48. Burkat CN and Lemke BN. Acquired lax eyelid syndrome: an unrecognized cause of the chronically irritated eye. *Ophthalmic Plast Reconstr Surg* 2005; 21: 52–58.
49. Valenzuela AA and Sullivan TJ. Medial upper eyelid shortening to correct medial eyelid laxity in floppy eyelid syndrome: a new surgical approach. *Ophthalmic Plast Reconstr Surg* 2005; 21: 259–263.
50. Abenavoli FM, Lofoco G and DeGaetano C. A technique to correct floppy eyelid syndrome. *Ophthalmic Plast Reconstr Surg* 2008; 24: 497–498.
51. Ezra DG, Beaconsfield M, Sira M, *et al.* Long-term outcomes of surgical approaches to the treatment of floppy eyelid syndrome. *Ophthalmology* 2010; 117: 839–846.
52. Phillips ME, Fowler BT, Dryden SC, *et al.* Canthal V-plasty for floppy eyelid surgery. *Plast Reconstr Surg Glob Open* 2019; 7: e2464.
53. Waldie AM, Francis IC, Coroneo MT, *et al.* Floppy eyelid syndrome 'plasty' procedure: employment of a periosteal transposition flap for surgery of floppy eyelid syndrome. *Clin Exp Ophthalmol* 2019; 47: 864–870.