
Delayed diagnosis of short QT syndrome concealed by pacemaker implant due to sick sinus syndrome

 **Ibrahim Başarıcı**
Department of Cardiology, Faculty of Medicine, Akdeniz University;
Antalya-Turkey

Introduction

Patients with rare diseases unfortunately confront with late or misdiagnosis issues due to unawareness and ignorance of ordinary physicians inexperienced in related subject. Short QT

syndrome (SQTS) is a rare and highly mortal inherited channelopathy. In this case report, we present delayed diagnosis of a SQTS case and underscore red flags to avoid misdiagnosis with sick sinus syndrome (SSS).

Case Report

A 26-year-old woman suffering from brief dizziness periods and atypical chest pain was evaluated. A VVI pacemaker was implanted for SSS at the age of 8 years. Atrial fibrillation (AF) was detected when the battery was replaced; on follow-up, she experienced frequent episodes of AF with rapid ventricular response. At the age of 21 years, her pacemaker was upgraded to DDD mode following a successful radiofrequency ablation of AF. Despite amiodarone treatment, AF recurred 18 months later, and electrical cardioversion failed to restore sinus rhythm. On presentation, she was on aspirin and metoprolol, and her physical examination was unremarkable except for a pansystolic murmur at the tricuspid area. Electrocardiography (ECG) indicated AF and pure ventricular pacing (Fig. 1a). Echocardiography displayed normal left ventricular function, mildly dilated left atria, and moderate tricuspid valve regurgitation. Laboratory findings were normal including serum electrolyte levels. Pacemaker interrogation indicated a chronically elevated pacing

threshold. Telecardiogram displayed retracted ventricular lead, whereas atrial lead was overlapped and bended toward the tricuspid valve. There was no evidence of significant dysrhythmia or pacemaker malfunction on prolonged Holter monitoring, but QT interval variation between paced and conducted beats was noticed (Fig. 1b). A repeat ECG revealed short QT interval (Fig. 1c) and was confirmed by sinus rhythm tracings found in past medical records (Fig. 1d). Family history was alarming as her father and grandfather had sudden cardiac deaths (SCDs). Her father was also diagnosed with SSS, and a VVI pacemaker was implanted before his SCD. Her father's available ECG tracing was consistent with AF and paced rhythm with a short QT interval more prominent in conducted beats (Fig. 1e). Therefore, a genetic testing was performed, and p.V141M_ *KCNQ1* mutation was identified confirming SQTS. Metoprolol was switched to sotalol. In addition, an implantable cardioverter defibrillator (ICD) upgrade procedure was performed involving extraction of the pacemaker leads.

Discussion

Diverse presentations of SSS involves chronotropic incompetence, episodic/persistent bradycardia, sinus pause/arrest,

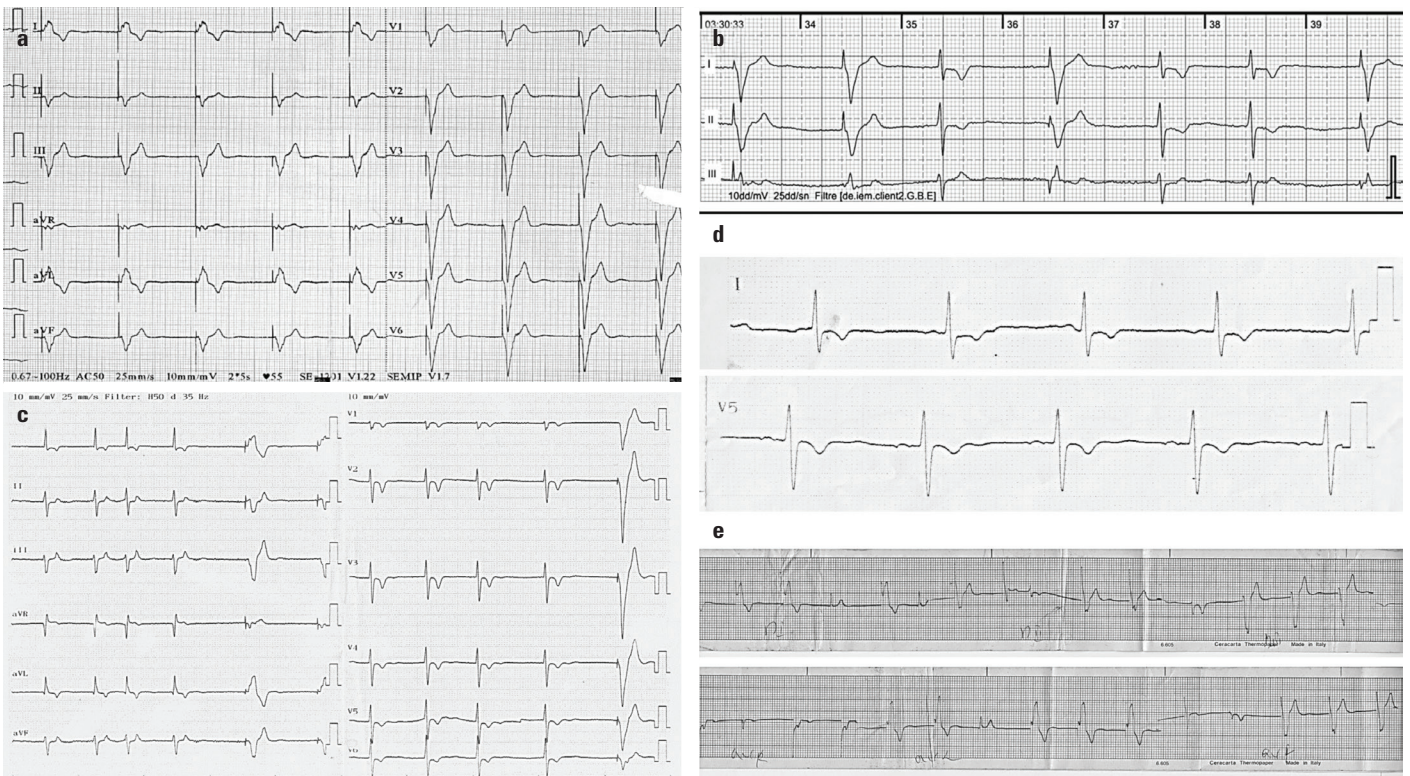


Figure 1. (a) The initial ECG captured during AF and pure ventricular pacing masks SQTS (corrected QT: 402 ms). (b) Event recording displays prominent QT variation between paced (400 ms) and conducted (320 ms) beats. (c) A repeat ECG suggests SQTS diagnosis with short QT interval (QT: 280 ms and corrected QT: 340 ms) prominent during conducted beats. (d) Sinus rhythm tracings found in past medical records confirm SQTS (corrected QT: 330 ms) in the index patient. (e) Deceased father's available ECG tracing also confirms SQTS as QT interval was short in both paced and conducted beats during AF

and occasional atrial tachyarrhythmias (1). It accounts for considerable amount of pacemaker implantations. Comprehensive clinical and ECG evaluation to assure symptom–rhythm correlation is a must before pacemaker implantation. Because SSS shares common symptoms (fatigue, palpitations, dizziness, or syncope) and components (sinus dysfunction and AF) with inherited primary arrhythmia syndromes and in some cases bradycardia might be a consequence of atrial tachyarrhythmias. SQTS is a rare disease associated with atrial and ventricular tachyarrhythmias and high risk of SCD (2). From sinus node dysfunction to AF, different aspects of SQTS may manifest in an evolutionary pattern as previously described (3), and short QT interval might be unrecognized such as the presented case. Syncope as initial presentation is not uncommon in SQTS, but generally, its association with SQTS cannot be established, resulting in delayed diagnosis (2). Thus, marked bradycardia or AF in childhood and adolescence should alert physicians to suspect SQTS (2). SQTS is diagnosed (4) if the patient's corrected QT interval is ≤ 340 ms. If it is ≤ 360 ms, one of the following additional criteria is required: (1) confirmed pathogenic mutation, (2) family history of SQTS, (3) family history of SCD before age <40 , and (4) survival from a VT/VF episode in the absence of structural heart disease. In our case, short QT interval was confirmed during conducted ventricular beats, but not in paced beats. However, short QT interval in the past ECG tracings was overlooked, and she and her father were both misdiagnosed with SSS. Prolonged QT interval during ventricular pacing may obscure the diagnosis, possibly when a purely paced ECG is obtained. Because pacing induced myocardial depolarization conduction wave is slower, hence the repolarization is also longer. Currently, mutations in three potassium (KCNH2, KCNQ1, and KCNJ2) and L-type cardiac calcium channel genes have been defined in association with SQTS (2, 4). In this case a highly pathogenic p.V141M_ *KCNQ1* mutation was identified warranting the SQTS diagnosis which is particularly related with cardiomyopathic changes in the left ventricle (5). Her family history supported the diagnosis and poor outcome expectation. There is no validated risk stratification scheme for SQTS, and electrophysiological study has no added value. Theoretically, patients may benefit from antiarrhythmic drugs that prolong QT interval. Hydroquinidine or sotalol is offered in asymptomatic patients with a family history of SCD or to those who refuse ICD implantation when indicated (4). Although the beneficial effect of sotalol is lacking in certain mutations, sotalol was prescribed until the preferential choice hydroquinidine (4, 6) is obtained from abroad. The patient's dizziness complaints may be related to nonsustained ventricular tachycardia episodes which could not be captured by prolonged Holter monitoring. However, individually, pacemaker leads were extracted, and an ICD was implanted. Currently, ICD implantation is offered only to survivors of aborted cardiac arrest and patients with SQTS with documented episodes of ventricular tachycardia (4). Based on strong family history of SCD and

additional ECG evidence of SQTS diagnosis in her deceased father and reported dismal prognosis in p.V141M mutations, ICD implantation was considered beneficial in such a young patient. The leads requiring revision due to their unfavorable position also influenced our decision.

Conclusion

SQTS is a highly lethal inherited cardiac channelopathy. Initial presentation may simulate SSS. When an SSS diagnosis is established, especially in children and young patients with slow heart rates and AF, the cardiologists should also keep in mind the possibility of SQTS. A careful systematic ECG analysis in pacemaker patients and comprehensive family history may avoid misdiagnosis as SSS.

Informed consent: An informed consent was obtained from the patient.

References

1. DePonti R, Marazzato J, Bagliani G, Leonelli F, Padeletti L. Sick Sinus Syndrome. *Card Electrophysiol Clin* 2018; 10: 183-95.
2. Bjerregaard P. Diagnosis and management of short QT syndrome. *Heart Rhythm* 2018; 15: 1261-7.
3. Righi D, Silvetti D, Drago F. Sinus bradycardia, junctional rhythm, and low-rate atrial fibrillation in short QT syndrome during 20 years of follow-up: three faces of the same genetic problem. *Cardiol Young* 2016; 26: 589-92.
4. Priori SG, Blomström-Lundqvist C, Mazzanti A, Blom N, Borggrefe M, Camm J, et al.; ESC Scientific Document Group. 2015 ESC Guidelines for the management of patients with ventricular arrhythmias and the prevention of sudden cardiac death: The Task Force for the Management of Patients with Ventricular Arrhythmias and the Prevention of Sudden Cardiac Death of the European Society of Cardiology (ESC). Endorsed by: Association for European Paediatric and Congenital Cardiology (AEPC). *Eur Heart J* 2015; 36: 2793-867.
5. Sarquella-Brugada G, Campuzano O, Iglesias A, Grueso J, Bradley DJ, Kerst G, et al. Short QT and atrial fibrillation: A KCNQ1 mutation-specific disease. Late follow-up in three unrelated children. *Heart-Rhythm Case Rep* 2015; 1: 193-7.
6. Mazzanti A, Maragna R, Vacanti G, Kostopoulou A, Marino M, Monteforte N, et al. Hydroquinidine prevents life-threatening arrhythmic events in patients with short QT syndrome. *J Am Coll Cardiol* 2017; 70: 3010-5.

Address for Correspondence: Dr. İbrahim Başarıcı,

Akdeniz Üniversitesi Hastanesi,
Kardiyoloji Anabilim Dalı,
07058-Konyaaltı,
Antalya- Türkiye

Phone: +90 242 249 68 06

E-mail: ibasarici@gmail.com

©Copyright 2020 by Turkish Society of Cardiology - Available online at www.anatoljcardiol.com

DOI:10.14744/AnatolJCardiol.2019.74318

