




Mid-Term Safety and Efficacy of the Modified Double Hydrodistention Implantation Technique (HIT), Termed Systematic Multi-Site HIT (SMHIT), for Patients with Primary Vesicoureteral Reflux

This article was published in the following Dove Press journal:
Research and Reports in Urology

Shigeru Nakamura ¹
Kazuya Tanabe¹
Taiju Hyuga^{1,2}
Taro Kubo¹
Satoru Inoguchi ¹
Shina Kawai ¹
Hideo Nakai¹

¹Department of Pediatric Urology, Jichi Medical University, Children's Medical Center Tochigi, Shimotsuke, Japan;

²Department of Developmental Genetics, Institute of Advanced Medicine, Wakayama Medical University (WMU), Wakayama, Japan

Purpose: To evaluate the treatment outcomes and postoperative complications associated with the systematic multi-site hydrodistention implantation technique (SMHIT) for primary vesicoureteral reflux (VUR) and to determine its mid-term efficacy and safety.

Patients and Methods: We retrospectively reviewed the data for 17 ureters from 12 consecutive children, aged ≥ 1 year, with grade II–IV reflux and a history of febrile urinary tract infections (FUTI), who underwent a single-session of SMHIT. The primary outcome was the absence of postoperative FUTI (clinical success). The secondary outcome was improvement in reflux to grade 0–I on postoperative voiding cystourethrography (radiographic success).

Results: Five and 7 children had bilateral and unilateral reflux, respectively. Reflux was categorized as grade II, III, and IV reflux in 2, 12, and 3 ureters, respectively. Seven of 10 (70%) toilet-trained children had bladder-bowel dysfunction (BBD) preoperatively. The SMHIT was performed for all patients, after which BBD improved. The mean postoperative follow-up period was 6 years and 9 months. The clinical success rate was 100%. Radiographic success was achieved in 16/17 ureters (94%) at 3–4 months, 17/17 (100%) ureters at 1 year, and 17/17 (100%) ureters at 3 years postoperatively. Major complications did not develop postoperatively.

Conclusion: When prioritizing treatment of concomitant BBD in children with primary VUR and avoiding dextranomer/hyaluronic acid injection therapy in contraindicated children according to the Food and Drug Administration recommendations, a single-session of SMHIT may be as effective and safe in the mid-term as performing open anti-reflux surgery.

Keywords: dextranomer hyaluronic acid, Dx/HA, endoscopic treatment, vesicoureteral reflux

Introduction

For primary vesicoureteral reflux (VUR), dextranomer/hyaluronic (Dx/HA) acid injection therapy (IT) is administered by subureteral transurethral injection (STING) and the hydrodistention implantation technique (HIT); since 2008, the double HIT has also been used. This therapy has since been widely adopted.¹ The radiographic success rate, defined as the VUR cure rate based on postoperative voiding cystourethrography (VCUG), of Dx/HA-IT is lower than that of open surgery. Most reports only describe short-term radiographic success rates at 3

Correspondence: Shigeru Nakamura
Department of Pediatric Urology, Jichi Medical University, Children's Medical Center, 3311-1, Yakushiji, Shimotsuke, Tochigi 329-0498, Japan
Tel +81-285-44-2111
Fax +81-285-44-8452
Email naka251148@gmail.com

months postoperatively. Only sporadic reports have described mid-term radiographic success rates beyond 1 year postoperatively; they showed a mid-term VUR recurrence rate of 13–26% at 1–5 years postoperatively with STING.^{2–5} Because the American Urological Association (AUA) guidelines state that open surgery or IT should be performed to treat VUR,⁶ the high VUR recurrence with IT remains a problem. The fact that the bulge generated by Dx/HA causes coaptation of the ureteral orifice and intramural ureter is the fundamental reason for which Dx/HA-IT is performed for VUR. Therefore, we decided to develop our original technique, which was named the systematic multi-site hydrodistention implantation technique (SMHIT), by modifying double HIT. SMHIT generates bulges, which can be directly visually assessed, by sequentially and systematically administering multiple Dx/HA injections from the proximal to the distal part of the intramural ureter. The coaptation area of the intramural ureter can be extended out further by SMHIT than by double HIT.

In 2001, the Food and Drug Administration (FDA) approved Dx/HA for IT use in children with grade II–IV primary VUR, with contraindications for grade V VUR, non-functioning kidneys, Hutch diverticulum, ureterocele, ongoing urinary tract infections (UTIs), or active voiding dysfunction (bladder-bowel dysfunction [BBD]). Additionally, the Dx/HA package insert does not indicate the efficacy and safety in children aged <1 year.⁷ As Dx/HA-IT has become widely adopted, its off-label use as increased; consequently, the VUR recurrence rate and incidence of postoperative complications increased.^{6,8} No further reports have evaluated the radiographic success rate beyond 3 years after HIT or double HIT.

Therefore, we aimed to evaluate the treatment outcomes and postoperative complications after using the SMHIT in all children eligible for Dx/HA-IT according to the FDA and to determine the mid-term efficacy and safety of SMHIT for primary VUR.

Patients and Methods

We retrospectively reviewed the data of 17 ureters from 12 consecutive children with primary VUR who underwent a single-session of SMHIT by a single surgeon (S.N.) between February 2011 and December 2016. Data were extracted from patient charts. This study was approved by the Clinical Research Institutional Review Board of Jichi Medical University Hospital and performed in accordance

with the Declaration of Helsinki. Written informed consent was obtained from all parents.

VUR was preoperatively diagnosed by VCUG and graded according to the International Classification System guidelines. A technetium-99m dimercaptosuccinic acid (DMSA) scan, at least 6 months after the last febrile UTI (FUTI), and renal ultrasound were preoperatively performed in all children. Renal function on the affected side was assessed by DMSA scan. Normal, moderate, and poor renal function were defined as a renal uptake that accounted for 45–55%, 20–45%, and <20% of the total renal activity, respectively.

The surgical procedure for treating VUR was either open surgery or SMHIT according to the family's request. The indications for SMHIT were similar to those for open surgery. SMHIT was indicated in children aged ≥ 1 year with grade II–IV VUR and a history of at least one episode of FUTI with a breakthrough UTI, new onset renal scarring, and older children with persistent VUR. Among toilet-trained children, SMHIT was indicated in those without BBD and those with BBD and grade II–IV VUR, persisting after BBD treatment. BBD was defined as urinary frequency and urgency, prolonged voiding intervals, daytime wetting, perineal/penile pain, holding maneuvers, and constipation/encopresis in toilet-trained children, according to the AUA guidelines.⁶ The treatment of BBD was based on urotherapy, including instructing regular voiding, timed voiding, complete bladder emptying during voiding, and regular bowel movements and increased fiber intake for defecation. Laxatives were administered as needed.⁶

SMHIT was performed in a lithotomy position under general anesthesia. A 9.5-Fr offset lens endoscope (Karl Storz) was used. The detailed SMHIT procedure is shown in Figures 1–3. Prior to needle insertion, while the ureteral orifice on the affected side was dilated by hydraulic pressure generated by physiological saline injected by an assistant, an endoscope was inserted into the ureter to observe the intramural ureter. Multiple Dx/HA injections were sequentially and systematically administered from the proximal to the distal intramural ureter. When Dx/HA induced insufficient bulging, the insertion depth of the needle was lessened, and Dx/HA was further injected until sufficient bulging was confirmed. Injected Dx/HA rarely leaked out from previously punctured holes. When it did, however, the insertion depth or puncture site was changed accordingly. While injections were performed multiple times up to the area near the ureteral orifice,

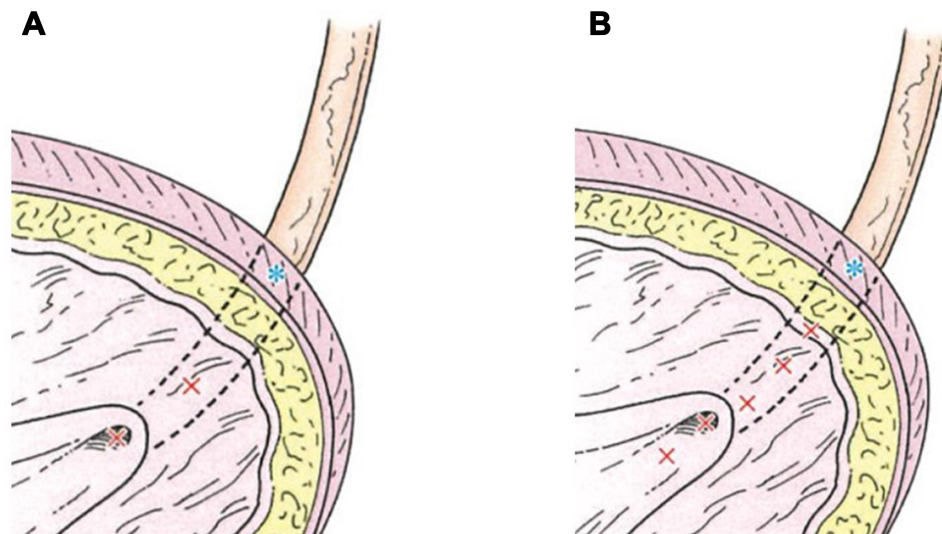


Figure 1 Dextranomer/hyaluronic acid (Dx/HA) injection therapies for primary vesicoureteral reflux. * Extravesical portion of ureter (adjacent to ureteral hiatus). x: position of needle insertion. **(A)** Double hydrodistention implantation technique (double HIT). **(B)** Systematic-multisite hydrodistention implantation technique (SMHIT). These figures show the coronal section of the ureterovesical junction. Multiple Dx/HA injections are sequentially and systematically administered from the proximal to the distal intramural ureter in SMHIT. The coaptation area of the intramural ureter created by Dx/HA bulges can be extended out further by SMHIT than by double HIT.

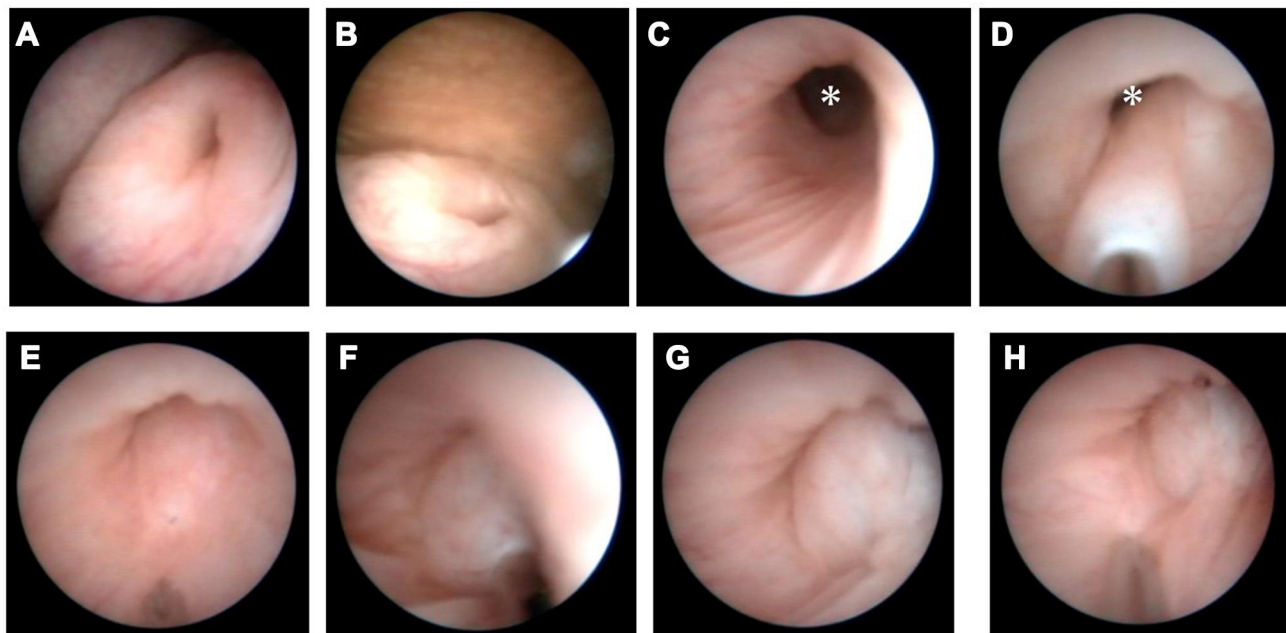


Figure 2 The first half of SMHIT (systematic-multisite hydrodistention implantation technique) for left VUR grade IV. * Extravesical portion of ureter (adjacent to ureteral hiatus). **(A)** Left ureteral orifice before SMHIT. **(B)** Mild opening of the ureteral orifice during hydrodistention. **(C)** Intramural ureter. **(D)** First insertion of a needle and injection of Dx/HA. **(E)** Bulge after first injection of Dx/HA and second insertion of a needle. **(F)** Second injection of Dx/HA. **(G)** Bulge after second injection of Dx/HA. **(H)** Bulge after second injection of Dx/HA and third insertion of a needle.

Dx/HA was injected into the entire intramural ureter along the ureteral course. Next, a relatively deep needle insertion was performed in a 6-o'clock position at the ureteral orifice, and the final Dx/HA injection was performed to turn the ureteral orifice upward and let the entire intramural ureter bulge into the bladder lumen. Finally,

hydrodistention at the ureteral orifice was performed again. After the ureteral orifice was confirmed not to have dilated and urine flow was confirmed from the orifice, surgery was completed.

In this study, the primary outcome was clinical success, defined by a lack of any evidence of postoperative FUTU.

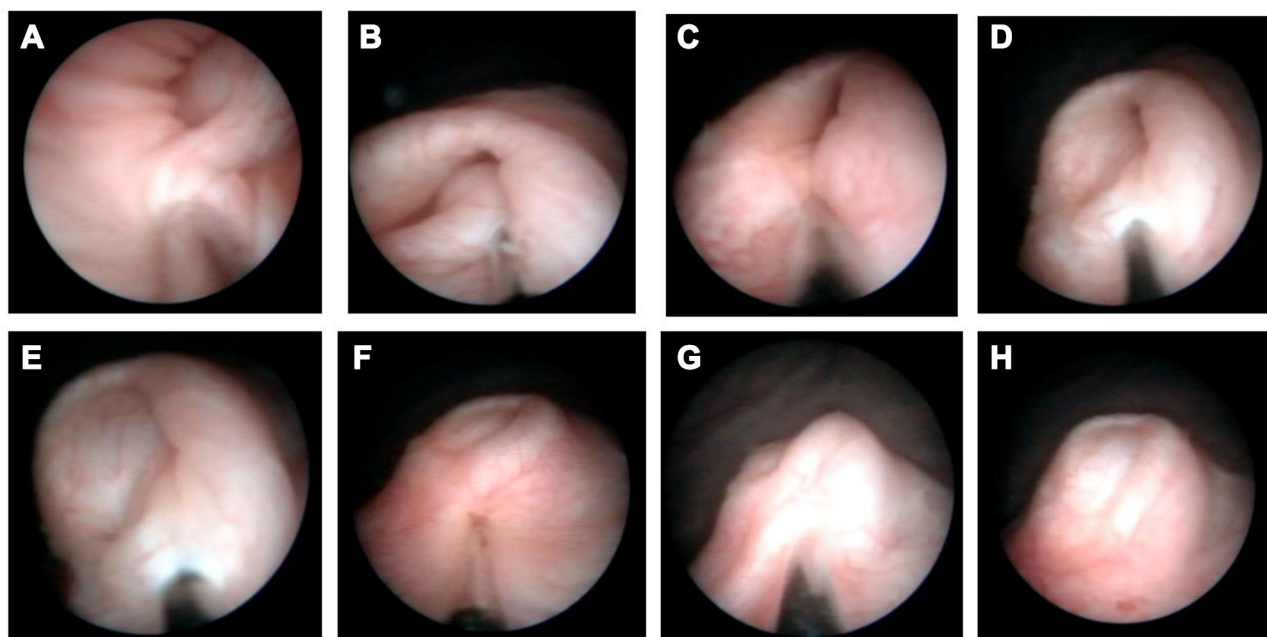


Figure 3 The latter half of SMHIT (systematic-multisite hydrodistention implantation technique) for left VUR grade IV (**A** and **B**) Third injection of Dx/HA. (**C**) Fourth insertion of a needle. (**D** and **E**) Fourth injection of Dx/HA (STING (suburethral transurethral injection) technique). (**F**) Fifth insertion of a needle. (**G**) Fifth injection of Dx/HA. (**H**) Left ureteral orifice after SMHIT.

The secondary outcome was radiographic success, defined by an improvement in VUR to grade 0–I at 3–4 months, 1 year, and 3 years on postoperative VCUG.^{9,10} All children received prophylactic antibiotics until VCUG was performed 3–4 months postoperatively. They were followed up with urinalysis, and renal ultrasound was performed every 1–3 months for the first year postoperatively and every 6 months to 1 year during the subsequent years.

Results

Table 1 summarizes the preoperative patient characteristics of the study group, and **Table 2** shows the intraoperative and postoperative results of this group.

SMHIT was performed in three boys and nine girls. The mean age at surgery was 8 years (range 1 y 6 m to 12 y 9 m). There were 10 toilet-trained children (83%). Five and 7 children had bilateral and unilateral VUR, respectively. There were 2, 8, and 2 children with grade II, III, and IV VUR, with bilateral VUR in children with higher grades of VUR. VUR was categorized as grade II, III, and IV in 2, 12, and 3 ureters, respectively. Of the 17 ureters, 15 (88%) were grade III or higher. VUR that occurred during urine storage was termed filling VUR, and VUR that occurred during voiding was termed voiding VUR. There were 10 (83%) and 2 children with filling and voiding VUR, respectively. Based on DMSA scans, renal

function on the affected side was normal in 14 ureters and moderately impaired in 3 ureters. SMHIT was performed because of breakthrough UTIs and persistent VUR in 3 and 9 children, respectively. Seven of the 10 toilet-trained children (70%) had preoperative BBD (100% female; mean age: 10 y 1 m, range: 5 y 9 m to 12 y 9 m). Four girls had only voiding symptoms, one had only defecation symptoms, and two had both. In all 7 girls, SMHIT was performed after BBD improved. The mean duration of BBD treatment was 23 (7–52) months. A single session of SMHIT was applied to all ureters. The endoscope was smoothly inserted into all ureters. The mean number of injections and mean dose of Dx/HA injections per ureter were 4.3 (3–7) and 0.89 (0.5–1.8) mL, respectively.

The mean postoperative follow-up period was 6 years and 9 months (range: 4 y 3 m to 9 y 2 m). The clinical success rate was 100%. Radiographic success was achieved in 16/17 ureters (94%) (grade III=1, grade 0=16) at 3–4 months, 17/17 ureters (100%) (grade I=2, grade 0=15) at 1 year, and 17/17 ureters (100%) (grade I=2, grade 0=15) at 3 years postoperatively. As for postoperative complications, lumbar pain on the affected side was observed in only 1 child on postoperative day 1 (Case 9). There were no cases of persistent hematuria or hydronephrosis, ureteral obstruction (UO), ureteral calculus, renal impairment, or other complications. The seven

Table 1 Preoperative Patient Characteristics

Patient	Sex	Age at SMHIT	Affected Side of VUR	Grade of Preoperative VUR*	Split Renal Function (%)	Timing of VUR	Preoperative BBD		
							Voiding Symptoms	Defecation Symptoms	Duration of BBD Treatment (Months)
1	Female	5y9m	Bilateral Right Left	III III	50 50	Filling	+	+	13
2	Female	8y8m	Unilateral Left	III	47	Voiding	+	-	21
3	Male	10y3m	Unilateral Right	III	46	Filling	-	-	-
4	Female	9y4m	Bilateral Right Left	III III	45 55	Filling	+	-	18
5	Male	1y8m	Bilateral Right Left	IV IV	47 53	Filling	-	-	-
6	Female	12y4m	Unilateral Right	III	47	Filling	+	-	23
7	Female	7y6m	Bilateral Right Left	III III	48 52	Filling	-	-	-
8	Female	12y9m	Unilateral Left	II	51	Filling	-	+	7
9	Female	9y7m	Unilateral Left	II	42	Filling	+	+	27
10	Female	11y11m	Unilateral Left	III	41	Voiding	+	-	52
11	Female	1y6m	Bilateral Right Left	IV III	49 51	Filling	-	-	-
12	Male	5y6m	Unilateral Left	III	21	Filling	-	-	-
Average		8y0m							23

Notes: *The grade of VUR was determined according to the International Classification System (International Reflux Study Committee).

Abbreviations: BBD, bladder-bowel dysfunction; SMHIT, systematic multi-site hydrodistention implantation technique; VUR, vesicoureteral reflux.

Table 2 Intraoperative and Postoperative Results

Patient	Sex	Age at SMHIT	Indication for SMHIT	Affected Side of VUR	Grade of Preoperative VUR*	Number of Needle Insertion	Dose of Dx/HA Injection (mL)	Grade of Postoperative VUR*			Postoperative Complications	Postoperative FUTIs	Postoperative Follow-Up Period
								3-4 Months	1 Year	3 Years			
1	Female	5y9m	Persistent VUR	Bilateral	Right Left	4 5	0.5 0.5	0 0	1 0	0 0	-	-	9y2m
2	Female	8y8m	Persistent VUR	Unilateral	Left	3	0.6	0	0	0	-	-	9y0m
3	Male	10y3m	Persistent VUR	Unilateral	Right	3	0.8	0	0	0	-	-	9y0m
4	Female	9y4m	Persistent VUR	Bilateral	Right Left	4 3	0.9 0.5	0 0	1 0	0 0	-	-	8n2m
5	Male	1y8m	Breakthrough FUTi	Bilateral	Right Left	4 3	0.6 0.5	III 0	0 0	1 0	-	-	7y11m
6	Female	12y4m	Persistent VUR	Unilateral	Right	6	1.8	0	0	0	-	-	7y1m
7	Female	7y6m	Persistent VUR	Bilateral	Right Left	7 3	1.5 0.5	0 0	0 0	0 0	-	-	6y8m
8	Female	12y9m	Persistent VUR	Unilateral	Left	6	1.4	0	0	0	-	-	5y8m
9	Female	9y7m	Persistent VUR	Unilateral	Left	5	1.2	0	0	0	Left lumbar pain	-	5y1m
10	Female	11y11m	Breakthrough FUTi	Unilateral	Left	5	1.1	0	0	0	-	-	5y0m
11	Female	1y6m	Breakthrough FUTi	Bilateral	Right Left	4 4	1.3 1	0 0	0 0	0 0	-	-	4y7m
12	Male	5y6m	Persistent VUR	Unilateral	Left	4	0.5	0	0	0	-	-	4y3m
Average		8y0m				4.3	0.89						6y9m

Notes: *The grade of VUR was determined according to the International Classification System (International Reflux Study Committee).
Abbreviations: Dx/HA, dextranomer/hyaluronic acid; FUTi, febrile urinary tract infection; SMHIT, systematic multi-site hydrodistention implantation technique; VUR, vesicoureteral reflux.

children with preoperative BBD continued urotherapy postoperatively; none experienced BBD recurrence.

Discussion

This study was the first to evaluate the mid-term postoperative radiographic success rates based on VCUG in all children with primary VUR who underwent a single session of SMHIT, which was originally modified double HIT. None of these children developed any mid-term postoperative complications. Both clinical success rates and radiographic success rates were 100%. This study suggested that SMHIT is an effective and safe technique with good mid-term outcomes.

The fact that the bulge generated by Dx/HA causes coaptation of the ureteral orifice and intramural ureter is the fundamental reason for which Dx/HA-IT is performed for VUR.^{11,12} SMHIT has several advantages over double HIT (Figure 1). First, SMHIT generates bulges, which can be directly visually assessed, by sequentially and systematically administering several Dx/HA injections from the proximal to the distal part of the intramural ureter. The coaptation area of the intramural ureter can be extended out further by SMHIT than by double HIT, making it easier for the intramural ureter to appear as a “mountain range.”¹¹ Second, because SMHIT ensures that injections are made in the proximal part of the ureter, it can prevent caudal migration of bulges, which causes injection failure.¹¹ To prevent caudal migration of bulges, IT has been improved for STING, HIT, and double HIT, enabling the generation of bulges at the more proximal part of the intramural ureter.¹¹ Third, the final deep injection in the 6-o’clock position of the ureteral orifice allows the orifice to protrude upward into the bladder lumen, extending the length of the submucosal tunnel of the intramural ureter and increasing the height of the “mountain range”. These mechanisms underly Dx/HA’s preventive effect on VUR.¹³ Conversely, compared to double HIT, because Dx/HA is injected proximally near the ureteral hiatus, SMHIT may be associated with a risk of accidental injection into the extravascular portion of the ureter. Thus, we sufficiently assessed the intramural ureter prior to Dx/HA injection. At this time, a constantly flat area in the 6-o’clock position of the intramural ureter without peristalsis was identified, and we avoided proximal insertion in the area thought to be the extravascular ureter. Furthermore, accidental injection of Dx/HA into the extravascular portion was prevented by reducing the needle insertion depth and confirming the bulges generated by Dx/HA by direct visual inspection.

Our careful and precise procedures may contribute to the mid-term absence of postoperative complications, such as delayed-onset UO^{8,14} and ureteral calcification.¹⁵ We agree with Puri and Kirsch et al who argued that injection failure is caused by technical errors.^{10,16} In addition, it has also been reported that the Dx/HA-IT by off label use, especially in patients with BBD, causes delayed-onset UO.^{8,14} In this study, untreated BBD cases were excluded from surgical indication for SMHIT and this may also have avoided the occurrence of delayed-onset UO after SMHIT. Voiding and filling VUR differ in their pathological manifestations.¹⁷ The spontaneous resolution rate of VUR is higher in voiding VUR.¹⁸ Likewise, the resolution rate of VUR after IT is higher in voiding VUR.^{17,19} In this study, although most children had filling VUR (83%), the success rate after SMHIT was high, which may reflect the high accuracy of SMHIT.

While this study showed that SMHIT was an excellent technique, the selection of appropriate children may have been useful. The exclusion of children with contraindications may have contributed to the high efficacy and safety of SMHIT. IT would not be performed in children with ongoing UTIs, and it would be futile in those with a non-functioning kidney. Treatment outcomes of IT for children with grade V VUR are poor. Based on meta-analyses, short-term postoperative radiographic success rates after a single session of IT are 51–62%.^{9,20} Friedmacher et al recently reported that the radiographic success rate at 3 months postoperatively was 62% in children with grade V VUR.¹⁰ Characteristics of VUR differ between children aged <1 year and ≥1 year.⁶ Friedmacher et al reported that radiographic failure in children with high-grade VUR undergoing a single session of IT occurred significantly more frequently in those aged <1 year.¹⁰ Arlen et al reported that radiographic failure in children with mild-to-moderate VUR occurred more frequently in those aged <2 years.²¹ Additionally, children aged <1 year who have undergone IT are likely to develop postoperative FUTIs,²² and IT for children aged <1 year is a possible risk factor for delayed-onset UO.⁸ Thus, the efficacy and safety of IT in children aged <1 year with VUR are not guaranteed in the Dx/HA package insert.⁷ As the short-term radiographic success rates of IT are 77–81%^{9,23} in VUR children with a Hutch diverticulum and 69%⁹ in VUR children with an ureterocele, the success rate after IT is low in children with anatomical abnormalities.⁹ Active voiding dysfunction or untreated BBD is a limiting factor for IT.^{9,11,20} The radiographic success

rate is low,^{9,24,25} which is attributable to the displacement of the Dx/HA implant due to bladder hypertension associated with uninhibited detrusor contraction.^{24,26} Moreover, the incidence of postoperative FUTIs is high, and the clinical success rate is low.^{21,26} Because the primary cause of FUTI in children with VUR is voiding dysfunction, mainly involving BBD, regardless of the presence or absence of VUR, the detection of voiding dysfunction is important. Additionally, because BBD, which is not detected preoperatively but manifests postoperatively, is a reported risk factor of FUTI after IT,^{10,26} managing BBD is important not only before but also after IT.^{26,27}

The VUR recurrence rate after IT is higher than that after open surgery.⁶ Thus, in this study, VCUg was performed a total of three times in each child until 3 years postoperatively to confirm whether VUR recurred. Our results confirmed the mid-term efficacy of SMHIT. In contrast, the American Academy of Pediatrics²⁸ and the National Institute for Health and Care Excellence²⁹ tend to discourage screening for VCUg, which is performed to closely investigate the causes of FUTI, because VCUg is a highly invasive procedure. In addition, Stenberg and Lackgren et al claimed that postoperative VCUg was the most undesirable option for VUR treatment in 72% of patients undergoing IT.³⁰ Therefore, if the long-term success rate of IT is comparable to that of open surgery, postoperative VCUg may not be needed multiple times. Based on short-term outcomes of SMHIT that the author (S.N.) had evaluated in 8 ureters (grades IV=1, grade III=4, and grade II=3) from 6 patients since 2017, the clinical success rate was 100%, and radiographic success was achieved in 8/8 ureters (100%) (grade I=1, grade 0=7) at 3–4 months postoperatively and in 3/3 ureters (100%) (grade I=2, grade 0=1) 1 year postoperatively (unpublished data). Arlen et al determined that postoperative VCUg is indicated for children at high risk of VUR recurrence (aged <2 years, high grade, recurrent FUTI) and by surgeons/family request.²¹ Hunziker et al determined that repeat VCUg is indicated for children who develop FUTI twice or more postoperatively or those in whom pyelocaliectasis is detected on ultrasound after the first episode of postoperative FUTI.²⁶ We developed SMHIT in consideration of the importance of adequate single-session treatment for children with VUR. It is currently necessary to confirm the resolution of VUR after IT on VCUg. Zambaiti et al reported that the injected Dx/HA stabilized within 6 months,¹³ therefore, we intend to

perform VCUg only once, between 6 months and 1 year postoperatively.

Limitations of the present study include its small sample size and retrospective design. The author (S.N.) has never experienced STING, HIT or double HIT for children with primary VUR, so it is the limitation of this study that the effectiveness and safety of SMHIT could not be evaluated in comparison with them.

Conclusions

When avoiding the use of Dx/HA in children with contraindications and prioritizing the treatment of concomitant BBD, a single session of SMHIT for children with primary VUR may be as effective and safe in the mid-term as performing open anti-reflux surgery.

Disclosure

The authors report no conflicts of interest in this work.

References

1. Kirsch AJ, Arlen AM, Lackgren G. Current trends in dextranomer hyaluronic acid copolymer (Deflux) injection technique for endoscopic treatment of vesicoureteral reflux. *Urology*. 2014;84:462–468.
2. Läckgren G, Wählin N, Sköldenberg E, et al. Long-term followup of children treated with dextranomer/hyaluronic acid copolymer for vesicoureteral reflux. *J Urol*. 2001;166(5):1887–1892. doi:10.1016/S0022-5347(05)65713-8
3. Lee EK, Gatti JM, Demarco RT, et al. Long-term followup of dextranomer/hyaluronic acid injection for vesicoureteral reflux: late failure warrants continued followup. *J Urol*. 2009;181(4):1869–1875. doi:10.1016/j.juro.2008.12.005
4. Holmdahl G, Brandström P, Läckgren G, et al. The Swedish reflux trial in children: II. Vesicoureteral reflux outcome. *J Urol*. 2010;184(1):280–285. doi:10.1016/j.juro.2010.01.059
5. Stredle RJ, Dietz HG, Stehr M. Long-term results of endoscopic treatment of vesicoureteral reflux in children: comparison of different bulking agents. *J Pediatr Urol*. 2013;9(1):71–76. doi:10.1016/j.jpuro.2011.12.004
6. Peters CA, Skoog SJ, Arant BS, et al. Summary of the AUA guideline on management of primary vesicoureteral reflux in children. *J Urol*. 2010;184(3):1134–1144. doi:10.1016/j.juro.2010.05.065
7. Salix Pharmaceuticals, Inc. Deflux; 2015. Available from: <http://www.salix.com/products/deflux>.
8. Papagiannopoulos D, Rosoklija I, Cheng E, et al. Delayed Obstruction with asymptomatic loss of renal function after dextranomer/hyaluronic acid copolymer (deflux) injection for vesicoureteral reflux: a close look at a disturbing outcome. *Urology*. 2017;101:63–66. doi:10.1016/j.urology.2016.09.013
9. Routh JC, Inman BA, Reinberg Y. Dextranomer/hyaluronic acid for pediatric vesicoureteral reflux: systematic review. *Pediatrics*. 2010;125(5):1010–1019. doi:10.1542/peds.2009-2225
10. Friedmacher F, Colhoun E, Puri P. Endoscopic injection of dextranomer/hyaluronic acid as first line treatment in 851 consecutive children with high grade vesicoureteral reflux: efficacy and long-term results. *J Urol*. 2018;200(3):650–655. doi:10.1016/j.juro.2018.03.074
11. Moliterno JA, Scherz HC, Kirsch AJ. Endoscopic treatment of vesicoureteral reflux using dextranomer hyaluronic acid copolymer. *J Pediatr Urol*. 2008;4(3):221–228. doi:10.1016/j.jpuro.2007.11.015

12. Kalisvaart JF, Scherz HC, Cuda S, et al. Intermediate to long-term follow-up indicates low risk of recurrence after double HIT endoscopic treatment for primary vesico-ureteral reflux. *J Pediatr Urol.* 2012;8(4):359–365. doi:10.1016/j.jpuro.2011.07.006
13. Zambaiti E, Sergio M, Di Pace MR, et al. The fate of implant after endoscopic injection of dextranomer/hyaluronic acid in vesicoureteral reflux: time to partial reabsorption and stabilization. *J Pediatr Urol.* 2020;16(2):191.e1–6. doi:10.1016/j.jpuro.2019.12.010
14. Friedmacher F, Puri P. Ureteral obstruction after endoscopic treatment of vesicoureteral reflux: does the type of injected bulking agent matter? *Curr Urol Rep.* 2019;20(9):49. doi:10.1007/s11934-019-0913-5
15. Yankovic F, Swartz R, Cuckow P, et al. Incidence of deflux[®] calcification masquerading as distal ureteric calculi on ultrasound. *J Pediatr Urol.* 2013;9:820–824.
16. Kirsch AJ, Perez-Brayfield MR, Scherz HC. Minimally invasive treatment of vesicoureteral reflux with endoscopic injection of dextranomer/hyaluronic acid copolymer: the Children's Hospitals of Atlanta experience. *J Urol.* 2003;170(1):211–215. doi:10.1097/01.ju.0000072523.43060.a0
17. Han DS, Cambareri G, Alagiri M, et al. Reflux timing is a predictor of successful endoscopic treatment of vesicoureteral reflux. *Urology.* 2019;124:237–240. doi:10.1016/j.urology.2018.09.034
18. Arsanjani A, Alagiri M. Identification of filling versus voiding reflux as predictor of clinical outcome. *Urology.* 2007;70(2):351–354. doi:10.1016/j.urology.2007.03.031
19. Lee JN, Lee SM, Ha YS, et al. VUR timing on VCUG as a predictive factor of VUR resolution after endoscopic therapy. *J Pediatr Urol.* 2016;12(4):255.e1–6. doi:10.1016/j.jpuro.2016.04.002
20. Elder JS, Diaz M, Caldamone AA, et al. Endoscopic therapy for vesicoureteral reflux: a meta-analysis. I. reflux resolution and urinary tract infection. *J Urol.* 2006;175:716–722.
21. Arlen AM, Scherz HC, Filimon E, et al. Is routine voiding cystourethrogram necessary following double hit for primary vesicoureteral reflux? *J Pediatr Urol.* 2015;11(1):40.e1–5. doi:10.1016/j.jpuro.2014.11.011
22. Kim H, Kim BS, Cheong HI, Cho BS, Kim KM. Long-term results of endoscopic deflux[®] injection for vesicoureteral reflux in children. *Child Kidney Dis.* 2015;19(1):31. doi:10.3339/chikd.2015.19.1.31
23. Cerwinka WH, Scherz HC, Kirsch AJ. Endoscopic treatment of vesicoureteral reflux associated with paraureteral diverticula in children. *J Urol.* 2007;178(4):1469–1473. doi:10.1016/j.juro.2007.05.168
24. Capozza N, Lais A, Matarazzo E, et al. Influence of voiding dysfunction on the outcome of endoscopic treatment for vesicoureteral reflux. *J Urol.* 2002;168(4 Part 2):1695–1698. doi:10.1016/S0022-5347(05)64391-1
25. Capozza N, Lais A, Nappo S, et al. The role of endoscopic treatment of vesicoureteral reflux: a 17-year experience. *J Urol.* 2004;172(4 Part 2):1626–1629. doi:10.1097/01.ju.0000138381.75175.b9
26. Hunziker M, Mohanan N, D'Asta F, et al. Incidence of febrile urinary tract infections in children after successful endoscopic treatment of vesicoureteral reflux: a long-term follow-up. *J Pediatr.* 2012;160(6):1015–1020. doi:10.1016/j.jpeds.2011.12.033
27. Lightfoot M, Bilgutay AN, Tollin N, et al. Long-term clinical outcomes and parental satisfaction after dextranomer/hyaluronic acid (Dx/HA) injection for primary vesicoureteral reflux. *Front Pediatr.* 2019;7:392.
28. Roberts KB. Subcommittee on urinary tract infection SeCoQIaM. Urinary tract infection: clinical practice guideline for the diagnosis and management of the initial UTI in febrile infants and children 2 to 24 months. *Pediatrics.* 2011;128:595–610.
29. National Institute for Health and Care Excellence. Urinary tract infection in children: diagnosis, treatment and longterm management. NICE guidelines [CG54]. NICE; 2007. Available from: <http://www.nice.org.uk/guidance/cg54>.
30. Stenberg A, Läckgren G. Treatment of vesicoureteral reflux in children using stabilized non-animal hyaluronic acid/dextranomer gel (NASHA/DX): a long-term observational study. *J Pediatr Urol.* 2007;3(2):80–85. doi:10.1016/j.jpuro.2006.08.001

Research and Reports in Urology

Publish your work in this journal

Research and Reports in Urology is an international, peer-reviewed, open access journal publishing original research, reports, editorials, reviews and commentaries on all aspects of adult and pediatric urology in the clinic and laboratory including the following topics: Pathology, pathophysiology of urological disease; Investigation and

treatment of urological disease; Pharmacology of drugs used for the treatment of urological disease. The manuscript management system is completely online and includes a very quick and fair peer-review system, which is all easy to use. Visit <http://www.dovepress.com/testimonials.php> to read real quotes from published authors.

Submit your manuscript here: <https://www.dovepress.com/research-and-reports-in-urology-journal>

Dovepress