

Emotion processing in Parkinson's disease: a blood oxygenation level-dependent functional magnetic resonance imaging study

Mohammed Benzagmout^{1,2,6}, Saïd Boujraf^{1,3,4,*}, Badreeddine Alami^{1,3,4}, Hassane Ali Amadou^{1,2}, Halima El Hamdaoui^{1,3}, Amine Bennani¹, Mounir Jaafari^{1,5}, Ismail Rammouz^{1,5}, Mustapha Maaroufi^{1,4}, Rabia Magoul⁶, Driss Boussaoud^{1,7}

1 Laboratory of Clinical Neuroscience, Faculty of Medicine, Fez, Morocco

2 Department of Neurosurgery, University Hospital of Fez, Fez, Morocco

3 Department of Biophysics and Clinical MRI Methods, Faculty of Medicine, Fez, Morocco

4 Department of Radiology and Clinical Imaging, University Hospital of Fez, Fez, Morocco

5 Department of Psychiatry, University Hospital of Fez, Fez, Morocco

6 Laboratory of Neuroendocrinology and Nutritional and Climatic Environment, Faculty of Sciences Dhar El Mahraz, Fez, Morocco

7 Aix Marseille Université, INSERM, INS, Institut de Neurosciences des Systèmes, Marseille, France

Abstract

Parkinson's disease is a neurodegenerative disorder caused by loss of dopamine neurons in the substantia nigra pars compacta. Tremor, rigidity, and bradykinesia are the major symptoms of the disease. These motor impairments are often accompanied by affective and emotional dysfunctions which have been largely studied over the last decade. The aim of this study was to investigate emotional processing organization in the brain of patients with Parkinson's disease and to explore whether there are differences between recognition of different types of emotions in Parkinson's disease. We examined 18 patients with Parkinson's disease (8 men, 10 women) with no history of neurological or psychiatric comorbidities. All these patients underwent identical brain blood oxygenation level-dependent functional magnetic resonance imaging for emotion evaluation. Blood oxygenation level-dependent functional magnetic resonance imaging results revealed that the occipito-temporal cortices, insula, orbitofrontal cortex, basal ganglia, and parietal cortex which are involved in emotion processing, were activated during the functional control. Additionally, positive emotions activate larger volumes of the same anatomical entities than neutral and negative emotions. Results also revealed that Parkinson's disease associated with emotional disorders are increasingly recognized as disabling as classic motor symptoms. These findings help clinical physicians to recognize the emotional dysfunction of patients with Parkinson's disease.

Key Words: Parkinson's disease; emotion; processing; Blood oxygenation level-dependent functional magnetic resonance imaging; brain; activation; dopamine; neural regeneration

Chinese Library Classification No. R445; R741

Introduction

Parkinson's disease (PD) is a neurodegenerative disease caused by progressive degeneration of nigrostriatal dopaminergic pathways. The major symptoms consist of motor problems including tremor, rigidity, and bradykinesia. However, affective and emotional impairments have been also reported (Peron et al., 2012). Thus, numerous studies have been conducted to elucidate PD-related impairment in affective processing (Gray and Tickle-Degnen, 2010). Surprisingly, these studies produced very different results (Gray and Tickle-Degnen, 2010). Some research groups described global emotion impairment while others reported problems in specific emotion processing. In contrast, some authors did not report any deficit (Ricciardi et al., 2017). The differences may result from confounding factors, including the stage of the disease, medication status, and comorbidities. However, it is well known that patients with PD suffer from reduced facial expressivity (hypomimia) and have difficulties in interpreting the emotional facial expressions of others, especially for non-positive emotions (Arriatti et al., 2008).

Most studies regarding emotion in PD were based on behavioral, cognitive and physiological measurements of

emotion recognition (Adolphs et al., 1998; Pell and Leonard, 2005; Bowers et al., 2006; Suzuki et al., 2006; Wieser et al., 2006; Laweence et al., 2007; Clark et al., 2008; Dara et al., 2008; Lotze et al., 2009; Miller et al., 2009; Schienle et al., 2015). However, all of these studies have addressed only one aspect of emotions (Schuenle et al., 2015; Ricciardi et al., 2017). To date, few studies have investigated emotional issues in PD using fMRI (Lotze et al., 2009). To the best of our knowledge, this is the first fMRI study exploring all aspects of emotions (positive, negative, and neutral) in a homogeneous population of patients with PD. The goal of this study was to investigate emotion organization in the brain of patients with PD and to explore whether there are differences between recognition of different types of emotions.

Subjects and Methods

Patient selection

This study was conducted according to the national ethical guidelines and regulations, which are mostly compliant with the National Institute of Health standards. The approval of the local ethical committee 'Comité d'Etique Hospitalo-universitaire de Fez, Fez; Morocco' was obtained (Reference:

***Correspondence to:**

Saïd Boujraf, Med Sc., PhD,
sboujraf@gmail.com.

orcid:

0000-0001-8298-6464
(Saïd Boujraf)

doi: 10.4103/1673-5374.247470

Received: September 8, 2018

Accepted: November 2, 2018

ECR 09/2018).

Eighteen patients with idiopathic PD including 16 patients having bilateral lesions and two patients having right-sided lesions were recruited for the study. The studied patients had no neurological or psychiatric comorbidities. The diagnosis of PD was established by a certified neurologist with advanced training in movement disorders. The diagnostic criteria were based on clinical symptoms including bradykinesia/hypokinesia and atypical movement disorders such as mix, myoclonic, task dependant, postural inaugural tremor, dopamine resistant tremor, isolated tremor at rest. Non motor symptoms are also considered. None of the patients had received deep brain stimulation before.

All patients underwent clinical assessment of motor disorders using the Unified Parkinson's Disease Rating Scale (UPDRS) section V (Goetz et al., 2010). Neurological examination was performed the day before scanning. All patients were also assessed by a psychiatrist using the Beck Depression Inventory-II (BDI-II) (scale) (Beck et al., 1996) to rule out a depressive propensity which might interfere with affective processing. All participants had normal vision.

All included patients were under L-dopa treatment. In addition, some of them simultaneously received other parkinsonian drugs trihexyphenidyl hydrochloride ($n = 4$), piribedil ($n = 3$), or a mixture of these drugs ($n = 2$). Medication was not discontinued prior to the fMRI session and all patients were investigated on the ON state of their dopaminergic medication cycle.

Both written and verbal informed consents were obtained from each patient. The demographic and clinical parameters of included patients are summarized in **Table 1**.

Table 1 Demographic and clinical characteristics of our PD patients

Case	Age (year)	Sex	Family history of PD	Symptom duration (year)	Hoehn and Yahr stage	Treatment
1	65	M	Yes	11	III	L-dopa + THC
2	63	F	No	2	II	L-dopa
3	60	F	Yes	6	III	L-dopa + THC
4	60	F	No	7	III	L-dopa + THC + Piribedil
5	54	F	No	1	I	L-dopa
6	83	M	No	4	II	L-dopa + THC
7	49	M	No	2	II	L-dopa + THC
8	69	F	No	1	II	L-dopa
9	56	M	No	12	III	L-dopa + Piribedil
10	65	M	No	3	II	L-dopa
11	79	F	No	3	III	L-dopa
12	63	M	Yes	4	III	L-dopa
13	62	F	No	6	III	L-dopa + Piribedil
14	50	M	No	8	III	L-dopa + Piribedil
15	45	M	Yes	4	I	L-dopa
16	66	F	No	10	III	L-dopa + THC + Piribedil
17	56	F	No	2	II	L-dopa
18	57	F	No	8	III	L-dopa

PD: Parkinson's disease; F: female; M: male; L-dopa: levodopa; THC: trihexyphenidyle chlorhydrate.

Emotion paradigm design

Emotion stimuli were based on the international affective picture system that was developed by the Center for the Study of Emotion and Attention, University of Florida, Gainesville, FL, USA (<https://csea.phhp.ufl.edu/media/requestform.html>). In addition, the used pictures consisted of cultural experience adapted and validated pictures in the Moroccan context.

Twenty-seven pictures were used in our experiment. The images were presented to the participants with formal instruction to simply experience the presented emotion.

We used a block design, each block comprising three different types of pictures, positive (e.g., joyful baby, happy family), negative (e.g., attacks by animals, craniofacial trauma) or neutral emotions (e.g., nature scenes) (**Figure 1**). Each picture was displayed for 6 seconds followed by the second and third pictures for the same duration and emotion. The single display of picture for 6 seconds was justified by avoiding habituation that starts at the ninth second of display. Thus each emotion stimulus lasted for 18 seconds (ON condition). Then rest phase (OFF condition) started when pictures vanished and lasted 18 seconds (**Figure 2**). Each block of stimulus was displayed in a pseudo-randomized order for all the included patients with PD.

The experiment was designed to last the shortest time possible to avoid potential motion artifacts during fMRI scanning sessions. In this study, the whole experiment lasted 342 seconds.

Blood oxygenation level-dependent functional magnetic resonance imaging (BOLD-fMRI) acquisition protocol

The BOLD-fMRI protocol used was identical for all patients. All image data acquisitions were achieved in MRI Unit, Radiology and Clinical Imaging Department of the University Hospital of Fez, Morocco.

A 1.5-Tesla MRI system (Sigma, General Electric; Milwaukee, WI, USA) was used to acquire all brain BOLD-fMRI and also anatomical MRI data series.

Image acquisition was achieved using single-shot gradient-echo echo-planar imaging sequence. This MRI approach was shown to be very sensitive to T2* effect originated by increased BOLD phenomena. This reflects the level of functional activity within the cortical brain tissue (Boujraf et al., 2006, 2009, 2017; Bucher et al., 2006; Halder et al., 2007; Belaïch et al., 2015, 2016, 2017).

BOLD-fMRI acquisition parameters were set according to the following configurations: repetition time = 3000 ms, echo time = 55 ms, slice thickness = 5 mm, field of view = 240 mm. All acquired slices were set in the axial orientation.

The acquisition of a single volume of brain was achieved within 3 seconds. The full BOLD-fMRI acquisition protocol allows acquiring 114 brain volumes within 342 seconds. The anatomical MRI data were also acquired.

Data post-processing and image generation

The BOLD-fMRI image data were processed using the Statistical Parametric Mapping package version 12 (SPM12, 2012; <http://www.fil.ion.ucl.ac.uk/spm>; Wellcome Depart-

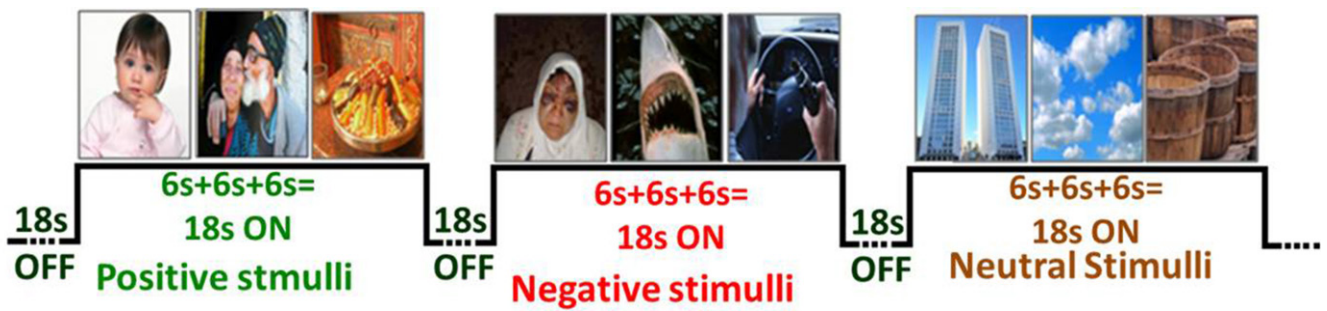

Figure 1 Blood oxygenation level-dependent functional magnetic resonance imaging paradigm components showing the main emotional tasks (positive, negative, and neutral).

Each emotional task was repeated three times with unique images, e.g. each picture was displayed once.

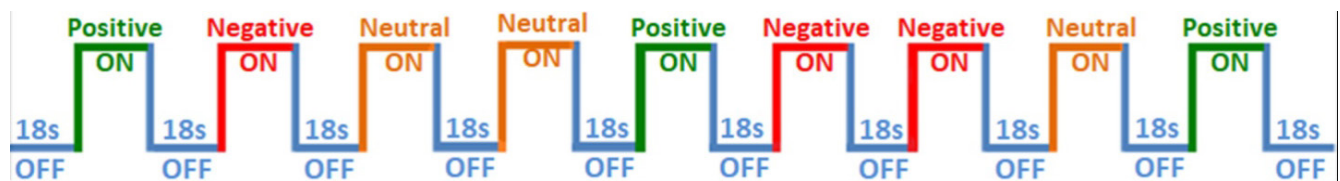

Figure 2 Block design paradigm showing the arrangement of the emotional tasks (positive, negative, and neutral).

Each emotional task was repeated three times with unique images, e.g. each picture was displayed once.

ment of Cognitive Neurology, London, UK). The statistical model used by SPM12 was general linear model approach. All brain MRI image volumes acquired were used in the post-processing steps.

The post-processing steps with SPM12 included realignment, co-registration, and spatial normalization in the Montreal Neurological Institute template (Boujraf et al., 2006, 2009, 2017; Bucher et al., 2006; Halder et al., 2007; Belaïch et al., 2015, 2016, 2017).

Indeed, the gradient-echo EPI image data underwent realignment using a rigid-body transformation to the first volume of the time series for each patient. Subsequently, the image data were spatially smoothed using a Gaussian filter Full width at half maximum (FWHM $8 \times 8 \times 8$ mm) and then spatially normalized (Boujraf et al., 2006, 2009, 2017; Bucher et al., 2006; Halder et al., 2007; Belaïch et al., 2015, 2016, 2017).

All cerebral activations were rendered onto brain slices of T1-weighted MRI image or on the surface of the standard brain of Montreal Neurological Institute, Montreal, Quebec, Canada. The task was designed according to the box-car pattern and convolved with the functional hemodynamic response recorded in the brain. The brain areas that were significantly activated were decided. Each voxel element was statistically processed using SPM12 (Boujraf et al., 2006, 2009, 2017; Bucher et al., 2006; Halder et al., 2007; Belaïch et al., 2015, 2016, 2017). A *P*-value less than 0.01 was considered statistically significant. The calculated BOLD activation maps were overlaid on anatomical images.

Quantitative evaluation of individual activation maps

Each calculated activation map of individual patients was evaluated and scored to reflect the activation level originated by each emotion (namely positive, negative, and neutral).

Statistical analysis

One-way analysis of variance was used for comparison of quantitative data between paired emotion categories (namely positive versus negative, positive versus neutral, and negative versus neutral). A value of *P* < 0.05 was considered to be statistically significant.

Results

Clinical assessment results

This study included 18 patients, consisting of 10 women and 8 men, with a mean age of 61 (45–86) years. All patients were right-handed. They had been in school for at least 5 years and three of them had a high level of education. Three patients had a history of arterial hypertension, two patients underwent operation for prostatic adenoma, and four had a history of familial PD. The mean duration of the disease was 5.4 years (range 11 months–12 years). The staging of PD for these patients was based on the Hoehn and Yahr scale. Two of our patients were classified as stage I, six of them as stage II, and ten as stage III (Hoehn and Yahr, 1967). **Table 1** summarizes the demographic and clinical profile of the included patients with PD.

fMRI assessment results

Different brain structures (in particular the occipito-temporal cortices, insula, orbitofrontal cortex, basal ganglia, and parietal cortex) involved in the organization of emotions were activated during the functional control. In addition, the activation level depended on the emotion type of stimuli. Thus, positive emotion was shown to activate larger volumes of the anatomical entities involved in the emotional processing in all patients. However, the importance of activation decreased significantly in the negative emotion compared with the positive emotion (**Figure 3**).

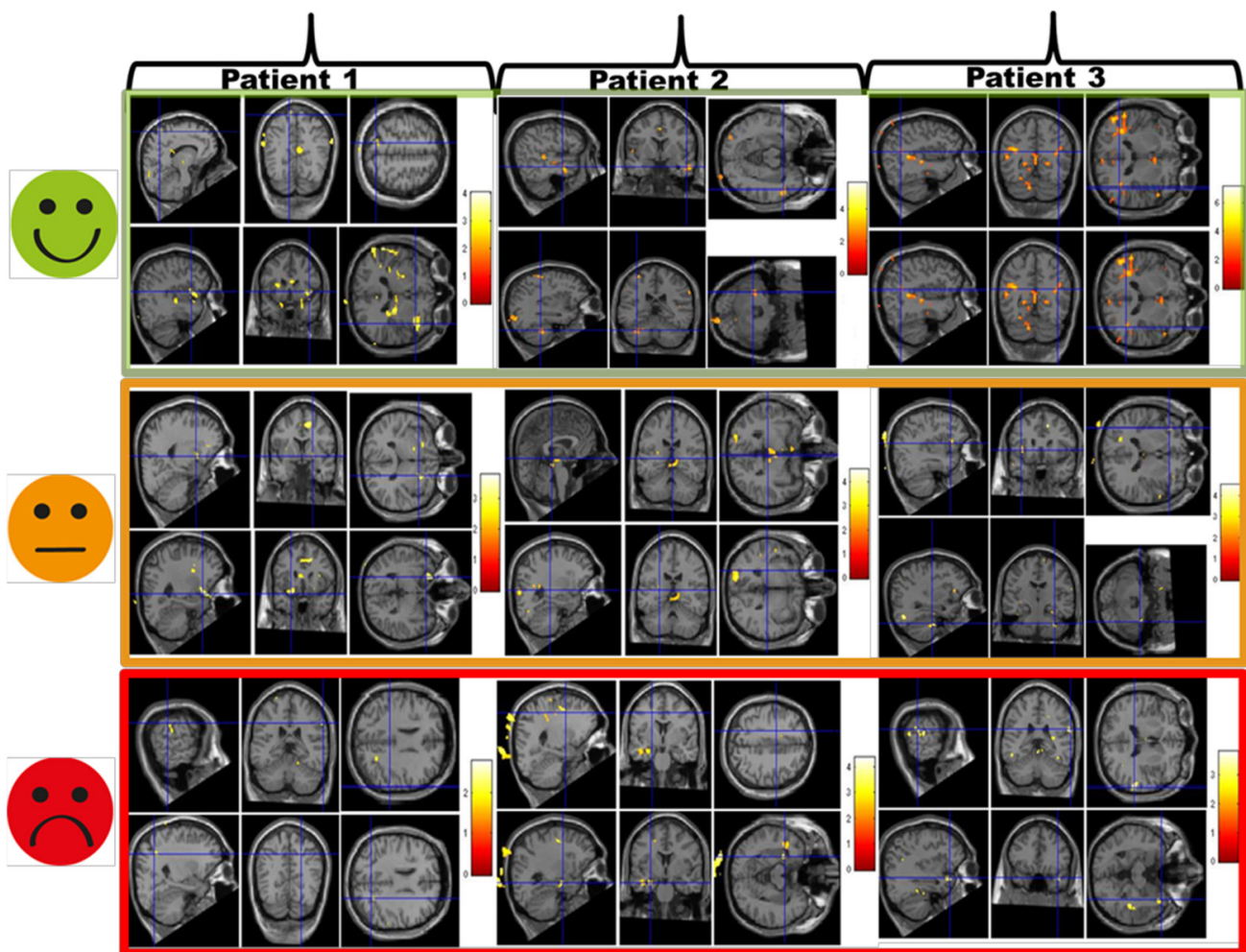


Figure 3 Blood oxygenation level-dependent activations in three Parkinson's disease patients showing that positive emotion activates larger volumes of the brain networks involved in emotional processing, compared to neutral and negative emotions. Green, orange and red faces to the left indicate activations in response to positive emotions (brain slices inside the green frame), neutral stimuli (orange frame) and negative emotions (red frame) respectively. A color scale is inserted next to each set of images to indicate the intensity of activations (black, no activation; yellow, highest activation).

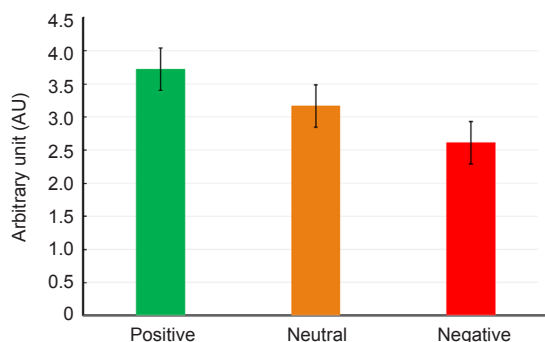


Figure 4 Whole brain blood oxygenation level-dependent activation elicited by positive, negative, and neutral emotions in the group of patients studied. The bars represent activation scores, and the error bars represent the standard error.

The global activation induced by the positive, negative, and neutral emotions was quantitatively evaluated (Figure 4). In PD patients, positive emotion had the largest activation area and negative emotion had the smallest activation area (Figure 4).

Statistical analysis

Global brain activation level in each motion category (positive, negative, and neutral) was statistically analyzed using analysis of variance. Positive and negative emotions produced significantly different effects on global brain activation level. Quantitative statistical analysis results demonstrated significant difference in the brain activation level associated with positive versus negative emotions ($P < 0.05$). However, there was no significant difference in the brain activation level between negative and neutral emotions ($P > 0.05$).

Discussion

PD is a neurodegenerative disorder characterized by depletion of dopaminergic neurons in specific brain anatomic entity called substantia nigra. This degenerative process of the nigrostriatal dopaminergic pathway instigates the impairment of the basal ganglia-thalamo-cortical circuit functions, including the motor and prefrontal cortex functions (Alexander et al., 1990). Besides motor symptoms, PD patients exhibit cognitive dysfunction (Jankovic, 2008; Hsu

et al., 2012) and a deficit in emotional processing (Assogna et al., 2008; Gray and Tickle-Degnen, 2010).

The basal ganglia are crucial structures for emotion recognition. Stroke (Fromm et al., 1985; Pogarell and Oertel, 1999) or other neurodegenerative diseases, such as Huntington's disease (Robotham et al., 2011) damage the basal ganglia, leading to marked deficits in emotion recognition. Mauss and Robinson (2009) reported that the state of emotion in PD involves a series of brain circuits rather than specific isolated brain regions. Moreover, the cortical and sub-cortical brain structures are involved together in emotional processing through cortical-thalamic-striatal cognitive loops (Owen et al., 1998). The limbic system represents the most important basal ganglia-thalamo-cortical circuits, which has a crucial role in emotional and motivational processes (Butters et al., 1973; Afifi, 2003). BOLD-fMRI studies have revealed an increased activation of orbitofrontal cortex and anterior cingulate cortex when volunteers are experiencing to recognize emotions using facial expressions (Dolan et al., 1996; Blair et al., 1999). Besides, impairment of emotional identification has been demonstrated in patients with orbitofrontal cortex and/or anterior cingulate cortex lesions using facial expressions (Hornak et al., 2003).

Several assessment methods such as BOLD-fMRI, positron emission tomography, PET scan, and electroencephalography were used to analyze interconnected neuronal activities in various brain regions to detect the activation yielded by emotional processing in the brain. Baumgartner et al. (2006) reported that electroencephalography activity in the left hemisphere was increased under happy conditions compared to negative emotional conditions. Hinrichs and Machleidt (1992) demonstrated a changed degree of coherence in the alpha frequency band on electroencephalography, principally with a larger coherence in happiness compared to sadness.

A recent meta-analysis regarding fMRI of emotional processing has suggested that basic emotions are implemented by different neural circuits, and each type of emotion activates preferentially a specific brain region (Fusar-Poli et al., 2009). Happy and fearful faces activate bilateral amygdala, sad faces activate the right amygdala only, and disgusting faces seem to activate essentially the anterior insula (Phan et al., 2002).

Numerous studies have found emotion recognition deficits in patients with PD (Jacobs et al., 1995; Benke et al., 1998; Breitenstein et al., 1998; St. Clair et al., 1998). Breitenstein et al. (1998) reported that compared to healthy controls, patients with PD performed poorer in commenting the emotional content of speech or sketches (Scott et al., 1984) and in recognizing emotional displays, in particular in prosodic recognition tasks involving anger and fear. PD patients showed reduced recognition of sadness, anger, and disgust facial expressions (St. Clair et al., 1998; Baggio et al., 2012).

With regard to recognition of emotional facial expression, a recent meta-analysis evaluating behavioral studies found that individuals with PD exhibited more severe impairment than healthy individuals in the recognition of negative emotions (anger, disgust, fear, and sadness) and individuals with PD exhibited more severe impairment in the recognition of neg-

ative emotions than in the recognition of positive emotions (happiness, surprise) (Gray and Tickle-Degnen, 2010). This problem is likely related to disturbances in the limbic loop, and in particular in the connections of the basal ganglia to the orbitofrontal cortex and anterior cingulate cortex.

Interestingly, a relationship was demonstrated between the expression of facial emotions by both PD patients and healthy volunteers and the ability to recognize facial emotions expressed by others (Ariatti et al., 2008). The capability of recognizing the emotions expressed by others is based on the processes that internally stimulate the identical emotional state in each individual (Scott et al., 1984; Heberlein and Atkinson., 2009; Baggio et al., 2012). This is called the simulation or goal directed model of emotion recognition which depends on the mirror neurons located in F5 brain area within the pars opercularis of the inferior frontal gyrus (Rizzolatti and Arbib, 1998).

In our study, we demonstrated that brain activation is weaker in negative emotion. Wieser et al. (2006) found that PD patients rated negative pictures as less arousing than did healthy controls, but they had no such problem in accurately rating positive and neutral pictures. Alonso-Recio et al. (2014) found also that patients with higher disease severity performed worse than healthy controls in the recognition of emotional facial expressions, however, such result was not found in patients with lower disease severity.

PD patients' deficits in the recognition of negative emotions may be related to faulty communication between the amygdala and prefrontal cortex due to low levels of dopamine (Lin et al., 2016). As supported by the present study, in PD patients, there is a reduction in the brain complexity during emotional processing initiated by a decrease of neural connectivity and the existence of functional disconnections between cortical areas (Adolphs et al., 1996; Lawrence et al., 2006; Kober et al., 2008; Cronin-Golomb, 2010; Lin et al., 2016).

In addition, dopamine levels have been shown to be correlated with patients' performance when recognizing facial emotions (Sprengelmeyer et al., 2003; Lawrence et al., 2007). Motor performances and cognitive functions worsen over time in PD patients because of dopaminergic neurodegeneration.

Our study showed that positive emotion activates large volumes of the anatomical entities involved in the emotional processing in PD patients. However, the negative emotions activate the least area of brain regions in the same PD patients. As the disease progresses, the recognition of negative emotions is impaired and then followed impairment to the recognition of positive emotions (Lawrence et al., 2007). These facts are supported by physiological data. It is well known that prefrontal dopamine influences cognitive functions (Arnsten et al., 2005; Cools and D'Esposito, 2011). Interestingly, dopamine uptake has been reported to be increased in prefrontal regions (Rakshi et al., 1999; Kaasiminen et al., 2000; Cools et al., 2002) in early PD. However, later in the disease, PET scanning revealed marked decrease in prefrontal dopamine and in D2-type dopamine receptors (Kaasinen et al., 2000; Rakshi et al., 2001; Yip et al., 2003). Based on this, we could speculate that preservation of rec-

ognition of positive emotion in our PD patients is related to the presence of dopamine reserve in the prefrontal cortex. However, the heterogeneity and the small sample of our population might be a limitation that should be considered. Future clinical and *in vivo* molecular imaging studies (e.g., PET/SPECT) of patients with early PD may resolve this question.

Finally, Yip et al. (2003) found that compared to unilateral PD patients, bilateral PD patients showed greater deficits in the emotion recognition task regardless of the stimulus modality.

Conclusion

Emotion is an essential tool for social communication between individuals. Because of dopaminergic degeneration, emotion is affected in PD similar to motor function. Thus, clinicians should be aware of this fact to identify the emotional impairment in PD patients and to direct specific treatment for the patients, such as computerized cognitive rehabilitation (Yuvaraj et al., 2016).

Our study demonstrated a specific impairment of negative emotional processing in PD patients. This result could be explained by our demographic data since all patients were relatively in the early stage of the disease. Nevertheless, we believe that prospective studies using clinical/fMRI emotional tests and involving larger number of PD patients would be the best way to confirm this hypothesis.

Author contributions: Study design: MB, SB; patient recruitment: MB, HAA, AB; follow-up evaluation: MB, HAA, AB, MJ, IR; fMRI data acquisition: MB, SB, BA, HEH; image post-processing: HEH, BA; result interpretation: SB, BA, DB; psychiatric evaluation: MJ, IR, AB, DB; imaging examination: MM; statistical analysis: SB; paper writing: MB, DB; paper review: SB, IR; PhD supervisor: RM. All authors approved the final version of this paper.

Conflicts of interest: None declared.

Financial support: None.

Institutional review board statement: This study was performed in accordance with the Declaration of Helsinki. This prospective study was conducted according to the national ethical guidelines and regulations, which are mostly compliant with the National Institute of Health standards. The approval of the local ethical committee 'Comité d'Etique Hospitalo-universitaire de Fez, Fez, Morocco' was requested (Reference: ECR 09/2018).

Declaration of patient consent: The authors certify that they have obtained all appropriate patient consent forms. In the form, the patients or guardians have given their consent for the patients' images and other clinical information to be reported in the journal. The patients or guardians understand that the patients' names and initials will not be published and due efforts will be made to conceal their identity.

Reporting statement: This study followed the STrengthening the Reporting of OBservational studies in Epidemiology (STROBE) statement.

Biostatistics statement: The statistical analysis was achieved by certified statistician, one of authors (SB) from the Faculty of Medicine of Fez/University and Hospital of Fez, Fez, Morocco.

Copyright license agreement: The Copyright License Agreement has been signed by all authors before publication.

Data sharing statement: For data sharing, individual participant data will be available when needed. The study protocol and informed consent form will be made available immediately upon request following article publication to investigators whose proposed use of the data has been approved by an independent review committee identified to achieve aims in the approved proposal. In order to gain access, data requestors will need to sign a data access agreement. Proposals should be directed to the corresponding author via sboujraf@gmail.com.

Plagiarism check: Checked twice by iThenticate.

Peer review: Externally peer reviewed.

Open access statement: This is an open access journal, and articles are

distributed under the terms of the Creative Commons Attribution-Non-Commercial-ShareAlike 4.0 License, which allows others to remix, tweak, and build upon the work non-commercially, as long as appropriate credit is given and the new creations are licensed under the identical terms.

Open peer reviewer: Hailong Song, University of Missouri Columbia, Pathology and Anatomical Sciences, One Hospital Drive, USA.

Additional file:

Additional file 1: Open peer review report 1.

References

- Adolphs R, Damasio H, Tranel D, Damasio AR (1996) Cortical systems for the recognition of emotion in facial expressions. *J Neurosci* 16:7678-7687.
- Adolphs R, Schul R, Tranel D (1998) Intact recognition of facial emotion in Parkinson's disease. *Neuropsychology* 12:253-258.
- Affi AK (2003) The basal ganglia: a neural network with more than motor function. *Semin Pediatr Neurol* 10:3-10.
- Alexander GE, Crutcher MD (1990) Functional architecture of basal ganglia circuits: neural substrates of parallel processing. *Trends Neurosci* 13:266-271.
- Alonso-Recio L, Martín-Plasencia P, Loeches-Alonso A, Serrano-Rodríguez JM (2014) Working memory and facial expression recognition in patients with Parkinson's disease. *J Int Neuropsychol Soc* 20:496-505.
- Ariatti A, Benuzzi F, Nichelli P (2008). Recognition of emotions from visual and prosodic cues in Parkinson's disease. *Neurol Sci* 29:219-227.
- Arnsten AFT, Li B-M (2005) Neurobiology of executive functions: catecholamine influences on prefrontal cortical functions. *Biol Psychiatry* 57:1377-1384.
- Assogna F, Pontieri FE, Caltagirone C, and Spalletta G (2008) The recognition of facial emotion expressions in Parkinson's disease. *Eur Neuropsychopharmacol* 18:835-848.
- Baggio HC, Segura B, Ibarretxe-Bilbao N, Valdeoriola F, Martí MJ, Compta Y, Tolosa E, Junqué C (2012) Structural correlates of facial emotion recognition deficits in Parkinson's disease patients. *Neuropsychologia* 50:2121-2128.
- Baumgartner T, Esslen M, Jancke L (2006) From emotion perception to emotion experience: emotions evoked by pictures and classical music. *Int J Psychophysiol* 60:34-43.
- Beck AT, Steer RA, Brown GK (1996) Manual for the Beck Depression Inventory-II. San Antonio, TX: Psychological Corporation.
- Belaïch R, Boujraf S, Benzagmout M, Maaroufi M, Housni A, Batta F, Tizniti S, Magoul R, Sqalli T (2016) Indices of adrenal deficiency involved in brain plasticity and functional control reorganization in hemodialysis patients with polysulfone membrane: BOLD-fMRI study. *J Integr Neurosci* 15:191-203.
- Belaïch R, Boujraf S, Housni A, Maaroufi M, Batta F, Magoul R, Sqalli T, Er-rasfa M, Tizniti S (2015) Assessment of hemodialysis impact by Polysulfone membrane on brain plasticity using BOLD-fMRI. *Neuroscience* 288:94-104.
- Belaïch R, Boujraf S, Benzagmout M, Magoul R, Maaroufi M, Tizniti S (2017) Implications of oxidative stress in the brain plasticity originated by fasting: a BOLD-fMRI study. *Nutr Neurosci* 20:505-512.
- Benke T, Bosch S, Andree B (1998) A study of emotional processing in Parkinson's disease. *Brain Cogn* 38:36-52.
- Blair RJ, Morris JS, Frith CD, Perrett DI, Dolan RJ (1999) Dissociable neural responses to facial expressions of sadness and anger. *Brain* 122:883-893.
- Boujraf S, Belaïch R, Housni A, Maaroufi M, Tizniti S, Sqalli T, Benzagmout M (2017) Blood oxygenation level-dependent functional MRI of early evidences of brain plasticity after hemodialysis session by helixone membrane of patients with indices of adrenal deficiency. *Ann Neurosci* 24:82-89.
- Boujraf S, Summers P, Belahsen F, Prüssmann K, Kollias S (2009) Ultrafast bold fMRI using single-shot spin-echo echo planar imaging. *J Med Phys* 34:37-42.
- Boujraf S, Benajiba N, Belahsen F, Tizniti S, Garey LJ (2006) The impact of restricted diet on brain function using BOLD-fMRI. *Exp Brain Res* 173:318-321.
- Bowers D, Miller K, Mikos A, Kirsch-Darrow L, Springer U, Fernandez H, Foote K, Okun M (2006) Startling facts about emotion in Parkinson's disease: blunted reactivity to aversive stimuli. *Brain* 129:3356-3365.
- Breitenstein C, Daum I, Ackermann H (1998) Emotional processing following cortical and subcortical brain damage: contribution of the fronto-striatal circuitry. *Behav Neurol* 11:29-42.

- Bucher K, Dietrich T, Marcar VL, Brem S, Halder P, Boujraf S, Summers P, Brandeis D, Martin E, Loenneker T (2006) Maturation of luminance- and motion-defined form perception beyond adolescence: a combined ERP and fMRI study. *Neuroimage* 31:1625-1636.
- Butters N, Butter C, Rosen J, Stein D (1973) Behavioral effects of sequential and one-stage ablations of orbital prefrontal cortex in the monkey. *Exp Neurol* 39:204-214.
- Clark US, Nearing S, Cronin-Golomb A (2008) Specific impairments in the recognition of emotional facial expressions in Parkinson's disease. *Neuropsychologia* 46:2300-2309.
- Cools R, D'Esposito M (2011) Inverted-U-shaped dopamine actions on human working memory and cognitive control. *Biol Psychiatry* 69:e113-125.
- Cools R, Stefanova E, Barker RA, Robbins TW, Owen AM (2002) Dopaminergic modulation of high-level cognition in Parkinson's disease: the role of the prefrontal cortex revealed by PET. *Brain* 125:584-594.
- Cronin-Golomb A (2010) Parkinson's disease as a disconnection syndrome. *Neuropsychol Rev* 20:191-208.
- Dara C, Monetta L, Pell MD (2008) Vocal emotion processing in Parkinson's disease: reduced sensitivity to negative emotions. *Brain Res* 1188:100-111.
- Dolan RJ, Fletcher P, Morris J, Kapur N, Deakin JF W, Frith CD (1996) Neural activation during covert processing of positive emotional facial expressions. *Neuroimage* 4:194-200.
- Fromm D, Holland AL, Swindell CS, Reinmuth OM (1985) Various consequences of subcortical stroke: prospective study of 16 consecutive cases. *Arch Neurol* 42:943-950.
- Fusar-Poli P, Placentino A, Carletti F, Landi P, Allen P, Surguladze S, Benedetti F, Abbamonte M, Gasparotti R, Barale F, Perez J, McGuire P, Politi P (2009) Functional atlas of emotional faces processing: a voxel-based meta-analysis of 105 functional magnetic resonance imaging studies. *J Psychiatry Neurosci* 34:418-432.
- Goetz CG, Stebbins GT, Chmura TA, Fahn S, Poewe W, Tanner CM (2010) Teaching program for the Movement Disorder Society-sponsored revision of the Unified Parkinson's Disease Rating Scale: (MDS-UPDRS). *Mov Disord* 25:1190-1194.
- Gray HM, Tickle-Degnen L (2010) A meta-analysis of performance on emotion recognition tasks in PD. *Neuropsychology* 24:176-191
- Halder P, Brem S, Bucher K, Boujraf S, Summers P, Dietrich T, Kollias S, Martin E, Brandeis D (2007) Electrophysiological and hemodynamic evidence for late maturation of hand power grip and force control under visual feedback. *Hum Brain Mapp* 28:69-84.
- Heberlein AS, Atkinson AP (2009) Neuroscientific evidence for simulation and shared substrates in emotion recognition: beyond faces. *Emot Rev* 1:162-177.
- Hinrichs H, Machleidt W (1992) Basic emotions reflected in EEG-coherences. *Int J Psychophysiol* 13:225-232.
- Hoehn MM, Yahr MD (1967) Parkinsonism: onset, progression, and mortality. *Neurology* 17:427-442.
- Hornak J, Bramham J, Rolls ET, Morris RG, O'Doherty J, Bullock PR, Polkey CE (2003) Changes in emotion after circumscribed surgical lesions of the orbitofrontal and cingulate cortices. *Brain* 126:1691-1712.
- Hsu YT, Lai HY, Chang YC, Chiou SM, Lu MK, Lin YC, Liu YL, Chen CC, Huang HC, Chien TF, Lin SZ, Chen YY, Tsai CH (2012) The role of the subthalamic nucleus in the preparation of volitional movement termination in Parkinson's disease. *Exp Neurol* 233:253-263.
- Jacobs DH, Shuren J, Bowers D, Heilman KM (1995) Emotional facial imagery, perception, and expression in Parkinson's disease. *Neurology* 45:1696-1702.
- Jankovic J (2008) Parkinson's disease: clinical features and diagnosis. *J Neurol Neurosurg Psychiatry* 79:368-376.
- Kaasinen V, Nagren K, Hietala J, Oikonen V, Vilkinen H, Farde L, Halldin C, Rinne JO (2000) Extra striatal dopamine D2 and D3 receptors in early and advanced Parkinson's disease. *Neurology* 54:1482-1487.
- Kaasinen V, Nurmi E, Brück A, Eskola O, Bergman J, Solin O, Rinne JO (2001) Increased frontal [(18)F] fluoro dopa uptake in early Parkinson's disease: sex differences in the prefrontal cortex. *Brain* 124:1125-1130.
- Kober H, Barrett LF, Joseph J, Bliss-Moreau E, Lindquist K, Wager TD (2008) Functional grouping and cortical-subcortical interactions in emotion: A meta-analysis of neuroimaging studies. *Neuroimage* 42:998-1031.
- Lawrence AD, Goerendt IK, Brooks DJ (2007) Impaired recognition of facial expression of anger in Parkinson's disease patients acutely withdrawn from dopamine replacement therapy. *Neuropsychologia* 45:65-74.
- Lin CY, Tien YM, Huang JT, Tsai CH, Hsu LC (2016) Degraded impairment of emotion recognition in Parkinson's disease extends from negative to positive emotions. *Behav Neurol* 2016:9287092.
- Lotze M, Reimold M, Heymans U, Laihin A, Patt M, Halsband U (2009) Reduced ventrolateral fMRI response during observation of emotional gestures related to the degree of dopaminergic impairment in Parkinson disease. *J Cogn Neurosci* 21:1321-1331.
- Mauss IB, Robinson MD (2009) Measures of emotion: A review. *Cogn Emot* 23:209-237.
- Miller KM, Okun MS, Marsiske M, Fennell EB, Bowers D (2009) Startle reflex hyporeactivity in Parkinson's disease: an emotion-specific or arousal-modulated deficit? *Neuropsychologia* 47:1917-1927.
- Owen AM, Doyon J, Dagher A, Sadikot A, Evans AC (1998) Abnormal basal ganglia outflow in Parkinson's disease identified with PET: implications for higher cortical functions. *Brain* 121:949-965.
- Pell MD, Leonard CL (2005) Facial expression decoding in early Parkinson's disease. *Cogn Brain Res* 23:327-340.
- Peron J, Dondaine T, Le Jeune F, Grandjean D, Vèrin M (2012) Emotional processing in Parkinson's disease: a systematic review. *Mov Disord* 27:186-199.
- Phan KL, Wager T, Taylor SF, Liberzon I (2002) Functional neuroanatomy of emotion: a meta-analysis of emotion activation studies in PET and fMRI. *Neuroimage* 16:331-348.
- Pogarell O, Oertel WH (1999) Parkinsonian syndromes and Parkinson's disease: diagnosis and differential diagnosis. In: *Parkinson's disease: the treatment options* (LeWitt PA, Oertel WH, eds). London, UK: Martin Dunitz 2010.
- Rakshi JS, Uema T, Ito K, Bailey DL, Morrish PK, Ashburner J, Dagher A, Jenkinson IH, Friston KJ, Brooks DJ (1999) Frontal, midbrain and striatal dopaminergic function in early and advanced Parkinson's disease A 3D [(18)F] dopa-PET study. *Brain* 122(Pt 9):1637-1650.
- Ricciardi L, Visco-Comandini F, Erro R, Morgante F, Bologna M, Fasano A, Ricciardi D, Edwards MJ, Kilner J (2017) Facial emotion recognition and expression in Parkinson's disease: an emotional mirror mechanism? *PLoS One* 12(1):e0169110.
- Rizzolatti G, Arbib MA (1998) Language within our grasp. *Trends Neurosci* 21:188-194.
- Robotham L, Sauter DA, Bachoud-Levi AC, Trinkler I (2011) The impairment of emotion recognition in Huntington's disease extends to positive emotions. *Cortex* 47:880-884.
- Schienze A, Ille R, Wabnegger A (2015) Experience of negative emotions in Parkinson's disease: An fMRI investigation. *Neurosci Lett* 609:142-146.
- Scott S, Caird F, Williams B (1984) Evidence for an apparent sensory speech disorder in Parkinson's disease. *J Neurol Neurosurg Psychiatry* 47:840-843.
- Sprengelmeyer R, Young AW, Mahn K, Schroeder U, Woitalla D, Büttner T, Kuhn W, Przuntek H (2003) Facial expression recognition in people with medicated and unmedicated Parkinson's disease. *Neuropsychologia* 41:1047-1057.
- St. Clair J, Borod JC, Sliwinski M, Cote LJ, Stern Y (1998) Cognitive and affective functioning in Parkinson's disease patients with lateralized motor signs. *J Clin Exp Neuropsychol* 20:320-327.
- Suzuki A, Hoshino T, Shigemasa K, Kawamura M (2006) Disgust-specific impairment of facial expression recognition in Parkinson's disease. *Brain* 129:707-717.
- Wabnegger A, Ille R, Schwingenschuh P, Katschnig-Winter P, Kögl-Wallner M, Wenzel K, Schienze A (2015) Facial emotion recognition in Parkinson's disease: An fMRI investigation. *PLoS One* 10:e0136110.
- Wieser MJ, Muhlberger A, Alpers GW, Macht M, Ellgring H, and Pauli P (2006) Emotion processing in Parkinson's disease: dissociation between early neuronal processing and explicit ratings. *Clin Neurophysiol* 117:94-102.
- Wieser MJ, Muhlberger A, Alpers G, Macht M, Ellgring H, Pauli P (2006) Emotion processing in parkinson's disease: Dissociation between early neuronal processing and explicit ratings. *Clin Neurophysiol* 117:94-102.
- Yip JT, Lee TM, Ho SL, Tsang KL, Li LS (2003) Emotion recognition in patients with idiopathic Parkinson's disease. *Mov Disord* 18:1115-1122.
- Yuvaraj R, Murugappan M, Acharya UR, Adeli H, Ibrahim NM, Mesquita E (2016) Brain functional connectivity patterns for emotional state classification in Parkinson's disease patients without dementia. *Behav Brain Res* 298(Pt B):248-260.

P-Reviewer: Song H; C-Editor: Zhao M; S-Editor: Li CH; L-Editor: Song LP; T-Editor: Liu XL