

## Clinical and translational advances in primary brain tumor therapy with a focus on glioblastoma-A comprehensive review of the literature

Muhammad Saqib<sup>a,\*</sup>, Aanus Zahoor<sup>b</sup>, Ahmed Rahib<sup>c</sup>, Amna Shamim<sup>d</sup>, Hassan Mumtaz<sup>e</sup>

<sup>a</sup> Khyber Medical College, Peshawar, Pakistan

<sup>b</sup> Bacha Khan Medical College, Mardan, Pakistan

<sup>c</sup> Nowshera Medical College, Nowshera, Pakistan

<sup>d</sup> King Edward Medical University, Lahore, Pakistan

<sup>e</sup> Maroof International Hospital, Islamabad, Pakistan

### ARTICLE INFO

#### Keywords:

Brain tumors  
Glioma  
Neural stem cells  
Cancer stem cells  
Neuron  
Glial cells  
Immunotherapy

### ABSTRACT

This comprehensive review paper examines the most updated state of research on glioblastoma, an aggressive brain tumor with limited treatment options. By analyzing 76 recent studies, from translational and basic sciences, to clinical trials, we highlight various aspects of glioblastoma and shed light on potential therapeutic strategies. The interplay between tumor cells, neural progenitor cells, and the tumor microenvironment is explored. Targeting the PI3K-Akt-mTOR pathway through extracellular-vesicle (EV)-mediated signaling emerges as a potential therapeutic strategy. Personalized modeling approaches utilizing patient-specific MRI data offer promise for optimizing treatment strategies. The response of glioblastoma stem cells (GSCs) to different treatment modalities is examined, emphasizing the need to inhibit the transformation of proneural (PN) GSCs into resistant mesenchymal (MES) GSCs. Metabolic therapy and combination therapies show potential in reversing treatment resistance and inhibiting both PN and MES GSCs. Immunotherapy, targeted approaches, and molecular dynamics in gliomas are discussed, providing insights into early-stage diagnosis and treatment. Additionally, the potential use of Zika virus as an oncolytic agent is explored. Analysis of phase 0 to 3 clinical trials reveal promising outcomes for various experimental treatments, highlighting the importance of combination therapies, predictive signatures, and patient selection strategies. Specific compounds demonstrate potential therapeutic benefits and tolerability. Phase 3 trials indicate the efficacy of DCVax-L in improving survival rates and deparutux-m in prolonging progression-free survival. These findings emphasize the importance of personalized treatment approaches and continued exploration of targeted therapies, immunotherapies, and tumor biology understanding in shaping the future of glioblastoma treatment.

### 1. Introduction

The classification of brain tumors and other central nervous system (CNS) tumors is a complex process that considers both histological and molecular characteristics. The fifth edition of the World Health Organization Classification of Tumors of the Central Nervous System (WHO CNS5) in 2021<sup>1</sup> places increased emphasis on the role of molecular diagnostics in the classification of CNS tumors.<sup>1</sup> The advancements in cancer genomics have significantly impacted diagnostic criteria, while the discovery of molecular-targeted therapies has provided new perspectives for the management and prognosis of these tumors. It is now recognized that a multidisciplinary treatment (MDT) approach and

personalized therapies are crucial for enhancing patient survival and improving their quality of life.<sup>2</sup> Glioblastoma Multiforme (GBM) is a primary brain tumor known for its poor prognosis and lack of a definitive cure despite significant research efforts. GBM tumors exhibit high heterogeneity, consisting of a combination of cancer cells, cancer stem cells (CSCs), and normal neural stem cells (NSCs). NSCs have a tendency to infiltrate the tumor and migrate within the central nervous system tissue alongside cancer cells.<sup>3</sup> Cancer stem cell (CSC) formation is a complex process influenced by factors like the tumor microenvironment, epigenetic changes, and developmental pathways. Neural stem cells (NSCs) can release factors that promote CSC characteristics in GBM cells, while GBM cells can induce NSC differentiation. Understanding these

\* Corresponding author. Khyber Medical College, University of Peshawar, Rd No. 2, Peshawar, 25120, Pakistan.

E-mail addresses: [muhammadsaqib.drkmc@gmail.com](mailto:muhammadsaqib.drkmc@gmail.com) (M. Saqib), [muhammadanas7226@gmail.com](mailto:muhammadanas7226@gmail.com) (A. Zahoor), [ahmedrahib301@gmail.com](mailto:ahmedrahib301@gmail.com) (A. Rahib), [amna.shamim16@gmail.com](mailto:amna.shamim16@gmail.com) (A. Shamim), [hassanmumtaz.dr@gmail.com](mailto:hassanmumtaz.dr@gmail.com) (H. Mumtaz).

<https://doi.org/10.1016/j.wnsx.2024.100399>

Received 8 June 2023; Accepted 20 September 2024

Available online 21 September 2024

2590-1397/© 2024 The Authors. Published by Elsevier Inc. This is an open access article under the CC BY-NC license (<http://creativecommons.org/licenses/by-nc/4.0/>).

mechanisms will help identify therapeutic targets to overcome cell resistance and improve treatment strategies. Targeting and eliminating CSCs can enhance the effectiveness of chemo-radiation therapy, controlling the malignant progression of GBM.<sup>3</sup> GBM is classified as a Grade IV tumor by the WHO.<sup>4</sup> Despite the availability of treatments such as surgery, chemotherapy, and radiotherapy, the prognosis for GBM patients remains extremely poor, with an average survival time of approximately 16 months. The current therapeutic approaches have not yielded significant improvements in survival rates, with only a small percentage of patients (around 6 %) surviving beyond five years. The difficulties in effectively treating GBM are attributed to the notable heterogeneity that exists both between different tumors and within individual tumors. GBM primarily affects older individuals, with the typical age of diagnosis being around 64 years. The incidence of GBM increases with age, peaking between 75 and 84 years. The age range of 55–64 years is where primary GBM is commonly diagnosed, while secondary GBM is more frequently observed in individuals around 40 years old. In contrast, GBM is relatively rare in children, with low incidence rates found in this particular population.<sup>5</sup> Immune checkpoint inhibition is one form of therapy used to treat cancers but the phenomenal efficacy of immune checkpoint blockade (ICB) seen in other various cancer types has not translated to glioblastoma (GBM), highlighting the need to understand the factors influencing immune responses in this particular brain tumor.<sup>6</sup> Previous immunotherapies have failed to improve outcomes for GBM patients. Despite this, some subsets of patients have shown positive responses to ICB, indicating the potential for clinical benefit. Understanding the tumor-immune crosstalk and the unique characteristics of the tumor microenvironment in GBM is crucial. Recent studies have revealed the presence of immune cells within the brain, challenging the notion of immune privilege in this organ.<sup>6</sup> The tumor microenvironment in GBM consists of a diverse array of immune cells, including myeloid cells, macrophages, and lymphocytes, with different phenotypes associated with distinct molecular programs. The interaction between immune cells and tumor cells shapes the inflammatory phenotypes observed in GBM. Different transcriptional programs have been identified, such as the astrocyte-like, oligodendrocyte precursor cell-like, neural progenitor cell-like, and mesenchymal-like programs, each associated with unique immune profiles. These inflammatory phenotypes may provide opportunities for personalized immunotherapeutic strategies. Furthermore, understanding the immunogenic GBM cell phenotype and its modulation by the tumor microenvironment can help identify patients likely to respond to immunotherapy.<sup>6</sup> Many different approaches and methods have been created to increase the amount of time that patients can survive. These approaches have shown improved effectiveness in treating animals, but only a few have been tested in clinical trials. Considering the challenges of drug resistance and the high likelihood of GBM returning, researchers are investigating combined therapies to achieve the best possible treatment outcomes. These combined therapies have been found to be more effective against GBM compared to using a single therapy alone. The choice of therapeutic agents used together, the timing of the treatments, and the delivery systems used all play significant roles in determining the overall results.<sup>7</sup> In this comprehensive review of the most updated and peer-reviewed literature, we aim to highlight the clinical and translational advances in primary brain tumor therapy with a focus on glioblastoma.

## 2. Methods

### 2.1. Literature search strategy

Multiple electronic databases, including PubMed, Scopus, and Web of Science, were searched using a combination of MeSH terms and keywords related to brain tumors, glioma, neural stem cells, cancer stem cells, neurons, glioblastoma, glial cells, and immunotherapy. Boolean operators “AND” and “OR” were used to refine the search. English

language and publication type of clinical trials were applied as filters. The search was conducted from January of 2019 till June of 2023.

### 2.2. Selection criteria

**Inclusion criteria:** Peer-reviewed journal articles with focus on brain tumors, particularly glioma, and associated cellular components; investigation of immunotherapy in brain tumor treatment; including only basic science translational experimental studies, and state of the art clinical trials were included. To provide a more holistic approach to the review, basic science papers, especially in the field of cell biology and nanotechnology were included. These papers contributed valuable insights into the cellular and molecular mechanisms underlying brain tumors, neural stem cells, cancer stem cells, neurons, glial cells, and immunotherapy. By incorporating basic science research, a broader understanding of the topic was achieved, encompassing both clinical and fundamental aspects. Only clinical trials that were completed and reported data were included in this review.

**Exclusion criteria:** Duplicates papers, papers that lacked relevance to the topic of primary brain tumors, papers that were unavailable as full text, case reports, opinion articles, cross sectional studies and papers published before the pre-determined timeframe (2019 till 2023) were excluded. This timeframe was chosen so that only the most updated studies can be included in our narrative review to reflect the current landscape. To maintain focus on primary brain tumors, studies specifically related to brain metastases were excluded. The review aimed to concentrate on the mechanisms and therapeutic strategies related to primary brain tumors, such as gliomas, rather than secondary brain involvement originating from distant primary tumors. Clinical trials with a sample size of less than 8 were excluded to ensure an adequate representation of the population and to reduce the potential impact of small sample biases.

### 2.3. Article screening and selection

Three independent reviewers screened the titles and abstracts of the retrieved articles for relevance. Full texts of the selected articles were evaluated based on the inclusion and exclusion criteria. Reference lists of relevant articles were manually examined for additional sources.

### 2.4. Data extraction and synthesis

Data extraction was conducted using a predefined form. Extracted information included author, study population, intervention or exposure, outcomes or implications. The data were tabulated and categorized according to headings of basic science and translational research and different phases of clinical trials. A narrative synthesis approach was employed to present a descriptive overview of the findings and discuss their implications within the context of brain tumors, neural stem cells, cancer stem cells, neurons, glial cells, and immunotherapy.

The methodology is summarized in the flowchart listed in [Fig. 1](#) below.

## 3. Results

A total of 16 phase 0/1 clinical trials were analyzed to explore various therapeutic approaches for gliomas as shown in [Table 1](#). Multiple trials assessed the safety and efficacy of targeted inhibitors, such as Isocitrate dehydrogenase (IDH) inhibitor DS-1001. DS-1001 is an oral selective inhibitor of mutant IDH1 that effectively crosses the blood–brain barrier (DS-1001), a brain-penetrant mutant IDH1 inhibitor, and Vorasidenib, a dual inhibitor of mutant IDH1/2. These trials aimed to evaluate the potential of these inhibitors in treating recurrent or progressive gliomas. One trial investigated the use of renin-angiotensin system modulators for glioblastoma treatment. The study sought to repurpose existing drugs to target gliomas and evaluated their

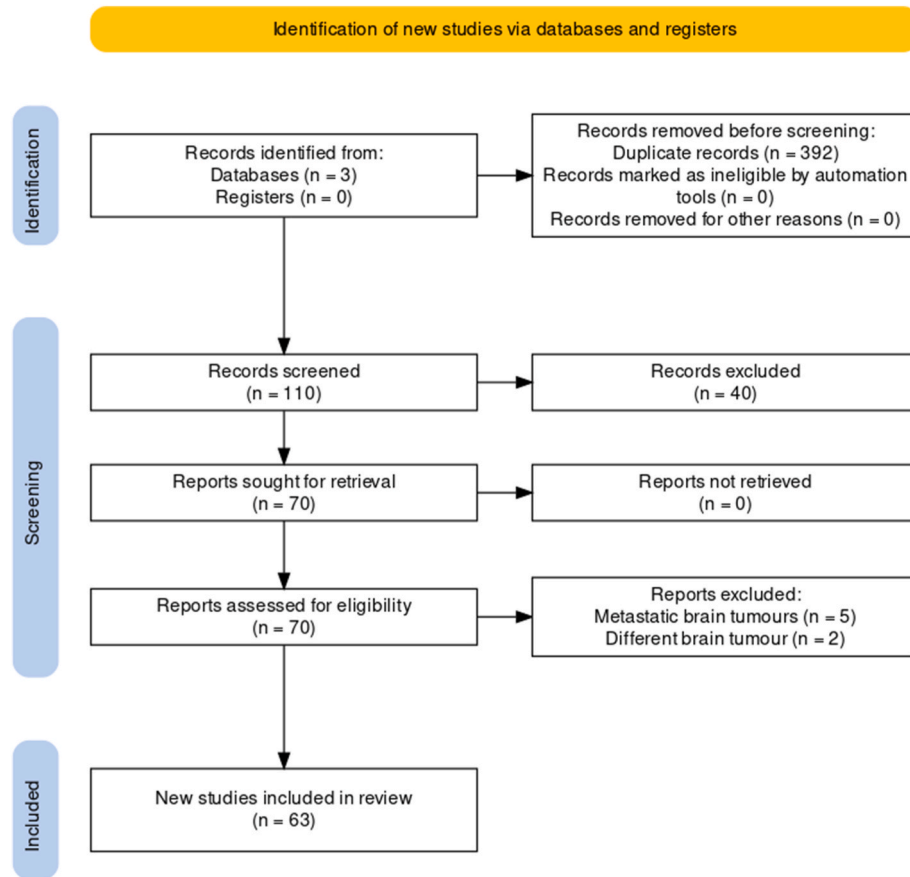


Fig. 1. Flowchart of study methodology.

effectiveness in a phase I setting. Trials focused on novel inhibitors included a study on the signal transducer and activator of transcription 3 (p-STAT3) inhibitor WP1066, which targeted recurrent malignant glioma, and Zotiraciclib, which was assessed in combination with Temozolomide for high-grade astrocytomas. Several trials explored combinations of different therapies. These included a study that combined pembrolizumab and bevacizumab with hypofractionated stereotactic re-irradiation, as well as the combination of afatinib, radiotherapy, and temozolomide for newly diagnosed glioblastoma. Trials investigated immunotherapy approaches through combinations with radiotherapy or gene-mediated cytotoxic immunotherapy using gene-mediated cytotoxic immunotherapy (AdV-tk) as an adjuvant to surgery and radiation. Additionally, specific trials focused on pediatric patients, examining the effects of palbociclib and ribociclib in children with progressive brain tumors or diffuse intrinsic pontine gliomas. Overall, these phase 0/1 trials explored a range of therapeutic strategies for gliomas, including targeted inhibitors, repurposed drugs, combination therapies, and immunotherapy. The findings from these studies provide valuable insights into potential treatment options for gliomas, highlighting the ongoing efforts in this field.

A total of 11 phase Ib/II clinical trials were included that focused on various therapeutic approaches for gliomas as shown in Table 2. The safety and efficacy of triple-mutated oncolytic herpes virus G47 $\Delta$  were investigated in a phase I/II study involving patients with progressive glioblastoma. Several trials evaluated the combination of vorinostat with radiation and maintenance vorinostat in children with diffuse intrinsic pontine glioma. Additionally, a trial explored the use of chloroquine in combination with concurrent radiotherapy and temozolomide for newly diagnosed glioblastoma. Studies examined the safety and efficacy of bevacizumab, irinotecan, and erlotinib in children with progressive diffuse intrinsic pontine glioma. Furthermore, the use of

depatuxizumab mafodotin was assessed in Japanese patients with malignant glioma. An autologous adoptive immune-cell therapy trial demonstrated a durable response with enhanced immune reaction signatures in patients with recurrent glioblastoma. The MEVITEM trial compared the effectiveness of vismodegib plus temozolomide with temozolomide alone in patients with recurrent or refractory medulloblastoma with Sonic Hedgehog pathway activation. Trials investigated the safety and efficacy of combining veliparib with radiation and temozolomide in newly diagnosed diffuse pontine glioma. Additionally, the effectiveness of VB-111, an anticancer gene therapy, was evaluated in patients with recurrent glioblastoma. A study focused on investigating the combination of galunisertib, a transforming growth factor-beta receptor I inhibitor, with standard temozolomide-based radiochemotherapy in patients with newly diagnosed malignant glioma. Overall, these phase I/II trials explored a wide range of therapeutic strategies, including oncolytic viruses, epigenetic modulation, targeted therapies, immunotherapy, hedgehog pathway inhibition, combination therapies, and growth factor inhibition. The findings from these studies contribute significantly to our understanding of potential treatment options for gliomas and underscore the ongoing efforts in this field.

29 phase Ib clinical trials on gliomas were included in our review, encompassing various therapeutic approaches as shown in Table 3. The trials evaluated the efficacy and safety of different treatments, including selinexor for recurrent glioblastoma, trabectedin for recurrent meningioma, and autologous dendritic cell vaccine – glioblastoma-1 (AV-GBM-1) for newly diagnosed glioblastoma. Other trials focused on targeted therapies, such as selumetinib for low-grade glioma, pembrolizumab plus bevacizumab for recurrent glioblastoma, and an oral gamma secretase inhibitor (RO4929097) for recurrent/progressive glioblastoma. Additionally, investigations included proton radiotherapy versus intensity-modulated radiotherapy for glioblastoma, ipilimumab

**Table 1**  
Phase 0 or 1 clinical trials.

Study (Year)	Trial name	Patient criteria	Number of patients	Drug	Primary endpoint	Outcome
Natsume et al <sup>8</sup> (2023)	The first-in-human phase I study of a brain-penetrant mutant IDH1 inhibitor DS-1001 in patients with recurrent or progressive IDH1-mutant gliomas	Patients aged 20 or above had to meet several criteria: confirmed glioma (grades 2–4) with a specific IDH1-R132 mutation, recurrent or progressive disease after standard treatment, measurable lesions according to RANO and RANO-LGG criteria, a life expectancy of at least three months, Eastern Cooperative Oncology Group performance status of 0–2, and satisfactory hematological, hepatic, and renal functions.	47	Isocitrate dehydrogenase (IDH) inhibitor DS-1001.	Tolerability of DS-1001, given orally twice a day at doses ranging from 125 to 1400 mg, for patients with recurrent or progressive IDH1 mutant glioma.	17.1 % response in enhancing tumors, 33.3 % in non-enhancing tumors. Well-tolerated, good brain distribution, and reduced D-2-hydroxyglutarate (D-2-HG) levels.
O’Rawe et al <sup>9</sup> (2021)	Treatment of glioblastoma with re-purposed renin-angiotensin system modulators: Results of a phase I clinical trial	Patients with relapsed glioblastoma who had already tried all available treatments and had a Karnofsky performance score of 60 or above.	17	Multiple oral medications (propranolol, aliskiren, cilazapril, celecoxib, curcumin with piperine, aspirin, metformin)	Effectiveness of combining RAS modulating drugs in slowing the progression of glioblastoma, maintaining quality of life and performance status, and improving overall survival in patients who had already tried all available treatments.	Average survival: 20.5 months; median survival: 19.9 months. Patients completing treatment had a mean survival of 23.8 months and maintained good quality of life. Results were not statistically significant due to small sample size.
Groot et al <sup>10</sup> (2022)	A first-in-human Phase I trial of the oral p-STAT3 inhibitor WP1066 in patients with recurrent malignant glioma	Patients aged 18 or above were included in the study if they had a Karnofsky Performance Scale (KPS) score of 60 or higher, had previously received radiation therapy and/or chemotherapy, and showed evidence of recurrence on magnetic resonance imaging (MRI). Recurrence was defined as the presence of progressive or new contrast enhancement, with at least one dimension measuring more than 10 mm, following initial treatment with radiation and temozolomide.	8	WP1066 (inhibitor of p-STAT3)	To determine the highest safe dosage (MTD/MFD) of WP1066 and assess its effectiveness in targeting p-STAT3 in patients with recurrent glioblastoma (GBM).	Safe dosage: 8 mg/kg. Common side effects: mild nausea and diarrhea. All patients experienced disease progression with a median survival of 25 months
Mehta et al <sup>11</sup> (2022)	A Phase 0 Trial of Ceritinib in Patients with Brain Metastases and Recurrent Glioblastoma	Adults over 18 years with brain metastasis or recurrent glioblastoma with tissue-confirmed samples of specific markers (pALK, IGF1R, pFAK) in their tumors with performance status $\leq 2$ , ANC $\geq 1.5 \times 10^9/L$ , Hgb $\geq 8$ g/dL, bilirubin $\leq 1.5 \times$ ULN, AST $< 3.0 \times$ ULN, and ALT $< 3.0 \times$ ULN.	10	Ceritinib (inhibitor of ALK, IGF1R, FAK)	To examine the tumor pharmacokinetics (PK) and pharmacodynamics (PD) of ceritinib in patients with brain metastasis or recurrent glioblastoma.	No dose-limiting toxicities. Strong binding to plasma proteins and brain tumor tissue, but no significant changes in pharmacodynamic biomarkers in treated tumor samples.
Fares et al <sup>12</sup> (2021)	Neural stem cell delivery of an oncolytic adenovirus in newly diagnosed malignant glioma: a first-in-human, phase 1, dose-escalation trial	Patients with newly diagnosed, histologically confirmed, high-grade gliomas (WHO grade III or IV) were recruited	12	NSC-CRAAd-S-pk7 (oncolytic adenovirus delivered by neural stem cells)	To determine the maximal tolerated dose of NSC-CRAAd-S-pk7	Feasible and safe. Strong evidence supports further study in larger phase 2/3 trials.
Mellinghoff et al <sup>13</sup> (2021)	Vorasidenib, a Dual Inhibitor of Mutant IDH1/2, in Recurrent or Progressive Glioma;	Patients with mutant IDH1/2 (mIDH1/2) solid tumors, including 52 patients with glioma that had recurred or progressed	93	Vorasidenib (AG-881) (inhibitor of mutant IDH1 and IDH2)	To determine tolerability of Vorasidenib in patients with recurrent or progressive nonenhancing mutant isocitrate dehydrogenase	Reversible side effects at higher doses. For nonenhancing gliomas: 18 % response rate, longer median progression-free

(continued on next page)

Table 1 (continued)

Study (Year)	Trial name	Patient criteria	Number of patients	Drug	Primary endpoint	Outcome
	Results of a First-in-Human Phase I Trial	following standard therapy			(mIDH) lower grade gliomas (LGGs).	survival, and observed tumor shrinkage in multiple patients.
Sahebjam et al <sup>14</sup> (2021)	Hypofractionated stereotactic re-irradiation with pembrolizumab and bevacizumab in patients with recurrent high-grade gliomas: results from a phase I study	Patients with recurrent glioblastoma or anaplastic astrocytoma	32	Pembrolizumab (anti-PD1), hypofractionated stereotactic irradiation (HFSRT), bevacizumab (VEGF inhibitor)	To evaluate the appropriate dosage, safety, tolerability, and initial effectiveness of combining pembrolizumab (an anti-PD1 antibody), hypofractionated stereotactic irradiation (HFSRT), and bevacizumab in patients with recurrent high-grade gliomas (HGGs).	Common adverse events: proteinuria, fatigue, increased alanine aminotransferase, hypertension. Bevacizumab-naïve group showed high response rate; bevacizumab-resistant group achieved partial response.
DeWire et al <sup>15</sup> (2021)	A Phase I and Surgical Study of Ribociclib and Everolimus in Children with Recurrent or Refractory Malignant Brain Tumors: A Pediatric Brain Tumor Consortium Study	Children with refractory malignant or recurrent brain tumors undergoing resection.	16	Ribociclib (CDK4/6 inhibitor) and Everolimus (mTOR inhibitor)	To determine the maximum tolerated dose (MTD) or recommended phase II dose (RP2D) of the treatment regimen	Well-tolerated with pharmacokinetics similar to adults. Potential therapeutic levels of ribociclib observed in cerebrospinal fluid and tumor tissue, with variability among patients.
Van Mater et al <sup>16</sup> (2021)	A phase I trial of the CDK 4/6 inhibitor palbociclib in pediatric patients with progressive brain tumors: A Pediatric Brain Tumor Consortium study (PBTC-042)	Pediatric patients who had progressive or refractory brain tumors and had an intact retinoblastoma protein.	35	Palbociclib (CDK4/6 inhibitor)	To establish the maximum tolerated dose (MTD) of palbociclib and to describe any toxicities associated with its use.	Maximum tolerated dose (MTD): 75 mg/m <sup>2</sup> . Main toxicities: myelosuppression, particularly grade 3/4 neutropenia and leukopenia. No objective responses observed with palbociclib treatment.
Saran et al <sup>17</sup> (2021)	Afatinib and radiotherapy, with or without temozolomide, in patients with newly diagnosed glioblastoma: results of a phase I trial	Patients who were recently diagnosed with grade 4 malignant glioma, confirmed by histological analysis, and had a documented O6-methylguanine-DNA methyltransferase gene promoter methylation status.	55	Afatinib (protein kinase inhibitor) in combination with radiotherapy (RT), with or without temozolomide (TMZ).	To determine the maximum tolerated dose (MTD) of daily afatinib when combined with radiotherapy (RT), either with concomitant TMZ treatment.	Afatinib discontinued by all patients primarily due to disease progression and adverse events. Most frequent adverse events: diarrhea and rash. Maximum tolerated dose: 30 mg with TMZ and RT, 40 mg with RT alone.
Wu et al <sup>18</sup> (2021)	Phase I Study of Zotiraciclib in Combination with Temozolomide for Patients with Recurrent High-grade Astrocytomas	Patients who had recurrent high-grade astrocytomas	53	Zotiraciclib (selective kinase inhibitor) and Temozolomide (alkylating agent).	To assess the toxicity profile of zotiraciclib when combined with temozolomide in patients with recurrent high-grade astrocytoma. Additionally, the goal was to determine the optimal dosing schedule for this combination treatment.	Safe combination for recurrent high-grade astrocytomas, despite transient neutropenia. Feasibility of personalized dosing.
Wei et al <sup>19</sup> (2021)	Safety and tolerability of asunercept plus standard radiotherapy/temozolomide in Asian patients with newly-diagnosed glioblastoma: a phase I study	Patients with newly-diagnosed glioblastoma	10	Asunercept (novel glycosylated fusion protein) in combination with standard radiotherapy and temozolomide (RT/TMZ).	To evaluate the tolerability and safety of asunercept in combination with standard radiotherapy and temozolomide (RT/TMZ) in Asian patients	Well-tolerated with promising efficacy: 57.1 % progression-free survival at 12 months.
Kaley et al <sup>20</sup> (2020)	Phase I clinical trial of temsirolimus and perifosine for recurrent glioblastoma	Adults with recurrent malignant glioma (MG), Karnofsky Performance Status $\geq 60$	35	Temsirolimus (mTOR inhibitor) and Perifosine (protein kinase B inhibitor, also known as Akt inhibitor)	To determine safety and a recommended phase II dose.	Temsirolimus and perifosine are tolerable in heavily pretreated adults with recurrent MGs when dosed at 115 mg and 100 mg weekly and daily, respectively.
Hipp et al <sup>21</sup> (2020)	A phase I trial of lenalidomide and radiotherapy in children with diffuse intrinsic pontine gliomas or high-grade gliomas	Children with diffuse intrinsic pontine gliomas or high-grade gliomas	29	Lenalidomide (immunomodulatory agent)	To determine the maximum tolerated dose (MTD) or the recommended phase 2 dose (RP2D).	Children can tolerate higher doses of lenalidomide (116 mg/m <sup>2</sup> /day) during radiation therapy than adults. This is important because higher doses of lenalidomide are more effective in treating malignant gliomas.

(continued on next page)



Table 1 (continued)

Study (Year)	Trial name	Patient criteria	Number of patients	Drug	Primary endpoint	Outcome
Kieran et al <sup>22</sup> (2019)	Phase I study of gene-mediated cytotoxic immunotherapy with Adv-tk as adjuvant to surgery and radiation for pediatric malignant glioma and recurrent ependymoma	Patients 3 years of age or older with malignant glioma or recurrent ependymoma.	8	Gene-mediated cytotoxic immunotherapy (GMCI)	To evaluate GMCI in patients 3 years of age or older with malignant glioma or recurrent ependymoma.	The treatment was well-tolerated and no patients had any serious side effects. Three patients who received the higher dose were alive more than 24 months after treatment, with two being alive without any signs of tumor growth for 37.3 and 47.7 months.
Galanis et al <sup>23</sup> (2019)	A phase 1 and randomized, placebo-controlled phase 2 trial of bevacizumab plus dasatinib in patients with recurrent glioblastoma: Alliance/North Central Cancer Treatment Group N0872	Patients with recurrent glioblastoma multiforme	121	Dasatinib (Src family kinase inhibitor) plus bevacizumab	To determine 6-month progression-free survival (PFS6).	No significant difference was observed in outcomes with addition of dasatinib.
Lassman et al <sup>24</sup> (2019)	Safety and efficacy of depatuxizumab mafodotin + temozolomide in patients with EGFR-amplified, recurrent glioblastoma: results from an international phase I multicenter trial	Patients with epidermal growth factor receptor (EGFR)-amplified, recurrent glioblastoma	60	Antibody-drug conjugate depatuxizumab mafodotin (depatux-m) plus temozolomide (TMZ)	To determine efficacy, safety and pharmacokinetics (PK) of depatux-m + temozolomide (TMZ) in patients with EGFR-amplified rGBM	Well-tolerated with common adverse events including blurred vision, fatigue, and photophobia. Objective response rate: 14.3 %. 6-month progression-free survival rate: 25.2 %. 6-month overall survival rate: 69.1 %.
Jiang et al <sup>25</sup> (2021)	Combination of Immunotherapy and Radiotherapy for Recurrent Malignant Gliomas: Results From a Prospective Study	Patients with recurrent WHO grade IV glioma	30	Intracranial and systemic immunoadjuvant drugs in combination with low-dose reirradiation.	To assess safety of the regimen.	Mild adverse events: fever, vomiting, headache, fatigue; one patient with grade 3 fever. No severe adverse events or deaths. Response rates: complete (3.3 %), partial (16.7 %), stable disease (30.0 %), progressive disease (50.0 %). Overall response rate: 20.0 %. Median progression-free survival: 88.0 days; median overall survival: 362.0 days. Significant survival differences observed between responders and non-responders, suggesting potential benefits for recurrent WHO grade IV glioma patients.

and nivolumab for leptomeningeal carcinomatosis, and continuous oral everolimus for pediatric low-grade glioma. These trials contribute valuable insights into potential treatment options for gliomas and highlight the ongoing efforts in this field.

In this comprehensive review, 7 phase III clinical trials for glioblastoma were also included as shown in Table 4, examining various therapeutic approaches. These trials investigated the efficacy of autologous tumor lysate-loaded dendritic cell vaccination, radiotherapy combined with nivolumab or temozolomide, depatuxizumab mafodotin, chemoradiotherapy with temozolomide plus nivolumab or placebo, nivolumab vs bevacizumab, personalized peptide vaccination, and adjuvant temozolomide chemotherapy with or without interferon alfa. These trials provide critical insights into treatment options for newly diagnosed and recurrent glioblastoma, contributing to the understanding and advancement of therapeutic strategies in this challenging disease.

## 4. Discussion

### 4.1. Translational and basic science research

Glioblastomas are aggressive brain tumors that pose a challenge due to their resistance to current therapies and ability to recruit normal cells from their surroundings. Neural progenitor cells (NPCs) migrate towards glioblastomas, but the mechanisms underlying this interaction are unclear. In a study by Pan et al,<sup>74</sup> glioblastoma-derived extracellular vesicles (EVs) were found to promote glioblastoma cell growth and migration. Additionally, these EVs significantly enhanced NPC proliferation and migration. The activation of the PI3K-Akt-mTOR pathway in NPCs mediated these effects. Inhibiting this pathway reversed the increased proliferation and migration caused by glioblastoma-derived EVs. These findings highlight the role of EVs in intercellular communication within the tumor microenvironment and suggest targeting the tumorigenic EVs-mediated PI3K-Akt-mTOR pathway as a potential therapeutic strategy for glioblastoma.<sup>74</sup> Not only do glioblastoma cells

**Table 2**  
Phase 1b or 2 clinical trials.

Study (Year)	Trial name	Patient criteria	Number of patients	Drug	Primary endpoint	Outcome
Todo et al <sup>26</sup> (2022)	A phase I/II study of triple-mutated oncolytic herpes virus G47Δ in patients with progressive glioblastoma	Japanese adults with recurrent/progressive glioblastoma despite radiation and temozolomide therapies	13	G47Δ, a triple-mutated oncolytic herpes simplex virus type 1	To assess the safety (primary endpoint) of G47Δ, a triple-mutated oncolytic herpes simplex virus type 1	G47Δ was well-tolerated. Median overall survival was 7.3 months and the 1-year survival rate was 38.5 %.
Su et al <sup>27</sup> (2022)	Phase I/II trial of vorinostat and radiation and maintenance vorinostat in children with diffuse intrinsic pontine glioma: A Children's Oncology Group report	Children with diffuse intrinsic pontine glioma	12	Vorinostat (suberoylanilide hydroxamic acid), an oral histone deacetylase inhibitor.	To determine the efficacy of the drug regimen by comparing the risk of progression or death	It was well tolerated, but did not improve overall survival.
Compter et al <sup>28</sup> (2021)	Chloroquine combined with concurrent radiotherapy and temozolomide for newly diagnosed glioblastoma: a phase IB trial	Patients with a newly diagnosed glioblastoma	13	Chloroquine in combination with radiotherapy and concurrent daily temozolomide	To explore the safety, pharmacokinetics and maximum tolerated dosages.	The maximum tolerated dose of chloroquine was 200 mg daily. Median overall survival was 16 months, with a 2-year survival rate of 38 %. Favorable toxicity and promising overall survival support further clinical studies of chloroquine for glioblastoma.
El-Khouly et al <sup>29</sup> (2021)	A phase I/II study of bevacizumab, irinotecan and erlotinib in children with progressive diffuse intrinsic pontine glioma	Children with progressive diffuse intrinsic pontine glioma	9	Combined treatment with VEGF inhibitor bevacizumab, topoisomerase I inhibitor irinotecan, and EGFR inhibitor erlotinib	To determine the safety, tolerability, and preliminary efficacy of combined treatment.	The median progression-free survival (PFS) at the start of the study was 7.3 months. The median overall survival (OS) was 13.8 months, and overall quality of life (QoL) was stable during treatment.
Narita et al <sup>30</sup> (2021)	Safety and efficacy of depatuxizumab mafodotin in Japanese patients with malignant glioma: A nonrandomized, phase 1/2 trial	Japanese patients with World Health Organization (WHO) grade III/IV glioma.	53	Antibody-drug conjugate targeting epidermal growth factor receptor (EGFR), depatuxizumab mafodotin (Depatux-M) alone or combined with chemotherapy or chemoradiotherapy.	6-month progression-free survival (PFS) in patients with EGFR-amplified tumors receiving second-line Depatux-M plus chemotherapy.	The study was halted due to lack of survival benefit with first-line Depatux-M. Second-line Depatux-M plus chemotherapy showed a 6-month PFS estimate of 25.6 %.
Lim et al <sup>31</sup> (2021)	Autologous adoptive immune-cell therapy elicited a durable response with enhanced immune reaction signatures in patients with recurrent glioblastoma: An open label, phase I/IIa trial	Patients with recurrent glioblastoma multiforme (GM).	14	Ex-vivo-expanded, and activated natural killer cells and T lymphocytes	To investigate the safety and efficacy of adoptive, ex-vivo-expanded, and activated natural killer cells and T lymphocytes from peripheral blood mononuclear cells of patients with recurrent GBM	Autologous adoptive immune-cell therapy was considered an effective treatment option for individuals with recurrent GBM (glioblastoma multiforme) who exhibited high immune responses in their tumor microenvironments.
Frappaz et al <sup>32</sup> (2021)	MEVITEM-a phase I/II trial of vismodegib + temozolomide vs temozolomide in patients with recurrent/refractory medulloblastoma with Sonic Hedgehog pathway activation	Patients with recurrent/refractory medulloblastoma	24	Vismodegib (sonic hedgehog inhibitor) + temozolomide (TMZ)	To explore the 6-month progression-free survival (PFS-6)	The addition of vismodegib to TMZ did not add toxicity but failed to improve PFS-6 in SHH recurrent/refractory medulloblastoma.
Baxter et al <sup>33</sup> (2020)	A phase I/II study of veliparib (ABT-888) with radiation and temozolomide in newly diagnosed diffuse pontine glioma: a Pediatric Brain Tumor Consortium study	Patients with newly diagnosed diffuse pontine glioma.	65	Veliparib (a poly-ADP ribose polymerase inhibitor) and radiation followed by veliparib and temozolomide.	To determine the recommended phase II dose (RP2D) of veliparib when administered concurrently with radiation therapy, assess the pharmacokinetic parameters of veliparib during radiation treatment, evaluate the feasibility of inpatient dose escalation of TMZ (temozolomide),	Veliparib at 65 mg/m <sup>2</sup> b. i. d. Was the recommended phase II dose (RP2D) with radiation therapy, but it caused serious side effects such as intratumoral hemorrhage, rash, and nervous system disorder. The treatment did not improve survival compared to previous cases, so enrollment was

(continued on next page)

Table 2 (continued)

Study (Year)	Trial name	Patient criteria	Number of patients	Drug	Primary endpoint	Outcome
Brenner et al <sup>34</sup> (2020)	Safety and efficacy of VB-111, an anticancer gene therapy, in patients with recurrent glioblastoma: results of a phase I/II study	Patients with recurrent glioblastoma	72	VB-111 (a type of adenovirus that does not replicate and contains a Fas-chimera transgene. It is designed to induce the targeted death of tumor blood vessel cells and stimulate a specific immune response against the tumor.) with or without bevacizumab	document any toxicities associated with the protocol therapy, and estimate the overall survival distribution in comparison to historical series. To assess the safety, tolerability, and efficacy of VB-111 with and without bevacizumab in recurrent glioblastoma.	stopped. The 1-year and 2-year survival rates were 37.2 % and 5.3 % respectively.  VB-111 was well tolerated, with the most common side effect being a temporary mild-moderate fever. The primed combination group showed significantly longer median overall survival compared to the LE and unprimed combination groups. Patients in the primed combination group also had a longer median progression-free survival compared to the LE group.
van den Bent et al <sup>35</sup> (2020)	A Phase Ib/II, open-label, multicenter study of INC280 (capmatinib) alone and in combination with buparlisib (BKM120) in adult patients with recurrent glioblastoma.	Adult patients with recurrent glioblastoma	33	Capmatinib (a kinase inhibitor that targets mesenchymal epithelial transition) and Buparlisib (PI3K/AKT kinase inhibitor)	To estimate the maximum tolerated dose (MTD) and/or identify the recommended Phase II dose (RP2D)	The maximum tolerated dose was Capmatinib Tab 300 mg twice daily + buparlisib 80 mg once daily. In Phase II, common adverse events were headache, constipation, fatigue, and increased lipase. The combination of Capmatinib and buparlisib didn't show significant activity in PTEN-deficient glioblastoma patients, highlighting the need for stricter molecular selection strategies.
Wick et al <sup>36</sup> (2020)	Phase 1 b/2a study of galunisertib, a small molecule inhibitor of transforming growth factor-beta receptor I, in combination with standard temozolomide-based radiochemotherapy in patients with newly diagnosed malignant glioma	Patients with newly diagnosed malignant glioma	Galunisertib alone ( <i>n</i> = 56); Combination of galunisertib and with temozolomide-based radiochemotherapy ( <i>n</i> = 40)	Galunisertib (a TGF-β inhibitor) with temozolomide-based radiochemotherapy (TMZ/RTX)	To confirm the tolerability and pharmacodynamic profile of galunisertib when used alongside TMZ/RTX.	No significant differences were observed in terms of efficacy, safety, or pharmacokinetics between the two treatment approaches.

recruit normal cells and turn them into cancerous cells, they also mutate themselves in such a way that they become resistant to radiotherapy. A schematic diagram representing the complex interplay between tumor cells, neural progenitor cells, and the tumor microenvironment can be visualized in Fig. 2. In a recently published review, Wang et al.<sup>75</sup> discussed the response of glioblastoma stem cells (GSCs) to different treatment modalities. They highlighted that radiotherapy could induce a transformation of proneural (PN) GSCs into resistant mesenchymal (MES) GSCs. Inhibiting the pathway associated with this transformation may restore GBM sensitivity to radiotherapy. Moreover, metabolic therapy targeting GSCs' activated glutamine metabolism shows promise in reversing their resistance to radiochemotherapy. Regarding chemotherapy, PN GSCs in primary glioblastoma (GBM) demonstrate resistance to multiple agents, while MES GSCs are initially resistant to temozolomide but regain sensitivity to radiotherapy. Combination therapies with temozolomide show potential in inhibiting both PN and MES GSCs. Immunotherapy targeting GSCs has made progress, with

differential gene expression and metabolic phenotypes influencing GSCs' response to immunotherapy. Inhibition of glutamine metabolism-related pathways may offer a strategy to enhance immunotherapy efficacy in GSCs. Although anti-VEGF therapy and tumor-treating fields have limitations in GBM treatment, targeting specific markers such as SOX2 on GSCs and utilizing combined therapeutic options show promise for improving treatment efficacy. Further research on this could elucidate the intricate mechanisms underlying GSCs' response to various treatments, ultimately leading to enhanced therapeutic strategies for GBM.<sup>75</sup>

Wang et al.<sup>76</sup> reported their findings on the gliomagenic path of glioblastoma (GBM) originating from human neural stem/progenitor cells (hNSCs/hNPCs). They addressed the challenges in understanding the early-stage development of GBM due to limited sampling and modeling techniques. They established two hNSC-derived malignant glioma models that closely resemble the histopathology and transcriptional heterogeneity of human GBM. By analyzing whole-exome



**Table 3**  
Phase 2 clinical trials.

Study (Year)	Trial name	Patient criteria	Number of patients	Drug	Primary endpoint	Outcome
Lassman et al <sup>37</sup> (2022)	A Phase II Study of the Efficacy and Safety of Oral Selinexor in Recurrent Glioblastoma	Patients with recurrent glioblastoma and Karnofsky Performance Status $\geq 60$ .	76	Selinexor (an oral selective inhibitor of exportin-1 (XPO1))	To assess intratumoral penetration, safety, and efficacy of selinexor monotherapy for recurrent glioblastoma.	Single-agent selinexor at 80 mg weekly showed promising responses and PFS6, with ongoing trials exploring combination therapies for glioblastoma.
Preusser et al <sup>38</sup> (2022)	Trabectedin for recurrent WHO grade 2 or 3 meningioma: A randomized phase II study of the EORTC Brain Tumor Group (EORTC-1320-BTG)	Adult patients with recurrent WHO grade 2 or 3 meningioma.	90	Local standard of care arm (LOC), $n = 29$ ; trabectedin (alkylating agent) arm, $n = 61$	To assess progression-free survival (PFS).	No benefits in terms of progression-free survival (PFS) and overall survival (OS) compared to the standard treatment (LOC) in patients with non-benign meningioma. Additionally, trabectedin was found to be associated with increased toxicity levels compared to the standard treatment.
Bota et al <sup>39</sup> (2022)	Phase 2 study of AV-GBM-1 (a tumor-initiating cell targeted dendritic cell vaccine) in newly diagnosed Glioblastoma patients: safety and efficacy assessment	Adults (18–70 years old) with a Karnofsky Performance Score (KPS) of 70 or greater, a successful tumor initiating cells (TIC) culture, and sufficient monocytes collected.	60	AV-GBM-1 (Aivita glioblastoma multiforme vaccine - 1: a tumor-initiating cell targeted dendritic cell vaccine)	To assess the manufacturing success rate of the Aivita glioblastoma multiforme vaccine - 1 (AV-GBM-1), investigate associated adverse events (AE), and analyze survival outcomes.	The success rates for TIC production and monocyte collection were 97 %. Median progression-free survival (mPFS) from enrollment was 10.4 months, while median overall survival (mOS) was 16.0 months. The two-year overall survival rate was 27 %. The mPFS exceeded historical benchmarks, but no improvement in mOS was observed.
Fangusaro J et al <sup>40</sup> (2021)	A phase II trial of selumetinib in children with recurrent optic pathway and hypothalamic low-grade glioma without NF1: a Pediatric Brain Tumor Consortium study	Children with recurrent/ progressive optic pathway and hypothalamic gliomas (OPHG).	25	Selumetinib (AZD6244, ARRY-142886) a MEK-1/2 inhibitor.	To evaluate the efficacy of selumetinib.	Selumetinib showed positive responses and prolonged disease stability in children with optic pathway gliomas.
Gilbert et al <sup>41</sup> (2021)	A phase II study of dose-dense temozolomide and lapatinib for recurrent low-grade and anaplastic supratentorial, infratentorial, and spinal cord ependymoma	Patients age 18 or older with histologically proven and progressive ependymoma or anaplastic ependymoma.	50	Temozolomide (TMZ) and lapatinib	To evaluate the effectiveness of this targeted treatment approach for ependymomas with specific molecular features	The treatment was well tolerated and showed promising results. The median progression-free survival (PFS) was 7.8 months, with 55 % and 38 % of patients having PFS rates at 6 and 12 months respectively. This treatment can be considered as a salvage regimen for adult patients with recurrent ependymoma, offering disease control and symptom improvement.
Nayak et al <sup>42</sup> (2021)	Randomized Phase II and Biomarker Study of Pembrolizumab plus Bevacizumab versus Pembrolizumab Alone for Patients with Recurrent Glioblastoma	Patients with recurrent glioblastoma	80	The study included two cohorts: cohort A with 50 patients receiving pembrolizumab in combination with bevacizumab, and cohort B with 30 patients receiving pembrolizumab alone.	To assess 6-month progression-free survival (PFS-6)	Pembrolizumab, with or without bevacizumab, showed limited benefit and tolerability.
Cheung et al <sup>43</sup> (2021)	Survival Impact of Anti-GD2 Antibody Response in a Phase II Ganglioside Vaccine Trial Among Patients With High-Risk Neuroblastoma With Prior Disease Progression	Patients with high risk-neuroblastomas (HR-NB) who achieved remission after salvage therapies.	102	Anti-di/trisialoganglioside monoclonal antibody (Anti-GD2/GD3) vaccine plus oral $\beta$ -glucan.	To assess the kinetics of mounting antibody response to vaccine and its prognostic impact on survival.	Patients with a history of disease progression (PD) episodes and prior anti-GD2 monoclonal antibody (mAb) therapy showed promising outcomes when treated with a GD2/GD3 vaccine plus $\beta$ -glucan. The 5-year progression-free survival (PFS) was 32 % $\pm$

(continued on next page)

Table 3 (continued)

Study (Year)	Trial name	Patient criteria	Number of patients	Drug	Primary endpoint	Outcome
Levy et al <sup>44</sup> (2021)	Temozolomide with irinotecan versus temozolomide, irinotecan plus bevacizumab for recurrent medulloblastoma of childhood: Report of a COG randomized Phase II screening trial	Patients with relapsed/refractory medulloblastoma (MB) or central nervous system primitive neuroendocrine tumor (CNS PNET)	105	Patients were randomly assigned to two treatment groups. Both groups received temozolomide (150 mg/m <sup>2</sup> /day orally, days 1–5) and irinotecan (50 mg/m <sup>2</sup> /day IV, days 1–5); the second group also received bevacizumab (10 mg/kg IV on days 1 and 15).	To compare the overall survival (OS) of patients with the specified regimen.	6 % and overall survival (OS) was 71 % ± 7 %. Serum antibody levels against GD2 and GD3 significantly increased with β-glucan treatment. Higher antibody levels were associated with improved survival. The median overall survival (OS) was reported to be 13 months in the standard arm and 19 months with the addition of bevacizumab. The addition of bevacizumab to TMZ/irinotecan reduced the risk of death in children with recurrent MB and was well tolerated.
Brown et al <sup>45</sup> (2021)	A prospective phase II randomized trial of proton radiotherapy vs intensity-modulated radiotherapy for patients with newly diagnosed glioblastoma	Patients with newly diagnosed glioblastoma.	90	Proton radiotherapy (PT) or intensity-modulated radiotherapy (IMRT)	The primary endpoint was time to cognitive failure. Secondary endpoints included overall survival (OS), intracranial progression-free survival (PFS), toxicity, and patient-reported outcomes (PROs).	The median follow-up was 48.7 months. Time to cognitive failure did not differ significantly between treatment arms. Proton therapy (PT) was associated with lower fatigue rates but showed no significant differences in other patient-reported outcomes (PROs) at 6 months. There were no differences in progression-free survival (PFS) or overall survival (OS) between treatment arms.
Peereboom et al <sup>46</sup> (2021)	A Phase II and Pharmacodynamic Trial of RO4929097 for Patients With Recurrent/Progressive Glioblastoma	Patients With Recurrent/Progressive Glioblastoma	47	RO4929097 (an oral gamma secretase inhibitor).	To determine the 6-month progression-free survival rate (PFS6) in patients with progressive glioblastoma (GBM) and to achieve a 50 % reduction in the formation of neurospheres in fresh tissue obtained from patients treated with RO4929097 (an oral gamma secretase inhibitor).	7 of the patients underwent tumor resection. Only 4 % achieved a 6-month progression-free survival (PFS6), and neurosphere formation inhibition was observed in just 1 out of the 7 patient samples.
Brastianos et al <sup>47</sup> (2021)	Phase II study of ipilimumab and nivolumab in leptomeningeal carcinomatosis	Patients with leptomeningeal disease.	18	Combination of ipilimumab (cytotoxic T lymphocyte antigen-4 inhibitor) and nivolumab (programmed death-1 inhibitor).	To evaluate the overall survival at 3 months (OS3) as the primary outcome. Secondary endpoints include assessing toxicity, cumulative time-to-progression at 3 months, and progression-free survival.	The study achieved the primary endpoint of 3-month overall survival (OS3), with 8 out of 18 patients (OS3 0.44; 90 % CI: 0.24 to 0.66) alive at that time. Combined ipilimumab and nivolumab showed promising activity in patients with leptomeningeal disease (LMD) and an acceptable safety profile.
Wright et al <sup>48</sup> (2021)	A POETIC Phase II study of continuous oral everolimus in recurrent, radiographically progressive pediatric low-grade glioma	Patients with low-grade glioma	23	Everolimus (mTOR inhibitor)	To assess the effectiveness, pharmacokinetics (PK), and pharmacodynamics of everolimus as a stand-alone treatment in pediatric patients with radiographically progressive low-grade glioma (LGG).	The 2-, 3-, and 5-year progression-free survival rates were 39 %, 26 %, and 26 % respectively. Overall survival rates were all 93 %. Everolimus demonstrated tolerability with manageable toxicities.
Tabouret et al <sup>49</sup> (2021)	TEMOBIC: Phase II Trial of Neoadjuvant Chemotherapy for Unresectable Anaplastic Gliomas: An ANOCEF Study	Adult patients diagnosed with unresectable anaplastic oligodendroglioma or	55	Combination of carmustine (BCNU: nitrosourea) and	To assess progression-free survival and response to therapy.	IDH mutation correlated with improved PFS and OS, while MGMT promoter methylation associated

(continued on next page)

Table 3 (continued)

Study (Year)	Trial name	Patient criteria	Number of patients	Drug	Primary endpoint	Outcome
		mixed gliomas, as per the World Health Organization (WHO) 2007 classification.		temozolomide prior to undergoing radiotherapy.		with better OS. BCNU and temozolomide combination demonstrated efficacy but had limited use due to toxicity.
Sim et al <sup>50</sup> (2021)	A randomized phase II trial of veliparib, radiotherapy, and temozolomide in patients with unmethylated MGMT glioblastoma: the VERTU study	Patients with unmethylated MGMT glioblastoma	125	The experimental arm received veliparib and radiotherapy, followed by adjuvant veliparib and temozolomide, while the standard arm received concurrent temozolomide and radiotherapy, followed by adjuvant temozolomide.	To extend the progression-free survival rate at six months (PFS-6m) in the experimental arm.	The veliparib-containing regimen was well tolerated, but there was insufficient evidence of clinical benefit in this specific population.
Dufour et al <sup>51</sup> (2021)	Prognostic relevance of clinical and molecular risk factors in children with high-risk medulloblastoma treated in the phase II trial PNET HR+5	Patients aged 5–19 years with newly diagnosed high-risk medulloblastoma	51	Etoposide and carboplatin followed by two courses of high-dose thiotepa (alkylating agent) with hematological stem cell support. Risk-adapted craniospinal radiation therapy was given within 45 days after the stem cell rescue, followed by temozolomide 1–3 months later.	To evaluate the 3-year progression-free survival (PFS) and identify the molecular characteristics linked to PFS in children and adolescents aged 5–19 years who were diagnosed with high-risk medulloblastoma.	The 3-year and 5-year progression-free survival rates were 78 % and 76 % respectively, and the overall survival rates were 84 % and 76 % respectively. Medulloblastoma subtype and molecular subgroup were significant prognostic factors.
Goldman et al <sup>52</sup> (2020)	Phase II study of peginterferon alpha-2b for patients with unresectable or recurrent craniopharyngiomas: a Pediatric Brain Tumor Consortium report	Patients with unresectable or recurrent craniopharyngiomas	19	Patients were enrolled in one of 2 strata: patients previously treated with surgery alone (stratum 1) or who received radiation (stratum 2). Pegylated interferon alpha-2b was then given to both strata.	To determine tolerability and progression-free survival	The therapy was well tolerated without severe toxicities. The use of pegylated interferon alpha-2b as a treatment for recurrent craniopharyngiomas in children and young adults was well tolerated. While objective responses were limited, the encouraging results in progression-free survival suggest the need for further studies.
Puduvalli et al <sup>53</sup> (2020)	A Bayesian adaptive randomized phase II multicenter trial of bevacizumab with or without vorinostat in adults with recurrent glioblastoma	Adults (aged 18 years and above) diagnosed with recurrent glioblastoma multiforme (GBM) after previous radiation therapy. Patients were required to have adequate organ function, a Karnofsky Performance Score (KPS) of 60 or higher, and no prior treatment with bevacizumab or histone deacetylase (HDAC) inhibitors.	90	Bevacizumab + Vorinostat (histone deacetylase inhibitor) versus Bevacizumab alone	Progression-free survival (PFS)	There was no significant difference observed in median progression-free survival (PFS) (3.7 months vs 3.9 months, $p = 0.94$ ) and median overall survival (OS) (7.8 months vs 9.3 months, $p = 0.64$ ) between the two treatment arms.
Fisher et al <sup>54</sup> (2020)	Phase 2 Study of a Temozolomide-Based Chemoradiation Therapy Regimen for High-Risk, Low-Grade Gliomas: Long-Term Results of Radiation Therapy Oncology Group 0424	Patients with low-grade gliomas, who present with three or more risk factors, including but not limited to the following: age equal to or exceeding 40 years, presence of astrocytoma, occurrence of a bihemispheric tumor, tumor size equal to or exceeding 6 cm, or preoperative neurologic function status greater than one, face distinct challenges in their medical journey.	136	Radiation alongside the administration of TMZ.	Overall survival (OS) at 3 years	The 5-year and 10-year OS rates were 60.9 % and 34.6 %, respectively, while the 5-year and 10-year progression-free survival (PFS) rates were 46.8 % and 25.5 %, respectively. Long-term results confirmed the efficacy of the RT-TMZ regimen, outperforming radiation-only control groups. Acceptable levels of toxicity were observed.

(continued on next page)

Table 3 (continued)

Study (Year)	Trial name	Patient criteria	Number of patients	Drug	Primary endpoint	Outcome
Van Den Bent et al <sup>55</sup> (2020)	INTELLANCE 2/EORTC 1410 randomized phase II study of Depatux-M alone and with temozolomide vs temozolomide or lomustine in recurrent EGFR amplified glioblastoma	Patients with centrally confirmed EGFR amplified glioblastoma at first recurrence after chemoradiation with temozolomide.	260	Depatuxizumab mafodotin (Depatux-M): an antibody-drug conjugate that targets tumor cells, administered with temozolomide as part of the treatment regimen.	Overall survival	Combining Depatux-M with temozolomide shows promise for treating recurrent glioblastoma with amplified EGFR, especially in patients who relapse after initial treatment. The 12-month survival rate was approximately 39.7%, with a 24-month survival rate of around 19.8%.
Balana et al <sup>56</sup> (2020)	A phase II randomized, multicenter, open-label trial of continuing adjuvant temozolomide beyond 6 cycles in patients with glioblastoma (GEINO 14-01)	Patients with glioblastoma who had not progressed after 6 cycles of temozolomide	159	Patients were randomly assigned to either discontinue temozolomide (control arm) or continue with the same doses they were receiving in cycle 6 for a maximum of 12 cycles (experimental arm).	Differences in 6-month progression-free survival (PFS)	Continuing temozolomide after 6 adjuvant cycles did not show any differences in 6-month progression-free survival (PFS), overall survival (OS), or PFS compared to stopping temozolomide.
Cloughesy et al <sup>57</sup> (2020)	A randomized controlled phase III study of VB-111 combined with bevacizumab vs bevacizumab monotherapy in patients with recurrent glioblastoma (GLOBE)	Patients with recurrent glioblastoma (rGBM)	256	Ofranergene obadenovec (VB-111), which is an anticancer viral therapy, along with bevacizumab or to receive bevacizumab alone (control arm).	Overall survival (OS)	The combination of Ofranergene obadenovec (VB-111) and bevacizumab did not significantly improve overall survival (OS) compared to bevacizumab alone, with median OS of 6.8 months in the combination arm and 7.9 months in the control arm.
Lafay-Cousin et al <sup>58</sup> (2020)	Phase II Study of Nonmetastatic Desmoplastic Medulloblastoma in Children Younger Than 4 Years of Age: A Report of the Children's Oncology Group (ACNS1221)	Children younger than 4 years of age with either nodular-desmoplastic or extensive-nodularity medullaoblastoma	25	The modified HIT SKK 2000 regimen described elsewhere <sup>59,60</sup> was used for their treatment, excluding intraventricular methotrexate.	To achieve a comparable outcome, specifically a 2-year progression-free survival (PFS) rate of at least 90%, while minimizing treatment-related neurotoxicity.	The two-year progression-free survival (PFS) rate was 52% (95% CI, 32.4%–71.6%), and the overall survival rate was 92% (95% CI, 80.8%–100.0%) in the study. However, the modified regimen of conventional systemic chemotherapy, which excluded serial intraventricular methotrexate injection, did not meet the targeted 2-year PFS rate of 90%.
Wen et al <sup>61</sup> (2019)	A Randomized Double-Blind Placebo-Controlled Phase II Trial of Dendritic Cell Vaccine ICT-107 in Newly Diagnosed Patients with Glioblastoma	Patients with GBM and HLA-A1+ and/or -A2+ genes and residual tumor $\leq 1 \text{ cm}^3$ .	124	Patients in the study were assigned to receive either ICT-107, which involved autologous dendritic cells pulsed with six synthetic peptide epitopes targeting GBM tumor/stem cell-associated antigens, or a control treatment with unpulsed dendritic cells followed by adjuvant temozolomide for 12 months.	Median overall survival	No significant difference in overall survival (OS) compared to control. However, ICT-107 showed improved progression-free survival (PFS) by 2.2 months ( $P = 0.011$ ) without compromising quality of life (QoL). HLA-A2 subgroup patients demonstrated increased clinical and immunological activity.
Lee et al <sup>62</sup> (2019)	Phase II trial of ponatinib in patients with bevacizumab-refractory glioblastoma	Adult patients with bevacizumab-refractory GBM and variants, Karnofsky performance score (KPS) $\geq 60$ , measurable disease, and normal organ and marrow function.	15	Ponatinib (protein kinase inhibitor)	3-month progression-free survival.	No positive responses to treatment were observed. The drug ponatinib showed minimal activity in GBM patients who were refractory to bevacizumab.
Wen et al <sup>63</sup> (2019)	Buparlisib in Patients With Recurrent Glioblastoma Harboring Phosphatidylinositol 3-Kinase Pathway Activation:	Patients With Recurrent Glioblastoma	65	Buparlisib (pan-PI3K inhibitor) for a period of 7–13 days prior to the surgery.	PI3K pathway inhibition in tumor tissue and buparlisib pharmacokinetics in cohort 1 and 6-month	Buparlisib showed limited efficacy as a single-agent treatment for recurrent glioblastoma, with only 8% achieving a 6-month

(continued on next page)

Table 3 (continued)

Study (Year)	Trial name	Patient criteria	Number of patients	Drug	Primary endpoint	Outcome
Kaley et al <sup>64</sup> (2019)	An Open-Label, Multicenter, Multi-Arm, Phase II Trial Phase II trial of an AKT inhibitor (perifosine) for recurrent glioblastoma	Adults with recurrent GBM with a minimum Karnofsky Performance Status of 50 following radiotherapy but without other restrictions on the number or types of prior therapy.	30	Perifosine (PRF) - oral alkylphospholipid which has anti-cancer effects.	progression-free survival (PFS6) in cohort 2. 6-month progression free survival (PFS6) rate	progression-free survival rate. While PRF was tolerable, it did not prove effective when used alone for GBM.
Blakeley et al <sup>65</sup> (2019)	Phase II Study of Iniparib with Concurrent Chemoradiation in Patients with Newly Diagnosed Glioblastoma	Adult patients with Newly Diagnosed Glioblastoma	81	Iniparib (induces cell death through intracellular conversion to nitro radical ions)	To achieve an improved mOS compared to a historical control	Iniparib, when used in combination with radiotherapy and temozolomide, was well tolerated in newly diagnosed GBM patients at doses up to 17.2 mg/kg weekly.
Brandes et al <sup>66</sup> (2019)	A Randomized Phase II Trial (TAMIGA) Evaluating the Efficacy and Safety of Continuous Bevacizumab Through Multiple Lines of Treatment for Recurrent Glioblastoma	Patients with newly diagnosed glioblastoma	296	Patients with glioblastoma received surgery, radiotherapy, temozolomide, and bevacizumab (BEV). Upon progression (PD1), they were assigned to lomustine (CCNU) plus BEV or placebo until further progression (PD2), then continued with BEV or placebo and chemotherapy.	To determine survival from randomization.	There were no significant differences in median progression-free survival (PFS2 and PFS3) or time to deterioration in health-related quality of life between the two groups. The study did not find evidence supporting the continued use of BEV in recurrent glioblastoma.

sequencing, bulk, and single-cell RNA sequencing data over time, they reconstructed the trajectories of gliomagenesis and identified a persistent NSC-like population throughout tumor progression. Through lineage tracing and trajectory analyses, they demonstrated that tumor progression primarily occurs through transcriptional reprogramming and fate-switches in NSC-like cells, leading to malignant heterogeneity and tumor phenotype transitions. Their study also uncovered stage-specific oncogenic cascades and validated complement component 1, q subcomponent-like 1 (C1QL1) as a new factor promoting glioma development. Notably, the neurogenic-to-gliogenic switch in NSC-like cells marked an early stage characterized by a burst of oncogenic alterations, and transient activator protein-1 (AP-1) inhibition which proved effective in inhibiting gliomagenesis. These findings shed light on the molecular dynamics and fate choices underlying de novo gliomagenesis from hNSCs, offering insights for potential early-stage treatment and diagnosis of GBM.<sup>76</sup> GBM has also been targeted using viruses. Francipane et al.<sup>77</sup> discussed the susceptibility of neural stem cells (NSCs) and neural progenitor cells (NPCs) to Zika virus (ZIKV) infection. They highlighted the decreased viability and growth of induced pluripotent stem cell (iPSC)-derived NPCs when exposed to ZIKV, accompanied by the down-regulation of pathways associated with cell cycle. The authors also demonstrated the detrimental effects of ZIKV on neurogenesis, revealing reduced viability and growth of iPSC-derived NSCs cultivated as neurospheres and organoids. They also emphasized the preferential targeting of undifferentiated cells by ZIKV, including NPCs, radial glial cells, and astrocytes. While the receptor tyrosine kinase AXL (which derives its name from a Greek word *anexelekto*, that means uncontrolled) was identified as a potential entry factor for ZIKV, other interactions are likely involved. Notably, ZIKV exhibited selective infection and destruction of glioblastoma stem cells (GSCs), suggesting its potential as an oncolytic virus for treating glioblastoma (GBM). In mouse models, treatment with ZIKV led to improved survival, decreased tumor size, and alleviation of neurological symptoms. Moreover, ZIKV induced alterations in the GBM microenvironment, facilitating the recruitment of immune cells and enhancing tumor clearance. These

findings highlight the therapeutic prospects of ZIKV for GBM treatment, underscoring the need for further investigation.<sup>77</sup> Brockman et al.<sup>78</sup> reported that stem-like cells in gliomas, particularly in the ventricular-subventricular zone of the brain (V-SVZ) can originate from the embryonic brain or adult V-SVZ and efficiently form tumors resembling human brain tumors. While some mutations found in V-SVZ cells support their role as the origin of certain brain tumors, mature astrocytes can also form tumors, though less effectively. The existence of stem-like cells within tumors, resistant to standard treatments, has been proposed based on the cancer stem cell theory. Various proteins and markers have been used to identify and sort these cells in brain tumors. Heterogeneity and plasticity within the malignant cell population further complicate the study of stem-like subsets in tumor initiation and growth. Recent findings suggest the presence of stem-like cells resembling embryonic progenitors, explaining the invasive behavior of glioblastomas. These cells may exploit the V-SVZ environment, rich in factors promoting self-renewal and immune suppression.<sup>78</sup> As it has been discussed previously, a multitude of therapies have been used to target glioblastoma. In their study, Okada et al.<sup>79</sup> found that human glioblastoma-derived stem-like cells (GSCs) were highly sensitive to folate antagonists like methotrexate (MTX) and pemetrexed (PEM), leading to significant cell death. In contrast, normal cells and differentiated GSCs survived in the presence of these antagonists. The concentration range of 0.1–0.2  $\mu\text{M}$  for folate antagonists reduced GSC viability by approximately 50%. This concentration range corresponds to the clinically relevant levels of MTX used in rheumatoid arthritis and malignant lymphoma treatments. The newly developed folate antagonist PEM also exhibited efficacy against GSCs at low concentrations. However, when MTX was administered alone in an in vivo transplantation assay, there was no decrease in the number of GSCs within the tumor. Possible explanations include the insufficient dose of MTX or the upregulation of dihydrofolate reductase (DHFR) expression in tumor cells, leading to MTX resistance. It was also suggested that non-GSCs might convert to GSCs after the elimination of GSCs by MTX. To address this, the combination of MTX with the differentiation inducer CEP1347 was

**Table 4**  
Phase 3 clinical trials.

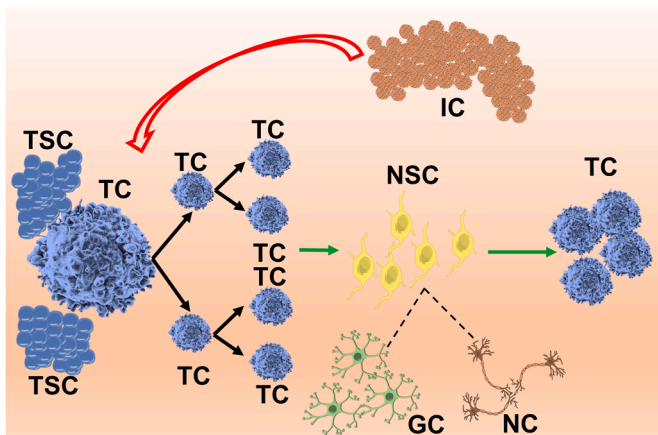
Study (Year)	Trial name	Patient criteria	Number of patients	Drug	Primary endpoint	Outcome
Liau et al <sup>67</sup> (2023)	Association of Autologous Tumor Lysate-Loaded Dendritic Cell Vaccination With Extension of Survival Among Patients With Newly Diagnosed and Recurrent Glioblastoma: A Phase 3 Prospective Externally Controlled Cohort Trial	Patients with newly diagnosed glioblastoma (nGBM) and recurrent glioblastoma (rGBM)	331	Newly diagnosed glioblastoma (nGBM) patients received a personalized vaccine called autologous tumor lysate-loaded dendritic cell vaccine (DCVax-L) in addition to temozolomide in the experimental group. Newly diagnosed GBM patients in the control group received temozolomide and a placebo, while recurrent GBM patients in the control group received approved therapies for recurrent GBM.	To compare overall survival (OS) in patients with newly diagnosed glioblastoma (nGBM),	The addition of DCVax-L resulted in improved survival rates at different time points for both nGBM and rGBM patients. Furthermore, patients with methylated MGMT and nGBM showed even better survival outcomes with DCVax-L.
Omuro et al <sup>68</sup> (2023)	Radiotherapy combined with nivolumab or temozolomide for newly diagnosed glioblastoma with unmethylated MGMT promoter: An international randomized phase III trial	Adult patients with newly diagnosed glioblastoma with unmethylated MGMT promoter	560	Combination of nivolumab (NIVO)- an anti-PD1 immune checkpoint inhibitor with radiotherapy (RT) to the combination of temozolomide (TMZ) with radiotherapy (RT).	To improve the overall survival	The study did not meet the primary endpoint of improving overall survival (OS), as TMZ + RT demonstrated a longer median OS compared to NIVO + RT.
Lassman et al <sup>69</sup> (2023)	Depatuxizumab mafodotin in EGFR-amplified newly diagnosed glioblastoma: A phase III randomized clinical trial	Patients with newly diagnosed EGFR-amplified glioblastoma	639	Patients were randomized in a 1:1 ratio to receive a combination of radiotherapy, temozolomide, and depatux-m or placebo	To assess the overall survival	Depatux-m had a similar median OS of 18.9 months compared to 18.7 months for placebo.
Lim et al <sup>70</sup> (2022)	Phase III trial of chemoradiotherapy with temozolomide plus nivolumab or placebo for newly diagnosed glioblastoma with methylated MGMT promoter	Patients with newly diagnosed glioblastoma with methylated MGMT promoter	716	Patients were randomly assigned to two treatment groups. The first group received NIVO in combination with radiation therapy (RT) and temozolomide (TMZ) according to a specific dosing schedule. The second group received a placebo (PBO) along with RT and TMZ, following the same dosing regimen.	To evaluate progression-free survival (PFS) and overall survival (OS) in two specific groups: patients without baseline corticosteroids and all randomized patients.	The median progression-free survival (PFS) was similar between the two groups.
Reardon et al <sup>71</sup> (2020)	Effect of Nivolumab vs Bevacizumab in Patients With Recurrent Glioblastoma: The CheckMate 143 Phase 3 Randomized Clinical Trial	Patients with glioblastoma at first recurrence following standard radiation and temozolomide therapy	369	The patients in the study were divided into two groups through randomization, with a 1:1 ratio. One group received nivolumab at a dosage of 3 mg/kg, while the other group received bevacizumab at a dosage of 10 mg/kg. The treatments were administered every two weeks until confirmed disease progression, unacceptable toxic effects, or death occurred.	To assess the overall survival (OS)	Although the primary goal of the trial was not achieved, the mOS was comparable between nivolumab and bevacizumab in the overall patient population with recurrent glioblastoma. The safety profile of nivolumab in glioblastoma patients was consistent with its use in other types of tumors.
Narita et al <sup>72</sup> (2019)	A randomized, double-blind, phase III trial of personalized peptide vaccination for recurrent glioblastoma	Adult patients with recurrent glioblastoma	88	Personalized peptide vaccination	To assess the overall survival	Biomarkers associated with favorable OS in PPV patients included lower levels of immunosuppressive monocytes and higher levels of activated T cells, along with intermediate levels of various cytokines and haptoglobin. However, the phase III trial did not meet its primary or secondary endpoints.

(continued on next page)



Table 4 (continued)

Study (Year)	Trial name	Patient criteria	Number of patients	Drug	Primary endpoint	Outcome
Guo et al. <sup>73</sup> (2023)	Adjuvant Temozolomide Chemotherapy With or Without Interferon Alfa Among Patients With Newly Diagnosed High-grade Gliomas: A Randomized Clinical Trial	Patients aged 18 to 75 with newly diagnosed and histologically confirmed high grade gliomas (HGGs) and had received no prior chemotherapy, radiotherapy, or immunotherapy for their HGG.	199	All patients in the study underwent standard radiotherapy along with temozolomide treatment. Following a 4-week interval, patients in the temozolomide with interferon alfa group received standard temozolomide along with interferon alfa on a 28-day cycle. Patients in the temozolomide group received only standard temozolomide treatment.	To assess 2-year overall survival (OS).	Patients who received temozolomide plus interferon alfa demonstrated a significantly longer median overall survival (OS) compared to those in the standard treatment group.



**Fig. 2.** Complex interplay between tumor cells, neural progenitor cells, and the tumor microenvironment. This figure shows the tumor microenvironment (faded gradient background) as a complex system of cells to promote tumor growth and metastasis. Tumor cells (TC), neural stem cells (NSC), and immune cells (IC) are all important components of the tumor microenvironment. Tumor cells are the main driver of tumor growth. They can divide rapidly and invade surrounding tissue. Neural progenitor cells are undifferentiated cells that have the potential (dotted line) to develop into a variety of cell types, including neural cells (NC) and glial cells (GC). Neural stem cells can be found in the tumor microenvironment, and they can be activated (green arrow) by tumor cells to differentiate into tumor cells (green arrow). Immune cells are also found in the tumor microenvironment. They can help to fight tumors (red arrow), but they can also be suppressed by tumor cells.

investigated and found to extend the survival time compared to treatment with CEP1347 alone. The study highlighted the potential of combining differentiation inducers with GSC-killing drugs as a promising treatment strategy for glioblastomas and other human cancers. Folate metabolism was identified as a crucial pathway for GSC viability, and further exploration of related molecules may lead to more effective and safer treatments. The study also revealed that the reduced folate carrier protein-1 (RFC-1) was more highly expressed in GSCs compared to differentiated GSCs, indicating their vulnerability to folate antagonists. Overall, the findings emphasized the importance of targeting GSCs in cancer treatment and provided insights into potential therapeutic approaches.<sup>79</sup> According to Bonnay et al.,<sup>80</sup> tumor cells possess the ability to divide indefinitely and disregard signals that control organismal proliferation. This distinguishing characteristic involves various cellular processes, including telomere stabilization, dysregulated proliferation control signaling pathways, inactivated cell cycle checkpoints, and evasion of apoptosis. While metabolic reprogramming is typically

considered an adaptation to the tumor environment, Bonnay et al.<sup>80</sup> revealed that metabolic changes, specifically a shift towards oxidative phosphorylation (OxPhos) and increased nicotinamide adenine dinucleotide (NAD<sup>+</sup>) biogenesis driven by glutamine incorporation, are essential for immortalizing stem cells during tumor initiation in *Drosophila* brain tumors. Additionally, they found that extensive fusion of mitochondria induces the transition of tumor-initiating cells (TICs) into tumor cells by altering OxPhos. These observations suggest that immortalization is an irreversible event requiring abrupt metabolic transformations, similar to other fate changes. The study by Bonnay et al.<sup>80</sup> also highlighted the significance of OxPhos in deregulating cell proliferation programs in *Drosophila* NSC-derived tumors, a feature conserved across various mammalian tumor types.<sup>80</sup> In the recent era, 3D bioprinting systems have been utilized in creation of glioblastoma-like tumor environments to better study the tumor microenvironment. Tang et al.<sup>81</sup> aimed to improve the modeling of glioblastoma. They utilized a 3D bioprinting system based on digital light processing (DLP) to create a glioblastoma model that accurately reproduced the complex tumor microenvironment. Unlike previous models that focused on specific aspects or used non-human cells, this human cell-based 3D model included normal brain tissue, immune components, stromal components, and crucial cues from the extracellular matrix. The model provided a physiologically relevant platform to investigate hypoxic signaling, growth factor signaling, immune interactions, and the influence of stromal elements on glioblastoma biology. It also demonstrated potential applications in studying immunotherapy efficacy, drug discovery, and identifying novel functional dependencies. Overall, this controlled, reproducible, and scalable 3D bioprinted glioblastoma model holds promise for advancing our understanding of the disease and facilitating the development of new treatment strategies.<sup>81</sup> Moving the discussion from glioblastoma and to other tumors, Li et al.<sup>82</sup> conducted a study on the use of Gamma-knife radiosurgery (GKRS) as an alternative treatment for prolactinomas in Chinese patients intolerant or resistant to medication. They observed an endocrine remission rate of 41.7% and a median remission time of 71.1 months. They did not find a significant association between prolactin normalization and prognostic factors, unlike previous studies. The majority of their patients were treated with bromocriptine due to unavailability of cabergoline in mainland China. They used a relatively low margin dose of 15 Gy to minimize the risk of new hypopituitarism. GKRS effectively controlled tumor growth in all patients, and visual dysfunction did not worsen after treatment. New-onset hypopituitarism occurred in 16.7% of patients, predominantly gonadotrophin deficiency.<sup>82</sup>

#### 4.2. Phase 0 or 1 clinical trials

In Phase 0 and Phase 1 clinical trials, several experimental treatments for brain tumors showed promising outcomes. DS-1001 demonstrated a notable objective response rate of 17.1 % for enhancing tumors and 33.3 % for non-enhancing tumors. Moreover, it was well tolerated, exhibited good brain distribution, and led to reduced levels of the tumor oncometabolite D-2-hydroxyglutarate (D-2-HG). These findings highlight the potential of DS-1001 as a therapeutic option.<sup>8</sup> Similarly, WP1066, targeting p-STAT3 in GBM patients, was found to be safe at a dosage of 8 mg/kg. Although disease progression occurred in all patients, the median survival rate of 25 months suggests potential benefits. Mild nausea and diarrhea were the common side effects observed during treatment.<sup>10</sup> Limitations and challenges for both DS-1001 and WP1066 were that even if they were used, they didn't completely halt the disease and the disease still progressed. In terms of brain tumor tissue penetration, Ceritinib displayed strong binding to both human plasma proteins and brain tumor tissue. However, it did not result in significant changes in pharmacodynamic biomarkers compared to matched archival tumor tissue. While the drug showed good tissue penetration, its impact on the target biomarkers may be limited, necessitating further investigations.<sup>11</sup> The main limitation and challenge of Ceritinib was due to its high bound state and insufficient concentration in the tumor site. The feasibility and safety of an engineered oncolytic adenovirus delivered by neural stem cells (NSC-CRAD-S-pk7) was established, as evidenced by strong immune responses and examination of tissues. This suggests that NSC-CRAD-S-pk7 holds promise as a potential therapeutic approach for brain tumors.<sup>12</sup> Although not in isolation, but if multiple intracranial injections with other immune checkpoint inhibitors is used in the future, it may prove more fruitful. In the case of an Vorasidenib, a novel drug, encouraging results were observed in patients with non-enhancing gliomas. The drug demonstrated an objective response rate of 18 % and a longer median progression-free survival compared to patients with enhancing gliomas. Additionally, tumor shrinkage was observed in multiple patients with nonenhancing gliomas, indicating the potential efficacy of the drug in treating this specific subgroup of tumors.<sup>13</sup> In terms of targeted therapies, ribociclib and everolimus showed good tolerability and comparable pharmacokinetic characteristics to those seen in adults. Furthermore, ribociclib demonstrated the potential to reach therapeutic levels in cerebrospinal fluid and tumor tissue. However, the variability reported among patients emphasizes the need for personalized dosing strategies to maximize efficacy.<sup>15</sup> On the other hand, palbociclib, despite being tolerated up to a maximum tolerated dose (MTD) of 75 mg/m<sup>2</sup>, did not elicit objective responses in patients. Myelosuppression, including grade 3/4 neutropenia and leukopenia, was the main toxicity observed. These findings suggest that while palbociclib may be tolerated, its effectiveness in treating brain tumors may be limited.<sup>16</sup> Afatinib, unfortunately, was discontinued by all patients primarily due to disease progression and adverse events. Diarrhea and rash were the most frequently reported adverse events, and the maximum tolerated dose was determined as 30 mg with temozolomide (TMZ) and radiotherapy (RT), and 40 mg with RT alone. These results indicate the challenges associated with afatinib treatment and the need for further exploration of alternative therapeutic options.<sup>17</sup> In another study, the combination of zotiraciclib with TMZ was deemed safe in patients with recurrent high-grade astrocytomas, despite the potential for transient and profound neutropenia. The feasibility of personalized dosing based on drug metabolism polymorphisms was also suggested.<sup>18</sup> Asunercept, in terms of both tolerability and efficacy, showed promising results with a 57.1 % progression-free survival at 12 months. This outcome indicates the potential benefits of asunercept as a therapeutic option for brain tumors.<sup>19</sup> Temsirolimus and perifosine were found to be tolerable in heavily pretreated adults with recurrent malignant gliomas when administered at doses of 115 mg and 100 mg weekly and daily, respectively. These findings suggest that these drugs may hold promise as treatment options for this patient population.<sup>20</sup> In pediatric patients,

higher doses of lenalidomide (116 mg/m<sup>2</sup>/day) were found to be tolerable during radiation therapy. This is significant as higher doses of lenalidomide have shown to be more effective in treating malignant gliomas, potentially offering improved outcomes for children.<sup>21</sup> The addition of dasatinib did not result in a significant difference in outcomes, suggesting that its use may not offer additional benefits in the context of the specific treatment being evaluated.<sup>23</sup> Depatux-m, a therapeutic option, was well tolerated with common adverse events including blurred vision, fatigue, and photophobia. The objective response rate was 14.3 %, the 6-month progression-free survival rate was 25.2 %, and the 6-month overall survival rate was 69.1 %. These findings provide insights into the efficacy of depatux-m as a treatment for brain tumors.<sup>24</sup> In conclusion, the outcomes from Phase 0 and Phase 1 clinical trials provide valuable insights into the safety, tolerability, and efficacy of various experimental treatments for brain tumors. These findings inform the potential of these treatments as therapeutic options and guide further investigations and larger-scale trials to validate their clinical benefits.

#### 4.3. Phase 1b or 2 clinical trials

Several Phase 1b and Phase 2 clinical trials have provided important insights into the safety, tolerability, and efficacy of various treatments for brain tumors. G47Δ demonstrated good tolerability, with common side effects such as fever, headache, and vomiting. The median overall survival was 7.3 months, and the 1-year survival rate was 38.5 %. Notably, some patients exhibited long-term survival, with three individuals surviving beyond 46 months. Encouragingly, there were instances of complete and partial responses at the 2-year mark.<sup>26</sup> Chloroquine showed promising results, with favorable toxicity and a median overall survival of 16 months. The 2-year survival rate was 38 %. Adverse events were mostly mild to moderate, and the maximum tolerated dose was determined as 200 mg daily. These findings warrant further clinical studies to explore the potential of chloroquine for glioblastoma treatment.<sup>28</sup> Autologous adoptive immune-cell therapy showed promise as an effective treatment option for recurrent glioblastoma patients with high immune responses in their tumor micro-environments.<sup>31</sup> The addition of vismodegib to TMZ did not result in increased toxicity but did not improve the 6-month progression-free survival in patients with SHH recurrent/refractory medulloblastoma.<sup>32</sup> VB-111 demonstrated good tolerability, with a temporary mild-moderate fever as the most common side effect. The primed combination group showed significantly longer median overall survival and median progression-free survival compared to other groups. Notably, radiographic responders to VB-111 exhibited distinct areas of necrosis in the initial disease areas.<sup>34</sup> In terms of Capmatinib, the determination of the recommended phase II dose was hindered by drug interactions. While monotherapy had limited activity, the combination of Capmatinib and buparlisib did not show significant activity in PTEN-deficient glioblastoma patients. Stricter molecular selection strategies are warranted.<sup>35</sup> These Phase 1b and Phase 2 clinical trial outcomes provide valuable insights into the safety, tolerability, and efficacy of various experimental treatments for brain tumors. They inform the potential of these treatments as therapeutic options and highlight the need for further investigation and larger-scale trials to validate their clinical benefits.

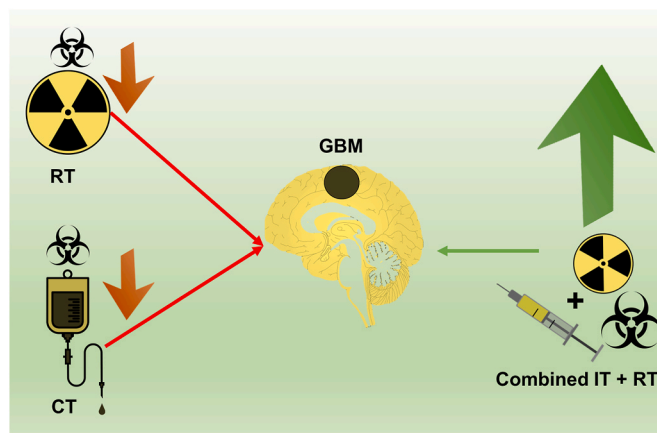
#### 4.4. Phase 2 clinical trials

In Phase 2 clinical trials, the concentrations of selinexor in surgically removed tumors varied between 39.7 and 291 nmol/L. The rates of progression-free survival at 6 months (PFS6) were 10 %, 7.7 %, and 17 % in Arms B, C, and D respectively, with confidence intervals ranging from 2.79 % to 50.6 %. Approximately 28 % of patients experienced a reduction in tumor size, and the overall response rate, as per the response assessment in neuro-oncology (RANO) criteria, was 8.8 %.

Notably, Arm D showed complete and partial responses. Serious adverse events were observed in 34 % of patients, including one fatality. The most common manageable side effects included fatigue, nausea, decreased appetite, and thrombocytopenia. Molecular studies identified a predictive signature for response, with an area under the curve (AUC) of 0.88. Single-agent selinexor at a weekly dose of 80 mg demonstrated promising responses and 6-month progression-free survival (PFS6). Ongoing trials are investigating combination therapies for glioblastoma.<sup>37</sup> In the context of non-benign meningioma, the use of trabectedin (an alkylating agent) did not yield any advantages in terms of progression-free survival (PFS) or overall survival (OS) when compared to the standard treatment. Moreover, trabectedin was associated with increased toxicity levels compared to the standard treatment.<sup>38</sup> A high success rate of 97 % was achieved in the production of tumor-infiltrating cells and the collection of monocytes. Common adverse events included local injection site reactions (16 %) and flu-like symptoms (10 %). Treatment-related adverse events encompassed seizures (33 %), headache (37 %), and focal neurologic symptoms (28 %). One patient discontinued treatment due to seizures. The median progression-free survival (mPFS) from enrollment was 10.4 months, and the median overall survival (mOS) was 16.0 months. Notably, the two-year overall survival rate reached 27 %. The manufacturing and tolerability of AV-GBM-1 were satisfactory, although adverse events impacting the central nervous system were notable. While the mPFS exceeded historical benchmarks, there was no improvement in mOS.<sup>39</sup> Selumetinib exhibited positive responses and prolonged disease stability in children with optic pathway gliomas. Treatment resulted in a partial response in 24 % of patients, stable disease in 56 %, and disease progression in 20 %. The median number of treatment courses was 26, and the two-year progression-free survival rate was  $78 \pm 8.5$  %. Visual acuity improved in 21 % of patients and remained stable in 68 %. The tolerability of selumetinib was generally mild to moderate, with no significant side effects.<sup>40</sup> For adult patients with recurrent ependymoma, the treatment regimen showed promising results and was well tolerated. The median progression-free survival (PFS) was 7.8 months, with 55 % and 38 % of patients experiencing PFS rates at 6 and 12 months respectively. Notably, there were 2 complete responses and 6 partial responses observed. The treatment also led to a reduction in pain and disease-related symptoms, positioning it as a viable salvage regimen.<sup>41</sup> In the case of pembrolizumab, with or without bevacizumab, limited benefits and tolerability were observed. Cohort A showed a 26.0 % PFS-6, 8.8 months median OS, and 20 % objective response rate (ORR). Cohort B exhibited a 6.7 % PFS-6, 10.3 months median OS, and 0 % ORR. Tumor immune markers did not serve as prognosticators for overall survival. The most common adverse events included fatigue, hypertension, and proteinuria. There were no treatment-related deaths reported, and the discontinuation rate due to adverse events was 10 %.<sup>42</sup>

#### 4.5. Phase 3 clinical trials

Among the phase 3 randomized clinical trials, some important outcomes emerged. Firstly, in patients with newly diagnosed glioblastoma multiforme (GBM), the addition of an autologous tumor lysate-loaded dendritic cell vaccine (DCVax-L) to standard care demonstrated improved survival rates. The median overall survival (OS) for non-methylated O6-methylguanine-DNA methyltransferase (MGMT) GBM patients receiving DCVax-L was 19.3 months, compared to 16.5 months in the control group. For recurrent GBM patients, the median OS was 13.2 months with DCVax-L, compared to 7.8 months in the control group. Additionally, patients with methylated MGMT and non-methylated GBM showed even better survival outcomes with DCVax-L, indicating significant and clinically meaningful benefits.<sup>67</sup> A schematic diagram representing the response of glioblastoma (GBM) to different treatment modalities is shown in Fig. 3. Secondly, a trial comparing nivolumab plus radiation therapy (NIVO + RT) to temozolomide plus radiation therapy (TMZ + RT) for GBM did not meet its primary



**Fig. 3.** Response of glioblastoma (GBM) to different treatment modalities. This figure shows Glioblastoma (GBM). Glioblastomas are resistant (red arrows pointing towards GBM) to many treatment modalities, including radiotherapy (RT) and chemotherapy (CT). Radiotherapy or chemotherapy alone are not that efficacious in treating glioblastoma (downwards pointing red arrows). Radiotherapy and chemotherapy can be hazardous to normal cells as well (biohazard sign). Glioblastoma responds differently to different treatment modalities. Combination therapies, such as immunotherapy (IT) and radiotherapy, can be more effective (bigger upwards pointing green arrow) than single-agent therapies in killing GBM (green arrow pointing towards GBM). However, combination therapies can also be more toxic (bigger size of biohazard sign) than single-agent therapies. The goal of treatment for glioblastoma is to kill as many GSCs as possible while minimizing the damage to healthy cells.

endpoint of improving overall survival. TMZ + RT demonstrated a longer median OS compared to NIVO + RT, confirming TMZ + RT as the established standard of care for GBM. No new safety signals were detected with nivolumab in this study.<sup>68</sup> Thirdly, the use of depatux-m in GBM patients showed a similar median OS of 18.9 months compared to placebo, but a longer median progression-free survival (PFS) of 8.0 months compared to 6.3 months for placebo. Notably, this effect was more pronounced in patients with epidermal growth factor receptor variant III (EGFRvIII)-mutant or MGMT unmethylated tumors. No new safety risks were identified during the interim analysis.<sup>69</sup>

Another approach in glioblastoma research involves using CRISPR gene editing to treat the disease. By precisely altering key genes involved in angiogenesis, such as Notch1, PDPN, DDX39B, and VEGF-related genes (BIG1 and BIG2), scientists have uncovered detailed insights into the molecular processes driving vascularization, which could serve as potential therapeutic targets. The diverse impact of CRISPR/Cas9 is seen when the emphasis is on inflammation within the GBM microenvironment. By targeting genes such as CIS, OPN, and AIM2, these studies utilize CRISPR/Cas9 to boost the effects of Natural Killer Cells, regulate M2 macrophages, and trigger pyroptosis, all of which contribute to the immune regulation of GBM. The adaptability of CRISPR/Cas9 in manipulating these microenvironment-related targets offers promising pathways for creating targeted therapies to limit the growth and progression of GBM, highlighting its potential as a groundbreaking tool in the search for effective treatments for glioblastoma.<sup>83</sup>

## 5. Summary

In summary, the reviewed studies encompassing translational and basic sciences, as well as phase 0, 1, 2, and 3 clinical trials, shed light on various aspects of glioblastoma, an aggressive brain tumor with limited treatment options. The findings highlight the complex interplay between tumor cells, neural progenitor cells, and the tumor microenvironment, providing insights into potential therapeutic strategies. The role of extracellular vesicles (EVs) in intercellular communication within the tumor microenvironment was emphasized. Glioblastoma-



derived EVs were found to promote tumor cell growth and migration, as well as enhance neural progenitor cell proliferation and migration through the activation of the PI3K-Akt-mTOR pathway. Targeting this pathway may offer a potential therapeutic strategy for glioblastoma. The response of glioblastoma stem cells (GSCs) to different treatment modalities was extensively explored. Radiotherapy was found to induce a transformation of proneural (PN) GSCs into resistant mesenchymal (MES) GSCs, highlighting the need for inhibiting this transformation to restore GBM sensitivity to radiotherapy. Metabolic therapy targeting GSCs' activated glutamine metabolism showed promise in reversing their resistance to radiochemotherapy. Combination therapies with temozolomide exhibited potential in inhibiting both PN and MES GSCs. Immunotherapy targeting GSCs and the exploration of glutamine metabolism-related pathways as potential targets for enhancing immunotherapy efficacy were also discussed. Additionally, targeting specific markers on GSCs and utilizing combined therapeutic options showed promise for improving treatment efficacy. The molecular dynamics and fate choices underlying *de novo* gliomagenesis from human neural stem/progenitor cells (hNSCs/hNPCs) were elucidated, providing insights into potential early-stage treatment and diagnosis of glioblastoma. A persistent NSC-like population was reported to be identified throughout tumor progression, indicating the importance of transcriptional reprogramming and fate-switches in NSC-like cells for malignant heterogeneity and tumor phenotype transitions. The review of literature also reported the identification of C1QL1 as a new factor promoting glioma development and demonstrated the potential efficacy of transient AP-1 inhibition in inhibiting gliomagenesis. Furthermore, the susceptibility of neural stem cells (NSCs) and neural progenitor cells (NPCs) to Zika virus (ZIKV) infection was explored, revealing the detrimental effects of ZIKV on neurogenesis and its potential as an oncolytic virus for treating glioblastoma. The therapeutic prospects of ZIKV for GBM treatment, including tumor clearance and modulation of the GBM microenvironment, were highlighted.

In phase 0 and 1 clinical trials, several experimental treatments for brain tumors showed promising outcomes. DS-1001, WP1066, Ceritinib, NSC-CRAD-S-pk7, and Vorasidenib demonstrated potential therapeutic benefits and were generally well tolerated. Ribociclib and everolimus exhibited good tolerability and pharmacokinetic characteristics, with ribociclib showing the potential to reach therapeutic levels in cerebrospinal fluid and tumor tissue. Phase 1b and Phase 2 clinical trials have contributed valuable insights into the safety, tolerability, and efficacy of various experimental therapies. G47Δ, chloroquine, autologous adoptive immune-cell therapy, and VB-111 have demonstrated promising results in terms of tolerability, survival rates, and treatment responses. In Phase 2 clinical trials, selinexor and selumetinib have shown positive responses and prolonged disease stability in specific patient populations. Trabectedin, AV-GBM-1, and pembrolizumab, with or without bevacizumab, have yielded mixed results and varying tolerability profiles. Limitations and challenges to the aforementioned trials give an impression that if multiple treatment modalities are used in combination, they provide a better treatment plan compared to if the modalities are used alone. The results of these trials show us that although individual therapies may be clinically not that significant, but if used in combination, they can provide with a much better tumor resolution. These studies emphasize the importance of investigating combination therapies, predictive signatures for response, and patient selection strategies to improve outcomes for glioblastoma patients. Phase 3 clinical trials have also provided important findings. The addition of DCVax-L to standard care has shown improved survival rates for newly diagnosed and recurrent glioblastoma patients, particularly in those with methylated MGMT and non-methylated GBM. The use of depatux-m demonstrated a longer median progression-free survival, especially in patients with EGFRvIII-mutant or MGMT unmethylated tumors. These Phase 3 trial results highlight the importance of exploring personalized treatment approaches based on specific molecular markers and patient characteristics. Further investigation into targeted therapies and

immunotherapies, as well as advancements in understanding tumor biology, will likely shape the future of glioblastoma treatment.

Glioblastoma is known to have been affected by bacteria in the gut through different mechanisms. Researchers found four specific microbial taxa—Eubacteriumbrachygroup, Anaerostipes, Faecalibacterium, Prevotella7, and Ruminococcaceae—to be significantly associated with GBM. Anaerostipes, Faecalibacterium, Prevotella7, and Ruminococcaceae notably showed a protective effect against GBM, suggesting their potential as therapeutic targets or indicators of reduced risk for this aggressive brain tumor. However, research on the effects of these microbiota and their metabolites on GBM development through specific pathways is limited. Chronic inflammation, known to contribute to tumorigenesis, is relevant to GBM, and their discussion draws from existing studies on inflammatory and immune responses. Previous research highlights Eubacteriumbrachygroup's potential role in promoting cancer development through inflammation, while other studies suggest it might play an anti-tumor role by releasing peptides recognized by T cells. Anaerostipes and Ruminococcaceae have demonstrated protective roles in various cancers and may influence immune responses in GBM. Faecalibacterium's role in modulating anti-inflammatory responses and its association with other cancers, such as prostate cancer, highlight its significance. The identification of Prevotella7 as a potential biomarker for GBM and other cancers underscores its diagnostic and therapeutic potential. Further research is needed to understand the mechanisms and clinical applications of these microbial taxa in cancer.<sup>84</sup>

In terms of diagnosis, interpreting MRI scans of patients with GBM can be challenging and subjective, but AI offers a promising solution by revolutionizing diagnostic imaging and treatment planning. Radiomics and radiogenomics enable AI to extract detailed features from images and integrate genetic information, aiding in tumor classification and identifying specific mutations. AI-driven segmentation techniques enhance surgical and radiotherapeutic planning by providing precise delineations, and predictive features help anticipate postoperative complications and survival rates. However, concerns about medical data quality, AI transparency, and ethical issues need to be addressed through collaboration between neurosurgeons, data scientists, ethicists, and regulatory bodies. Overall, AI has the potential to significantly improve the diagnosis and management of aggressive brain tumors like GBM.<sup>85</sup>

## 6. Conclusion

In conclusion, this comprehensive review provides valuable insights into glioblastoma treatment and identifies promising therapeutic avenues. Intercellular communication mediated by extracellular vesicles within the tumor microenvironment emerges as a key factor in tumor growth and migration. Targeting the transformation of proneural to resistant mesenchymal cells and exploring metabolic therapy show promise in overcoming treatment resistance. Immunotherapy, combined therapies, and molecular marker-targeted approaches hold potential for enhancing treatment efficacy. The molecular dynamics of gliomagenesis contribute to early-stage diagnosis and treatment, while the exploration of the Zika virus as an oncolytic agent presents an intriguing avenue for therapy. Phase 0 to 3 clinical trials demonstrate promising outcomes, emphasizing the need for combination therapies and appropriate patient selection strategies. Several compounds, including DS-1001, WP1066, Ceritinib, NSC-CRAD-S-pk7, and Vorasidenib, show therapeutic benefits and good tolerability. Ribociclib and everolimus exhibit favorable pharmacokinetic characteristics, while selinexor and selumetinib demonstrate positive responses in specific patient populations. Phase 3 trials highlight the efficacy of DCVax-L in improving survival rates, particularly for patients with specific molecular markers, and depatux-m in prolonging progression-free survival. These findings underscore the importance of personalized treatment approaches and continued exploration of targeted therapies, immunotherapies, and our understanding of tumor biology to enhance glioblastoma treatment outcomes.

in the future.

### Funding disclosure

All authors declare that they received no funding for this study.

### Ethical considerations

All authors adhered to all applicable ethical guidelines during all steps of the manuscript.

### Prior publication or duplication

All authors declare that the review paper is an original work and has not been previously published or submitted for publication elsewhere.

### Data availability statement

All data used in this review manuscript is publicly available online.

### CRediT authorship contribution statement

**Muhammad Saqib:** Writing – review & editing, Writing – original draft, Visualization, Validation, Supervision, Resources, Project administration, Methodology, Investigation, Formal analysis, Data curation, Conceptualization. **Aanus Zahoor:** Writing – review & editing, Writing – original draft, Visualization, Conceptualization. **Ahmed Rahib:** Writing – review & editing, Writing – original draft, Visualization, Conceptualization. **Amna Shamim:** Writing – review & editing, Writing – original draft, Data curation. **Hassan Mumtaz:** Writing – review & editing, Writing – original draft, Data curation, Conceptualization.

### Declaration of competing interest

All authors declare that they have no potential conflicts of interest that may have influenced the review process or the interpretation of the findings. This includes financial interests, employment affiliations, or any other personal or professional relationships that could be perceived as influencing the objectivity of the review.

### Acknowledgements

None.

### References

- Louis DN, Perry A, Wesseling P, et al. The 2021 WHO classification of tumors of the central nervous system: a summary. *Neuro Oncol.* 2021;23(8):1231–1251. <https://doi.org/10.1093/neuonc/noab106>.
- Li S, Wang C, Chen J, et al. Signaling pathways in brain tumors and therapeutic interventions. *Signal Transduct Targeted Ther.* 2023;8(1):8. <https://doi.org/10.1038/s41392-022-01260-z>.
- Vaidya M, Sreerama S, Gonzalez-Vega M, Smith J, Field M, Sugaya K. Coculture with neural stem cells may shift the transcription profile of glioblastoma multiforme towards cancer-specific stemness. *Int J Mol Sci.* 2023;24(4). <https://doi.org/10.3390/ijms24043242>.
- Louis DN, Perry A, Reifenberger G, et al. The 2016 World Health Organization classification of tumors of the central nervous system: a summary. *Acta Neuropathol.* 2016;131(6):803–820. <https://doi.org/10.1007/s00401-016-1545-1>.
- Loras A, Gonzalez-Bonet LG, Gutierrez-Arroyo JL, Martinez-Cadenas C, Marques-Torres MA. Neural stem cells as potential glioblastoma cells of origin. *Life.* 2023;13(4). <https://doi.org/10.3390/life13040905>.
- Arrieta VA, Dmello C, McGrail DJ, et al. Immune checkpoint blockade in glioblastoma: from tumor heterogeneity to personalized treatment. *J Clin Invest.* 2023;133(2). <https://doi.org/10.1172/jci163447>.
- Yang J, Shi Z, Liu R, Wu Y, Zhang X. Combined-therapeutic strategies synergistically potentiate glioblastoma multiforme treatment via nanotechnology. *Theranostics.* 2020;10(7):3223–3239. <https://doi.org/10.7150/thno.40298>.
- Natsume A, Arakawa Y, Narita Y, et al. The first-in-human phase I study of a brain-penetrant mutant IDH1 inhibitor DS-1001 in patients with recurrent or progressive IDH1-mutant gliomas. *Neuro Oncol.* 2023;25(2):326–336. <https://doi.org/10.1093/neuonc/noac155>.
- O'Rawe M, Wickremesekera AC, Pandey R, et al. Treatment of glioblastoma with repurposed renin-angiotensin system modulators: results of a phase I clinical trial. *J Clin Neurosci.* 2022;95:48–54. <https://doi.org/10.1016/j.jocn.2021.11.023>.
- Groat J, OTT M, Wei J, et al. A first-in-human Phase I trial of the oral p-STAT3 inhibitor WP1066 in patients with recurrent malignant glioma. *CNS oncology.* 2022;11(2), Cns87. <https://doi.org/10.2217/cns-2022-0005>.
- Mehta S, Fiorelli R, Bao X, et al. A phase 0 trial of Ceritinib in patients with brain metastases and recurrent glioblastoma. *Clin Cancer Res : an official journal of the American Association for Cancer Research.* 2022;28(2):289–297. <https://doi.org/10.1158/1078-0432.Ccr-21-1096>.
- Fares J, Ahmed AU, Ulasov IV, et al. Neural stem cell delivery of an oncolytic adenovirus in newly diagnosed malignant glioma: a first-in-human, phase 1, dose-escalation trial. *Lancet Oncol.* 2021;22(8):1103–1114. [https://doi.org/10.1016/s1470-2045\(21\)00245-x](https://doi.org/10.1016/s1470-2045(21)00245-x).
- Mellinghoff IK, Penas-Prado M, Peters KB, et al. Vorasidenib, a dual inhibitor of mutant IDH1/2, in recurrent or progressive glioma; results of a first-in-human phase I trial. *Clin Cancer Res : an official journal of the American Association for Cancer Research.* 2021;27(16):4491–4499. <https://doi.org/10.1158/1078-0432.Ccr-21-0611>.
- Sahbjam S, Forsyth PA, Tran ND, et al. Hypofractionated stereotactic re-irradiation with pembrolizumab and bevacizumab in patients with recurrent high-grade gliomas: results from a phase I study. *Neuro Oncol.* 2021;23(4):677–686. <https://doi.org/10.1093/neuonc/noaa260>.
- DeWire MD, Fuller C, Campagne O, et al. A phase I and surgical study of ribociclib and everolimus in children with recurrent or refractory malignant brain tumors: a pediatric brain tumor consortium study. *Clin Cancer Res : an official journal of the American Association for Cancer Research.* 2021;27(9):2442–2451. <https://doi.org/10.1158/1078-0432.Ccr-20-4078>.
- Van Mater D, Gururangan S, Becher O, et al. A phase I trial of the CDK 4/6 inhibitor palbociclib in pediatric patients with progressive brain tumors: a Pediatric Brain Tumor Consortium study (PBTC-042). *Pediatr Blood Cancer.* 2021;68(4), e28879. <https://doi.org/10.1002/pbc.28879>.
- Saran F, Welsh L, James A, et al. Afatinib and radiotherapy, with or without temozolomide, in patients with newly diagnosed glioblastoma: results of a phase I trial. *Journal of neuro-oncology.* 2021;155(3):307–317. <https://doi.org/10.1007/s11060-021-03877-6>.
- Wu J, Yuan Y, Long Priel DA, et al. Phase I study of zotiraciclib in combination with temozolomide for patients with recurrent high-grade astrocytomas. *Clin Cancer Res : an official journal of the American Association for Cancer Research.* 2021;27(12):3298–3306. <https://doi.org/10.1158/1078-0432.Ccr-20-4730>.
- Wei KC, Hsu PW, Tsai HC, et al. Safety and tolerability of asunercept plus standard radiotherapy/temozolomide in Asian patients with newly-diagnosed glioblastoma: a phase I study. *Sci Rep.* 2021;11(1), 24067. <https://doi.org/10.1038/s41598-021-02527-1>.
- Kaley TJ, Panageas KS, Pentsova EI, et al. Phase I clinical trial of tlemsirolimus and perfosine for recurrent glioblastoma. *Annals of clinical and translational neurology.* 2020;7(4):429–436. <https://doi.org/10.1002/acn3.51009>.
- Hipp SJ, Goldman S, Kaushal A, et al. A phase I trial of lenalidomide and radiotherapy in children with diffuse intrinsic pontine gliomas or high-grade gliomas. *Journal of neuro-oncology.* 2020;149(3):437–445. <https://doi.org/10.1007/s11060-020-03627-0>.
- Kieran MW, Goumnerova L, Manley P, et al. Phase I study of gene-mediated cytotoxic immunotherapy with AdV-tk as adjuvant to surgery and radiation for pediatric malignant glioma and recurrent ependymoma. *Neuro Oncol.* 2019;21(4):537–546. <https://doi.org/10.1093/neuonc/noy202>.
- Galanis E, Anderson SK, Twohy EL, et al. A phase 1 and randomized, placebo-controlled phase 2 trial of bevacizumab plus dasatinib in patients with recurrent glioblastoma: alliance/North Central Cancer Treatment Group N0872. *Cancer.* 2019;125(21):3790–3800. <https://doi.org/10.1002/cncr.32340>.
- Lassman AB, van den Bent MJ, Gan HK, et al. Safety and efficacy of deputuxizumab mafodotin + temozolomide in patients with EGFR-amplified, recurrent glioblastoma: results from an international phase I multicenter trial. *Neuro Oncol.* 2019;21(1):106–114. <https://doi.org/10.1093/neuonc/noy091>.
- Jiang H, Yu K, Cui Y, et al. Combination of immunotherapy and radiotherapy for recurrent malignant gliomas: results from a prospective study. *Front Immunol.* 2021;12, 632547. <https://doi.org/10.3389/fimmu.2021.632547>.
- Todo T, Ino Y, Ohtsu H, Shibahara J, Tanaka M. A phase I/II study of triple-mutated oncolytic herpes virus G47Δ in patients with progressive glioblastoma. *Nat Commun.* 2022;13(1):4119. <https://doi.org/10.1038/s41467-022-31262-y>.
- Su JM, Kilburn LB, Mansur DB, et al. Phase I/II trial of vorinostat and radiation and maintenance vorinostat in children with diffuse intrinsic pontine glioma: a Children's Oncology Group report. *Neuro Oncol.* 2022;24(4):655–664. <https://doi.org/10.1093/neuonc/noab188>.
- Compter I, Eekers DBP, Hoeben A, et al. Chloroquine combined with concurrent radiotherapy and temozolomide for newly diagnosed glioblastoma: a phase IB trial. *Autophagy.* 2021;17(9):2604–2612. <https://doi.org/10.1080/15548627.2020.1816343>.
- El-Khouly FE, Veldhuijzen van Zanten SEM, Jansen MHA, et al. A phase I/II study of bevacizumab, irinotecan and erlotinib in children with progressive diffuse intrinsic pontine glioma. *Journal of neuro-oncology.* 2021;153(2):263–271. <https://doi.org/10.1007/s11060-021-03763-1>.
- Narita Y, Muragaki Y, Kagawa N, et al. Safety and efficacy of deputuxizumab mafodotin in Japanese patients with malignant glioma: a nonrandomized, phase 1/2 trial. *Cancer Sci.* 2021;112(12):5020–5033. <https://doi.org/10.1111/cas.15153>.
- Lim J, Park Y, Ahn JW, et al. Autologous adoptive immune-cell therapy elicited a durable response with enhanced immune reaction signatures in patients with

- recurrent glioblastoma: an open label, phase I/IIa trial. *PLoS One*. 2021;16(3), e0247293. <https://doi.org/10.1371/journal.pone.0247293>.
32. Frappaz D, Barriault M, Montané L, et al. MEVITEM-a phase I/II trial of vismodegib + temozolomide vs temozolomide in patients with recurrent/refractory medulloblastoma with Sonic Hedgehog pathway activation. *Neuro Oncol*. 2021;23(11):1949–1960. <https://doi.org/10.1093/neuonc/noab087>.
  33. Baxter PA, Su JM, Onar-Thomas A, et al. A phase I/II study of veliparib (ABT-888) with radiation and temozolomide in newly diagnosed diffuse pontine glioma: a Pediatric Brain Tumor Consortium study. *Neuro Oncol*. 2020;22(6):875–885. <https://doi.org/10.1093/neuonc/noaa016>.
  34. Brenner AJ, Peters KB, Vredenburg J, et al. Safety and efficacy of VB-111, an anticancer gene therapy, in patients with recurrent glioblastoma: results of a phase I/II study. *Neuro Oncol*. 2020;22(5):694–704. <https://doi.org/10.1093/neuonc/noz231>.
  35. van den Bent M, Azaro A, De Vos F, et al. A Phase Ib/II, open-label, multicenter study of INC280 (capmatinib) alone and in combination with buparlisib (BKM120) in adult patients with recurrent glioblastoma. *Journal of neuro-oncology*. 2020;146(1):79–89. <https://doi.org/10.1007/s11060-019-03337-2>.
  36. Wick A, Desjardins A, Suarez C, et al. Phase 1b/2a study of galunisertib, a small molecule inhibitor of transforming growth factor-beta receptor I, in combination with standard temozolomide-based radiochemotherapy in patients with newly diagnosed malignant glioma. *Invest N Drugs*. 2020;38(5):1570–1579. <https://doi.org/10.1007/s10637-020-00910-9>.
  37. Lassman AB, Wen PY, van den Bent MJ, et al. A phase II study of the efficacy and safety of oral selinexor in recurrent glioblastoma. *Clin Cancer Res : an official journal of the American Association for Cancer Research*. 2022;28(3):452–460. <https://doi.org/10.1158/1078-0432.Ccr-21-2225>.
  38. Preusser M, Silvani A, Le Rhun E, et al. Trabectedin for recurrent WHO grade 2 or 3 meningioma: a randomized phase II study of the EORTC Brain Tumor Group (EORTC-1320-BTG). *Neuro Oncol*. 2022;24(5):755–767. <https://doi.org/10.1093/neuonc/noab243>.
  39. Bota DA, Taylor TH, Piccioni DE, et al. Phase 2 study of AV-GBM-1 (a tumor-initiating cell targeted dendritic cell vaccine) in newly diagnosed Glioblastoma patients: safety and efficacy assessment. *J Exp Clin Cancer Res : CR*. 2022;41(1):344. <https://doi.org/10.1186/s13046-022-02552-6>.
  40. Fangusaro J, Onar-Thomas A, Poussaint TY, et al. A phase II trial of selumetinib in children with recurrent optic pathway and hypothalamic low-grade glioma without NF1: a Pediatric Brain Tumor Consortium study. *Neuro Oncol*. 2021;23(10):1777–1788. <https://doi.org/10.1093/neuonc/noab047>.
  41. Gilbert MR, Yuan Y, Wu J, et al. A phase II study of dose-dense temozolomide and lapatinib for recurrent low-grade and anaplastic supratentorial, infratentorial, and spinal cord ependymoma. *Neuro Oncol*. 2021;23(3):468–477. <https://doi.org/10.1093/neuonc/noaa240>.
  42. Nayak L, Molinaro AM, Peters K, et al. Randomized phase II and biomarker study of pembrolizumab plus bevacizumab versus pembrolizumab alone for patients with recurrent glioblastoma. *Clin Cancer Res : an official journal of the American Association for Cancer Research*. 2021;27(4):1048–1057. <https://doi.org/10.1158/1078-0432.Ccr-20-2500>.
  43. Cheung IY, Cheung NV, Modak S, et al. Survival impact of anti-GD2 antibody response in a phase II ganglioside vaccine trial among patients with high-risk neuroblastoma with prior disease progression. *J Clin Oncol : official journal of the American Society of Clinical Oncology*. 2021;39(3):215–226. <https://doi.org/10.1200/jco.20.01892>.
  44. Levy AS, Kraillo M, Chi S, et al. Temozolomide with irinotecan versus temozolomide, irinotecan plus bevacizumab for recurrent medulloblastoma of childhood: report of a COG randomized Phase II screening trial. *Pediatr Blood Cancer*. 2021;68(8), e29031. <https://doi.org/10.1002/pbc.29031>.
  45. Brown PD, Chung C, Liu DD, et al. A prospective phase II randomized trial of proton radiotherapy vs intensity-modulated radiotherapy for patients with newly diagnosed glioblastoma. *Neuro Oncol*. 2021;23(8):1337–1347. <https://doi.org/10.1093/neuonc/noab040>.
  46. Peereboom DM, Ye X, Mikkelsen T, et al. A phase II and pharmacodynamic trial of RO4929097 for patients with recurrent/progressive glioblastoma. *Neurosurgery*. 2021;88(2):246–251. <https://doi.org/10.1093/neuros/nyaa412>.
  47. Brastianos PK, Strickland MR, Lee EQ, et al. Phase II study of ipilimumab and nivolumab in leptomeningeal carcinomatosis. *Nat Commun*. 2021;12(1):5954. <https://doi.org/10.1038/s41467-021-25859-y>.
  48. Ewertl KD, Yao X, London WB, et al. A POETIC Phase II study of continuous oral everolimus in recurrent, radiographically progressive pediatric low-grade glioma. *Pediatr Blood Cancer*. 2021;68(2), e28787. <https://doi.org/10.1002/pbc.28787>.
  49. Tabouret E, Fabbro M, Autran D, et al. TEMOBIC: phase II trial of neoadjuvant chemotherapy for unresectable anaplastic gliomas: an ANOCEF study. *Oncol*. 2021;26(8). <https://doi.org/10.1002/onco.13765>, 647–e1304.
  50. Sim HW, McDonald KL, Lwin Z, et al. A randomized phase II trial of veliparib, radiotherapy, and temozolomide in patients with unmethylated MGMT glioblastoma: the VERTU study. *Neuro Oncol*. 2021;23(10):1736–1749. <https://doi.org/10.1093/neuonc/noab111>.
  51. Dufour C, Foulon S, Geoffray A, et al. Prognostic relevance of clinical and molecular risk factors in children with high-risk medulloblastoma treated in the phase II trial PNET HR+5. *Neuro Oncol*. 2021;23(7):1163–1172. <https://doi.org/10.1093/neuonc/noaa301>.
  52. Goldman S, Pollack IF, Jakacki RI, et al. Phase II study of peginterferon alpha-2b for patients with unresectable or recurrent craniopharyngiomas: a Pediatric Brain Tumor Consortium report. *Neuro Oncol*. 2020;22(11):1696–1704. <https://doi.org/10.1093/neuonc/noaa119>.
  53. Puduvalli VK, Wu J, Yuan Y, et al. A Bayesian adaptive randomized phase II multicenter trial of bevacizumab with or without vorinostat in adults with recurrent glioblastoma. *Neuro Oncol*. 2020;22(10):1505–1515. <https://doi.org/10.1093/neuonc/noaa062>.
  54. Fisher BJ, Pugh SL, Macdonald DR, et al. Phase 2 study of a temozolomide-based chemoradiation therapy regimen for high-risk, low-grade gliomas: long-term results of radiation therapy oncology group 0424. *Int J Radiat Oncol Biol Phys*. 2020;107(4):720–725. <https://doi.org/10.1016/j.ijrobp.2020.03.027>.
  55. Van Den Bent M, Eoli M, Sepúlveda JM, et al. INTELLANCE 2/EORTC 1410 randomized phase II study of Depatux-M alone and with temozolomide vs temozolomide or lomustine in recurrent EGFR amplified glioblastoma. *Neuro Oncol*. 2020;22(5):684–693. <https://doi.org/10.1093/neuonc/noz222>.
  56. Balana C, Vaz MA, Manuel Sepúlveda J, et al. A phase II randomized, multicenter, open-label trial of continuing adjuvant temozolomide beyond 6 cycles in patients with glioblastoma (GEINO 14-01). *Neuro Oncol*. 2020;22(12):1851–1861. <https://doi.org/10.1093/neuonc/noaa107>.
  57. Cloughesy TF, Brenner A, de Groot JF, et al. A randomized controlled phase III study of VB-111 combined with bevacizumab vs bevacizumab monotherapy in patients with recurrent glioblastoma (GLOBE). *Neuro Oncol*. 2020;22(5):705–717. <https://doi.org/10.1093/neuonc/noz232>.
  58. Lafay-Cousin L, Bouffet E, Strother D, et al. Phase II study of nonmetastatic desmoplastic medulloblastoma in children younger than 4 Years of age: a report of the children's oncology group (ACNS1221). *J Clin Oncol : official journal of the American Society of Clinical Oncology*. 2020;38(3):223–231. <https://doi.org/10.1200/jco.19.00845>.
  59. Rutkowski S, Bode U, Deinlein F, et al. Treatment of early childhood medulloblastoma by postoperative chemotherapy alone. *N Engl J Med*. 2005;352(10):978–986. <https://doi.org/10.1056/NEJMoa042176>.
  60. Rutkowski S, Gerber NU, von Hoff K, et al. Treatment of early childhood medulloblastoma by postoperative chemotherapy and deferred radiotherapy. *Neuro Oncol*. 2009;11(2):201–210. <https://doi.org/10.1215/15228517-2008-084>.
  61. Wen PY, Reardon DA, Armstrong TS, et al. A randomized double-blind placebo-controlled phase II trial of dendritic cell vaccine ICT-107 in newly diagnosed patients with glioblastoma. *Clin Cancer Res : an official journal of the American Association for Cancer Research*. 2019;25(19):5799–5807. <https://doi.org/10.1158/1078-0432.Ccr-19-0261>.
  62. Lee EQ, Muzikansky A, Duda DG, et al. Phase II trial of ponatinib in patients with bevacizumab-refractory glioblastoma. *Cancer Med*. 2019;8(13):5988–5994. <https://doi.org/10.1002/cam4.2505>.
  63. Wen PY, Touat M, Alexander BM, et al. Buparlisib in patients with recurrent glioblastoma harboring phosphatidylinositol 3-kinase pathway activation: an open-label, multicenter, multi-arm, phase II trial. *J Clin Oncol : official journal of the American Society of Clinical Oncology*. 2019;37(9):741–750. <https://doi.org/10.1200/jco.18.01207>.
  64. Kaley TJ, Panageas KS, Mellinghoff IK, et al. Phase II trial of an AKT inhibitor (perifosine) for recurrent glioblastoma. *Journal of neuro-oncology*. 2019;144(2):403–407. <https://doi.org/10.1007/s11060-019-03243-7>.
  65. Blakeley JO, Grossman SA, Chi AS, et al. Phase II study of iniparib with concurrent chemoradiation in patients with newly diagnosed glioblastoma. *Clin Cancer Res : an official journal of the American Association for Cancer Research*. 2019;25(1):73–79. <https://doi.org/10.1158/1078-0432.Ccr-18-0110>.
  66. Brandes AA, Gil-Gil M, Saran F, et al. A randomized phase II trial (TAMIGA) evaluating the efficacy and safety of continuous bevacizumab through multiple lines of treatment for recurrent glioblastoma. *Oncol*. 2019;24(4):521–528. <https://doi.org/10.1634/theoncologist.2018-0290>.
  67. Liao LM, Ashkan K, Brem S, et al. Association of autologous tumor lysate-loaded dendritic cell vaccination with extension of survival among patients with newly diagnosed and recurrent glioblastoma: a phase 3 prospective externally controlled cohort trial. *JAMA Oncol*. 2023;9(1):112–121. <https://doi.org/10.1001/jamaoncol.2022.5370>.
  68. Omuro A, Brandes AA, Carpentier AF, et al. Radiotherapy combined with nivolumab or temozolomide for newly diagnosed glioblastoma with unmethylated MGMT promoter: an international randomized phase III trial. *Neuro Oncol*. 2023;25(1):123–134. <https://doi.org/10.1093/neuonc/noac099>.
  69. Lassman AB, Pugh SL, Wang TJC, et al. Depatuxizumab mafodotin in EGFR-amplified newly diagnosed glioblastoma: a phase III randomized clinical trial. *Neuro Oncol*. 2023;25(2):339–350. <https://doi.org/10.1093/neuonc/noac173>.
  70. Lim M, Weller M, Idbaih A, et al. Phase III trial of chemoradiotherapy with temozolomide plus nivolumab or placebo for newly diagnosed glioblastoma with methylated MGMT promoter. *Neuro Oncol*. 2022;24(11):1935–1949. <https://doi.org/10.1093/neuonc/noac116>.
  71. Reardon DA, Brandes AA, Omuro A, et al. Effect of nivolumab vs bevacizumab in patients with recurrent glioblastoma: the CheckMate 143 phase 3 randomized clinical trial. *JAMA Oncol*. 2020;6(7):1003–1010. <https://doi.org/10.1001/jamaoncol.2020.1024>.
  72. Narita Y, Arakawa Y, Yamasaki F, et al. A randomized, double-blind, phase III trial of personalized peptide vaccination for recurrent glioblastoma. *Neuro Oncol*. 2019;21(3):348–359. <https://doi.org/10.1093/neuonc/noy200>.
  73. Guo C, Yang Q, Xu P, et al. Adjuvant temozolomide chemotherapy with or without interferon Alfa among patients with newly diagnosed high-grade gliomas: a randomized clinical trial. *JAMA Netw Open*. 2023;6(1), e2253285. <https://doi.org/10.1001/jamanetworkopen.2022.53285>.
  74. Pan J, Sheng S, Ye L, et al. Extracellular vesicles derived from glioblastoma promote proliferation and migration of neural progenitor cells via PI3K-Akt pathway. *Cell Commun Signal : CCS*. 2022;20(1):7. <https://doi.org/10.1186/s12964-021-00760-9>.



75. Wang Z, Zhang H, Xu S, Liu Z, Cheng Q. The adaptive transition of glioblastoma stem cells and its implications on treatments. *Signal Transduct Targeted Ther.* 2021;6(1):124. <https://doi.org/10.1038/s41392-021-00491-w>.
76. Wang X, Zhou R, Xiong Y, et al. Sequential fate-switches in stem-like cells drive the tumorigenic trajectory from human neural stem cells to malignant glioma. *Cell Res.* 2021;31(6):684–702. <https://doi.org/10.1038/s41422-020-00451-z>.
77. Francipane MG, Douradinha B, Chinnici CM, Russelli G, Conaldi PG, Iannolo G. Zika virus: a new therapeutic candidate for glioblastoma treatment. *Int J Mol Sci.* 2021;22(20). <https://doi.org/10.3390/ijms222010996>.
78. Brockman AA, Mobley BC, Ihrle RA. Histological studies of the ventricular-subventricular zone as neural stem cell and glioma stem cell niche. *J Histochem Cytochem : official journal of the Histochemistry Society.* 2021;69(12):819–834. <https://doi.org/10.1369/00221554211032003>.
79. Okada M, Suzuki S, Togashi K, Sugai A, Yamamoto M, Kitanaka C. Targeting folate metabolism is selectively cytotoxic to glioma stem cells and effectively cooperates with differentiation therapy to eliminate tumor-initiating cells in glioma xenografts. *Int J Mol Sci.* 2021;22(21). <https://doi.org/10.3390/ijms222111633>.
80. Bonnay F, Veloso A, Steinmann V, et al. Oxidative metabolism drives immortalization of neural stem cells during tumorigenesis. *Cell.* 2020;182(6). <https://doi.org/10.1016/j.cell.2020.07.039>, 1490-507.e19.
81. Tang M, Xie Q, Gimple RC, et al. Three-dimensional bioprinted glioblastoma microenvironments model cellular dependencies and immune interactions. *Cell Res.* 2020;30(10):833–853. <https://doi.org/10.1038/s41422-020-0338-1>.
82. Li Y, Huang M, Liang S, et al. Gamma knife radiosurgery (GKRS) for patients with prolactinomas: long-term results from a single-center experience. *Med Sci Mon Int Med J Exp Clin Res : international medical journal of experimental and clinical research.* 2020;26, e924884. <https://doi.org/10.12659/msm.924884>.
83. Begagić Emir, Bečulić Hakija, Džurčić Nermin, et al. CRISPR/Cas9-Mediated gene therapy for glioblastoma: a scoping review. *Biomedicines.* 2024;12(1):238. <https://doi.org/10.3390/biomedicines12010238>.
84. Zeng C, Zhang C, He C, et al. Investigating the causal impact of gut microbiota on glioblastoma: a bidirectional Mendelian randomization study. *BMC Genom.* 2023;24:784. <https://doi.org/10.1186/s12864-023-09885-2>.
85. Ibrahim M, Muhammad Q, Zamarud A, Eiman H, Fazal F. Navigating glioblastoma diagnosis and care: transformative pathway of artificial intelligence in integrative oncology. *Cureus.* 2023 Aug 27;15(8), e44214. <https://doi.org/10.7759/cureus.44214>. PMID: 37645667; PMCID: PMC10461885.

## Abbreviations

EV: extracellular-vesicle  
GSCs: glioblastoma stem cells

PN: proneural  
MES: mesenchymal  
CNS: central nervous system  
WHO CNS5: World Health Organization Classification of Tumors of the Central Nervous System  
MDT: multidisciplinary treatment  
GBM: Glioblastoma Multiforme  
CSCs: cancer stem cells  
NSCs: neural stem cells  
ICB: immune checkpoint blockade  
IDH: Isocitrate dehydrogenase  
p-STAT3: signal transducer and activator of transcription 3  
MTD: maximum tolerated dose  
MFD: minimum fatal dose  
hNSCs/hNPCs: human neural stem/progenitor cells  
C1QL1: complement component 1, q subcomponent-like 1  
AP-1: activator protein-1  
NPCs: neural progenitor cells  
ZIKV infection: Zika virus  
iPSC: of induced pluripotent stem cell  
V-SVZ: ventricular-subventricular zone of the brain  
MTX: methotrexate  
PEM: pemetrexed  
DHFR: dihydrofolate reductase  
RFC-1: reduced folate carrier protein-1  
OxPhos: oxidative phosphorylation  
NAD+: nicotinamide adenine dinucleotide  
TICs: tumor-initiating cells  
DLP: digital light processing  
GKRS: Gamma-knife radiosurgery  
D-2-HG: D-2-hydroxyglutarate  
NSC-CRAd-S-pk7: oncolytic adenovirus delivered by neural stem cells  
TMZ: Temozolomide  
RT: Radiotherapy  
PFS6: progression-free survival at 6 months  
RANO: response assessment in neuro-oncology  
OS: overall survival  
mPFS: median progression-free survival  
mOS: median overall survival  
ORR: objective response rate  
AV-GBM-1: autologous dendritic cell vaccine – glioblastoma-1  
NIVO + RT: nivolumab plus radiation therapy  
MGMT: methylguanine-DNA methyltransferase