

A Mini-Review of Office Hysteroscopic Techniques for Endometrial Tissue Sampling in Postmenopausal Bleeding

Sergio Haimovich, Tanvir Tanvir¹

Department of Obstetrics and Gynecology, Del Mar University Hospital, Barcelona, Spain,
¹Department of Obstetrics and Gynecology, Tanvir Hospital, Hyderabad, Telangana, India

Submitted: 14-Mar-2021
Revised: 20-Mar-2021
Accepted: 28-Mar-2021
Published: 17-Apr-2021

INTRODUCTION

Abnormal uterine bleeding in climacteric and postmenopausal women is a common cause for a gynecological visit and accounts for two-thirds of all visits.^[1,2] Few common causes of postmenopausal bleeding (PMB) include vaginal atrophy, endometrial atrophy, endometrial polyps (EPs), endometrial cancer (EC), endometrial hyperplasia (EH), endometritis, uterine fibroids, cervical polyps, and cervical cancer.^[3] EC risk varies from 3% to 25% in women with PMB.^[4-9] The initial steps to facilitate a diagnosis are noninvasive methods which include a complete gynecological, speculum

ABSTRACT

Postmenopausal bleeding (PMB) is a common cause for a gynecological visit. Endometrial cancer risk varies from 3% to 25% in women with PMB. There is a significant concern of malignancy of the endometrium and the endocervical canal by a physician in postmenopausal women, and hence, most prefer operating room hysteroscopies with dilation and curettage (D & C) compared to in-office procedures. With increased availability of miniaturized instruments such as mini- resectoscope and tissue removal systems, there is high likelihood of blind D & C being replaced by hysteroscopic- guided targeted biopsy or visual D & C. The cost-effectiveness of office hysteroscopy is also well demonstrated. In December 2020, an electronic search was performed of PubMed, MEDLINE, and Cochrane Library to look for articles on office hysteroscopic biopsy techniques in postmenopausal women from 2010 to 2020. Relevant studies were included where various office hysteroscopic techniques are used for endometrial sampling in PMB. Studies with 5 Fr scissors, biopsy forceps, crocodile forceps, cup forceps, bipolar electrode, in-office tissue removal system (morcellator), flexible hysteroscope, and mini-resectoscope were included. Standard reference was used as an adequate endometrial sample for histology. The objective of this review is to explore the current evidence on different office hysteroscopic techniques available for endometrial tissue sampling in PMB.

Research Question: What are the different available in - office hysteroscopy techniques for obtaining endometrial biopsy?

Clinical Importance: Understanding the adequacy of an endometrial tissue sample obtained by different in - office hysteroscopy techniques and their accuracy by histology.

KEYWORDS: *Office hysteroscopy techniques, postmenopausal bleeding, targeted biopsy*

examination and a transvaginal ultrasound.^[10] Diagnostic workup strategies are inconsistent in different countries and vary widely in different clinic/hospital settings. Invasive investigations include saline infusion sonography, outpatient blind endometrial biopsies, hysteroscopic-guided targeted biopsy, and dilatation and curettage (D & C).^[2,10,11] Failure of office-based procedures is due to failure to obtain access to the uterine cavity or inadequate sample.^[12]

Address for correspondence: Dr. Tanvir Tanvir,
Department of Obstetrics and Gynecology, Tanvir Hospital,
Hyderabad, Telangana, India.
E-mail: tanvirsinghtan@gmail.com

This is an open access journal, and articles are distributed under the terms of the Creative Commons Attribution-NonCommercial-ShareAlike 4.0 License, which allows others to remix, tweak, and build upon the work non-commercially, as long as appropriate credit is given and the new creations are licensed under the identical terms.

For reprints contact: WKHLRPMedknow_reprints@wolterskluwer.com

How to cite this article: Haimovich S, Tanvir T. A mini-review of office hysteroscopic techniques for endometrial tissue sampling in postmenopausal bleeding. J Mid-life Health 2021;12:21-9.

Access this article online	
Quick Response Code: 	Website: www.jmidlifehealth.org
	DOI: 10.4103/jmh.jmh_42_21

Postmenopausal women carry a higher risk of inadequate endometrial tissue for sampling (ETS).^[13] The inadequacy can be overcome by selecting an endometrial sampling technique where a large tissue sample is obtained for histology and has good sensitivity and specificity for both focal and global lesions.^[14,15] The other aspects of being looked at are the risk or complications associated with the technique, patient's comfort and satisfaction, cost of the sampling technique, and the surgeon's expertise.^[12,16] Office hysteroscopy (OH) has made it possible to overcome these challenges and allows targeted biopsies. This review aims to describe the techniques of OH available for ETS in women with PMB and to concur their diagnostic accuracy with the histology.

WHY IS THIS REVIEW UNDERTAKEN?

This review helps to explore the available OH techniques for adequate ETS for histology in women with PMB. OH procedures are proven beyond doubt to be a success without anesthesia. Nevertheless, even today, dilation and curettage (D & C) is preferred under general anesthesia for ETS. Hysteroscopy, as a "Walk-In/Walk-Out" procedure, allows a woman to be a part of the procedure, avoid the use of medications, and enable her to resume activities. It gives a physician a chance to treat her in the same sitting if a benign uterine pathology is identified.

METHODOLOGY

In December 2020, an electronic search was performed of PubMed, MEDLINE, and Cochrane Library to search for articles on techniques of OH biopsy in postmenopausal women from 2010 to 2020. Relevant studies were included were various office hysteroscopic techniques using 5 Fr scissors, biopsy forceps, crocodile forceps, cup forceps, bipolar electrode, in-office tissue removal system (morcellator), flexible hysteroscope, or mini-resectoscope used for ETS in PMB. Standard reference used was an adequate endometrial tissue sample for histology. We excluded studies where only diagnostic OH was performed, followed by D & C or ETS using blind methods. We used the following keywords or a combination: postmenopausal bleeding, targeted biopsy, vaginoscopy, office or outpatient hysteroscopy, punch biopsy, grasp technique, biopsy with scissors and crocodile forceps, biopsy with a bipolar electrode, tissue removal system, hysteroscopic morcellator, mini-resectoscope, endometrial tissue adequacy, abnormal uterine bleeding, pain scores, discomfort, patient satisfaction.

DISCUSSION

The endometrium is biopsied for the knowledge of the uterus' function and the presence of a disease. The endometrium of postmenopausal women contains only the basalis layer.^[17,18] A detailed evaluation of the uterine cavity under direct vision is essential to exclude the cause of PMB, especially premalignant and malignant lesions.^[19]

VAGINOSCOPY TECHNIQUE

The technique of vaginoscopy is by the introduction of the hysteroscope into the vagina. The vagina is distended like a cavity by introducing normal saline via the inlet of the hysteroscope. With gentle side-to-side movements, the vagina is inspected for atrophy or other vaginal lesions. Advantages of vaginoscopy are as follows: (1) it is possible in the office setting, (2) it avoids the use of vaginal speculum or cervical tenaculum, (3) it allows a complete inspection of the vagina and external cervix,^[20] (4) it facilitates entry of hysteroscope into the uterine cavity, and is found to be more tolerable than the traditional method.^[21] Vaginoscopy allows a comfortable ergonomic position to the surgeon and allows a direct visualization to the assistant and nurse.^[22]

CERVICAL NEGOTIATION

The limitation of OH in postmenopausal women is cervical stenosis.^[23] The use of cervical priming agents such as misoprostol and vaginal dinoprostone was found to help in pain reduction but has adverse effects such as abdominal cramps, nausea, diarrhea, and fever.^[24] In a recent randomized trial, the passage of hysteroscope was easier with the use of preprocedural vaginal dinoprostone. The use is limited due to the high cost of medicine, the subjectivity in reporting pain perception, and the level of difficulty in the hysteroscope passage.^[25] A meta-analysis on the use of vaginal prostaglandin in OH showed no reduction in failure rates.^[26] The use of local anesthesia has not found to reduce the incidence of vasovagal attacks, though the paracervical and intracervical blocks have shown to be effective in significant pain reduction and are to be considered routinely in postmenopausal women.^[27,28] The use of a miniature hysteroscope and the technique of vaginoscopy have made it possible to pass hysteroscope through the cervical os by reducing the patient's discomfort.^[29,30]

DISTENTION MEDIA

The choice of distention media depends on its availability, image quality, and operative procedure. Normal saline solution is cheap, easily available, gives a clear vision, and allows bipolar energy in operative procedures. The

OH is completed quicker with the use of normal saline. CO₂ may be used as a distention medium, but the image is unsatisfactory due to the production of bubbles and bleeding and does not wash them out, as with normal saline.^[28] In OH procedures, electronic fluid management systems give a constant clear image, maintain the uterine cavity's distension, and control the distension pressure. It is best to keep the distension pressures below 100 mmHg to avoid spilling the malignant cells via the fallopian tubes into the peritoneal cavity.^[31,32]

ENDOMETRIAL SAMPLING WITH HYSTEROSCOPY USING 5 FR INSTRUMENTS

Miniature-sized hysteroscope varies from 2 to 2.9 mm, with outer sheath varying from 4 to 5 mm. The use of a smaller diameter hysteroscope has been found to reduce patient discomfort.^[28] The oval-shaped hysteroscope allows easy negotiation via the cervical canal and the internal os, and studies have found a significant reduction in patient discomfort.^[33] The diagnostic accuracy of hysteroscopy is improved by targeted endometrial biopsy sampling, yielding a sensitivity of 97.5% and a specificity of 100% [Figure 1].^[34]

Punch biopsy

A punch biopsy is a standard technique, where a 5 Fr biopsy forceps is introduced through the working channel of the hysteroscope. The forceps are kept close to the hysteroscope, jaws are opened, endometrial tissue is grasped, and jaws are kept closed. The forceps holding the tissue are retracted through the working channel, while the hysteroscope remains in the uterine cavity. The limitation of this technique is the small volume of tissue obtained for histological analysis. It is recommended to take multiple punch biopsies from various endometrium areas, both abnormal and normal.^[19]

Grasp biopsy

This technique of grasp biopsy was introduced by Bettocchi in 2002 to obtain a larger amount of endometrial tissue for histological analysis. A 5 Fr alligator forceps is introduced through the working channel, and jaws are opened and kept parallel to the site to be biopsied on the endometrium. The open jaws are advanced and push the tissue parallel forward for about 0.5–1 cm, without coming in contact with the myometrium, to avoid any pain stimuli. Now, the jaws are closed, holding the tissue, and the complete hysteroscope with the forceps *in situ* is brought out. The length of the tissue obtained, if done correctly, with alligator forceps is about 5 mm and with biopsy forceps is 2.5 mm. Random endometrial biopsies are advocated to improve the sensitivity and specificity of the diagnostic method [Figure 2].^[35-37]

Biopsy using scissors or bipolar electrode

More definite cuts are possible with the use of 5 Fr scissors or bipolar electrodes. Their use has been specified in cases of atrophic endometrium, when there is difficulty in obtaining tissue sample using punch or grasp technique. A scissors or bipolar electrode is guided parallel to the target area for biopsy. Precise cuts are made, avoiding going deep into the myometrium, and the tissue sample is retrieved by grasping with the alligator forceps [Figure 3].^[38]

The grasp technique described above in Sections "Grasp biopsy and Biopsy using scissors or bipolar electrode" is retrospectively studied and found to have 100% diagnostic accuracy for EC, especially of endometrioid type. They also compared with Novak's biopsy and found the hysteroscopic grasp technique superior in the diagnostic accuracy of both histology and tumor type in endometrioid cancer cases. This study's limitations are its retrospective analysis, OH performed only by experienced surgeons, and to add, the armamentarium and training availability in certain parts of the world.^[38]

A recent prospective study evaluated the accuracy of OH using the punch or grasp technique for ETS for EH. The correlation of hysteroscopy with histological diagnosis is high. The number of cases of EC was too low to correlate in this study [Table 1].^[39]

A multicenter, single-blinded randomized trial compared three biopsy forceps for hysteroscopic-guided targeted biopsy in 75 postmenopausal women, and found lower pain scores and wider biopsy with more tissue available for histology with alligator and snake forceps compared to spoon forceps.^[47]

The above techniques are cost-effective and often under-utilized. Some reasons for this could be inadequate training in OH, leading to inadequate technique with insufficient sample for histopathology, and many a time an anxious patient.^[38]

CHROMOHYSTEROSCOPY

5 ml of 5% methylene blue dye (MBD) is injected via the inlet of the hysteroscope, followed by the reintroduction of distention media after 5 min to wash out the endometrial cavity.^[48] Multiple targeted biopsies are obtained from MBD-stained and unstained areas. There is no statistical difference in the histopathological results on following ETS.^[49]

ENDOMETRIAL SAMPLING WITH TISSUE REMOVAL SYSTEM

Hysteroscopic tissue removal system (HTRS) works on

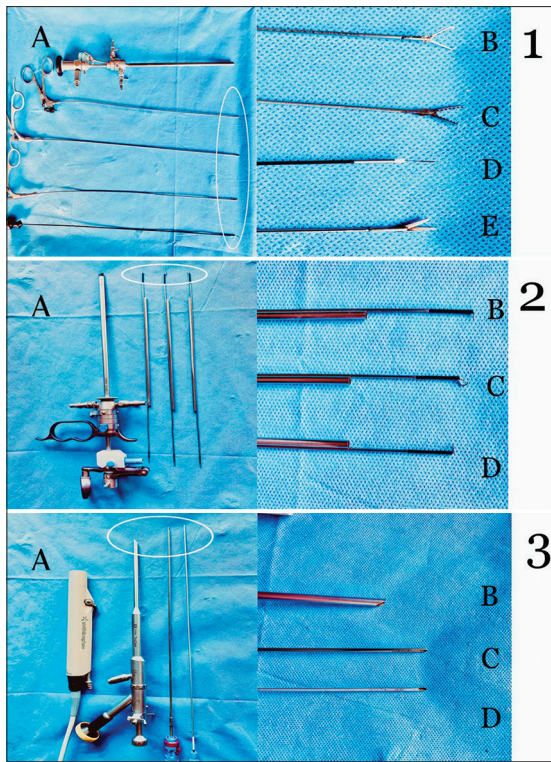


Figure 1: (A) 5 mm office hysteroscope; (B) 5 Fr tenaculum; (C) 5 Fr alligator forceps; (D) 5 Fr bipolar electrode; (E) 5 Fr scissors. 2: (A) 14.9 Fr gubini resectoscope; (B) reusable bipolar loop large; (C) reusable knife; (D) reusable loop electrode straight. 3: (A) TruClear™ handpiece; (B) TruClear™ Elite 6 mm hysteroscope; (C and D) TruClear™ soft tissue shaver mini

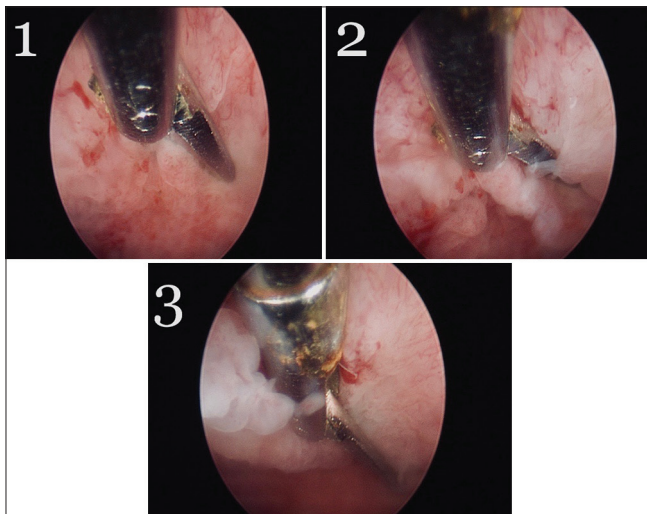


Figure 3: Biopsy using a scissors. 1: Introduction of the scissors; 2: Jaws are opened; 3: Precise cuts are made parallel to the tissue and tissue brought out with an alligator forceps

the principle of suction and aspiration. The cutting blade window is placed in contact with the pathology, and the tissue is cut and aspirated at the same time. It offers many advantages over conventional resection, such as reduced operative time, no use of electric energy, saline

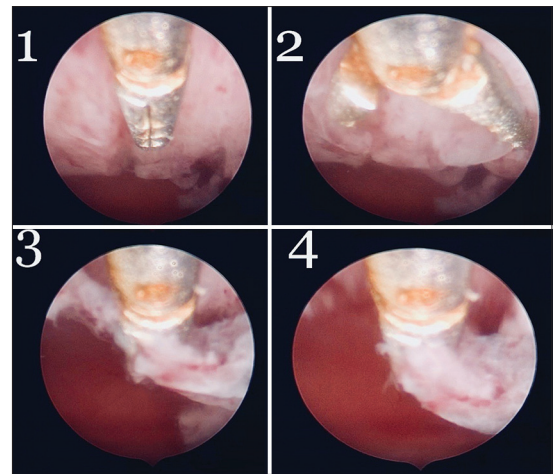


Figure 2: Grasp technique. 1: Introduction of the alligator forceps; 2: Jaws are opened; 3: Forceps is advanced up to 0.5–1 cm; 4: Tissue is brought out along with the instrument

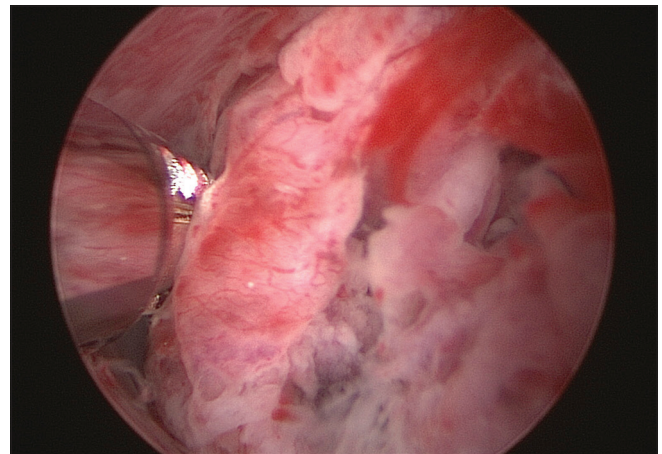


Figure 4: Biopsy with TruClear™ Elite using a soft tissue shaver mini

use, single or fewer insertions, a vision not impeded by air bubbles or tissue chips, and complete tissue available for histology [Figure 1].

Most HTRS' structural design consists of a power control unit, foot switch, hand-piece, hysteroscope, cutting blades, fluid management system, and software.^[50] TruClear (previously Smith & Nephew, now Medtronic), MyoSure LITE and Omni Hysteroscope (Hologic Inc.), Integrated Bigatti Shaver (Storz), and Symphion system (Boston Scientific, Minerva Surgical) are the available office HTRSs.^[51] Many gynecologists have reported HTRS' benefits such as shorter operation time, higher total resection rate, and higher patient acceptability.^[52] In India, only TruClear is available.

TruClear 5C is a fiberoptic system and works with a zero-degree scope using the disposable 2.9 mm INCISOR™/Ultra Mini with a 5 mm cutting window at one end attached to a reusable hand-piece with

Table 1: Sensitivity, specificity and diagnostic accuracy of hysteroscopic-guided biopsy for endometrial hyperplasia and endometrial cancer

Author	Endometrial sampling method	Biopsy technique	Type of study	n (number of participants)	Time frame	Sensitivity (%)	Specificity (%)	Diagnostic accuracy (%)
Clark <i>et al.</i> ^[40]	Hysteroscopy	Various	Systemic review	26,346	2002	86.4	99.2	-
Garuti <i>et al.</i> ^[41]	Hysteroscopy	Targeted biopsy	Retrospective multicenter Italian study	984	2012-2018	76.2	52.8	75.3
Garuti <i>et al.</i> ^[41]	Hysteroscopy	Hysteroscopic view for diagnosing endometrial cancer	Retrospective multicenter Italian study	984	2012-2018	54.2	47.2	54
Ianieri <i>et al.</i> ^[42]	Hysteroscopy	Hysteroscopic risk scoring based the hysteroscopic view	Retrospective study	435	-	95.4	98.2	-
Di Spiezio Sardo <i>et al.</i> ^[38]	Hysteroscopy	Grasp technique	Retrospective cross-sectional study	129	2015-2018	100 (for G1 endometrioid cancer)	97 (for G1 endometrioid cancer)	100
De Franciscis <i>et al.</i> ^[39]	Hysteroscopy	Punch or grasp biopsy	Prospective cohort study	92	2018	97.9 for EH 100 EC	39.5 for EH 100 for EC	100 for EC
Sarvi <i>et al.</i> ^[43]	Hysteroscopy	Targeted biopsy	Cross-sectional study	67	2014-15	100	97	-
Giannella <i>et al.</i> ^[44]	Hysteroscopy biopsy versus hysteroscopic resection versus D and C	Targeted biopsy versus resection versus D and C	Retrospective observational study	75	2000-2017	-	-	19.5% risk of underestimation of endometrial cancer in a diagnosed case of atypical endometrial hyperplasia, targeted biopsy whereas hysteroscopic resection is only 11.6% (lowest) and D and C is 35.3% (highest)*
Omar <i>et al.</i> ^[45]	Hysteroscopy	Targeted biopsy	Multicenter retrospective study	189	2014-16	85.4	96.1	-
Rosenblatt <i>et al.</i> ^[46]	Hysteroscopy	Myosure lite	Prospective pilot study (<i>in vitro</i> study)	7	2015-2016	-	-	100

EC: Endometrial cancer; EH: Endometrial hyperplasia; * Therefore we understand that hysteroscopic resection has the highest rate of detection for endometrial cancer and D & C has the lowest

two connectors; one to the motor unit and second to the suction bottle with a collection bag. The overall diameter of TruClear 5C is 5.6 mm, and the optic size is 0.8 mm.^[53] The mechanism of action is rotation and reciprocation [Figure 4]. TruClear Elite comes with a rod lens optic with an overall diameter of 6 mm and an

optic size of 1.9 mm. The other features are similar to TruClear 5C.

The MyoSure LITE and Omni HTRS are hand-held rod lens systems with a zero-degree hysteroscope and a disposable 4.0-mm cutting device with an overall diameter with an outer sheath of 6.25 mm. The

optic size is 2 mm. The mechanical drive assembly connects to a shaft of 4 mm diameter that inserts the cutting blade. The mechanism of action is rotation and reciprocation.^[46]

The mini-Bigatti Shaver (IBS) is a rod lens system with a 6-degree optics. The overall diameter is 6.3 mm and inserts a reusable cutting device of size 4.5 mm and has an action of rotation.^[54]

Franchini *et al.* demonstrated that despite tissue fragmentation, the adequate tissue for histology is obtained using HTRS in the removal of polyps.^[55]

Rosenblatt *et al.* found that the specimen quality and volume of ETS were better with MyoSure LITE than conventional curettage.^[46]

VISUAL TARGETED OR BLIND BIOPSY

In postmenopausal women, there is a serious concern of malignancy of the endometrium and the endocervical canal by the physician, and hence, most prefer operating room (OR) hysteroscopies in this age group for a D & C.^[56,57] Where focal lesions are present, it would be agree that targeted biopsies are acceptable. However, in generalized hyperplasia cases, some authors propose resection to get a large amount of tissue, up to a depth of 5 mm.^[37] With newer technologies, increased availability of miniaturized instruments such as mini-resectoscopes and HTRS, the likelihood of OH guided visual D & C biopsy has a higher chance of replacing blind D & C soon. The cost-effectiveness of OH is also well demonstrated.^[58,59]

BLIND BIOPSIES

The sensitivity and specificity of Pipelle biopsy for detecting EC and atypical hyperplasia are 99.6% and 98%–100%.^[60] Cervical stenosis and inadequate sample in cases of endometrial atrophy were the limitations of the Pipelle biopsy.^[40] The pooled likelihood ratio of a positive test for EC following Pipelle biopsy was 64.6 (95% confidence interval [CI], 22.3–187.1) and 0.1 (95% CI, 0.04–0.28) for a negative test.

The use of Pipelle, samples only 4.2% of the uterine cavity. The value of Pipelle is only when the result is positive, and a negative result does not rule out pathology in the cavity, which might be missed as Pipelle is a blind procedure like D & C, and if symptoms persist, it should be further investigated.^[40,61]

Blind D & C in the OR has been found to miss nearly 10% of EC resulting in false-negative diagnosis.^[62-64] In 60% of cases, less than half of the uterine cavity is curetted, and a high risk of undiagnosed EC (32.7%) following D & C is found in a diagnosed case of atypical EH.^[65,66] D & C has a high failure rate of 11% in postmenopausal women.^[67]

VISUAL-GUIDED BIOPSY

Hysteroscopy is the gold standard for the evaluation of the uterine cavity.^[68] Hysteroscopy has a high diagnostic accuracy for EC but only moderate for EH. In the case of EC, a positive hysteroscopy had a pooled LR of 62.8 (95% CI 52.8–74.6), while a negative hysteroscopy had a pooled LR of 0.15 (95% CI 0.13–0.18).^[40] In a randomized trial, the pre/malignancy rate detection was 6% following hysteroscopic-guided biopsy in women with recurrent PMB, after the initial blind endometrial biopsy report was benign.^[69] Smith *et al.* found that 1 in 4 causes of recurrent PMB following blind biopsy is an EPs. The technique of hysteroscopic-guided biopsy is not described in the study.^[70]

Garuti *et al.* evaluated various ETS techniques (5 Fr instruments, 16 Fr mini-resectoscope, or 26–27 Fr resectoscope). Although the hysteroscopic image was able to differentiate between EC and EH, unfortunately, the operator's opinion regarding the hysteroscopic view findings varied considerably in different centers, causing a limitation concerning hysteroscopic imaging due to lack of interobserver standardization.^[41] An individual sensitivity, specificity, and accuracy rate of individual techniques used for ETS was not available [Table 1]. We understand from this study that there was no statistical difference between the various biopsy techniques and that inpatient hysteroscopy in the operating theater had higher chances of correct diagnosis of EC than the OH. However, we do not know how many women were sampled with each technique in OH or inpatient. However, hysteroscopic-guided target biopsy correlated with the correct diagnosis of EC.^[41]

The hysteroscopic risk scoring system for evaluating endometrial pathology is proposed based on evaluating all videos recorded of diagnostic hysteroscopy before the biopsy, and the morphological endometrial pathology was noted [Table 1]. The positive predictive values and negative predictive values, respectively, were 76.8% and 80% for Normal endometrium (NE), 62% and 73.5% for EH, 32.7% and 97% for Atypical endometrial hyperplasia (AEH), and 85.7% and 99.5% for adenocarcinoma. In contrast to the above study, the accuracy of the scoring system is much higher for EC.^[42]

Another cross-sectional study gives high diagnostic accuracy of hysteroscopic-guided targeted biopsy for detecting carcinoma. The number of participants is low to conclude on effectiveness of hysteroscopy-targeted biopsy, and there is no comparison in the various techniques used for ETS^[43] [Table 1].

The overall failure rate of hysteroscopy is 3.6%.^[64] Capmas *et al.*, in their retrospective observational study

of OH in 2402 women, found a failure rate of 9.5%, and more with advancing age.^[23] However, interestingly, Bettocchi *et al.* reported the success of OH to be 93.9% among a total of 31,025 women and were successfully able to manage cervical stenosis in 98.5% of cases. This is feasible due to the recent advancement in technique, technicalities, and miniaturized instruments used.^[71]

INSUFFICIENT SAMPLE

In postmenopausal women, the average rate of an insufficient sample with blind sampling techniques is 31%. The reasons for low samples include cervical stenosis, uterine prolapse, focal endometrial pathology (e.g., uterine polyps and submucosal fibroids), and endometrial atrophy.^[16,67] An inadequate sample for histopathological diagnosis sometimes leaves the clinician unsure whether to proceed with other invasive testing or not, with a fear of missing cancer.^[55]

Among postmenopausal women with insufficient endometrial sampling by blind biopsies, the rate of significant endometrial pathology on further evaluation was 6% and endometrial (pre) cancer was found in 7%.^[16,60]

The updated NICE guidelines support OH as a first-line diagnostic tool for abnormal uterine bleeding. They propose a one-stop clinic at primary care and believe that offering hysteroscopy increases cost but is an offset to the reduced number of ultrasounds and follow-up visits.^[28,72]

Hence, we can safely conclude that hysteroscopic-guided biopsy is superior to blind procedures.

COMPLICATIONS

There is a shallow risk of complication, 0.5%, with OH using the vaginoscopic technique.^[23] Diagnostic hysteroscopy in cases of EC is controversial, with conflicting results from various studies. The International Federation of Gynecology and Obstetrics for EC does not include the peritoneal cytology results for tumor staging. Recent studies show that advanced and safe instruments with low intrauterine pressures of <100 mmHg during OH do not increase the rate of positive peritoneal cytology.^[73]

CONCLUSION

This review shows that the grasp technique has a high accuracy for endometrioid cancer, and HTRS is promising. Further, the hysteroscopic view has a fair accuracy in differentiating EH from EC. This review highlights the need to evaluate different OH techniques

used for endometrial sampling in postmenopausal women, and it could replace blind biopsies.

Financial support and sponsorship

Nil.

Conflicts of interest

There are no conflicts of interest.

REFERENCES

1. ESHRE Capri Workshop Group, Collins J, Crosignani PG. Endometrial bleeding. *Hum Reprod Update* 2007;13:421-31.
2. van Hanegem N, Breijer MC, Khan KS, Clark TJ, Burger MP, Mol BW, *et al.* Diagnostic evaluation of the endometrium in postmenopausal bleeding: An evidence-based approach. *Maturitas* 2011;68:155-64.
3. Vitale SG, Capriglione S, Zito G, Lopez S, Gulino FA, Di Guardo F, *et al.* Management of endometrial, ovarian and cervical cancer in the elderly: Current approach to a challenging condition. *Arch Gynecol Obstet* 2019;299:299-315.
4. van Doorn HC, Opmeer BC, Jitze Duk M, Kruitwagen RF, Dijkhuizen FP, Mol BW. The relation between age, time since menopause, and endometrial cancer in women with postmenopausal bleeding. *Int J Gynecol Cancer* 2007;17:1118-23.
5. Schindler AE, Schmidt G. Post-menopausal bleeding: A study of more than 1000 cases. *Maturitas* 1980;2:269-74.
6. Randelzhofer B, Prömpeler HJ, Sauerbrei W, Madjar H, Emons G. Value of sonomorphological criteria of the endometrium in women with postmenopausal bleeding: A multivariate analysis. *Ultrasound Obstet Gynecol* 2002;19:62-8.
7. Mantalenakis SJ, Papapostolou MG. Genital bleeding in women aged 50 and over. *Int Surg* 1977;62:103-5.
8. Critchley HO, Warner P, Lee AJ, Brechin S, Guise J, Graham B. Evaluation of abnormal uterine bleeding: Comparison of three outpatient procedures within cohorts defined by age and menopausal status. *Health Technol Assess* 2004;8:iii-iv, 1-139.
9. Burbos N, Musonda P, Crocker SG, Morris EP, Nieto JJ, Duncan TJ. Management of postmenopausal women with vaginal bleeding when the endometrium can not be visualized. *Acta Obstet Gynecol Scand* 2012;91:686-91.
10. Breijer MC, Timmermans A, van Doorn HC, Mol BW, Opmeer BC. Diagnostic strategies for postmenopausal bleeding. *Obstet Gynecol Int* 2010;2010:850812.
11. ACOG Committee Opinion No. 734: The role of transvaginal ultrasonography in evaluating the endometrium of women with postmenopausal bleeding. *Obstet Gynecol* 2018;131:e124-9.
12. Dijkhuizen FP, Mol BW, Brölmann HA, Heintz AP. The accuracy of endometrial sampling in the diagnosis of patients with endometrial carcinoma and hyperplasia: A meta-analysis. *Cancer* 2000;89:1765-72.
13. Aue-Aungkul A, Kleebkaow P, Kietpeerakool C. Incidence and risk factors for insufficient endometrial tissue from endometrial sampling. *Int J Womens Health* 2018;10:453-7.
14. Adambekov S, Goughnour SL, Mansuria S, Donnellan N, Elishaev E, Villanueva HJ, *et al.* Patient and provider factors associated with endometrial Pipelle sampling failure. *Gynecol Oncol* 2017;144:324-8.
15. Kandil D, Yang X, Stockl T, Liu Y. Clinical outcomes of patients with insufficient sample from endometrial biopsy or curettage. *Int J Gynecol Pathol* 2014;33:500-6.
16. Narice BF, Delaney B, Dickson JM. Endometrial sampling in low-risk patients with abnormal uterine bleeding: A systematic

- review and meta-synthesis. *BMC Fam Pract* 2018;19:135.
17. Valentijn AJ, Palial K, Al-Lamee H, Tempest N, Drury J, Von Zglinicki T, *et al.* SSEA-1 isolates human endometrial basal glandular epithelial cells: Phenotypic and functional characterization and implications in the pathogenesis of endometriosis. *Hum Reprod* 2013;28:2695-708.
 18. Tempest N, Baker AM, Wright NA, Hapangama DK. Does human endometrial LGR5 gene expression suggest the existence of another hormonally regulated epithelial stem cell niche? *Hum Reprod* 2018;33:1052-62.
 19. Fagioli R, Vitagliano A, Carugno J, Castellano G, De Angelis MC, Di Spiezio Sardo A. Hysteroscopy in postmenopause: From diagnosis to the management of intrauterine pathologies. *Climacteric* 2020;23:360-8.
 20. Singh AC. MASTERCLASS: Vaginoscopy in Practice. Available from: <https://www.mdedge.com/obgyn/article/50867/vaginoscopy-practice>. [Last accessed on 2021 Dec 16].
 21. Miller CE. MASTERCLASS: Vaginoscopy's Approach to Hysteroscopy. Available from: <https://www.mdedge.com/obgyn/article/50867/vaginoscopy-practice>. [Last accessed on 2021 Dec 16].
 22. Heredia F, Donetch G, Escalona J, Hinostroza M. Single-port/pneumovagina technique for two further applications. *J Minim Invasive Gynecol* 2020;27:807-8.
 23. Capmas P, Pourcelot AG, Giral E, Fedida D, Fernandez H. Office hysteroscopy: A report of 2402 cases. *J Gynecol Obstet Biol Reprod (Paris)* 2016;45:445-50.
 24. Abulnour AE, Mohamed ME, Khalaf WM, Tarek SA. Dinoprostone versus misoprostol for cervical ripening before diagnostic hysteroscopy in nulliparous women: A randomized controlled trial. *Egypt J Hosp Med* 2018;71:2287-93.
 25. Samy A, Abbas AM, Rashwan AS, Talaat B, Eissa AI, Metwally AA, *et al.* Vaginal dinoprostone in reducing pain perception during diagnostic office hysteroscopy in postmenopausal women: A randomized, double-blind, placebo-controlled trial. *J Minim Invasive Gynecol* 2020;27:847-53.
 26. Cooper NA, Smith P, Khan KS, Clark TJ. Does cervical preparation before outpatient hysteroscopy reduce women's pain experience? A systematic review. *BJOG* 2011;118:1292-301.
 27. Lukes AS, Roy KH, Presthus JB, Diamond MP, Berman JM, Konsker KA. Randomized comparative trial of cervical block protocols for pain management during hysteroscopic removal of polyps and myomas. *Int J Womens Health* 2015;7:833-9.
 28. RCOG - BSGE Joint Guideline.No. 59. Hysteroscopy, Best Practice in Outpatient; 2011.
 29. Smith PP, Kolhe S, O'Connor S, Clark TJ. Vaginoscopy against standard treatment: A randomised controlled trial. *BJOG* 2019;126:891-9.
 30. Bettocchi S, Nappi L, Ceci O, Pontrelli G, Pinto L, Selvaggi L. Hysteroscopy and menopause: Past and future. *Curr Opin Obstet Gynecol* 2005;17:366-75.
 31. Vitale SG, Bruni S, Chiofalo B, Riemma G, Lasmar RB. Updates in-office hysteroscopy: A practical Decalogue to perform a correct procedure. *Updates Surg* 2020;72:967-76.
 32. Polyzos NP, Mauri D, Tsioras S, Messini CI, Valachis A, Messinis IE. Intraoperative dissemination of endometrial cancer cells after hysteroscopy: A systematic review and meta-analysis. *Int J Gynecol Cancer* 2010;20:261-7.
 33. Di Spiezio Sardo A, Calagna G, Di Carlo C. Tips and tricks in-office hysteroscopy. *Gynecol Minim Invasive Ther* 2015;4:3-7.
 34. Elfayomy AK, Habib FA, Elkablawy MA. Role of hysteroscopy in the detection of endometrial pathologies in women presenting with postmenopausal bleeding and thickened endometrium. *Arch Gynecol Obstet* 2012;285:839-43.
 35. Luerti M, Vitagliano A, Di Spiezio Sardo A, Angioni S, Garuti G, De Angelis C, *et al.* Effectiveness of hysteroscopic techniques for endometrial polyp removal: The Italian multicenter trial. *J Minim Invasive Gynecol* 2019;26:1169-76.
 36. Sarkar P, Mikhail E, Schickler R, Plosker S, Imudia AN. Optimal order of successive office hysteroscopy and endometrial biopsy for the evaluation of abnormal uterine bleeding: A randomized controlled trial. *Obstet Gynecol* 2017;130:565-72.
 37. Nappi C, Di Spiezio Sardo A. State-of-the-Art Hysteroscopic Approaches to Pathologies of the Genital Tract. Tuttingen: EndoPress; 2014.
 38. Di Spiezio Sardo A, De Angelis MC, Della Corte L, Carugno J, Zizolfi B, Guadagno E, *et al.* Should endometrial biopsy under direct hysteroscopic visualization using the grasp technique become the new gold standard for the preoperative evaluation of the patient with endometrial cancer? *Gynecol Oncol* 2020;158:347-53.
 39. De Franciscis P, Riemma G, Schiattarella A, Cobellis L, Guadagno M, Vitale SG, *et al.* Concordance between the hysteroscopic diagnosis of endometrial hyperplasia and histopathological examination. *Diagnostics (Basel)* 2019;9:142.
 40. Clark TJ, Mann CH, Shah N, Khan KS, Song F, Gupta JK. Accuracy of outpatient endometrial biopsy in the diagnosis of endometrial cancer: A systematic quantitative review. *BJOG* 2002;109:313-21.
 41. Giancarlo G, Stefano A, Liliana M, Stefano C, Luca M, Federica S, *et al.* Hysteroscopic view with targeted biopsy in the assessment of endometrial carcinoma. What is the rate of underestimated diagnosis? The results of a multicenter Italian trial. *Gynecol Surg* 2020;17:10.
 42. Ianieri MM, Staniscia T, Pontrelli G, Di Spiezio Sardo A, Manzi FS, Recchi M, *et al.* A new hysteroscopic risk scoring system for diagnosing endometrial hyperplasia and adenocarcinoma. *J Minim Invasive Gynecol* 2016;23:712-8.
 43. Sarvi F, Alleyassin A, Aghahosseini M, Ghasemi M, Gity S. Hysteroscopy: A necessary method for detecting uterine pathologies in post-menopausal women with abnormal uterine bleeding or increased endometrial thickness. *Turk J Obstet Gynecol* 2016;13:183-8.
 44. Giannella L, Delli Carpini G, Sopracordevole F, Papiccio M, Serri M, Giorda G, *et al.* Atypical endometrial hyperplasia and unexpected cancers at final histology: A study on endometrial sampling methods and risk factors. *Diagnostics (Basel)* 2020;10:474.
 45. Omar AA, Seham A, Al-Kharabsheh AM, Alshara E, Sindiani AM, Hamdan O, *et al.* Clinical and sonographic evaluation of postmenopausal bleeding (PMB) followed by diagnostic and/or therapeutic hysteroscopy and guided biopsy in Jordanian hospitals. *Medicina (Kaunas)* 2020;56:147.
 46. Rosenblatt P, Barcia S, DiSciullo A, Warda H. Improved adequacy of endometrial tissue sampled from postmenopausal women using the MyoSure Lite hysteroscopic tissue removal system versus conventional curettage. *Int J Womens Health* 2017;9:789-94.
 47. Vitale SG, Laganà AS, Caruso S, Garzon S, Vecchio GM, La Rosa VL, Casarin J, Ghezzi F. Comparison of three biopsy forceps for hysteroscopic endometrial biopsy in postmenopausal patients (HYGREB-1): A multicenter, single-blind randomized clinical trial. *Int J Gynaecol Obstet*. 2021 Mar 8. doi: 10.1002/ijgo.13669. Epub ahead of print. PMID: 33686708.
 48. Küçük T, Safali M. "Chromohysteroscopy" for evaluation of

- endometrium in recurrent *in vitro* fertilization failure. *J Assist Reprod Genet* 2008;25:79-82.
49. Alay A, Usta TA, Ozay P, Karadugan O, Ates U. Comparison of two modalities: A novel technique, 'chromohysteroscopy', and blind endometrial sampling for the evaluation of abnormal uterine bleeding. *J Obstet Gynaecol Res* 2014;40:1407-14.
 50. Singh S, Tavakkolizadeh A, Arya A, Compson J. Arthroscopic powered instruments: A review of shavers and burrs. *Orthop Trauma* 2009;23:357-36.
 51. Stoll F, Lecointre L, Meyer N, Faller E, Host A, Hummel M, *et al.* Randomized study comparing a reusable morcellator with a resectoscope in the hysteroscopic treatment of uterine polyps: The RESMO study. *J Minim Invasive Gynecol* 2020;S1553-4650(20)30338-1.
 52. Meulenbroeks D, Hamerlynck TW, Saglam-Kara S, Van Rijssel NK, Van Vliet HA, Schoot BC. Hysteroscopic tissue removal systems: A randomized *in vitro* comparison. *J Minim Invasive Gynecol* 2017;24:159-64.
 53. Ceci O, Franchini M, Cannone R, Giarrè G, Bettocchi S, Fascilla FD, *et al.* Office treatment of large endometrial polyps using truclear 5C: Feasibility and acceptability. *J Obstet Gynaecol Res* 2019;45:626-33.
 54. Bigatti G, Ansari SH, Di W. The 19 Fr. Intrauterine Bigatti Shaver (IBS®): A clinical and technical update. *Facts Views Vis Obgyn* 2018;10:161-164.
 55. Franchini M, Zolfanelli F, Gallorini M, Giarrè G, Fimiani R, Florio P. Hysteroscopic polypectomy in an office setting: Specimens quality assessment for histopathological evaluation. *Eur J Obstet Gynecol Reprod Biol* 2015;189:64-7.
 56. Moawad NS, Santamaria E, Johnson M, Shuster J. Cost-effectiveness of office hysteroscopy for abnormal uterine bleeding *JSLs* 2014;18(3).
 57. Daniele A, Ferrero A, Maggiorotto F, Perrini G, Volpi E, Sismondi P. Suspecting malignancy in endometrial polyps: Value of hysteroscopy. *Tumori* 2013;99:204-9.
 58. Saridogan E, Tilden D, Sykes D, Davis N, Subramanian D. Cost-analysis comparison of outpatient see-and-treat hysteroscopy service with other hysteroscopy service models. *J Minim Invasive Gynecol* 2010;17:518-25.
 59. Salazar CA, Isaacson KB. Office operative hysteroscopy: An update. *J Minim Invasive Gynecol* 2018;25:199-208.
 60. van Doorn HC, Opmeer BC, Burger CW, Duk MJ, Kooi GS, Mol BW, *et al.* Inadequate office endometrial sample requires further evaluation in women with postmenopausal bleeding and abnormal ultrasound results. *Int J Gynaecol Obstet* 2007;99:100-4.
 61. Demirkiran F, Yavuz E, Erenel H, Bese T, Arvas M, Sanioglu C. Which is the best technique for endometrial sampling? Aspiration (pipelle) versus dilatation and curettage (D&C). *Arch Gynecol Obstet* 2012;286:1277-82.
 62. Wang X, Huang Z, Di W, Lin Q. Comparison of D&C and hysterectomy pathologic findings in endometrial cancer patients. *Arch Gynecol Obstet* 2005;272:136-41.
 63. Epstein E, Valentin L. Rebleeding and endometrial growth in women with postmenopausal bleeding and endometrial thickness <5 mm managed by dilatation and curettage or ultrasound follow-up: A randomized controlled study. *Ultrasound Obstet Gynecol* 2001;18:499-504.
 64. Clark TJ, Voit D, Gupta JK, Hyde C, Song F, Khan KS. Accuracy of hysteroscopy in the diagnosis of endometrial cancer and hyperplasia: A systematic quantitative review. *JAMA* 2002;288:1610-21.
 65. Clark TJ, Gupta JK. Endometrial sampling of gynecological pathology. *Obstet Gynaecol* 2002;4:169-74.
 66. Bourdel N, Chauvet P, Tognazza E, Pereira B, Botchorishvili R, Canis M. Sampling in atypical endometrial hyperplasia: Which method results in the lowest underestimation of endometrial cancer? A systematic review and meta-analysis. *J Minim Invasive Gynecol* 2016;23:692-701.
 67. van Hanegem N, Prins MM, Bongers MY, Opmeer BC, Sahota DS, Mol BW, *et al.* The accuracy of endometrial sampling in women with postmenopausal bleeding: A systematic review and meta-analysis. *Eur J Obstet Gynecol Reprod Biol* 2016;197:147-55.
 68. Bakour SH, Timmermans A, Mol BW, Khan KS. Management of women with postmenopausal bleeding: Evidence-based review. *Obstet Gynecol* 2012;14:243-9.
 69. van Hanegem N, Breijer MC, Slockers SA, Zafarmand MH, Geomini P, Catshoek R, *et al.* Diagnostic workup for postmenopausal bleeding: A randomized controlled trial. *BJOG* 2017;124:231-40.
 70. Smith PP, O'Connor S, Gupta J, Clark TJ. Recurrent postmenopausal bleeding: A prospective cohort study. *J Minim Invasive Gynecol* 2014;21:799-803.
 71. Bettocchi S, Bramante S, Bifulco G, Spinelli M, Ceci O, Fascilla FD, *et al.* Challenging the cervix: Strategies to overcome the anatomic impediments to hysteroscopy: Analysis of 31,052 office hysteroscopies. *Fertil Steril* 2016;105:e16-7.
 72. National Institute for Health and Care Excellence. Heavy menstrual bleeding. Quality standard. Available at: <https://www.nice.org.uk/guidance/qs47/resources/heavy-menstrual-bleeding-pdf-2098671748549>. [Last accessed on 02 Feb 2021].
 73. Ribeiro CM, Brito LG, Benetti-Pinto CL, Teixeira JC, Yela DA. Is diagnostic hysteroscopy safe for the investigation of type II endometrial cancer? A retrospective cohort analysis. *J Minim Invasive Gynecol* 2021;S1553-4650(21)00029-7.