



# Surgical Versus Medical Treatment for Diabetic Macular Edema: A Review

Nicolás CRIM <sup>1</sup>; Raúl VELEZ-MONTOYA <sup>1</sup>; Virgilio MORALES-CANTON <sup>1</sup>

1. Retina Department, Asociacion Para Evitar la Ceguera en México, "Hospital Dr. Luis Sanchez Bulnes", IAP. Mexico City, Mexico

## ABSTRACT

We aimed to compare the results of pars plana vitrectomy (PPV) with internal limiting membrane (ILM) peeling, an alternative therapeutic strategy, with those of medical treatment for chronic macular edema. We conducted a review of the literature on the microscopic, anatomical, and functional reasons for performing PPV with ILM peeling in patients with diabetic macular edema (DME). We searched the PubMed database for articles published between 2000 and 2017. We used the medical subject heading "vitrectomy diabetic macular edema" and the keywords "diabetic macular edema", "internal limiting membrane peeling", "pars plana vitrectomy", "diabetic retinopathy", and "optical coherence tomography". Analysis of the literature revealed that cytokines, vascular endothelial growth factor, reactive oxygen species (ROS), and advanced glycation end-products (AGEs) play a unique role in DME. The vitreous cavity serves as a physiological reservoir for all inflammatory molecules. AGE receptors are localized at the footplates of Müller cells and the external limiting membrane (ELM). The footplates of Müller cells are in contact with the ILM, which suggests that they might be responsible for the structural damage (i.e., thickening) observed in the ILM of patients with DME. Therefore, PPV could allow a reduction of cytokines and pro-inflammatory molecules from the vitreous cavity. ILM peeling could eliminate not only the physical traction of a thickened structure, but also the natural reservoir of AGEs, ROS, and inflammatory molecules. PPV with ILM peeling is a surgical option that should be considered when treating patients with chronic DME.

## KEY WORDS

Diabetic Retinopathy; Vitrectomy, Diabetic Macular Edema; Optical Coherence Tomography, Internal Limiting Membrane

©2017, Med Hypothesis Discov Innov Ophthalmol.

This is an open-access article distributed under the terms of the Creative Commons Attribution Non-Commercial 3.0 License (CC BY-NC 3.0), which allows users to read, copy, distribute and make derivative works for non-commercial purposes from the material, as long as the author of the original work is cited properly.

## Correspondence to:

Nicolás Crim. Vicente García Torres 46, Delegación Coyoacán, Barrio San Lucas, Mexico City DF, Mexico. Tel: +52 (55) 1084 1400, Fax: +52 (55) 1084 1404; E-mail: [nicolasgrim@hotmail.com](mailto:nicolasgrim@hotmail.com)

## INTRODUCTION

Diabetic macular edema (DME) is one of the most common complications of diabetic retinopathy (DR) and is a frequent cause of sudden impairment of visual acuity (VA). The incidence of DME ranges from 14% to 29% in patients with DR. According to the Wisconsin Epidemiologic Study of Diabetic Retinopathy, the estimated prevalence of DME after 20 years following a diagnosis of diabetes mellitus (DM) is 12%–29% in patients with DM type 1 and 2 [1]. DME represents a

severe threat to public health. The World Health Organization (WHO) Global Report of Diabetes 2016 indicates that Mediterranean East, South East Asia, and the American continent are the most affected regions in the world [2]. The cost of the disease varies according to the country. However, according to data from countries in the European Union, the annual cost is EURO 777 to EURO 7153, depending on the need for different



treatments, such as laser or anti-vascular endothelial growth factor (VEGF) drugs [3].

The aim of this study was to review scientific evidence for considering pars plana vitrectomy (PPV) as a treatment for DME.

## MATERIALS AND METHODS

We conducted a review of the literature about the microscopic, anatomical, and functional reasons supporting the use of PPV with internal limiting membrane (ILM) peeling as a treatment option for DME. We searched the PubMed database for articles published between 2000 and 2017. We used the medical subject heading “pars plana vitrectomy diabetic macular edema” and the keywords “diabetic macular edema,” “internal limiting membrane peeling,” “pars plana vitrectomy,” “diabetic retinopathy,” and “optical coherence tomography.” As inclusion criteria, we used clinical trials, review, systematic review, case reports, clinical studies, and multicenter studies as filters. Exclusion criteria were repeated papers, incomplete information, or missing data. If no statistical analysis of data was reported, we focused on molecular analysis and clinical evidence reported in the surgical management of DME.

## RESULTS

A search was performed in PubMed database, and 190 papers were found with PPV and DME. After filters and key words were applied, 67 papers were retained; however, many of these were discarded because of incomplete data, confusing evidence, or repeated information. We finally selected 22 publications for this review, which are summarized in [Table 1](#).

There is a close association between DME and diabetic metabolic control. A higher level of glycosylated hemoglobin, high systolic blood pressure, and borderline proteinuria are all risk factors for DME [3]. The pathophysiology of this condition is complex, and some aspects are still being debated. The oxidative stress caused by multiple inflammatory cytokines is believed to be a key factor for vascular damage [4]. Chronic hyperglycemia causes oxidative stress by inducing the formation of advanced glycation end-products (AGEs) and non-enzymatic glycosylation of proteins. AGEs can cross-link the amino-termini of proteins, lipids, and DNA, leading to modification of their tertiary structure and function. They can also activate intercellular adhesion molecule-1 (ICAM-1), causing damage to cellular membranes and endothelia by increasing transcription factors, such as nuclear factor kappa B [5]. In addition, alteration in the expression of adhesion molecules and release of pro-inflammatory cytokines induce the

upregulation of other proteins, such as adhesion molecule-1 (E-selectin) and vascular cell adhesion molecule-1 (VCAM-1), which in conjunction with ICAM-1, induce leukostasis and further cell damage [6]. The formation of reactive oxygen species (ROS) has also been implicated in the pathophysiology of DME. ROS cause oxidative damage to the lipid bilayer of cell membranes by lipid peroxidation [7]. Damage to specific cells, such as perivascular pericytes, induces microvessel occlusion and microaneurysm formation. The resulting hemodynamic dysfunction leads to abnormal autoregulation of the retinal blood flow and an imbalance in retinal metabolism homeostasis. The damage exerted on capillary-vessel basement membranes by ROS and AGEs induces an increase in the deposition of extracellular matrix components, which in turn further exacerbate hemodynamic dysfunction, thus impairing autoregulation [8-10].

VEGF is a dimeric glycoprotein that has a fundamental role in pathological angiogenesis. Its concentration in the vitreous is increased exponentially in patients with DR [11]. VEGF-A has six major isoforms (121, 145, 165, 183, 189, and 206) and three main membrane receptors (VEGFR-1, 2, and 3) [5]. In DME, VEGF can induce vasodilation of the retinal vessels, enhance vascular permeability, and activate endothelial cells [6]. VEGF also phosphorylates claudin-1, a protein that is present in the tight junctions of retinal endothelial cells. The protein is then downregulated and delocalized, leading to increased vascular permeability and retinal edema [12, 13].

There is evidence that RD depends not only on the usual diet or glycemic levels, but also on a genetic background that promotes development of diabetes and its complications, and which varies across different populations [14]. Traditionally, DME is classified as focal or diffuse based on leakage patterns on fluorescein angiography (FA). More recently, optical coherence tomography (OCT) is used to provide in-depth information about tissue structure, which is essential for elaborate therapeutic strategies in DME [15]. The classification proposed by Kim et al. in 2006 describes five well-defined patterns of DME by OCT: diffuse retinal thickening, cystoid macular edema, serous retinal detachment (RD) without posterior hyaloidal traction (PHT), PHT without tractional RD, and PHT with RD [16] ([Fig 1 A and B](#)). OCT angiography (OCTA) is a new diagnostic device that allows the theoretical identification of the blood flow through retinal blood vessels [17]. Early reports have shown areas of decreased signal intensity that correlate well with areas of

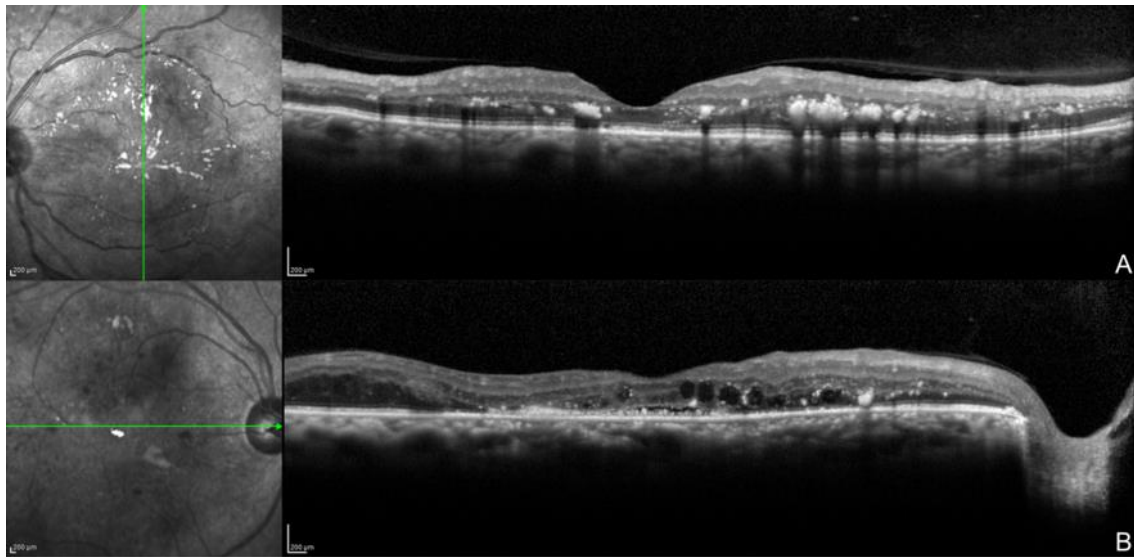


intraretinal fluid accumulation on OCT. Areas of cystoid edema appear entirely devoid of flow with borders where there is no vascular flow surrounding the capillary meshwork [18].

**Table 1:** Summary of the Most Relevant Data Regarding Pars Plana Vitrectomy and Diabetic Macular Edema from 2000 to 2017

Year	Author	Type of Study	Main Outcome
2001	Augustin et al.	Clinical Trial	Oxidative metabolites are able to modulate growth activity via VEGF activity directly
2002	Kumagai et al.	Clinical Trial	ILM peeling accelerates the absorption of edema in more severe DME without change in VA
2005	Holeamp et al.	Case Series	Vitrectomy increases intraocular oxygen tension, which may lead to nuclear cataract formation
2006	Stefánsson et al.	Review	Both laser and vitrectomy treatment help to increase inner retina oxygenation
2009	Bhagat et al.	Review	Combined surgical and medical treatment is the best option to manage DME
2009	Sakamoto et al.	Retrospective	Postoperative photoreceptor status of the fovea is closely related to the final VA
2010	DRCR.Net et al.	Clinical Trial	Vitrectomy performed for DME and vitreomacular traction; retinal thickening was reduced in most eyes
2010	Otani et al.	Case Series	OCT showed that the integrity of the external limiting membrane and inner and outer segments of the photoreceptors were more strongly correlated with VA
2011	Deissler et al.	Experimental	VEGF 165 is mainly responsible for changes in cellular permeability in retinal endothelial cells
2011	Yanyali et al.	Case Series	The integrity of the ELM and IS/OS lines was positively correlated with final visual acuity after PPV
2012	Tamura et al.	Case Series	The ILM is thickened and numerous types of inflammatory cells are attached
2012	Chhablani et al.	Retrospective	Preoperative evaluation of the ELM predicts vision improvement more accurately than the IS/OS junction
2013	Koskela et al.	Case–Control	Elevated IL-6 and IL-8 levels in vitreous, but not in plasma, are evidence favouring local over systemic inflammation in PDR
2013	Yamada et al.	Clinical Trial	Glycemic control may be important for retinal thickness after ocular surgery
2013	Nizawa et al.	Case–Control	PPV either with or without preoperative treatments can significantly improve the BCVA and reduce the central macular thickness MT in patients with diffuse DME
2014	Romano et al.	Retrospective	DME with intraretinal cysts larger than 390 µm should not be treated with vitrectomy with ILM peeling, because this may induce subfoveal atrophy
2015	Kumagai et al.	Clinical Trial	PPV with or without peeling improves long term VA of DME
2015	Bonnin et al.	Case–Control	Vitrectomized eyes are not different in terms of anatomical and visual outcomes in patients with or without tractional DME
2016	Ichiyama et al.	Clinical Trial	Vitrectomy can be a useful treatment option for diffuse DME, particularly for eyes with subretinal fluid
2017	Gonzalez-Salinas et al.	Case–Control	Different VEGF polymorphisms could be related to grades of proliferative DR
2017	Jackson et al.	Systematic Review	Vitrectomy produces structural and functional improvements in select eyes with DME, but the visual gains are not significantly better than with laser or observation.

Abbreviations: Pars plana vitrectomy (PPV); internal limiting membrane (ILM); reactive oxygen species (ROS); advanced glycation end-product (AGE); external limiting membrane (ELM); diabetic macular edema (DME); diabetic retinopathy (DR); visual acuity (VA); diabetes mellitus (DM); World Health Organization (WHO), vascular endothelial growth factor (VEGF); intercellular adhesion molecule-1 (ICAM-1); vascular cell adhesion molecule-1 (VCAM-1); vascular endothelial growth factor receptor (VEGFR); fluorescein angiography (FA); optical coherence tomography (OCT); posterior hyaloidal traction (PHT); optical coherence tomography angiography (OCTA); best-corrected visual acuity (BCVA); gliial fibrillary acid protein (GFAP); inner segments/outer segments (IS/OS)



**Figure 1:** Optical coherence tomography images showing diffuse bilateral diabetic macular edema.

Multiple hard exudates (hyperreflective dots) and vitreous macular adhesion. B. Hard exudates (hyperreflective dots), cystic macular spaces (black cysts), and serous retinal detachment.

Nevertheless, the diagnostic value of this new technology is still debated, since issues such as image artifacts and hard-to-understand changes limit the clinical application of the results.

#### Medical Treatment for DME

Anti-angiogenic drugs that specifically target VEGF are the current standard of care for DME treatment. There are currently two approved anti-VEGF drugs (ranibizumab and aflibercept) and one open-label anti-VEGF drug (bevacizumab), with more drugs to come in the near future (conbercept, bevasiranib, razumab, xlucane, etc.). Several studies sponsored by the National Institutes of Health, such as those conducted by the Diabetic Retinopathy Clinical Research Network (DRCR.net) [19], and studies sponsored by the pharmaceutical industry (RESOLVE, RESTORE, RIDE, RISE, and DAVINCI) demonstrate that, alone or in combination, anti-VEGF drugs are superior to laser, sham treatment, or intravitreal triamcinolone for the treatment of DME, with excellent security profiles [20-22]. However, it is important to highlight that patients with chronic DME will probably develop tachyphylaxis after years of intravitreal injections of anti-VEGF. Moreover, there are many cytokines as important as VEGF in DME [23]. In relapsing or chronic cases of DME, a treatment alternative is the intravitreal implant of dexamethasone. Dexamethasone is five times more powerful than triamcinolone and is more hydrophilic, which allows higher vitreous concentrations [24]. A 6-mm implant

containing 700 mg of dexamethasone is placed in the eye, where the drug is slowly released into the vitreous cavity over a period of 6 months [25-27]. In clinical trials of difficult cases of DME, the implant has demonstrated to be an effective alternative, alone or in combination with anti-VEGF drugs, by improving central macular thickness, best-corrected visual acuity (BCVA), microperimetry results, and electrofunctional test results after treatment [28-31].

#### Surgical Treatment for DME

Inflammatory cytokines, ROS, and AGEs play unique roles in DME. In patients with DR, the vitreous cavity serves as a physiological reservoir to all of the above-mentioned molecules. As the blood-retinal barrier becomes damaged with time, more pro-inflammatory cytokines and growth factors can gain access into this anatomical space. The accumulation of AGEs can destroy the vitreoretinal interface and induce neurovascular damage [5]. Moreover, accumulation of AGEs can also be found in the posterior vitreous cortex and ILM. AGE receptors have been found in the footplates of Müller cells and the external limiting membrane (ELM), suggesting that they might be responsible for the structural damage (thickening) observed in the ILM of patients with DME. Activation of AGEs may induce non-tractional cell-mediated effects on adjacent retinal layers (from ILM to ELM, including the deep retinal capillary plexus) [5]. Finally, the accumulation of AGEs in the posterior vitreous cortex can increase the adhesion of the



posterior vitreous cortex to the ILM. The consequence is a thickened and taut posterior hyaloid cortex, which can be seen on slit lamp examination as a glittering taut membrane, and by FA and OCT imaging, as a firm attachment of the posterior hyaloid to the fovea with diffuse leakage in the macular area [5]. VEGF levels are substantially increased in the vitreous cavity of patients with DR. As retinal hypoxia increases, the concentration of VEGF also increases, inducing retinal neovascularization and capillary vasodilation [32-35].

Following PPV, vitreous oxygen content improves, and VEGF concentration decreases. This can potentially decrease vascular permeability and stimulate vasoconstriction with the concomitant reduction of the blood flow, hindering DME formation [36]. In addition, the peeling of the thickened ILM eliminates physical traction and removes AGEs from the vitreoretinal interface. In some cases, there is an associated epiretinal membrane and/or vitreoretinal traction, which can also be removed. In summary, there is strong evidence supporting the removal of the vitreous, the vitreous cortex, and the ILM in selected cases of DME.

The identification of patients with DME that can possibly benefit from surgery is of uttermost importance [37-39]. A good metabolic control is essential. Patients with low levels of glycosylated hemoglobin have a greater likelihood of improved BCVA after PPV [40]. The integrity of the ELM, the myoid, and ellipsoid zones (interdigitation zone) has been mentioned in several studies as a possible predictive factor of visual improvement [37, 41]. Patients with DME and signs of retinal gliosis are associated with increased expression of glial fibrillary acid protein (GFAP) in Müller cells and astrocytes. GFAP has an essential role in cell adhesion through the cytoskeleton, surface receptors, and extracellular matrix. Surgeons must be aware of large intraretinal cysts and enlarged foveal avascular zones because, as Romano et al. demonstrated, patients with those characteristics have a higher risk of subfoveal atrophy and visual deterioration [42]. The identification of the morphological pattern of DME by OCT, as described by Ichiyama et al., could also be a prognostic factor for visual improvement. Patients with sponge-like diffuse retinal thickening are the least likely to improve BCVA significantly after PPV [43].

#### **Clinical Evidence Supporting PPV as a Treatment Option for DME**

In 2002, Kumagai et al. published the results of PPV in the treatment of DME. The study reported a 90% reduction of DME, with or without ILM peeling. They discussed that ILM removal might accelerate the

resolution of the edema in more severe cases, but no statistical difference in VA was observed [44]. In another study, Kumagai et al. treated patients with non-tractional DME with PPV, dividing the population into two groups: ILM peeling and no ILM peeling. Both groups achieved a statistically significant reduction in central macular thickness during the follow-up. However, the role of ILM peeling was still unclear, since it did not affect the results conclusively [45]. The results were similar to those of the study by Bonnin et al., in which patients with tractional and non-tractional DME were treated with PPV. Both groups had improved BCVA at the end of the follow-up period, but the authors failed to demonstrate any anatomical or functional differences between the two groups [46]. Nizawa et al. explored the effect of PPV in patients with diffuse DME, with or without previous treatments (bevacizumab, triamcinolone, or micropulse laser). BCVA was improved in both groups, and there was no significant difference between them [47]. A study from the DRCR.net reported that 68% of the participants achieved at least a 50% reduction in edema; 38% (95% confidence interval [CI]: 28%–49%) had improved BCVA (more than 10 letters) and 22% had deteriorated BCVA (less than 10 letters). Complications included vitreous hemorrhages, RD, and elevated intraocular pressure (IOP) at low rates [48].

As in any other scenario, PPV for DME patients is not without risk and complications. However, the incidence is similar to any other PPV surgical event. The most frequent intraoperative complication is retinal breaks (7.08%) and iatrogenic tears (0.68%). During the follow-up period, patients can experience cataract formation (2.56%), elevation of the IOP (5.19%), epiretinal membrane development (3.27%), vitreous hemorrhages (2.43%), and neovascular glaucoma (1.06%) [49].

#### **CONCLUSIONS**

In summary, PPV with ILM peeling can be considered a treatment option for chronic DME. The vitreous cavity in patients with DME is rich in cytokines and pro-inflammatory molecules such as VEGF; decreasing their levels could reduce their effects on retinal layers and increase oxygen levels in the vitreous. ILM peeling can not only eliminate physical traction, but can also remove the natural reservoir of AGEs, ROS, and inflammatory molecules. However, PPV is not a risk-free treatment, with retinal breaks and elevation of IOP being the most frequent adverse effects. In future, multicenter clinical trials are needed to understand the microscopic changes that occur in the ILM of patients with diabetes as well as the rate of anatomical and functional success. A



prospective follow-up of those patients should provide further knowledge about DME recurrence.

#### DISCLOSURE

No funding or sponsorship was received for this study. All named authors meet the International Committee of Medical Journal Editors (ICMJE) criteria for authorship for this manuscript, take responsibility for the integrity of the work as a whole, and have given final approval for the version to be published.

#### REFERENCES

1. Klein R, Knudtson MD, Lee KE, Gangnon R, Klein BE. The Wisconsin Epidemiologic Study of Diabetic Retinopathy XXIII: the twenty-five-year incidence of macular edema in persons with type 1 diabetes. *Ophthalmology*. 2009;116(3):497-503. doi: [10.1016/j.ophtha.2008.10.016](https://doi.org/10.1016/j.ophtha.2008.10.016) pmid: [19167079](https://pubmed.ncbi.nlm.nih.gov/19167079/)
2. WHO. Global Report on Diabetes: World Health Organization; 2016 [cited 2017]. Available from: [http://apps.who.int/iris/bitstream/10665/204871/1/9789241565257\\_eng.pdf?ua=1](http://apps.who.int/iris/bitstream/10665/204871/1/9789241565257_eng.pdf?ua=1).
3. Romero-Aroca P, de la Riva-Fernandez S, Valls-Mateu A, Sagarra-Alamo R, Moreno-Ribas A, Soler N, et al. Cost of diabetic retinopathy and macular oedema in a population, an eight year follow up. *BMC Ophthalmol*. 2016;16:136. doi: [10.1186/s12886-016-0318-x](https://doi.org/10.1186/s12886-016-0318-x) pmid: [27491545](https://pubmed.ncbi.nlm.nih.gov/27491545/)
4. Burke SJ, Karlstad MD, Eder AE, Regal KM, Lu D, Burk DH, et al. Pancreatic beta-Cell production of CXCR3 ligands precedes diabetes onset. *Biofactors*. 2016;42(6):703-15. doi: [10.1002/biof.1304](https://doi.org/10.1002/biof.1304) pmid: [27325565](https://pubmed.ncbi.nlm.nih.gov/27325565/)
5. Bhagat N, Grigorian RA, Tutela A, Zarbin MA. Diabetic macular edema: pathogenesis and treatment. *Surv Ophthalmol*. 2009;54(1):1-32. doi: [10.1016/j.survophthal.2008.10.001](https://doi.org/10.1016/j.survophthal.2008.10.001) pmid: [19171208](https://pubmed.ncbi.nlm.nih.gov/19171208/)
6. Koskela UE, Kuusisto SM, Nissinen AE, Savolainen MJ, Liinamaa MJ. High vitreous concentration of IL-6 and IL-8, but not of adhesion molecules in relation to plasma concentrations in proliferative diabetic retinopathy. *Ophthalmic Res*. 2013;49(2):108-14. doi: [10.1159/000342977](https://doi.org/10.1159/000342977) pmid: [23257933](https://pubmed.ncbi.nlm.nih.gov/23257933/)
7. Mishra S, Mishra BB. Study of Lipid Peroxidation, Nitric Oxide End Product, and Trace Element Status in Type 2 Diabetes Mellitus with and without Complications. *Int J Appl Basic Med Res*. 2017;7(2):88-93. doi: [10.4103/2229-516X.205813](https://doi.org/10.4103/2229-516X.205813) pmid: [28584737](https://pubmed.ncbi.nlm.nih.gov/28584737/)
8. Ciulla TA, Amador AG, Zinman B. Diabetic retinopathy and diabetic macular edema: pathophysiology, screening, and novel therapies. *Diabetes Care*. 2003;26(9):2653-64. pmid: [12941734](https://pubmed.ncbi.nlm.nih.gov/12941734/)
9. Ciulla TA, Harris A, Latkany P, Piper HC, Arend O, Garzosi H, et al. Ocular perfusion abnormalities in diabetes. *Acta Ophthalmol Scand*. 2002;80(5):468-77. pmid: [12390156](https://pubmed.ncbi.nlm.nih.gov/12390156/)
10. Paget C, Lecomte M, Ruggiero D, Wiernsperger N, Lagarde M. Modification of enzymatic antioxidants in retinal microvascular cells by glucose or advanced glycation end products. *Free Radic Biol Med*. 1998;25(1):121-9. pmid: [9655530](https://pubmed.ncbi.nlm.nih.gov/9655530/)
11. Duh E, Aiello LP. Vascular endothelial growth factor and diabetes: the agonist versus antagonist paradox. *Diabetes*. 1999;48(10):1899-906. pmid: [10512352](https://pubmed.ncbi.nlm.nih.gov/10512352/)
12. Bazzoni G. Endothelial tight junctions: permeable barriers of the vessel wall. *Thromb Haemost*. 2006;95(1):36-42. pmid: [16543959](https://pubmed.ncbi.nlm.nih.gov/16543959/)
13. Deissler HL, Deissler H, Lang GE. Inhibition of vascular endothelial growth factor (VEGF) is sufficient to completely restore barrier malfunction induced by growth factors in microvascular retinal endothelial cells. *Br J Ophthalmol*. 2011;95(8):1151-6. doi: [10.1136/bjo.2010.192229](https://doi.org/10.1136/bjo.2010.192229) pmid: [21273213](https://pubmed.ncbi.nlm.nih.gov/21273213/)
14. Gonzalez-Salinas R, Garcia-Gutierrez MC, Garcia-Aguirre G, Morales-Canton V, Velez-Montoya R, Soberon-Ventura VR, et al. Evaluation of VEGF gene polymorphisms and proliferative diabetic retinopathy in Mexican population. *Int J Ophthalmol*. 2017;10(1):135-9. doi: [10.18240/ijo.2017.01.22](https://doi.org/10.18240/ijo.2017.01.22) pmid: [28149790](https://pubmed.ncbi.nlm.nih.gov/28149790/)
15. Kawashima H, Mizukawa K, Kiryu J. Factors associated with visual recovery after sub-Tenon injection of triamcinolone acetonide in diabetic macular edema. *Clin Ophthalmol*. 2012;6:1307-14. doi: [10.2147/OPHTH.S34631](https://doi.org/10.2147/OPHTH.S34631) pmid: [22927745](https://pubmed.ncbi.nlm.nih.gov/22927745/)
16. Kim BY, Smith SD, Kaiser PK. Optical coherence tomographic patterns of diabetic macular edema. *Am J Ophthalmol*. 2006;142(3):405-12. doi: [10.1016/j.ajo.2006.04.023](https://doi.org/10.1016/j.ajo.2006.04.023) pmid: [16935584](https://pubmed.ncbi.nlm.nih.gov/16935584/)
17. Sambhav K, Grover S, Chalam KV. The application of optical coherence tomography angiography in retinal diseases. *Surv Ophthalmol*. 2017;62(6):838-66. doi: [10.1016/j.survophthal.2017.05.006](https://doi.org/10.1016/j.survophthal.2017.05.006) pmid: [28579550](https://pubmed.ncbi.nlm.nih.gov/28579550/)



18. Matsunaga DR, Yi JJ, De Koo LO, Ameri H, Puliafito CA, Kashani AH. Optical Coherence Tomography Angiography of Diabetic Retinopathy in Human Subjects. *Ophthalmic Surg Lasers Imaging Retina*. 2015;46(8):796-805. doi: [10.3928/23258160-201509-09-03](https://doi.org/10.3928/23258160-201509-09-03) pmid: 26431294
19. Diabetic Retinopathy Clinical Research N, Scott IU, Edwards AR, Beck RW, Bressler NM, Chan CK, et al. A phase II randomized clinical trial of intravitreal bevacizumab for diabetic macular edema. *Ophthalmology*. 2007;114(10):1860-7. doi: [10.1016/j.ophtha.2007.05.062](https://doi.org/10.1016/j.ophtha.2007.05.062) pmid: 17698196
20. Massin P, Bandello F, Garweg JG, Hansen LL, Harding SP, Larsen M, et al. Safety and efficacy of ranibizumab in diabetic macular edema (RESOLVE Study): a 12-month, randomized, controlled, double-masked, multicenter phase II study. *Diabetes Care*. 2010;33(11):2399-405. doi: [10.2337/dc10-0493](https://doi.org/10.2337/dc10-0493) pmid: 20980427
21. Mitchell P, Bandello F, Schmidt-Erfurth U, Lang GE, Massin P, Schlingemann RO, et al. The RESTORE study: ranibizumab monotherapy or combined with laser versus laser monotherapy for diabetic macular edema. *Ophthalmology*. 2011;118(4):615-25. doi: [10.1016/j.ophtha.2011.01.031](https://doi.org/10.1016/j.ophtha.2011.01.031) pmid: 21459215
22. Nguyen QD, Brown DM, Marcus DM, Boyer DS, Patel S, Feiner L, et al. Ranibizumab for diabetic macular edema: results from 2 phase III randomized trials: RISE and RIDE. *Ophthalmology*. 2012;119(4):789-801. doi: [10.1016/j.ophtha.2011.12.039](https://doi.org/10.1016/j.ophtha.2011.12.039) pmid: 22330964
23. Arevalo JF, Lasave AF, Wu L, Acon D, Farah ME, Gallego-Pinazo R, et al. Intravitreal bevacizumab for diabetic macular oedema: 5-year results of the Pan-American Collaborative Retina Study group. *Br J Ophthalmol*. 2016;100(12):1605-10. doi: [10.1136/bjo.ophthalmol-2015-307950](https://doi.org/10.1136/bjo.ophthalmol-2015-307950) pmid: 26912377
24. Haller JA, Bandello F, Belfort R, Jr., Blumenkranz MS, Gillies M, Heier J, et al. Randomized, sham-controlled trial of dexamethasone intravitreal implant in patients with macular edema due to retinal vein occlusion. *Ophthalmology*. 2010;117(6):1134-46 e3. doi: [10.1016/j.ophtha.2010.03.032](https://doi.org/10.1016/j.ophtha.2010.03.032) pmid: 20417567
25. EMC. Ozurdex Summary of Product Characteristics: EMC; 2017 [cited 2017].
26. London NJ, Chiang A, Haller JA. The dexamethasone drug delivery system: indications and evidence. *Adv Ther*. 2011;28(5):351-66. doi: [10.1007/s12325-011-0019-z](https://doi.org/10.1007/s12325-011-0019-z) pmid: 21494891
27. Chang-Lin JE, Attar M, Acheampong AA, Robinson MR, Whitcup SM, Kuppermann BD, et al. Pharmacokinetics and pharmacodynamics of a sustained-release dexamethasone intravitreal implant. *Invest Ophthalmol Vis Sci*. 2011;52(1):80-6. doi: [10.1167/iovs.10-5285](https://doi.org/10.1167/iovs.10-5285) pmid: 20702826
28. Callanan DG, Gupta S, Boyer DS, Ciulla TA, Singer MA, Kuppermann BD, et al. Dexamethasone intravitreal implant in combination with laser photocoagulation for the treatment of diffuse diabetic macular edema. *Ophthalmology*. 2013;120(9):1843-51. doi: [10.1016/j.ophtha.2013.02.018](https://doi.org/10.1016/j.ophtha.2013.02.018) pmid: 23706947
29. Boyer DS, Yoon YH, Belfort R, Jr., Bandello F, Maturi RK, Augustin AJ, et al. Three-year, randomized, sham-controlled trial of dexamethasone intravitreal implant in patients with diabetic macular edema. *Ophthalmology*. 2014;121(10):1904-14. doi: [10.1016/j.ophtha.2014.04.024](https://doi.org/10.1016/j.ophtha.2014.04.024) pmid: 24907062
30. Gillies MC, Lim LL, Campain A, Quin GJ, Salem W, Li J, et al. A randomized clinical trial of intravitreal bevacizumab versus intravitreal dexamethasone for diabetic macular edema: the BEVORDEX study. *Ophthalmology*. 2014;121(12):2473-81. doi: [10.1016/j.ophtha.2014.07.002](https://doi.org/10.1016/j.ophtha.2014.07.002) pmid: 25155371
31. Mastropasqua R, Toto L, Borrelli E, Di Antonio L, De Nicola C, Mastrocola A, et al. Morphology and Function over a One-Year Follow Up Period after Intravitreal Dexamethasone Implant (Ozurdex) in Patients with Diabetic Macular Edema. *PLoS One*. 2015;10(12):e0145663. doi: [10.1371/journal.pone.0145663](https://doi.org/10.1371/journal.pone.0145663) pmid: 26720268
32. Aiello LP, Avery RL, Arrigg PG, Keyt BA, Jampel HD, Shah ST, et al. Vascular endothelial growth factor in ocular fluid of patients with diabetic retinopathy and other retinal disorders. *N Engl J Med*. 1994;331(22):1480-7. doi: [10.1056/NEJM199412013312203](https://doi.org/10.1056/NEJM199412013312203) pmid: 7526212
33. Augustin AJ, Keller A, Koch F, Jurklics B, Dick B. [Effect of retinal coagulation status on oxidative metabolite and VEGF in 208 patients with proliferative diabetic retinopathy]. *Klin Monbl Augenheilkd*. 2001;218(2):89-94. doi: [10.1055/s-2001-12251](https://doi.org/10.1055/s-2001-12251) pmid: 11258131
34. Stefansson E. Ocular oxygenation and the treatment of diabetic retinopathy. *Surv Ophthalmol*. 2006;51(4):364-80. doi: [10.1016/j.survophthal.2006.04.005](https://doi.org/10.1016/j.survophthal.2006.04.005) pmid: 16818083
35. Holekamp NM, Shui YB, Beebe DC. Vitrectomy surgery increases oxygen exposure to the lens: a possible mechanism for nuclear cataract formation. *Am J Ophthalmol*. 2005;139(2):302-10. doi: [10.1016/j.ajo.2004.09.046](https://doi.org/10.1016/j.ajo.2004.09.046) pmid: 15733992
36. Tamura K, Yokoyama T, Ebihara N, Murakami A. Histopathologic analysis of the internal limiting membrane surgically peeled from eyes with diffuse diabetic macular edema. *Jpn J Ophthalmol*. 2012;56(3):280-7. doi: [10.1007/s10384-012-0130-y](https://doi.org/10.1007/s10384-012-0130-y) pmid: 22438196
37. Yanyali A, Bozkurt KT, Macin A, Horozoglu F, Nohutcu AF. Quantitative assessment of photoreceptor layer in eyes with resolved edema after pars plana vitrectomy with internal limiting membrane removal for diabetic macular



- edema. *Ophthalmologica*. 2011;226(2):57-63. doi: [10.1159/000327597](https://doi.org/10.1159/000327597) pmid: 21555906
38. Sakamoto A, Nishijima K, Kita M, Oh H, Tsujikawa A, Yoshimura N. Association between foveal photoreceptor status and visual acuity after resolution of diabetic macular edema by pars plana vitrectomy. *Graefes Arch Clin Exp Ophthalmol*. 2009;247(10):1325-30. doi: [10.1007/s00417-009-1107-5](https://doi.org/10.1007/s00417-009-1107-5) pmid: 19430805
39. Otani T, Yamaguchi Y, Kishi S. Correlation between visual acuity and foveal microstructural changes in diabetic macular edema. *Retina*. 2010;30(5):774-80. doi: [10.1097/IAE.0b013e3181c2e0d6](https://doi.org/10.1097/IAE.0b013e3181c2e0d6) pmid: 19996821
40. Yamada Y, Suzuma K, Ryu M, Tsuiki E, Fujikawa A, Kitaoka T. Systemic factors influence the prognosis of diabetic macular edema after pars plana vitrectomy with internal limiting membrane peeling. *Curr Eye Res*. 2013;38(12):1261-5. doi: [10.3109/02713683.2013.820327](https://doi.org/10.3109/02713683.2013.820327) pmid: 23972000
41. Chhablani JK, Kim JS, Cheng L, Kozak I, Freeman W. External limiting membrane as a predictor of visual improvement in diabetic macular edema after pars plana vitrectomy. *Graefes Arch Clin Exp Ophthalmol*. 2012;250(10):1415-20. doi: [10.1007/s00417-012-1968-x](https://doi.org/10.1007/s00417-012-1968-x) pmid: 22354371
42. Romano MR, Romano V, Vallejo-Garcia JL, Vinciguerra R, Romano M, Cereda M, et al. Macular hypotrophy after internal limiting membrane removal for diabetic macular edema. *Retina*. 2014;34(6):1182-9. doi: [10.1097/IAE.000000000000076](https://doi.org/10.1097/IAE.000000000000076) pmid: 24846134
43. Ichiyama Y, Sawada O, Mori T, Fujikawa M, Kawamura H, Ohji M. The effectiveness of vitrectomy for diffuse diabetic macular edema may depend on its preoperative optical coherence tomography pattern. *Graefes Arch Clin Exp Ophthalmol*. 2016;254(8):1545-51. doi: [10.1007/s00417-015-3251-4](https://doi.org/10.1007/s00417-015-3251-4) pmid: 26780461
44. Kumagai K, Ogino N, Furukawa M, Demizu S, Atsumi K, Kurihara H, et al. [Internal limiting membrane peeling in vitreous surgery for diabetic macular edema]. *Nippon Ganka Gakkai Zasshi*. 2002;106(9):590-4. pmid: 12385125
45. Kumagai K, Hangai M, Ogino N, Larson E. Effect of Internal Limiting Membrane Peeling on Long-Term Visual Outcomes for Diabetic Macular Edema. *Retina*. 2015;35(7):1422-8. doi: [10.1097/IAE.0000000000000497](https://doi.org/10.1097/IAE.0000000000000497) pmid: 26102439
46. Bonnini S, Sandali O, Bonnel S, Monin C, El Sanharawi M. VITRECTOMY WITH INTERNAL LIMITING MEMBRANE PEELING FOR TRACTIONAL AND NONTRACTIONAL DIABETIC MACULAR EDEMA: Long-term Results of a Comparative Study. *Retina*. 2015;35(5):921-8. doi: [10.1097/IAE.0000000000000433](https://doi.org/10.1097/IAE.0000000000000433) pmid: 25545486
47. Nizawa T, Arai M, Takatsuna Y, Oshitari T, Sato E, Yamamoto S. [Comparison of visual acuity and central macular thickness after vitrectomy for diffuse diabetic macular edema with or without preoperative treatments]. *Nippon Ganka Gakkai Zasshi*. 2013;117(10):785-92. pmid: 24354262
48. Diabetic Retinopathy Clinical Research Network Writing C, Haller JA, Qin H, Apte RS, Beck RR, Bressler NM, et al. Vitrectomy outcomes in eyes with diabetic macular edema and vitreomacular traction. *Ophthalmology*. 2010;117(6):1087-93 e3. doi: [10.1016/j.ophtha.2009.10.040](https://doi.org/10.1016/j.ophtha.2009.10.040) pmid: 20299105
49. Jackson TL, Nicod E, Angelis A, Grimaccia F, Pringle E, Kanavos P. PARS PLANA VITRECTOMY FOR DIABETIC MACULAR EDEMA: A Systematic Review, Meta-Analysis, and Synthesis of Safety Literature. *Retina*. 2017;37(5):886-95. doi: [10.1097/IAE.00000000000001280](https://doi.org/10.1097/IAE.00000000000001280) pmid: 27632713