

# Thirteen dogs and a cat with ultrasonographically detected gallbladder wall edema associated with cardiac disease

Gregory R. Lisciandro<sup>1</sup>  | Jennifer M. Gambino<sup>2</sup> | Stephanie C. Lisciandro<sup>3</sup>

<sup>1</sup>Hill Country Veterinary Specialists,  
Spicewood, Texas

<sup>2</sup>IDEXX Laboratories, Clackamas, Oregon

<sup>3</sup>Oncura Partners Diagnostics, Fort Worth,  
Texas

## Correspondence

Gregory R. Lisciandro, Hill Country Veterinary  
Specialists, 1049 Lakeshore Drive, Spicewood,  
TX 78669.

Email: fastsaveslives@gmail.com

## Abstract

**Background:** Ultrasonographically detected gallbladder wall edema (GBWE) is a marker for anaphylaxis in dogs. Cardiac disease can cause GBWE with similar signs and should be included as a differential diagnosis to prevent interpretation errors.

**Hypothesis/Objectives:** Document GBWE associated with cardiac disease.

**Animals:** Fourteen client-owned animals.

**Methods:** Prospective case series with abdominal focused assessment with abdominal sonography in trauma, triage and tracking (AFAST), and thoracic focused assessment with abdominal sonography in trauma, triage, and tracking (TFAST) performed at triage. Animals with GBWE and cardiac disease were enrolled. A board-certified radiologist reviewed images to confirm cardiac disease, GBWE, and characterize the caudal vena cava (CVC) and hepatic veins.

**Results:** Thirteen dogs and 1 cat had GBWE associated with cardiac disease. Gallbladder findings included mural thickness ranging from 3 to 5 mm, mild to moderate sludge (n = 3), and mild to moderate luminal distension (n = 6). CVC and hepatic venous distension were found in 5/6. Cardiac diagnoses in dogs included 11 with pericardial effusion (PCE) and 1 each with dilated cardiomyopathy and right-sided myocardial failure. Severity of PCE was rated as mild (n = 1), moderate (n = 6), or severe (n = 4). Seven of 11 had pericardiocentesis performed. Nine of 13 had ascites with 4 having abdominal fluid scores of 1 (n = 2), 2 (n = 2), 3 (n = 1), and 4 (n = 0). Lung ultrasound findings were as follows: dry lung (n = 6), B-lines (n = 4), and nodules (n = 1). The cat had moderate PCE, ascites scored as 1, and severe right-sided ventricular enlargement associated with a ventricular septal defect. Primary presenting complaints included acute weakness (n = 9), acute collapse (n = 5), gastrointestinal signs (n = 3), respiratory distress (n = 2), and need for cardiopulmonary resuscitation (n = 1).

**Conclusions and Clinical Importance:** Ultrasonographically detected GBWE was associated with PCE in this small cohort of cases.

## KEYWORDS

cardiac gallbladder, FAST, gallbladder wall edema, ultrasound

**Abbreviations:** AFAST, abdominal FAST; AX, anaphylaxis; FAST, focused assessment with sonography in trauma, triage, and tracking; Global FAST, combination of AFAST, TFAST, and Vet BLUE; PCE, pericardial effusion; TFAST, thoracic FAST; Vet BLUE, veterinary brief lung ultrasound exam.

This is an open access article under the terms of the Creative Commons Attribution-NonCommercial-NoDerivs License, which permits use and distribution in any medium, provided the original work is properly cited, the use is non-commercial and no modifications or adaptations are made.

© 2021 The Authors. *Journal of Veterinary Internal Medicine* published by Wiley Periodicals LLC on behalf of American College of Veterinary Internal Medicine.

## 1 | INTRODUCTION

In the acute setting, gallbladder wall edema (GBWE) has been referred to as the gallbladder halo sign and shown to be a sensitive marker for anaphylaxis (AX) in dogs.<sup>1</sup> Gallbladder wall edema is characterized ultrasonographically by striation of the gallbladder wall, which may be thickened or within reference range.<sup>1,2</sup> Although not a pathognomonic finding, many veterinarians use focused assessment with sonography for trauma, triage, and tracking (FAST) ultrasound to identify GBWE at the time of triage in acutely collapsed or weak dogs with suspected AX.<sup>3-5</sup> Limited anecdotal observations and an experimental model in dogs have suggested cardiac disease and pericardial effusion (PCE) as additional causes of GBWE.<sup>2</sup> Dogs with cardiac disease can present similarly to dogs with AX (eg, acute weakness, collapse, respiratory, gastrointestinal signs).<sup>1,2,4-7</sup> Inclusion of cardiac disease as a differential diagnosis for GBWE can prevent sonographers from making image interpretation errors.

Gallbladder wall edema can be nonspecific and may be caused by several disease states, (eg, cholecystitis, cholangiohepatitis, hepatitis, pancreatitis, sepsis, acute hemorrhagic diarrhea syndrome, hypoalbuminemia, some drugs).<sup>7,9,10</sup> However, animals with these causes typically are not presented with acute signs that include respiratory distress, weakness or collapse as with AX and cardiac disease.

Our objective was to document that GBWE occurs in dogs and cats with cardiac disease.

## 2 | METHODS

Standardized FAST ultrasound examination of the abdomen (AFAST) was carried out in small animals at the time of triage in all patients having a history of acute weakness, collapse, or respiratory distress.<sup>3-5,11</sup> Inclusion criteria were presence of ultrasonographically detected GBWE and cardiac disease. Still images of the gallbladder and heart were saved in all cases. Gallbladder wall edema was ultrasonographically defined as having a gallbladder having a striated mixed echogenicity consisting of a hyperechoic inner (luminal) and outer (serosal) wall with a central hypoechoic striation (hyperechoic-hypoechoic-hyperechoic layering) with or without abnormal thickness (normal thickness, 1-3 mm in dogs and <1 mm in cats).<sup>1,2,9,10</sup> Most cases also were evaluated by standardized FAST ultrasound examination of the thorax (TFAST) including heart and lung (Vet BLUE).<sup>3-5,11-14</sup>

Patients were enrolled and supervised by 1 of the authors (G.R. Lisciandro) over a 42-month period. All sonographers participated in a lecture and hands-on training course for AFAST, TFAST, and Vet BLUE.<sup>3-5,12-14</sup> In all cases, B-mode ultrasound images of the gallbladder at the AFAST diaphragmatico-hepatic view and a representative image of the heart from TFAST were saved for later review by a board-certified radiologist. Examples are shown in Figure 1.

Findings of TFAST, AFAST, and Vet BLUE were recorded in the medical records for all patients using a standardized data entry template. The TFAST entries included checkboxes for the presence of pericardial and pleural effusion and its severity, normal, or abnormal

systolic function, the presence of right ventricular and left atrial enlargement and the diaphragmatico-hepatic view for subjective characterization of the caudal vena cava (CVC) and hepatic veins as “unremarkable,” “distended,” or “indeterminate.”<sup>3-5,15</sup> Not assessed was used for those patients lacking an entry. Most cases (n = 13) also had AFAST examination using a template that included checkboxes for the presence of ascites and its severity by an assigned abdominal fluid score (AFS), a space for recording soft tissue abnormalities of target organs (ie, GBWE)<sup>3-5</sup>; and a space to document Vet BLUE lung examination (n = 11) for pulmonary pathology at each of its respective Vet BLUE acoustic windows (ie, alveolar-interstitial edema [B-lines] and signs of pulmonary-parenchymal consolidation including the shred sign and nodules).<sup>14,16,17</sup>

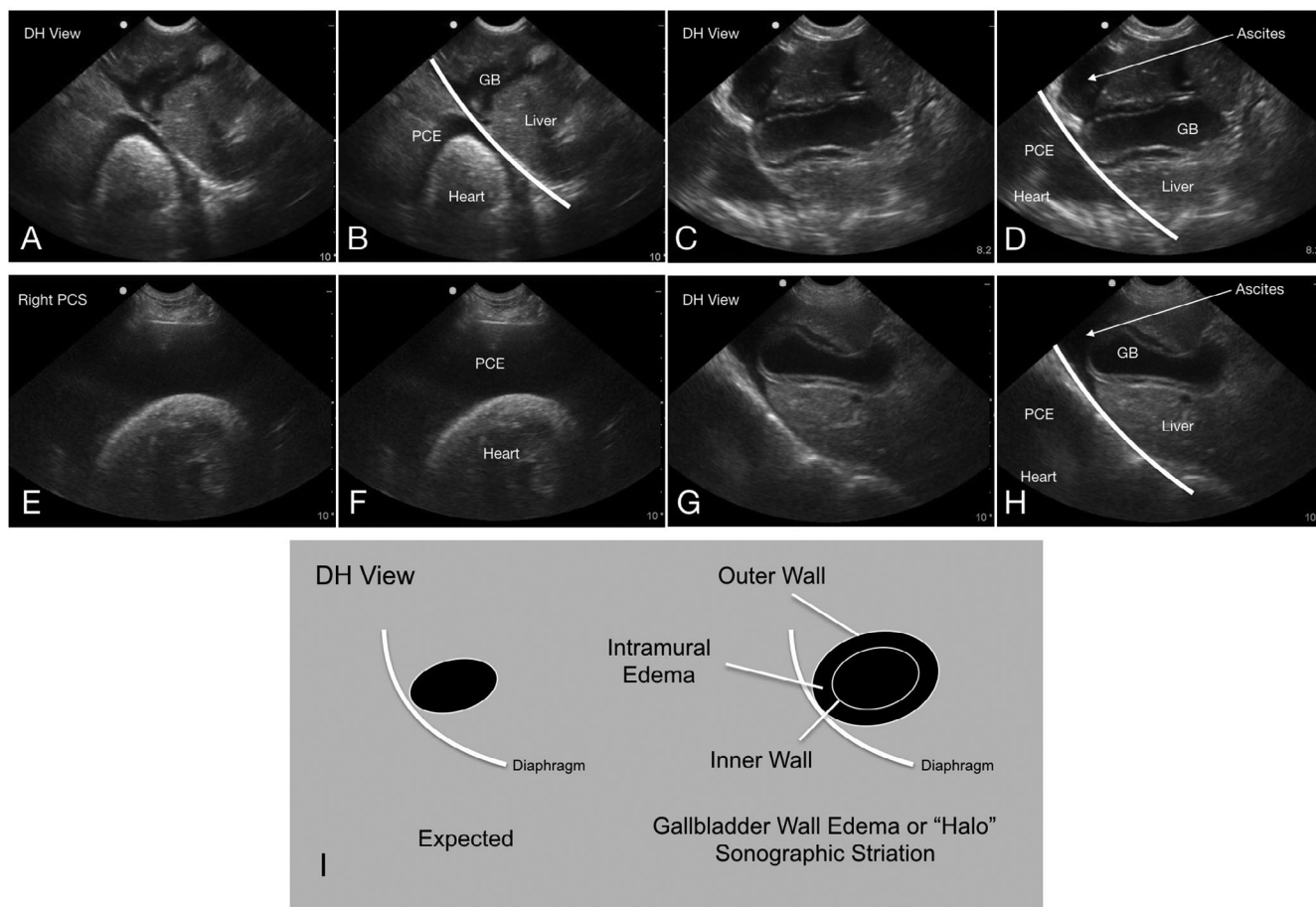
All gallbladder images were blindly reviewed by a board-certified radiologist, and cardiac assessment was made either by a board-certified cardiologist or board-certified internist who had advanced echocardiography training. Although not part of the study's inclusion criteria, characterization of the CVC and hepatic veins by a board-certified radiologist was performed on cine clips saved from 6 of the cases.

## 3 | RESULTS

Fourteen animals were included with enrollment of 13 dogs and 1 cat. Dogs included 10 breeds, 4 spayed females, 5 neutered males, 4 intact females, and an intact male, and an 8-week old, intact male, domestic shorthair cat. Primary presenting complaints included acute weakness (n = 9), acute collapse (n = 5), gastrointestinal signs (n = 3), respiratory distress (n = 2), and need for cardiopulmonary resuscitation (n = 1). Median values for the dogs were: age of 11 years (range, 0.25-14 years; n = 13); body temperature of 38.3 C (range, 36.7-38.9; n = 9); heart rate of 128 beats per minute (range, 90-230; n = 9); respiratory rate of 44 breaths per minute (range, 32-60; n = 8); and body weight of 12.7 kg (range, 4.5-35.8; n = 12). Patient data are summarized in Supplementary Table 1.

All cases had an ultrasonographically striated (layered) gallbladder wall with mural thickening ranging from 3 to 5 mm. Gallbladder wall echogenicity was heterogenous with a striated appearance of layered mural bands with those along the serosal and luminal aspects of the gallbladder wall found to be hyperechoic with a central hypoechoic band. In 8 dogs, gallbladder shape and size ranged from oval to round and empty to subjectively normal distention. In 5 dogs and the cat, gallbladders were round with mild to moderate distension. None of the gallbladders were severely distended, nor was there any evidence of biliary tract distension or obstruction. Luminal contents were normal (anechoic) in all but 3 dogs. Mild (n = 2) to moderate (n = 1) amounts of echogenic sludge were observed in 3 dogs.

Of the dogs, 11 of 13 had PCE. One dog had dilated cardiomyopathy (n = 1) and another right ventricular myocardial failure (n = 1). Severity of PCE was subjectively classified as mild (n = 1), moderate (n = 6) or severe (n = 4) and 9 of 13 dogs had ascites with 4 of the 9 dogs having AFSs recorded as 1 (n = 1), 2 (n = 2), 3 (n = 1), and 4



**FIGURE 1** A-I, Examples of pericardial effusion (PCE) and gallbladder (GB) wall edema (GBWE). Example 1: In (A) and (B) are unlabeled and labeled images showing PCE as it surrounds the muscular cardiac apex at the AFAST-TFAST diaphragmatico-hepatic (DH) view. Note in between the falciform fat and diaphragm in the near field is a small unlabeled volume of ascites seen as a small anechoic triangulation. In (C) and (D) of the same patient (same DH View), GBWE was detected and characterized as striated with a layered appearance (hyperechoic-hypoechoic-hyperechoic). Note the ascites (labeled) is more apparent in this scanning plane. Example 2: In (E) and (F) are unlabeled and labeled images from the right TFAST pericardial site view (PCS) showing encircling of the cardiac apex with anechoic PCE. The DH view in (G) and (H) of this patient showed the characteristic, striated GBWE or sonographic pattern of the wall being hyperechoic-hypoechoic-hyperechoic. Note there is also ascites (labeled) present that is recognized as an anechoic triangulation between the GB and diaphragm in the near field. I, A schematic illustration demonstrates the thin hyperechoic gallbladder wall in normalcy and the abnormal hyperechoic-hypoechoic-hyperechoic layered appearance expected of GBWE in (C), (D), (G) and (H). Heavy white curved line indicates the approximate course of the diaphragm

( $n = 0$ ).<sup>3-5,8,13</sup> Seven of 11 dogs underwent pericardiocentesis. No animals had pleural effusion or pneumothorax. Vet BLUE lung ultrasound results ( $n = 11$ ) included dry lung artifacts in all views ( $n = 6$ ), positive B-lines ( $n = 4$ ), and nodules ( $n = 1$ ). The cat had moderate PCE and small volume ascites scored as 1 with severe right-sided ventricular enlargement associated with a ventricular septal defect (Supplementary Table 1). The CVC and hepatic veins were characterized by emergency clinicians in 9 of the medical records and recorded as distended (3/9), unremarkable (5/9), indeterminate (1/9), or not assessed (5/9). Characterization of the CVC and hepatic veins using cine clips ( $n = 6$ ) confirmed hepatic venous distension in 5/6 cases by a blinded board-certified radiologist.

Agreement was 100% between the board-certified emergency clinician and the board-certified radiologist regarding the presence of GBWE ( $\kappa = 1.0$ ). Pericardial effusion was the most likely cause of cardiogenic GBWE in 85% of the dogs (11/13).

## 4 | DISCUSSION

The case series documents the presence of GBWE likely resulting from cardiac disease (most commonly PCE) but our study population also included patients with dilated cardiomyopathy, right-sided systolic failure, and a left-to-right shunting ventricular septal defect. The most common presenting signs included acute weakness and collapse in these triaged emergency cases. Thus, FAST ultrasound examination was an initial diagnostic test to help rule out causes of cardiovascular collapse including AX.

Underlying cardiac disease is an additional cause of GBWE, which can be detected using FAST and other point-of-care ultrasound formats, an approach that has become common in the veterinary triage setting. Awareness of cardiogenic causes of GBWE can avoid interpretation errors and common imaging errors such as satisfaction of search error and confirmation bias error resulting from selective

imaging limited to the abdomen.<sup>18</sup> The term “cardiac gallbladder” has been used to describe GBWE associated with underlying cardiac disease in human medicine.<sup>18</sup> The term is appropriate because it differentiates cardiogenic etiologies of GBWE from other noncardiogenic causes of GBWE in the acute setting during initial patient assessment.

In this small case series, PCE was the most common cardiac cause of GBWE. Ascites was present in 69% of dogs (9/13) dogs and in the cat, which may have clinical implications regarding cardiac disease duration before acute signs.<sup>19</sup> The observation of GBWE during AFAST should prompt the sonographer to integrate echocardiography into patient assessment to evaluate for other potential causes of GBWE, such as PCE. Moreover, thoracic radiography and other advanced imaging techniques should be performed when indicated.

Although limited in our study, integrating characterization of the CVC size including distensibility and evaluation for hepatic venous distension can increase the index of suspicion for right-sided congestive heart failure.<sup>2-5,8,15,20-22</sup> It is a limitation of our study that recording of the CVC and hepatic venous appearance was not consistently performed. However, since this data collection, techniques have improved for rapidly and more consistently identifying and characterizing the CVC and hepatic veins. A distended CVC and hepatic veins with a lack of dynamic change in CVC diameter during respiratory and cardiac cycles support the presence of cardiogenic causes of GBWE. On the other hand, a small attenuated CVC and absence of hepatic venous distension support a higher likelihood of AX in acutely ill patients.<sup>3-5</sup> Similar integrative ultrasound approaches have been advocated in human medicine.<sup>18,23-26</sup>

Additional limitations of our case series include the fact that enrolled patients were limited to animals presented to an emergency service. Additional prospective studies are warranted to confirm the true prevalence of GBWE in patients with cardiac disease in a larger cohort of cardiac disease patients including those with PCE, right-sided congestive heart failure, and other diseases. Other limitations include that the ascites was not verified as a modified transudate in all cases, and the cause for PCE often was not definitively determined (Supplementary Table 1). Furthermore, other GBWE differential diagnoses were not conclusively ruled out, but primary gallbladder disease was considered unlikely because concurrent evidence of biliary tract disease was not evident. Validation of the presence or absence of cholecystic disease would have required more invasive measures such as gallbladder wall biopsy. In this small cohort, as is typical of abbreviated imaging formats, FAST ultrasound findings were a useful first line screening test. However, all of the patient's clinical data and comprehensive follow-up imaging and testing (ie, laboratory test results, complete abdominal ultrasonography, thoracic radiography, and complete echocardiography) should be evaluated.

In people with right-sided congestive heart failure, selective right upper quadrant ultrasonography with the finding of GBWE led to unnecessary cholecystectomy, indicating the risk in patient management of misinterpretation errors from confirmation bias and satisfaction of search errors.<sup>18</sup> These errors likewise should be considered risks of veterinary point-of-care ultrasound evaluation in which clinicians perform selective (ie, targeted or focused) ultrasound examinations without evaluation of other systems. Thus, the combination of

AFAST, TFAST, and Vet BLUE as an extension of the initial physical examination helps achieve an unbiased set of data imaging points to prevent such image interpretation errors.<sup>3,5,11,15</sup> A similar proposal for point-of-care and FAST ultrasound examination as an integrative approach has occurred in human medicine.<sup>18,23-26</sup>

## 5 | CONCLUSION

Gallbladder wall edema, also referred to as the gallbladder halo sign, may be caused by cardiac disease in both dogs and cats.

### ACKNOWLEDGMENT

No funding was received for this study. This study was presented in part as an abstract at the International Veterinary Emergency and Critical Care Symposium, Washington DC, September 2019. We are grateful to the Emergency Pet Center, San Antonio, Texas, and their staff; and Dr. Chris Johnson of Oklahoma Veterinary Specialists, Tulsa, Oklahoma.

### CONFLICT OF INTEREST DECLARATION

Authors declare no conflict of interest.

### OFF-LABEL ANTIMICROBIAL DECLARATION

Authors declare no off-label use of antimicrobials.

### INSTITUTIONAL ANIMAL CARE AND USE COMMITTEE (IACUC) OR OTHER APPROVAL DECLARATION

Authors declare no IACUC or other approval was needed.

### HUMAN ETHICS APPROVAL DECLARATION

Authors declare human ethics approval was not needed for this study.

### ORCID

Gregory R. Lisciandro  <https://orcid.org/0000-0001-6266-3430>

### REFERENCES

1. Quantz JE, Miles MS, Reed AL, et al. Elevation of alanine transaminase and gallbladder wall abnormalities as biomarkers of anaphylaxis in canine hypersensitivity patients. *J Vet Emerg Crit Care*. 2009;19(6):536-544.
2. Nelson NC, Drost WT, Lerche P, et al. Noninvasive estimation of central venous pressure in anesthetized dogs by measurement of hepatic venous blood flow velocity and abdominal venous diameter. *Vet Radiol Ultrasound*. 2010;51(3):313-323.
3. Lisciandro GR. Abdominal and thoracic focused assessment with sonography for trauma, triage and monitoring in small animals. *J Vet Emerg Crit Care*. 2011;21(2):104-122.
4. Boysen SR, Lisciandro GR. The use of ultrasound in the emergency room (AFAST and TFAST). *Vet Clin North Amer Small Anim Pract*. 2013;43(4):773-797.
5. Lisciandro GR. Cageside ultrasonography in the emergency room and the intensive care unit. *Vet Clin North Am*. 2020;50(6):1445-1467.
6. Fahey R, Rozanski E, Paul A, et al. Prevalence of vomiting in dogs with pericardial effusion. *J Vet Emerg Crit Care*. 2017;27(2):250-252.
7. Walters AM, O'Brien MA, Selmic LE, et al. Comparison of clinical findings between dogs with suspected anaphylaxis and dogs with confirmed sepsis. *J Am Vet Med Assoc*. 2017;251(6):681-688.

8. Lisciandro GR, Lagutchnik MS, Mann KA, et al. Evaluation of an abdominal fluid scoring (AFS) system determined using abdominal focused assessment with sonography for trauma (FAFAST) in 101 dogs with motor vehicle trauma. *J Vet Emerg Crit Care*. 2009;19(5):426-437.
9. d'Anjou MA. Liver. In: Penninck D, D'anjou MA, eds. *Atlas of Small Animal Ultrasonography*. Ames, IA: Blackwell Publishing; 2008:243-247.
10. Nyland TG, Larson MM, Mattoon JS. Liver. In: Mattoon JS, Nyland TG, eds. *Small Animal Diagnostic Ultrasound*. 3rd ed. St. Louis, MO: Elsevier Saunders; 2015:332-399.
11. McMurray J, Boysen S, Chalhoub S. Focused assessment with sonography in nontraumatized dogs and cats in the emergency and critical care setting. *J Vet Emerg Crit Care*. 2016;26(1):64-73.
12. Lisciandro GR, Lagutchnik MS, Mann KA, et al. Accuracy of focused assessment with sonography for trauma (TFAST) to detect pneumothorax in 145 dogs with blunt and penetrating trauma. *J Vet Emerg Crit Care*. 2008;18(3):258-269.
13. Lisciandro GR. The use of the diaphragmatico-hepatic (DH) views of the abdominal and thoracic focused assessment with sonography for triage (FAFAST/TFAST) examinations for the detection of pericardial effusion in 24 dogs (2011-2012). *J Vet Emerg Crit Care*. 2016;26(1):125-131.
14. Lisciandro GR, Fosgate GT, Fulton RM. Frequency of ultrasound lung rockets using a regionally-based lung ultrasound examination named veterinary bedside lung ultrasound exam (Vet BLUE) in 98 dogs with normal thoracic radiographic lung findings. *Vet Rad Ultrasound*. 2014;55(3):315-322.
15. Lisciandro GR, Armenise A. Chapter 16: Focused or COAST<sup>3</sup> – cardiopulmonary resuscitation (CPR), global FAST (GFAST<sup>3</sup>) & the FAST-ABCDE exam. In: Lisciandro GR, ed. *Focused Ultrasound for the Small Animal Practitioner*. Ames, IA: Wiley Blackwell; 2014:269-285.
16. Ward JL, Lisciandro GR, Tou SP, Keene BW, DeFrancesco TC. Accuracy of point-of-care lung ultrasound (Vet BLUE protocol) for the diagnosis of cardiogenic pulmonary edema in dogs and cats with acute dyspnea. *J Am Vet Assoc*. 2017;250(6):666-675.
17. Ward JL, Lisciandro GR, Ware WA, Miles KG, DeFrancesco TC. Lung ultrasound findings in 100 dogs with various etiologies of cough. *J Am Vet Med Assoc*. 2019;255(5):574-583.
18. Lichtenstein DA. Gallbladder. In: Lichtenstein DA, ed. *Whole Body Ultrasound in the Critically Ill*. London: Springer; 2010:59-67.
19. Stafford Johnson M, Martin M, Binns S, Day MJ. A retrospective study of clinical findings, treatment and outcome in 143 dogs with pericardial effusion. *J Small Anim Pract*. 2004;45(11):546-552.
20. Ferrada P, Vanguri P, Anand RJ, et al. Flat inferior vena cava: indicator of poor prognosis in trauma and acute care surgery patients. *Am Surg*. 2012;78(12):1396-1398.
21. Ferrada P, Attand RJ, Whelan J, et al. Qualitative assessment of the inferior vena cava: useful tool for the evaluation of volume status in critically ill patients. *Am Surg*. 2012;78(4):468-470.
22. Himelman RB, Kircher B, Rockey DC, et al. Inferior vena cava plethora with blunted respiratory response: a sensitive echocardiographic sign of cardiac tamponade. *J Am Coll Cardiol*. 1988;12(6):1470-1477.
23. Narasimhan M, Koenig SJ, Mayo PH. A whole-body approach to point of care ultrasound. *Chest*. 2016;150(4):772-776.
24. Tavares J, Ivo R, Gonzales F, et al. Global ultrasound check for the critically ill (GUCCI) – a new systematized protocol unifying point-of-care ultrasound in critically ill patients based on clinical presentation. *Emerg Med*. 2019;11:133-145.
25. Perera P, Mailhot T, Riley D, et al. The RUSH exam: rapid ultrasound in shock in the evaluation of the critically ill. *Emerg Med Clin North Am*. 2010;28(1):29-56.
26. Zieleskiewicz L, Fresco R, Duclos G, et al. Integrating extended focused assessment with sonography for trauma (eFAST) in the initial assessment of severe trauma: impact on management of 756 patients. *Injury*. 2018;49(10):1774-1780.

#### SUPPORTING INFORMATION

Additional supporting information may be found online in the Supporting Information section at the end of this article.

**How to cite this article:** Lisciandro GR, Gambino JM, Lisciandro SC. Thirteen dogs and a cat with ultrasonographically detected gallbladder wall edema associated with cardiac disease. *J Vet Intern Med*. 2021;35:1342–1346. <https://doi.org/10.1111/jvim.16117>