

# Polyethylene Suture Augmentation of the Medial Patellofemoral Ligament in Skeletally Immature Patients with Recurrent Patella Dislocation



Jin Tang, B.M., and Jinzhong Zhao, M.D.

**Abstract:** In skeletally immature patients with recurrent patella dislocation that needs operation, how to increase the medial stability of the patella effectively without disturbance of the epiphysal plate is of concern. Through evaluation of multiple techniques that designed to avoid injury to the epiphysal plate, we found that medial patellofemoral ligament augmentation with high-strength nonabsorbable sutures is feasible and effective. Thus, we would like to describe this technique, whose critical point is the correct location and creation of the 2 femoral tunnels. We consider the introduction of the current technique will provide reasonable choices when operation is needed in this special group of patients.

Recurrent patella dislocation in skeletally immature patients is a challenging condition because once patella dislocation recurs, it is doomed to repeated attacks. The principle of treatment for recurrent patellar dislocation in patients with open epiphysal plate is the same as that for adults, but when it comes to surgical treatment, appropriate treatment methods should be used. For patients with high-growth potential and who are indicted for operation, surgeries that avoid or minimize injury to the epiphysal plate should be considered.<sup>1-3</sup> Many methods have been reported to augment the medial side of the patella without disturbing the epiphysal plate, which include medial retinaculum plication, vastus medialis plasty, medial patella-femoral ligament (MPFL) reconstruction with graft suspension to the adductor magnus tenon, adductor magnus tendon transfer, etc.<sup>4,5</sup> However, a feasible surgical procedure with predictable results is still being pursued.<sup>6</sup> Thus, we

would like to introduce an MPFL augmentation technique with high-strength nonabsorbable sutures through femoral tunnels, avoiding interference of the epiphysal plate. Our clinical experience indicates this technique can be easily performed with predictable favorable results.

## Surgical Procedures

Preoperatively, a 3-dimensional computed tomography (CT) examination is taken to evaluate the location of the femoral epiphysal plate and its relation to the adductor tubercle and the medial femoral epicondyle. The locations of the proximal and distal femoral tunnels are defined with reference to the adductor tubercle and the medial femoral epicondyle, respectively, in preoperative planning.

The patient is placed in a supine position. A tourniquet is placed at the proximal thigh. One lateral post is placed at the thigh for the leg to lean on it in knee flexion.

## Debridement of the Knee

Routine anteromedial and anterolateral portals are fabricated. All parts of the knee, especially the lateral gutter, the space under the lateral meniscus, and the posteromedial and posterolateral compartments, are examined. Any free body or osteochondral fracture fragment are removed.

## Lateral Retinaculum Release and Quadriceps Rebalance

Lateral retinaculum release is performed except for patient with medial instability of the patella. With the

From the Operating Theater (J.T.) and Department of Sports Medicine (J.Z.), Shanghai Sixth People's Hospital, Shanghai Jiao Tong University, Shanghai, China.

The authors report that they have no conflicts of interest in the authorship and publication of this article. Full ICMJE author disclosure forms are available for this article online, as [supplementary material](#).

Received July 11, 2021; accepted August 17, 2021.

Address correspondence to Jinzhong Zhao, M.D., Department of Sports Medicine, Shanghai Sixth People's Hospital, Shanghai Jiao Tong University, 600 Yishan Rd., Shanghai 200233, China. E-mail: [zhaojinzhong@vip.163.com](mailto:zhaojinzhong@vip.163.com)

© 2021 by the Arthroscopy Association of North America. Published by Elsevier. This is an open access article under the CC BY-NC-ND license (<http://creativecommons.org/licenses/by-nc-nd/4.0/>).

2212-6287/21996

<https://doi.org/10.1016/j.eats.2021.08.033>

**Table 1.** Step-by-Step Procedure of Polyethylene Suture Augmentation of the Medial Patellofemoral Ligament in Skeletally Immature Patients With Recurrent Patella Dislocation

1. A 1-cm long longitudinal incision is made over the medial edge of the patella, at a level of the junction of the proximal and middle one-third of the patella.
2. A K wire is first drilled at a level approximately 5 mm proximal to the junction point, from the medial edge of the patella to its anterior surface. The K wire is overdrilled with a 4.5-mm drill to create a patellar tunnel.
3. Another K wire is drilled at a level approximately 5-mm distal to the junction point, from the medial edge of the patella to its anterior surface. The K wire is overdrilled with a 4.5-mm drill to create the second patellar tunnel.
4. One guide suture is passed through the patellar tunnel from the medial to the lateral side.
5. Three No. 2 ultra-high molecular weight polyethylene sutures are passed through the proximal patellar tunnel from the medial to the lateral side and then passed through the distal patellar tunnel from the lateral to the medial side.
6. A 2- to 3-cm long longitudinal incision is made over the medial femoral epicondyle and the adductor tubercle.
7. The proximal femoral tunnel is located and created sequentially with a K wire and a 4.5-mm cannulated drill. A polydioxanone suture is placed in the proximal femoral tunnel.
8. The distal femoral tunnel is located and created in the same way.
9. The augmentation sutures are pulled subcutaneously out of the medial incision.
10. The proximal and distal sutures limbs are pulled into the proximal and distal femoral tunnels, respectively, out of the lateral thigh.
11. A 2-cm lateral incision is made at the anterior edge of the iliotibial band at a level at the proximal pole of the patella.
12. With the knee at full extension, the suture limbs are pulled tight and exposed.
13. The sutures are retrieved out of the lateral incision through the space resulted from lateral retinaculum release.
14. The knee is flexed at 90°. The sutures are tied over the bone bridge between the lateral orifices of the femoral tunnels.

knee in full extension, the arthroscope is placed in through the anteromedial portal, and the radio-frequency probe is placed in through the anterolateral portal. Lateral retinaculum release is performed in the space between the vastus lateralis and the iliotibial band.

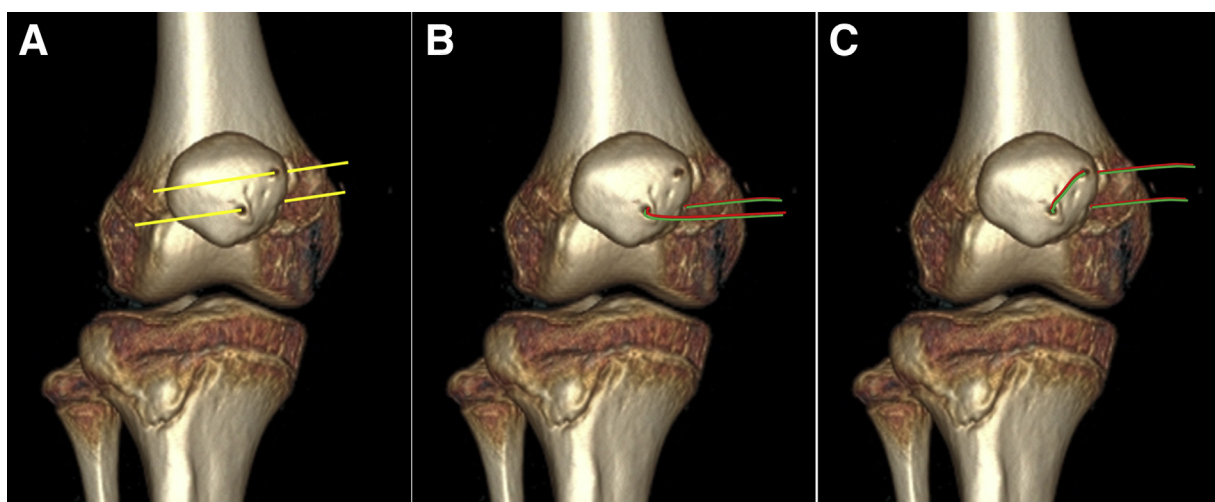
### Creating the Patellar Tunnels

The knee is flexed at 30° in a cross-leg position. The proximal and distal poles and the widest part of the patella is defined by palpation. A 1-cm long longitudinal incision is made on the medial edge of the widest part of the patella, which is over the junction of the proximal and middle one-third of the patella. The

junction point is defined along the medial edge of the patella (Video 1 and Table 1).

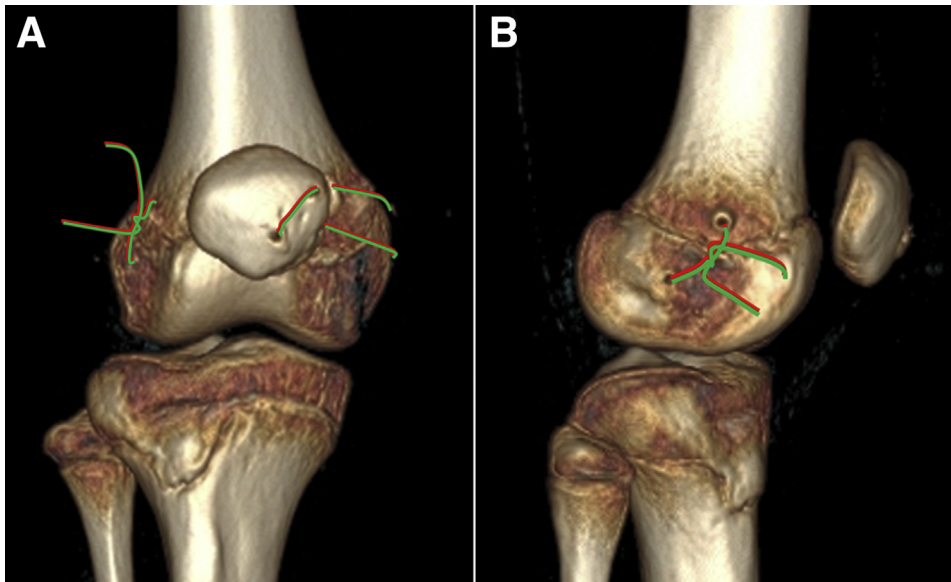
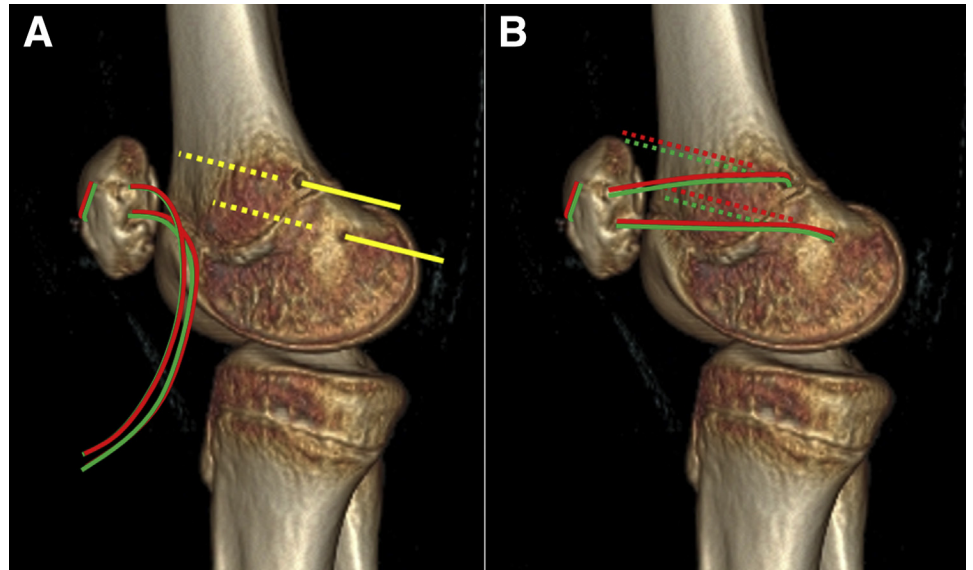
A K wire is first drilled at a level approximately 5 mm proximal to the junction point, from the medial edge of the patella to its anterior surface (Fig 1A). The K wire is overdrilled with a 4.5-mm cannulated drill to create a patellar tunnel. A K wire is placed into this tunnel for a reference to create the second patellar tunnel.

Another K wire is drilled at a level approximately 5 mm distal to the junction point, from the medial edge of the patella to its anterior surface. The K wire is overdrilled with a 4.5-mm cannulated drill to create the second patellar tunnel.

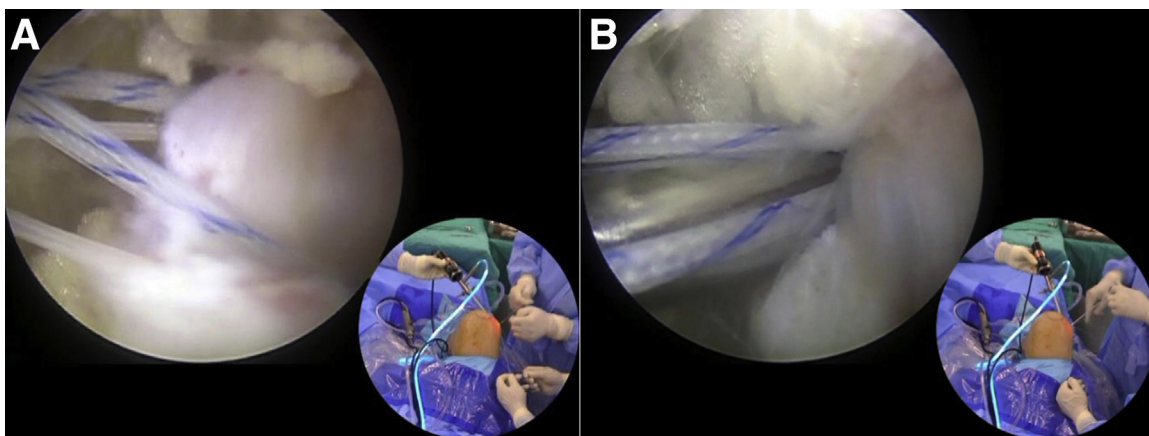


**Fig 1.** Illustrations indicating creating the patellar tunnel and holding the patella with augmenting sutures. (A) Two patellar tunnels are created at a level approximately 5 mm proximal and distal to the junction point of the proximal and middle one third of the patella, from the medial edge of the patella to its anterior surface. (B) Fixation sutures are passed through the distal patellar tunnel from the medial to the lateral side. (C) Fixation sutures are passed through the proximal patellar tunnel from the lateral to the medial side to hold the patella.

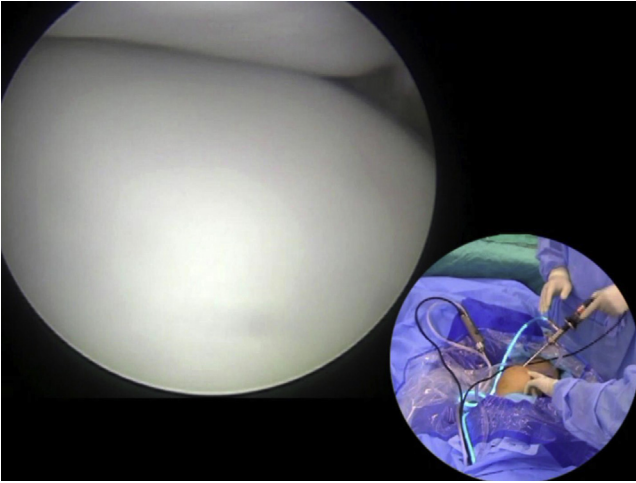
**Fig 2.** Illustrations indicating creating the femoral tunnels (A) at the proximal and distal side of the epiphyseal plate (A) and passing the fixation sutures through the femoral tunnels (B).



**Fig 3.** Illustrations indicating tying the fixation sutures at the lateral side of the distal femur. (A) Anterior view of right knee. (B) Lateral view of right knee.



**Fig 4.** The augmentation sutures are retrieved out through the tissue space resulted from lateral retinaculum release (A) and tied over the bone bridge between the lateral orifices of the femoral tunnel (B) (Arthroscopic views of the lateral side of the distal femur of right knee through the anterolateral portal).



**Fig 5.** The reduction of the patella and the matching of the patellofemoral joint is checked at 30° flexion of the knee (Arthroscopic views of the patellofemoral joint I of right knee through the anterolateral portal).

### Placing Augmenting Sutures Through the Patellar Tunnels

With a guide pin with a tailed suture loop, one guide suture is passed through each patellar tunnel from the medial to the lateral side. With the guide sutures, three No. 2 ultra-high molecular weight polyethylene sutures are passed through the distal patellar tunnel from the medial to the lateral side (Fig 1B) and then through the proximal patellar tunnel from the lateral to the medial side with the guide sutures (Fig 1C). Thus, the augmentation sutures are hung over the bone bridge between the anterior orifices of the patellar tunnels.

### Creating the Femoral Tunnels

The knee is flexed at 90°. A 2- to 3-cm long longitudinal incision is made over the medial femoral epicondyle and the adductor tubercle. The medial

femoral epicondyle, the adductor tubercle, as well the gastrocnemius tubercle is defined through this incision.

According to the preoperative CT examination, the proximal femoral tunnel is located, which is usually proximal and close to the adductor tubercle on the posterior medial edge of the distal femur and created sequentially with a K wire and a 4.5-mm cannulated drill, in a direction perpendicular to the sagittal plane. The drill is pushed through the lateral skin. A polydioxanone suture is placed through the cannulated drill and left in the tunnel following removal of the drill.

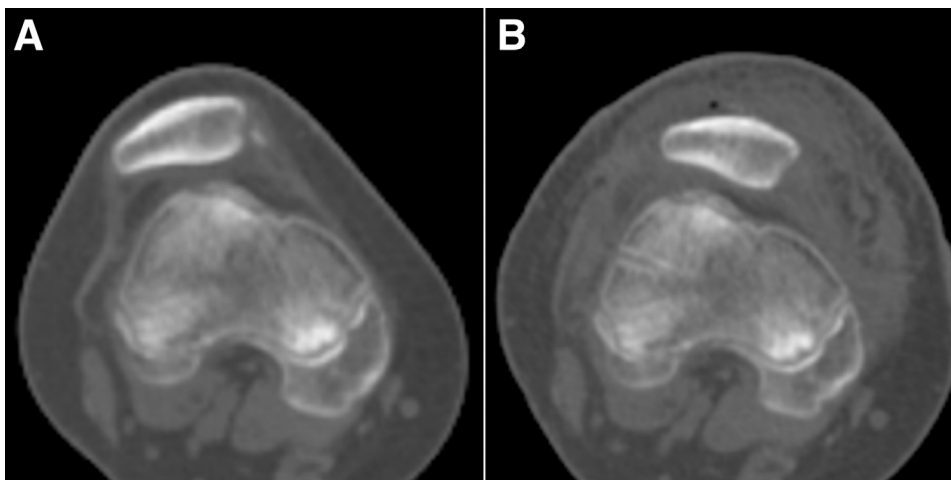
The distal femoral tunnel is located, which is usually at the center of the triangle formed by the adductor tubercle, the medial femoral epicondyle and gastrocnemius tubercle, and created sequentially with a K wire and a 4.5-mm cannulated drill, in a direction perpendicular to the sagittal plane. A polydioxanone suture is placed through this tunnel (Fig 2A).

### Placing Sutures Through the Femoral Tunnels

The augmentation sutures are pulled subcutaneously out of the medial incision. With the 2 PDS suture as guide sutures, the proximal and distal sutures limbs are pulled into the proximal and distal femoral tunnels respectively, out of the lateral thigh (Fig 2B).

### Retrieving Sutures Through the Space Resulting From Lateral Retinaculum Release

A 2-mm lateral incision is made at the anterior edge of the iliotibial band at a level at the proximal pole of the patella. With the knee at full extension, the suture limbs are pulled tight. A shaver is placed through the lateral incision to remove the soft tissue around the suture limbs to expose them. The suture limbs are pulled out of the lateral incision through the space resulted from lateral retinaculum release.



**Fig 6.** Computed tomography images indicating the preoperative lateral deviation (A) and post-operative reduction (B) of the patella.

**Table 2.** Pearls and Pitfalls of Polyethylene Suture Augmentation of the Medial Patellofemoral Ligament in Skeletally Immature Patients With Recurrent Patella Dislocation

1. We consider the current suture augmentation technique is a temporary technique because the high patella position and the tibial tubercle-trochlear groove distance cannot be corrected. Although the short-term clinical result of the current procedure is good, tibial tubercle transfer is still preserved for later stages.
2. Because the sutures are nonabsorbable, the current procedure is recommended not to be used in children whose bony structure of the knee is far from developed. For this condition, we recommend vastus medial plasty.
3. During the location of the patellar tunnels, the superior and inferior poles of the patella should be accurately defined. Needle puncture is an effective method to detect the patella poles.
4. The patellar tunnels go from the medial patella edge to the anterior surface of the patella, as close to the anterior midline. Too medial location of the lateral orifices of the patellar tunnel will result in too much loss of the bone volume and increase the risk of patellar fracture. Too-medial location of the lateral orifices of the patellar tunnels may reduce the controlling force of the sutures to the patella.
5. Even though a single No. 2 ultra-high molecular weight polyethylene suture is strong enough to hold the patella, we still recommend multiple sutures to reduce the potential of suture cutting through the bone.
6. During the location of the femoral tunnels, a fluoroscopy examination can be undertaken. However, preoperative computed tomography is highly recommended for preoperative planning of tunnel location and, in most cases, fluoroscopy can be avoided.
7. The proximal femoral tunnel should not be located too proximally. Otherwise, the isometry of the proximal suture limbs will be affected.
8. Correct location of the medial orifices of the femoral tunnels does not mean there will be no injury to the epiphysal plate. Creating the femoral tunnels perpendicular to the sagittal plane may reduce the risk of injury.
9. During fixation of the augmentation sutures, the knee is flexed at 90°. Fixation of the augmentation sutures at a lesser knee flexion angle may result in overtension in the augmentation sutures, which may cause knee flexion limitation or medial patellofemoral arthritis.

### Fixing the Augmentation Sutures

The knee is flexed at 90°. The sutures are tied over the bone bridge between the lateral orifices of the femoral tunnels (Figs 3 and 4). The reduction of the patella and the matching of the patellofemoral joint is checked at 30° flexion of the knee (Figs 5 and 6).

### Postoperative Rehabilitation

Weight-bearing and range of motion and muscle strengthening exercises begin immediately after operation. Agility training is allowed 6 weeks after operation, depending on the condition of the contralateral leg because patellofemoral dysplasia usually occurs on both legs.

### Discussion

For recurrent patella dislocation in children, we compared medial retinaculum plication and vastus medialis plasty and found medial retinaculum plication is less reliable.<sup>5</sup> However, open vastus medialis plasty is invasive and is indicated only in patients with quadriceps imbalance. For patients without quadriceps imbalance but with recurrent patella dislocation, other MPFL augmentation techniques are needed. Furthermore, our clinical experiences indicate MPFL reconstruction with graft suspension to the adductor magnus tenon and adductor magnus tendon transfer are extremely unreliable, as reported in the literature.<sup>4</sup> The current technique provides a feasible option for this special condition.

The critical point of the current technique is correct location and creation of the femoral tunnels. Preoperative CT examination is helpful to define the exact locations. The location of the distal femoral tunnel is always away from the epiphysal plate. However, the location of the proximal tunnel should be set precisely,

with the desired location at the postural medial ridge of the distal femur, 5 mm proximal to the epiphysal plate. Too-proximal placement of the proximal femoral tunnel may result in unfavorable length-tension features of the proximal augmentation suture limbs. The pearls and pitfalls are listed in Table 2. The potential risk of the current technique is disturbance of the epiphysal plate during creation of the femoral tunnels. The correct location of the femoral tunnel is one way. Creating the femoral tunnel with a small drill is another way.

### References

1. Vellios EE, Trivellas M, Arshi A, Beck JJ. Recurrent patellofemoral instability in the pediatric patient: Management and pitfalls. *Curr Rev Musculoskelet Med* 2020;13:58-68.
2. Abouelsoud MM, Abdelhady A, Elshazly O. Anatomic physeal-sparing technique for medial patellofemoral ligament reconstruction in skeletally immature patients with ligamentous laxity. *Eur J Orthop Surg Traumatol* 2015;25:921-926.
3. Uppstrom TJ, Price M, Black S, Gausden E, Haskel J, Green DW. Medial patellofemoral ligament (MPFL) reconstruction technique using an epiphysal femoral socket with fluoroscopic guidance helps avoid physeal injury in skeletally immature patients. *Knee Surg Sports Traumatol Arthrosc* 2019;27:3536-3542.
4. Alm L, Krause M, Mull C, Frosch KH, Akoto R. Modified adductor sling technique: A surgical therapy for patellar instability in skeletally immature patients. *Knee* 2017;24:1282-1288.
5. Zhao J, Huangfu X, He Y, Liu W. Recurrent patellar dislocation in adolescents: medial retinaculum plication versus vastus medialis plasty. *Am J Sports Med* 2012;40:123-132.
6. Wilkens OE, Hannink G, van de Groes SAW. Recurrent patellofemoral instability rates after MPFL reconstruction techniques are in the range of instability rates after other soft tissue realignment techniques. *Knee Surg Sports Traumatol Arthrosc* 2020;28:1919-1931.