

# Parathyroidectomy Ameliorates Glucose and Blood Pressure Control in a Patient with Primary Hyperparathyroidism, Type 2 Diabetes, and Hypertension

Alok Kumar<sup>1</sup> and Sunita Singh<sup>2</sup>

<sup>1</sup>MK Diabetes Clinic, Ghaziabad, NCR, India. <sup>2</sup>Saraswathi Institute of Medical Sciences (SIMS), Hapur, UP, India.

**ABSTRACT:** Effect of parathyroidectomy on glucose control and hypertension is controversial. Here, we report a case of a patient with primary hyperparathyroidism, type 2 diabetes mellitus, and hypertension in whom parathyroidectomy ameliorated both glucose control and blood pressure. Once high serum calcium levels were noticed, ultrasonography of neck confirmed a well-defined oval hypoechoic mass posterior to the right lobe of the thyroid, confirmed by scintiscan. Parathyroidectomy resulted in improvement of blood pressure and blood glucose. We could stop insulin and antihypertensive medications. We conclude that in patients with type 2 diabetes with vague complaints like fatigue, body ache, and refractory hypertension, as a part of the diagnostic workup, clinicians should also check serum calcium levels and parathyroid hormone to rule out hyperparathyroidism. Correction of hyperparathyroidism may result in improvement of hypertension and glucose control.

**KEYWORDS:** calcium, hyperparathyroidism, parathyroidectomy, glucose control, hypertension

**CITATION:** Kumar and Singh. Parathyroidectomy Ameliorates Glucose and Blood Pressure Control in a Patient with Primary Hyperparathyroidism, Type 2 Diabetes, and Hypertension. *Clinical Medicine Insights: Endocrinology and Diabetes* 2015;8 63–66 doi:10.4137/CMED.S31292.

**TYPE:** Case Report

**RECEIVED:** July 3, 2015. **RESUBMITTED:** August 3, 2015. **ACCEPTED FOR PUBLICATION:** August 5, 2015.

**ACADEMIC EDITOR:** Nigel Irwin, Editor in Chief

**PEER REVIEW:** Four peer reviewers contributed to the peer review report. Reviewers' reports totaled 1,275 words, excluding any confidential comments to the academic editor.

**FUNDING:** Authors disclose no funding sources.

**COMPETING INTERESTS:** Authors disclose no potential conflicts of interest.

**COPYRIGHT:** © the authors, publisher and licensee Libertas Academica Limited. This is an open-access article distributed under the terms of the Creative Commons CC-BY-NC 3.0 License.

**CORRESPONDENCE:** dralokkr@hotmail.com

Paper subject to independent expert blind peer review. All editorial decisions made by independent academic editor. Upon submission manuscript was subject to anti-plagiarism scanning. Prior to publication all authors have given signed confirmation of agreement to article publication and compliance with all applicable ethical and legal requirements, including the accuracy of author and contributor information, disclosure of competing interests and funding sources, compliance with ethical requirements relating to human and animal study participants, and compliance with any copyright requirements of third parties. This journal is a member of the Committee on Publication Ethics (COPE).

Published by Libertas Academica. Learn more about this journal.

## Introduction

Primary hyperparathyroidism (PHPT) is a disorder of calcium metabolism with high levels of serum calcium due to increased levels of parathyroid hormone (PTH). The incidence of PHPT is approximately 25 cases per 100,000 individuals in the general population, and it is more common in women than men.<sup>1</sup>

The prevalence of diabetes mellitus in patients with PHPT and the prevalence of PHPT in diabetic patients is approximately 8% and 1%, respectively, which is higher compared with the prevalence in general population. PHPT occurs prior to diabetes in approximately 20% of patients, and conversely, diabetes mellitus occurs prior to PHPT in 40% of cases. Both disorders present together, or within 1 year, in 40% of cases.<sup>2</sup> Also, approximately 40% of patients with PHPT have impaired glucose tolerance.<sup>2</sup> Hyperparathyroidism may cause insulin resistance probably due to raised intracellular free calcium concentration, increasing the insulin requirement.<sup>2,3</sup>

Effect of the parathyroidectomy on glucose control is controversial. A study has shown that patients with diabetes show improved glycemic control after parathyroidectomy,<sup>4</sup> whereas, other studies showed that parathyroidectomy does not lead to statistically significant insulin dose reduction,<sup>5</sup> and no correlation was found between parathyroidectomy and reduction of insulin doses.<sup>6</sup>

Hypertension is commonly seen in patients with hyperparathyroidism, and 10%–70% of patients with PHPT are found to have hypertension.<sup>7,8</sup> Hyperparathyroidism may induce hypertension, and both conditions may coexist coincidentally.<sup>9</sup> However, the cause of this association is clearly not known. Results of various studies on the effect of parathyroidectomy in resolving hypertension are conflicting. Few studies reported that in hypertensive patients, parathyroidectomy reduces systolic and diastolic blood pressure.<sup>10–12</sup>

In contrast, some other studies reported that parathyroidectomy does not have reliable effect in reducing blood pressure.<sup>13,14</sup> Here, we report a case of a patient with PHPT and type 2 diabetes mellitus in whom parathyroidectomy ameliorated both glucose control and hypertension.

## Case

In April 2013, a 52-year-old female with type 2 diabetes and hypertension for the last 5 years was referred to our diabetes clinic. She had been complaining of fatigue and generalized body pain for a long time. She attributed her symptoms to uncontrolled blood glucose levels and high blood pressure. She was taking oral hypoglycemic agents such as sitagliptin (100 mg per day), metformin (1000 mg twice daily), gliclazide (modified-release 60 mg twice daily), voglibose (0.3 mg twice daily), olmesartan (40 mg once daily), hydrochlorothiazide

(12.5 mg once daily), and carvedilol (3.125 mg twice daily) for managing high blood pressure. On examination, her body mass index was 21.7 kg/m<sup>2</sup> and blood pressure was 160/90 mmHg. Control of blood glucose was poor, as her latest glycosylated hemoglobin (HbA1c) was 11.9%. We decided to discontinue gliclazide and voglibose and added insulin premix (30:70) 14 units before breakfast and dinner, in order to manage high glucose levels. The doses of sitagliptin and metformin were maintained. Along the aforementioned anti-hypertensive drugs, the dihydropyridine-type calcium channel blocker amlodipine (5 mg daily) was added.

While going back through her past medical records, it was noticed that, in January 2013, her serum calcium value was slightly above the upper normal limit, 11.85 mg/dL (reference range 8.8–10.6 mg/dL), with high to normal serum alkaline phosphatase (122 U/L, reference range 30–122 U/L), and slightly low 25 (OH) vitamin D3 levels (26.8 ng/mL, normal values >30 ng/mL).

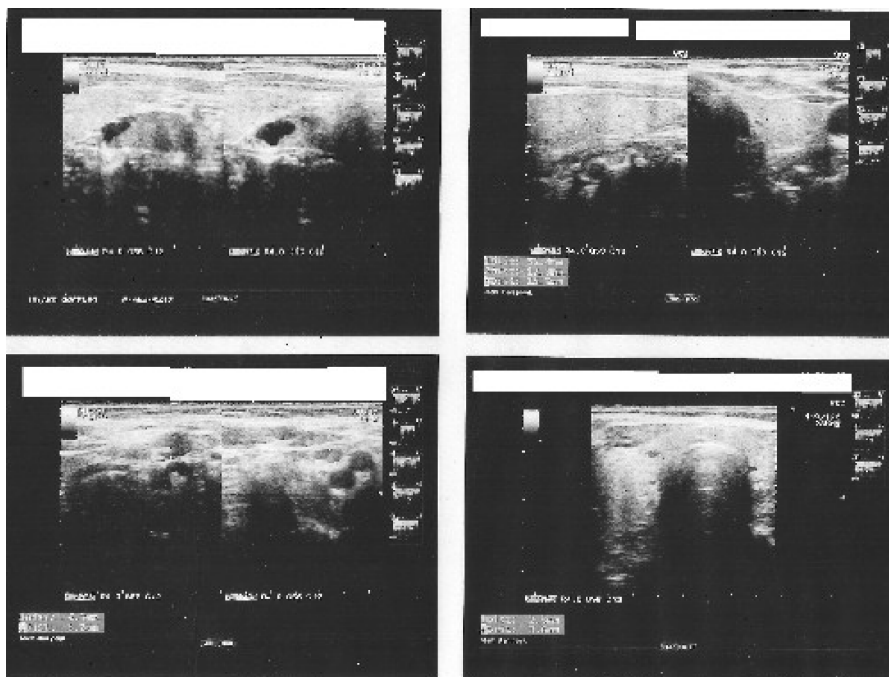
On a subsequent visit, her blood pressure was 152/84 mmHg. Her biochemical reports revealed the following: HbA1c 10.3%, serum calcium 11.55 mg/dL (reference 8.8–10.6 mg/dL), serum phosphate 3.76 mg/dL (reference 2.4–4.4 mg/dL) serum alkaline phosphatase 160 U/L (reference 30–120 U/L), and 25 (OH) vitamin D3 20.6 ng/mL (reference <30 ng/mL [insufficient], <20 ng/mL [deficient]). Keeping in mind the two calcium levels that were above the upper normal limit, some further investigations were done to find out the cause of hypercalcemia: serum albumin 4.28 g/dL (reference range 3.5–5.2 g/dL), PTH 206 pg/mL (reference range

15.0–68 pg/mL), thyroid-stimulating hormone 1.575 uIU/mL (0.5–4.780 uIU/mL), free T4 1.13 ng/dL (0.89–1.76 ng/dL), and free T3 3.45 pg/mL (2.3–4.2 pg/mL).

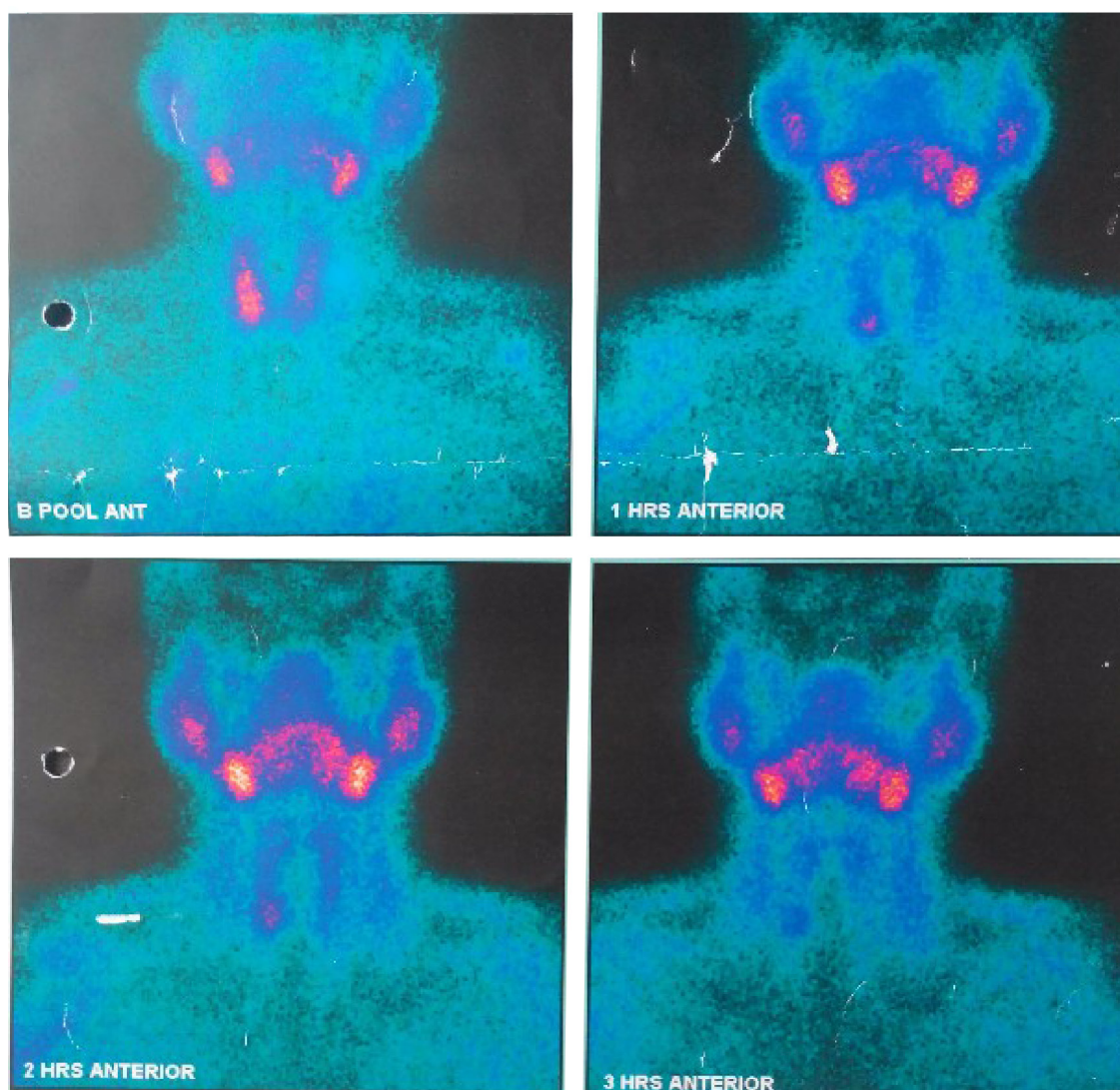
Diagnosis of PHPT was made, and ultrasonography of the neck was performed. A well-defined oval hypoechoic mass posterior to the right lobe of the thyroid was noticed. The lesion measured 19.6 mm superior inferior (SI) × 12.3 mm transverse (TR) × 8.5 mm anterior posterior (AP), was largely hypoechoic, and showed small cystic/necrotic change within (Fig. 1). No significant vascularity was seen on color Doppler.

The parathyroid 99mTc-sestamibi scintigraphy confirmed the parathyroid lesion (Fig. 2). The patient underwent right inferior parathyroidectomy. Histopathological examination of the nodule proved that it was parathyroid adenoma. Microscopic sections showed an encapsulated lesion made up of monomorphic small cells with dense nuclear chromatin. These cells showed perivascular arrangement. No capsular or vascular invasion was seen. Postoperative period was uneventful. Her serum calcium after parathyroidectomy was 9.8 mg/dL (reference 8.8–10.6 mg/dL).

After surgery, her insulin dose was tapered and eventually withdrawn after 4 weeks due to frequent episodes of hypoglycemia. However, sitagliptin 100 mg once daily and metformin 1,000 mg twice daily were continued. Her antihypertensive medications were also reduced and gradually stopped due to frequent reading of low blood pressure. Three months later, her HbA1c was 7.2% and blood pressure was 128/70 mmHg. Her quality of life had improved. She did not complain of fatigue and generalized body aches. In the following months,



**Figure 1.** High-resolution ultrasonography of neck showing a well-defined oval hypoechoic mass in the region of parathyroid, posterior to the right lobe of thyroid. The lesion measured 19.6 mm (SI) × 12.3 mm (TR) × 8.5 mm (AP), was largely hypoechoic, and showed a small cystic/necrotic change within it.



**Figure 2.** 99mTc-MIBI radioisotope dual-phase parathyroid scan. A 30-min image showing an area of increased uptake in the lower pole of the right lobe. Delayed images (1–3 hours) show prolonged tracer retention with minimal washout in the area of increased tracer concentration adjacent to the lower pole of the right lobe.

her glycemic control and blood pressure were maintained in the normal range without addition of other oral hypoglycemic and antihypertensive drugs. Twenty-two months after surgery, her most recent HbA1c was 7.1% and blood pressure was 122/76 mmHg.

### Discussion

PHPT may cause insulin resistance, leading to derangement in carbohydrate metabolism,<sup>2,3</sup> and after parathyroidectomy, the diabetic condition shows improvement in glycemic control.<sup>4</sup> However, some studies have found no statistically significant correlation between parathyroidectomy and glycemic control.<sup>5,6</sup>

Increased levels of intracellular free calcium ( $\text{Ca}^{++}$ ) probably interfere with tyrosine kinase activity of insulin receptor and the intrinsic activity of glucose transporters at the post-binding steps of insulin action.<sup>15</sup> PHPT can also be a cause of

hypertension, by increasing serum calcium and plasma renin activity.<sup>9,16,17</sup> Studies have shown a relation between high calcium levels and high PTH levels and hypertension.

Correction of hyperparathyroidism reduces intracellular calcium and also the plasma renin activity due to the renal vasodilatory effect.<sup>10</sup> Parathyroidectomy can stabilize or improve glucose control in patients with diabetes mellitus<sup>4,18</sup> and also improve blood pressure in some patients.<sup>10</sup> Effect of parathyroidectomy on glucose control and blood pressure has been controversial, and there is no firm evidence for a relationship between PHPT and cardiovascular or metabolic diseases.<sup>19</sup> The reason for varying results of different studies looking at the effect of parathyroidectomy on glycemic control and blood pressure is not clear. However, these discrepancies in results can be attributed to the difference in the population size and duration of follow-up period in various studies.<sup>20</sup> To get further clarity, long-term studies are required to assess



the effect of parathyroidectomy on glucose control and blood pressure.

In this case we demonstrated that parathyroidectomy resulted in improvement of glucose and blood pressure levels in a woman with type 2 diabetes and hypertension, so that insulin and antihypertensive medications were withdrawn.

### Conclusion

We conclude that in patients with type 2 diabetes complaining of fatigue, body ache, and refractory hypertension, as a part of diagnostic workup, clinicians should also check serum calcium levels and PTH to rule out hyperparathyroidism. Correction of hyperparathyroidism may result in improvement of hypertension and glucose control.

### Author Contributions

Conceived the concepts: AK. Analyzed the data: AK. Wrote the first draft of the manuscript: AK. Contributed to the writing of the manuscript: AK, SS. Made critical revisions and approved final version: AK. All authors reviewed and approved of the final manuscript.

### REFERENCES

- Bilezikian JP, Silverberg SJ. Clinical practice. Asymptomatic primary hyperparathyroidism. *N Engl J Med*. 2004;350:1746–1751.
- Taylor WH, Khaleeli AA. Coincident diabetes mellitus and primary hyperparathyroidism. *Diabetes*. 2001;17(3):175–180.
- Ybarra J, Doñate T, Jurado J, Pou JM. Primary hyperparathyroidism, insulin resistance and cardiovascular disease: a review. *Nurs Clin North Am*. 2007;42:79–85.
- Cheung PS, Thompson NW, Brothers TE, Vinik AI. Effect of hyperparathyroidism on the control of diabetes mellitus. *Surgery*. 1986;100(6):1039–1047.
- Bannon MP, van Heerden JA, Palumbo PJ, Ilstrup DM. The relationship between primary hyperparathyroidism and diabetes mellitus. *Ann Surg*. 1988;207(4):430–433.
- Wermers RA, Khosla S, Atkinson EJ, Achenbach SJ, Oberg AL, Grant CS. Incidence of primary hyperparathyroidism in Rochester, Minnesota, 1993–2001: an update on the changing epidemiology of the disease. *J Bone Miner Res*. 2006;21(1):171–177.
- Hellstrom J, Birke G, Edvall CA. Hypertension in hyperparathyroidism. *Br J Urol*. 1958;30:13–24.
- Diamond TW, Botha JR, Wing J. Parathyroid hypertension: a reversible disorder. *Arch Intern Med*. 1986;146(9):1709–1712.
- Niederle B, Roka R, Woloszczuk W, Klaushofer K, Kovarik J, Scherthauer G. Successful parathyroidectomy in primary hyperparathyroidism: a clinical follow up study of 212 consecutive patients. *Surgery*. 1987;102:903–909.
- Broulik PD, Brouliková A, Adámek S, et al. Improvement of hypertension after parathyroidectomy of patients suffering from primary hyperparathyroidism. *Int J Endocrinol*. 2011;2011:309068.
- Heyliger V, Tangpricha C, Weber C, Sharma J. Parathyroidectomy decreases systolic and diastolic blood pressure in hypertensive patients with primary hyperparathyroidism. *Surgery*. 2009;146(6):1042–1047.
- Dluhy RG, Williams RH. Endocrine hypertension. In: Williams RH, Wilson JD, eds. *Williams Textbook of Endocrinology*. 9th ed. Philadelphia: Saunders; 1998:729–749.
- Feldstein CA, Akopian M, Pietrobelli D, Olivieri A, Garrido D. Long-term effects of parathyroidectomy on hypertension prevalence and circadian blood pressure profile in primary hyperparathyroidism. *Clin Exp Hypertens*. 2010;32(3):154–158.
- Sancho JJ, Rouco J, Riera-Vidal R, Sitges-Serra A. Long-term effects of parathyroidectomy for primary hyperparathyroidism on arterial hypertension. *World J Surg*. 1992;16:732–735. discussion 736.
- Draznin B, Lewis D, Houlder N, et al. Mechanism of insulin resistance induced by sustained levels of cytosolic free calcium in rat adipocytes. *Endocrinology*. 1989;125:2341–2349.
- Horký K, Broulik PD, Pacovský V. The effect of parathyroid hormone on plasma renin activity in humans and hypertension in patients with primary hyperparathyroidism. *J Hypertens*. 1986;4:S585–S587.
- Broulik PD, Horký K, Pacovský V. Effect of parathyroid hormone on plasma renin activity in humans. *Horm Metab Res*. 1986;18(7):490–492.
- Richards ML, Thompson NW. Diabetes mellitus with hyperparathyroidism: another indication for parathyroidectomy? *Surgery*. 1999;126(6):1160–1166.
- Bilezikian JP, Brandi ML, Eastell R, et al. Guidelines for the management of asymptomatic primary hyperparathyroidism: summary statement from the Fourth International Workshop. *J Clin Endocrinol Metab*. 2014;99:3561–3569.
- Garcia de la Torre N, Wass JA, Turner HE. Parathyroid adenomas and cardiovascular risk. *Endocr Relat Cancer*. 2003;10:309–322.