

Double trouble with the disc - Hickam's dictum versus Occam's razor!

Sujatha V Kadambi, Vijaya Lingam, Smita Praveen¹,
Durga Priyadarshini¹, Ronnie George

Differentiating glaucomatous and non-glaucomatous optic neuropathy can be challenging even to an experienced clinician and it is even more complex to identify early ophthalmic manifestation of neurological lesions when the optic nerve is already jeopardized by advanced glaucoma. This is a case of a patient with juvenile open-angle glaucoma with advanced glaucomatous cupping who developed an intracranial tuberculoma and subsequent obstructive hydrocephalus. Subtle edema identified in an almost totally damaged nerve, coupled with a history of headache and tinnitus, was the clinching factor prompting early treatment in the form of ventriculoperitoneal shunting and antituberculous therapy. Detailed history, systematic clinical exam, and appropriate imaging are imperative in reducing morbidity and sometimes mortality associated with these neurological conditions.

Key words: Disc edema, hydrocephalus, juvenile glaucoma, non-glaucomatous neuropathy, tuberculoma

Occam's razor principle in case solving tells the clinician to look for the most simple and unifying diagnosis which could explain all of a patient's problems. It's counter argument, the Hickam's dictum says 'a patient can have as many diagnoses as he darn well pleases' and cautions one from being biased and misled by the first recognizable pattern. This is an interesting case where the Hickam's dictum reigns supreme over Occam's razor principle. It describes a patient with juvenile open-angle glaucoma with advanced glaucomatous cupping and early cataractous changes who presented with sudden unexplained vision loss in her only seeing eye. Recognizing subtle edema in a nerve already lost to glaucomatous optic atrophy was challenging and coupled with a history of headache and tinnitus, was the connect factor in prompting imaging and clinching the diagnosis. It reinforces

the importance of systematic history and meticulous clinical exam in case solving.

Case Report

A 27-year-old lady with juvenile-onset open-angle glaucoma presented to our clinic with a history of sudden drop in vision in the left eye since two months.

Her left eye had advanced glaucomatous damage uncontrolled on medical therapy for which she had undergone trabeculectomy nearly two years ago, which was uneventful intra- and postoperatively. At this visit when she presented to us, her vision had dropped from 20/50 to 20/200 over a 2-month period.

Her right eye, an absolute eye since 5 years was asymptomatic on intraocular pressure-lowering agents.

On examination, her left eye had a large cystic bleb which was seidel's negative and she had an early posterior subcapsular cataract [Fig. 1]. Intraocular pressure was 10 mm Hg on no medication. Extraocular movements were full in range and painless.

Fundus examination in the right eye revealed glaucomatous optic atrophy. The optic disc in the left eye was pale, tilted with apparent reduction in cup size from 0.9 to 0.6, blurring of disc margins, superior glial tissue, and inferior peripapillary atrophy [Fig. 2]. There were a few retinal pigment epithelium alterations at the macula. However, optical coherence tomography (OCT) macula showed a normal foveal contour. The disc showed edema with subretinal fluid surrounding the disc and schitic changes were noted nasal to disc. Neural canal margins were displaced [Fig. 3].

The patient had advanced tubular visual fields with a split macular fixation on Humphrey visual fields 10-2.

She denied any history of trauma/blebitis, which could have led to intermittent bleb leak and hypotony. When a potential acuity meter test was done, vision improved to 20/320. This raised the question, whether it was the early posterior subcapsular cataract (otherwise thought to be noncontributory) being responsible for significant visual obscuration, (in the mesopic/undilated pupil state as her visual field was already advanced and tubular). But this fact could not explain the disc picture, as the patient had disc edema not related to hypotony. So a cross-referral to neuro-ophthalmology was made.

On reviewing the clinical history with the patient again, we elicited complaints of headache and tinnitus suggestive of raised intracranial pressure. She did not have any altered sensorium or focal neurological deficits. When Magnetic resonance imaging (MRI) was done, a right cerebellar space-occupying lesion was detected [Fig. 4].

| Access this article online | |
|---|--|
| Quick Response Code: | Website: www.ijjo.in |
|  | DOI: 10.4103/ijjo.IJO_825_20 |
| | |

Smt Jadhavbai Nathmal Singhvee Glaucoma Services, Sankara Nethralaya, Medical Research Foundation, ¹Department of Neuro Ophthalmology, Sankara Nethralaya, Medical Research Foundation, Chennai, India

Correspondence to: Dr. Sujatha V Kadambi, Smt Jadhavbai Nathmal Singhvee Glaucoma Services, Sankara Nethralaya, Medical Research Foundation, Chennai-600006, India. E-mail: drsja@snmail.org

Received: 14-Apr-2020
Accepted: 21-Sep-2020

Revision: 07-Jul-2020
Published: 26-Oct-2020

This is an open access journal, and articles are distributed under the terms of the Creative Commons Attribution-NonCommercial-ShareAlike 4.0 License, which allows others to remix, tweak, and build upon the work non-commercially, as long as appropriate credit is given and the new creations are licensed under the identical terms.

For reprints contact: WKHLRPMedknow_reprints@wolterskluwer.com

Cite this article as: Kadambi SV, Lingam V, Praveen S, Priyadarshini D, George R. Double trouble with the disc - Hickam's dictum versus Occam's razor! Indian J Ophthalmol 2020;68:2605-7.

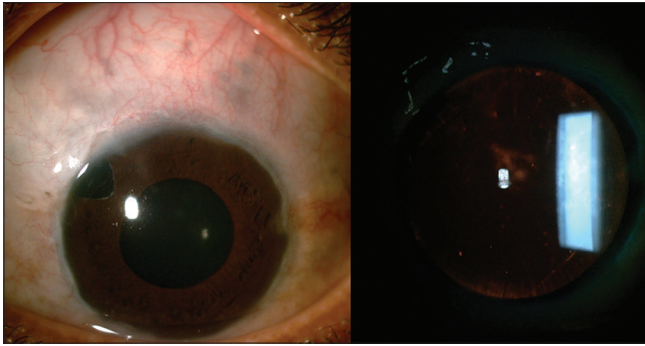


Figure 1: Anterior segment image of left eye showing large cystic bleb, seidel's negative, formed anterior chamber and early posterior subcapsular cataract

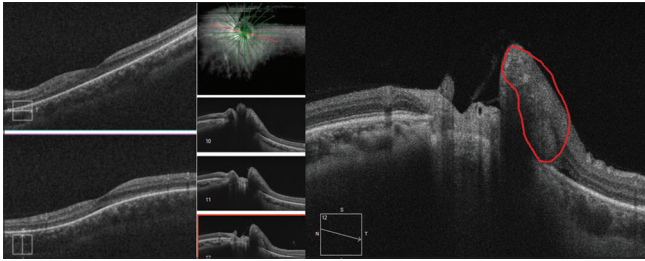


Figure 3: OCT macula showing normal foveal contour. OCT disc showing subretinal fluid and schitic changes nasal to disc

She underwent ventriculo peritoneal shunt followed by suboccipital craniectomy and tumor excision. Cerebrospinal fluid analysis revealed *Mycobacterium tuberculosis* and histopathology was suggestive of tuberculoma. She was started on Antitubercular treatment and low-dose steroids. At one month review, the patient was symptomatically better. Disc edema had begun to resolve but visual acuity remained unchanged.

Discussion

In this case, the right eye had glaucomatous optic atrophy, a complete loss of axons, hence no axoplasmic stasis and no manifest disc edema, while the left eye had a few remnant nerve fibers manifesting as edema in a small sector of the disc. A brief review of literature and studies on when to do neuroimaging in a cupped disc with normal intraocular pressure, when to suspect a non-glaucomatous optic neuropathy, and diagnostic yield of these indicators is summarised in Table 1.^[1-3]

This case is intriguing as both the glaucomatous and neurological conditions were co-existing, increasing the complexity and none of these enlisted points could direct towards diagnosis. The clinching factor was history of headache, tinnitus and the peculiar appearance of the disc.

Intracranial tuberculosis is a serious form of tuberculosis (TB) and constitutes 1% of active cases of TB.^[4] Tuberculoma is the second most common manifestation of CNS TB, constituting 20-30% of space-occupying lesions in the brain. It is insidious in onset, may not have associated systemic symptoms and sometimes can co-exist with TB meningitis. Clinical presentation is related to mass effect of lesion and can be focal seizures, raised intracranial pressure or focal neurological deficits.^[5] Initiation of treatment in the early stage is the single

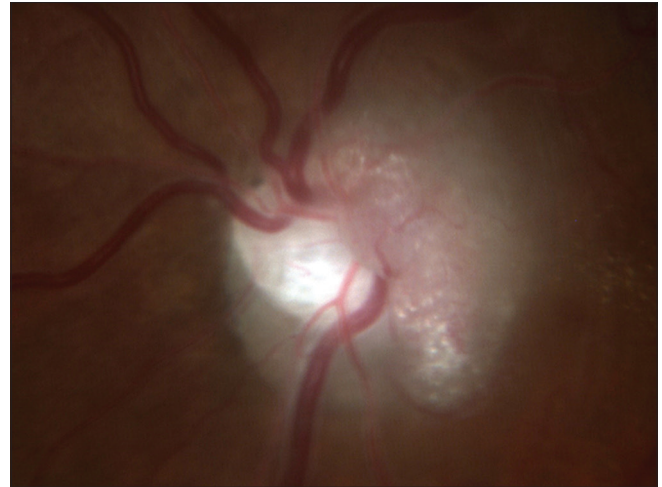

Figure 2: Disc picture showing tilted anomalous disc with subtle edema

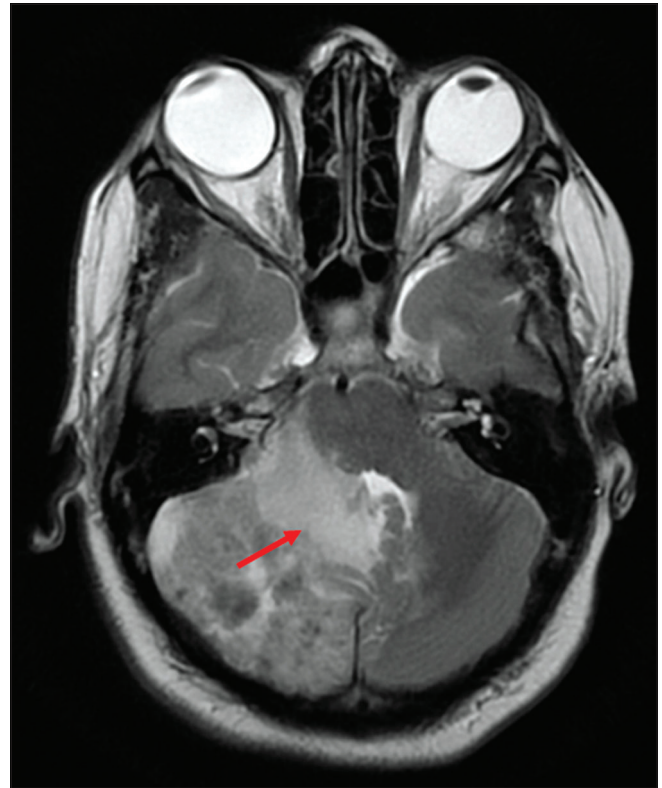


Figure 4: MRI showing right cerebellar space occupying lesion causing mass effect on brainstem and vermis. This leads to a mass effect over fourth ventricle and aqueduct of sylvius causing obstructive hydrocephalus of lateral and third ventricle

most important predictor to decrease morbidity and mortality associated with CNS TB.^[6]

In our patient, the only sign was papilledema, which was also subtle as the nerve was already compromised due to glaucomatous optic neuropathy. OCT, if done in the fellow eye as well, would have possibly shown displacement of neural canal borders.^[7]

Conclusion

Detailed history, meticulous clinical evaluation, and appropriate imaging is essential to differentiate glaucomatous and non-

Table 1: Diagnostic yield of indicators that help differentiate non-glaucomatous and glaucomatous optic neuropathy

| Criteria | Specificity (%) | Sensitivity (%) |
|---|-----------------|-----------------|
| Age <50 years | 93 | 46 |
| Visual acuity <20/40 | 77 | 52 |
| Pallor more than cupping | 90 | 45 |
| Visual field respecting vertical meridian | 81 | 47 |
| Unilateral or highly asymmetric | 79 | 42 |

*Sudden rapidly progressive vision loss, diplopia, severe headache, vision loss occurring relatively early in the disease, impaired colour vision early in the disease which parallels visual acuity decline, poor correlation between disc cupping and field loss, poor correlate between disc cupping and visual acuity are other important differentiating factors

glaucomatous optic neuropathy and assumes even greater significance when the two co-exist. Prompt and appropriate management of these intracranial lesions with neuro-ophthalmic manifestations can be potentially sight and lifesaving.

Declaration of patient consent

The authors certify that they have obtained all appropriate patient consent forms. In the form the patient(s) has/have given his/her/their consent for his/her/their images and other clinical information to be reported in the journal. The patients understand that their names and initials will not be published

and due efforts will be made to conceal their identity, but anonymity cannot be guaranteed.

Financial support and sponsorship

Nil.

Conflicts of interest

There are no conflicts of interest.

References

1. Greenfield DS, Siatkowski RM, Glaser JS, Schatz NJ, Parrish RK II. Cupped disc. Who needs neuroimaging? *Ophthalmology* 1998;105:1866-74.
2. Ahmed II, Feldman F, Kucharczyk W, Trope GE. Neuroradiologic screening in normal-pressure glaucoma: Study results and literature review. *J Glaucoma* 2002;11:279-86.
3. Choudhari NS, Neog A, Fudnawala V, George R. Cupped disc with normal intraocular pressure: The long road to avoid misdiagnosis. *Indian J Ophthalmol* 2011;59:491-7.
4. Nicolls DJ, King M, Holland D, Bala J, del Rio C. Intracranial tuberculomas developing while on therapy for pulmonary tuberculosis. *Lancet Infect Dis* 2005;5:795-801.
5. Mukherjee S, Das R, Begum S. Tuberculoma of the brain – A diagnostic dilemma: Magnetic resonance spectroscopy a new ray of hope. *J Assoc Chest Physicians* 2015;3:3-8.
6. Cherian A, Thomas SV. Central nervous system tuberculosis. *Afr Health Sci* 2011;11:116-27.
7. Kupersmith MJ. Optical imaging of the optic nerve. *J Neuro-Ophthalmol* 2015;35:210-9.