



Case Report

# Spontaneous improvement of secondary empty sella syndrome due to re-expansion of an intrasellar cyst: A case report

Shodai Yamada<sup>1</sup>, Kenji Yagi<sup>1</sup>, Kazuhiro Hirano<sup>2</sup>, Masaaki Uno<sup>1</sup>

<sup>1</sup>Department of Neurosurgery, Kawasaki Medical School, Kurashiki, <sup>2</sup>Department of Neurosurgery, Okayama Central Hospital, Okayama, Japan.

E-mail: Shodai Yamada - girudora1987@gmail.com; \*Kenji Yagi - kenji-yagi@mail.goo.ne.jp; Kazuhiro Hirano - hirano\_k@kohjin.ne.jp; Masaaki Uno - muno@med.kawasaki-m.ac.jp

\*Corresponding author:

Kenji Yagi,  
Department of Neurosurgery,  
Kawasaki Medical School,  
577 Matsushima, Kurashiki  
7010192, Okayama, Japan.

kenji-yagi@mail.goo.ne.jp

Received : 24 April 2020

Accepted : 18 July 2020

Published : 12 September 2020

DOI

10.25259/SNI\_212\_2020

Quick Response Code:



## ABSTRACT

**Background:** In patients with secondary empty sella syndrome (ESS), optic nerve herniation into the sella turcica is caused by shrinkage of the mass lesion at the sella turcica, resulting in visual disturbance. ESS is often surgically treated using chiasmepexy. Here, we report the first case of spontaneous improvement in a patient with ESS.

**Case Description:** A 69-year-old woman presented with a month-long history of visual disturbance in the right eye, poor visual acuity, and quadrantanopia in her upper temporal visual field. Magnetic resonance (MR) imaging showed herniation of her right optic nerve and gyrus rectus into the sella turcica. The visual disturbance gradually improved, and the patient's vision became almost normal after a month without any treatment. On repeated MR imaging, it was observed that the herniation of the right optic nerve and gyrus rectus disappeared due to an intrasellar cyst re-expansion. The secondary ESS caused by the shrinkage of the intrasellar cyst resulted in the visual disturbance and re-expansion of the cyst resulted in spontaneous improvement of symptoms. The visual disturbance did not recur for a year.

**Conclusion:** Patients with secondary ESS without severe symptoms may be followed up conservatively. However, surgical treatment should be applied if symptoms deteriorate or do not improve.

**Keywords:** Chiasmepexy, Rathke's cleft cyst, Secondary empty sella syndrome, Visual disturbance

## INTRODUCTION

Empty sella syndrome (ESS) has been reported to occur in 5.5% of patients with pituitary disease.<sup>[2]</sup> This can result in damage to optic nerve cells due to the downward herniation of the optic nerve, optic nerve tract, and chiasm, thereby resulting in visual impairments such as loss of vision, visual field impairment, and color blindness. ESS is classified as primary or secondary ESS according to the pathogenesis. Primary ESS is idiopathic, and herniation of the optic nerve into the sella turcica has been attributed to congenital defects of the diaphragm. In secondary ESS, the herniation of the optic nerve is associated with adhesion of the diaphragm and optic nerve. After shrinkage of a lesion in the sella turcica or removal of the mass lesion, the diaphragm might be herniated into the sella turcica together with the optic nerve.<sup>[4]</sup>

Patients with secondary ESS could theoretically recover if the intrasellar lesion re-expands and the herniated optic nerve returns to its original position. However, such a case has never been reported in the literature. Rather, patients with secondary ESS have been surgically treated by chiasmectomy to relocate and fix the herniated optic nerve at the suprasellar and its normal site.<sup>[1]</sup> Here, we report a very rare case of secondary ESS which was improved by spontaneous re-expansion of the intrasellar cyst.

### CASE DESCRIPTION

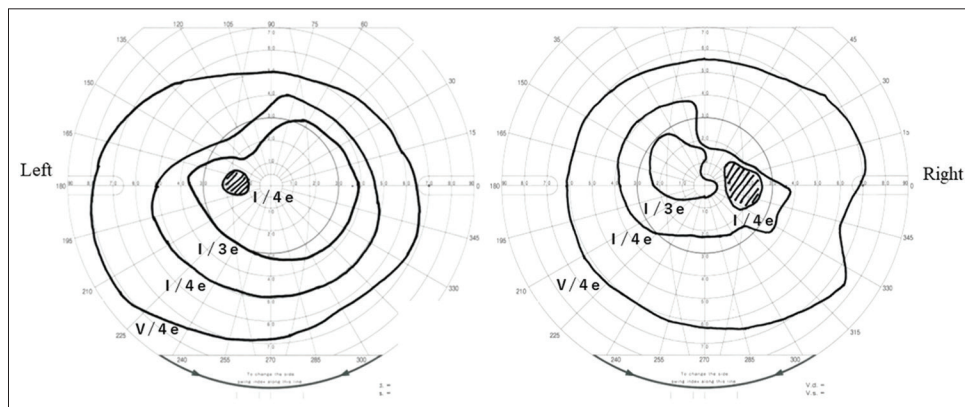
A 69-year-old woman presented with a month-long history of poor eye sight in her right eye. She had hypertension and diabetes mellitus and had previously undergone surgeries to remove cancers in her breast 9 years ago and in her lung 2 years ago. Her recovery from these past surgeries was uneventful with no recurrence.

Her right eye vision was remarkably disturbed, while her left eye vision was not remarkably impaired. Corrected visual acuity in the right eye was 20/100, which was 20/25 previously. In a visual field test by Goldmann perimetry, a remarkable upper temporal visual field defect and slight defect were observed in the right and left eye, respectively [Figure 1]. No other neurological

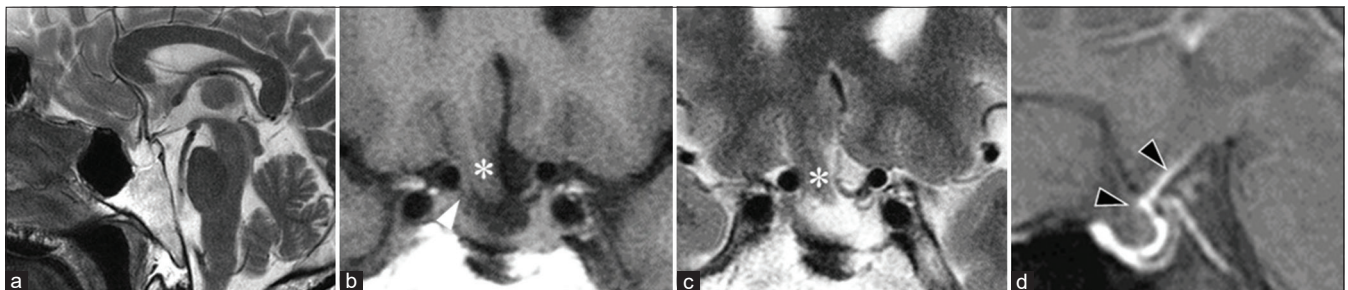
deficit was identified. Magnetic resonance (MR) imaging showed herniation of her right optic nerve and gyrus rectus into the sella turcica, which was considered to have resulted in the visual disturbance [Figure 2]. The blood examination showed no remarkable pituitary dysfunction. Surgical treatment was planned; however, the visual disturbance gradually improved, and the patient's vision returned to almost normal after a month. Corrected visual acuity was 20/25 in the right eye and 20/20 in the left, while only a slight visual defect was left in the right eye [Figure 3]. MR imaging at the time (1 month post presentation) showed the disappearance of the optic nerve and rectal gyrus herniation due to the expansion of the intrasellar cyst [Figure 4]. MR imaging at 3 months postpresentation showed that the bilateral optic nerves were cranially dislocated [Figure 5], while the visual disturbance was almost absent with a very narrow and slight temporal defect of the visual field in her right eye. The visual disturbance was attributed to secondary ESS and improved due to the re-expansion of the intrasellar cyst. Repeat blood examination still showed no remarkable pituitary dysfunction. The visual disturbance did not recur for a year.

### DISCUSSION

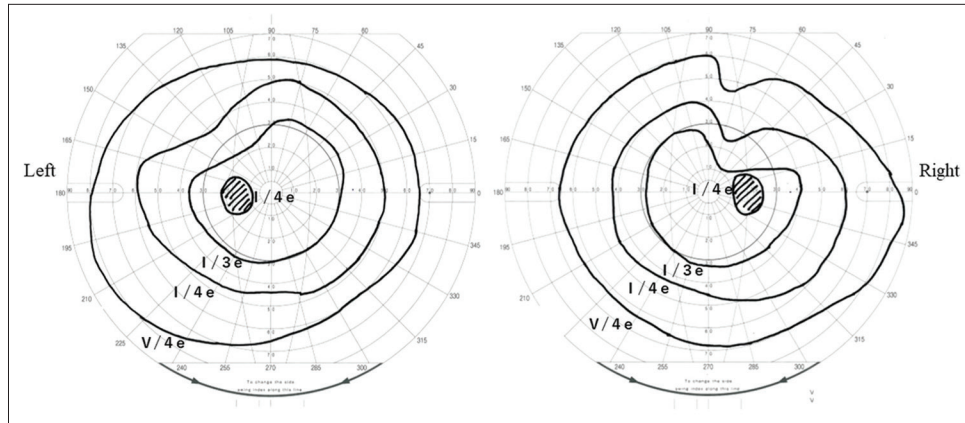
In our patient with secondary ESS, visual disturbance improved due to spontaneous expansion of the intrasellar



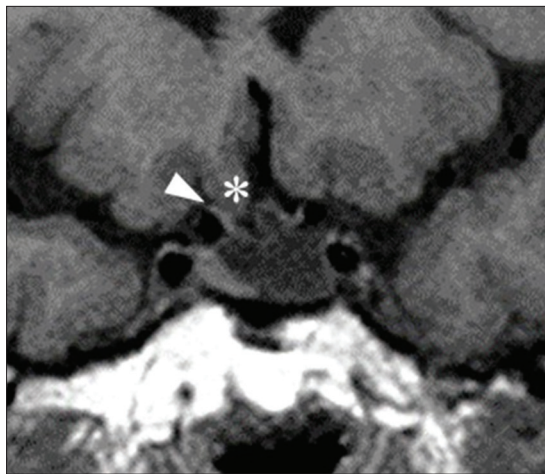
**Figure 1:** Visual field test at presentation. A remarkable upper temporal visual field defect and slight defect were observed in the right and left eye, respectively.



**Figure 2:** Magnetic resonance (MR) imaging at presentation. On sagittal of T2-weighted image (a) and coronal sections of (b) T1- and (c) T2-weighted images, herniation of the gyrus rectus (\*) and right optic nerves (white arrow head) is shown. The sagittal section of contrasted fat-saturated T1-weighted MR image (d) shows an enhancement at the diaphragm (black arrow head).



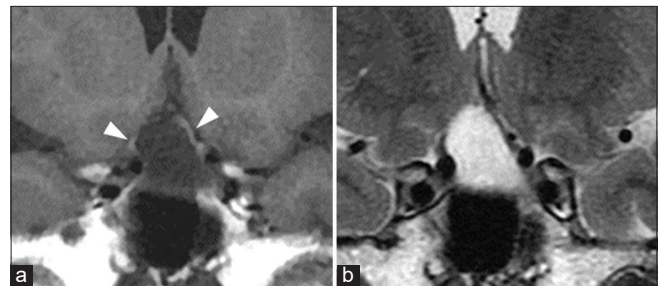**Figure 3:** Visual field test at presentation at 1 month post presentation. Defect of visual fields was well improved although an only slight visual defect was left in the right eye.



**Figure 4:** Coronal sections of the repeated T1-weighted magnetic resonance images at 1 month post presentation. The herniation of the right optic nerve (arrow head) and gyrus rectus (\*) improved.

cyst under a conservative follow-up. To the best of our knowledge, this is the first reported case of spontaneous improvement in a patient with ESS.

Secondary ESS is caused by downward herniation of the diaphragm adhered to the optic nerve.<sup>[1,6]</sup> Adhesion of the diaphragm and the suprasellar tissue is attributed to focal inflammation, which can be induced by surgery, radiotherapy, drug treatment, autoimmune diseases, infection, trauma, or long-existing tumors. Suprasellar inflammation is observed by enhanced diaphragm on contrast MR imaging, consistent with the present case.<sup>[6]</sup> Previously reported cases of secondary ESS occurred after treatment for tumors or cysts in the sella turcica.<sup>[3,7]</sup> However, our case presented with secondary ESS that spontaneously occurred without any treatment for an intrasellar cystic lesion, which might be attributed to the rupture of an intrasellar cyst. Although a histological examination of the lesion was not performed,



**Figure 5:** Coronal sections of repeated (a) T1- and (b) T2-weighted magnetic resonance images at 3 months post presentation. The bilateral optic nerves were cranially dislocated, resulting in remarkable expansion of the intrasellar cyst (arrow head). The contents of the cyst had a signal similar to signals of cerebrospinal fluid.

it may have been a Rathke's cleft cyst based on the radiographical findings. Because Rathke's cleft cysts could rupture and shrink spontaneously, inflammation-associated adhesion around the diaphragm and herniation of the optic nerve could occur without any treatment for the cyst.<sup>[6]</sup>

Surgeries have been performed for secondary ESS and various methods of chiasmectomy, to relocate and fix the herniated suprasellar tissue, including the optic nerve.<sup>[1,5]</sup> A transsphenoidal approach is preferred over a transcranial approach. With or without intradural procedures to dissect the chiasma from the diaphragm, the diaphragm is elevated using various materials such as the bone, cartilage, muscle, fascia, fat, and silicon products, resulting in relocating and fixing the herniated optic nerve at the suprasellar and its normal site.<sup>[1]</sup> However, spontaneous improvement of secondary ESS has not been previously reported in the literature. The reduction of the visual disturbance was attributed to the re-expansion of the cyst. In addition, secondary ESS in our case occurred spontaneously with no association to treatment for an intrasellar lesion, which

has not been previously reported. Secondary ESS due to an intrasellar cyst may improve spontaneously. The prognoses may differ between patients who show improvement after spontaneous rupture of the intrasellar cyst and those treated for reduction of the intrasellar mass. In a patient in whom secondary ESS improved due to expansion of the intrasellar cyst, a careful and close follow-up might be needed. If visual disturbance recurred for further expansion of the intrasellar cyst, the cyst drainage with chiasmectomy might be needed.

## CONCLUSION

A patient without a severe symptom may be followed up conservatively. However, surgical treatment should be applied if the symptoms deteriorate or do not improve.

## Ethical approval

All procedures performed in studies involving human participants were in accordance with the ethical standards of the institutional and/or national research committee and with the 1964 Helsinki declaration and its later amendments or comparable ethical standards. Informed consent was obtained from the individual participant included in the study.

## Declaration of patient consent

The authors certify that they have obtained all appropriate patient consent.

## Financial support and sponsorship

Nil.

## Conflicts of interest

There are no conflicts of interest.

## REFERENCES

1. Barzaghi LR, Donofrio CA, Panni P, Losa M, Mortini P. Treatment of empty sella associated with visual impairment: A systematic review of chiasmectomy techniques. *Pituitary* 2018;21:98-106.
2. Busch W. Morphology of sella turcica and its relation to the pituitary gland. *Virchows Arch Pathol Anat Physiol Klin Med* 1951;320:437-58.
3. Fischer EG, DeGirolami U, Suojanen JN. Reversible visual deficit following debulking of a Rathke's cleft cyst: A tethered chiasm? *J Neurosurg* 1994;81:459-62.
4. Kaufman B, Tomsak RL, Kaufman BA, Arafah BU, Bellon EM, Selman WR, *et al.* Herniation of the suprasellar visual system and third ventricle into empty sellae: Morphologic and clinical considerations. *AJR Am J Roentgenol* 1989;152:597-608.
5. Kubo S, Hasegawa H, Inui T, Tominaga S, Yoshimine T. Endonasal endoscopic transsphenoidal chiasmectomy with silicone plates for empty sella syndrome: Technical note. *Neurol Med Chir (Tokyo)* 2005;45:428-32.
6. Olson DR, Guiot G, Derome P. The symptomatic empty sella. Prevention and correction via the transsphenoidal approach. *J Neurosurg* 1972;37:533-7.
7. Taniguchi H, Muguruma K, Hiura Y, Inoue T, Kawa G, Kinoshita H, *et al.* Acquired male hypogonadotropic hypogonadism (MHH) in a patient with empty sella: A case report. *Hinyokika Kyo* 2008;54:791-3.

**How to cite this article:** Yamada S, Yagi K, Hirano K, Uno M. Spontaneous improvement of secondary empty sella syndrome due to re-expansion of an intrasellar cyst: A case report. *Surg Neurol Int* 2020;11:282.