

## Cavernous sinus thrombosis with central retinal artery occlusion in COVID-19: A case report and review of literature

Anuradha Raj, Navjot Kaur, Navdeep Kaur<sup>1</sup>

Coronavirus disease-2019 (COVID-19) is showing a wide spectrum of ocular manifestations. They are creeping from vision sparing to irreversible visual loss as a result of its thromboembolic events. Hypercoagulability associated with COVID-19 is also called “sepsis-induced coagulopathy” and may predispose to thromboembolic phenomenon that decides the morbidity and mortality of this pandemic. A 37-year-old man presented with no perception of light in the left eye with optic atrophy and macular pucker on fundus examination. Visual evoked potential showed extinguished P 100 wave. His past medical history revealed severe pneumonia secondary to

severe acute respiratory syndrome-coronavirus-2 (SARS-CoV 2) infection about 3 months back.

**Key words:** Cavernous sinus thrombosis, COVID-19, optic neuropathy

Coronavirus disease-2019 (COVID-19), which causes severe acute respiratory syndrome-coronavirus-2 (SARS-CoV2), was first recognized and reported in December 2019 in Wuhan, China. Unfortunately, COVID-19 had evolved into a global pandemic infecting 70 million cumulative people and 1.6 million deaths globally till December 15, 2020.<sup>[1]</sup> Ocular manifestations of this virus include conjunctivitis, corneal epithelial defect, subepithelial infiltrates, asymptomatic retinal lesions, and retinal microhemorrhages.<sup>[2]</sup> Cavernous sinus thrombosis (CST) leading central retinal artery occlusion (CRAO) with eventual optic neuropathy in patient with COVID-19 has never been reported in the available literature to the best of our knowledge. Keeping this in view, we are reporting this case.

### Case Report

A 37-year-old man presented to us with the complaint of loss of vision in the left eye (OS). On enquiring about his past systemic and ocular history, patient revealed that he had suffered from COVID-19 infection 3 months back. He had shortness of breath, difficulty in breathing, generalized weakness, and fever with loss of smell and taste. He got tested for real-time reverse transcription-polymerase chain reaction (RT-PCR) for

Access this article online	
Quick Response Code:	Website: www.ijo.in
	DOI: 10.4103/ijo.IJO_3770_20

Departments of Ophthalmology, and <sup>1</sup>Radiodiagnosis, All India Institute of Medical Sciences, Bathinda, Punjab, India

**Correspondence to:** Dr. Anuradha Raj, Department of Ophthalmology, All India Institute of Medical Sciences, Bathinda, Punjab - 151 001, India. E-mail: dranuradha\_sagar@yahoo.com

Received: 26-Dec-2020

Revision: 27-Feb-2021

Accepted: 08-Mar-2021

Published: 30-Apr-2021

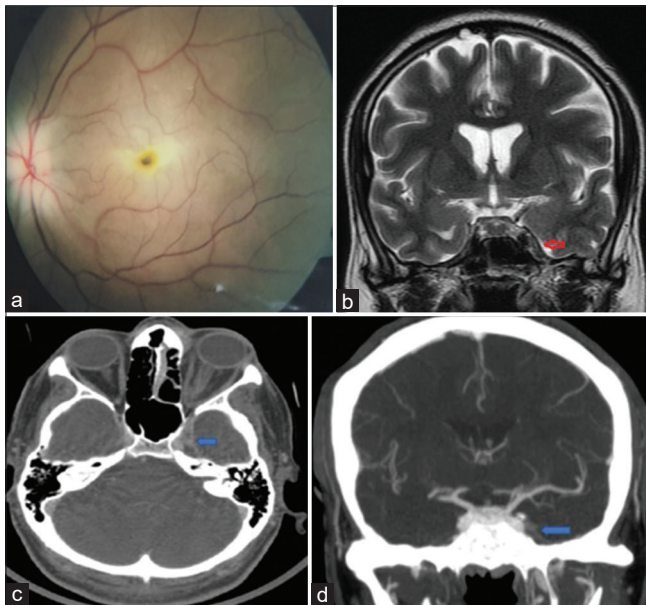
This is an open access journal, and articles are distributed under the terms of the Creative Commons Attribution-NonCommercial-ShareAlike 4.0 License, which allows others to remix, tweak, and build upon the work non-commercially, as long as appropriate credit is given and the new creations are licensed under the identical terms.

**For reprints contact:** WKHLRPMedknow\_reprints@wolterskluwer.com

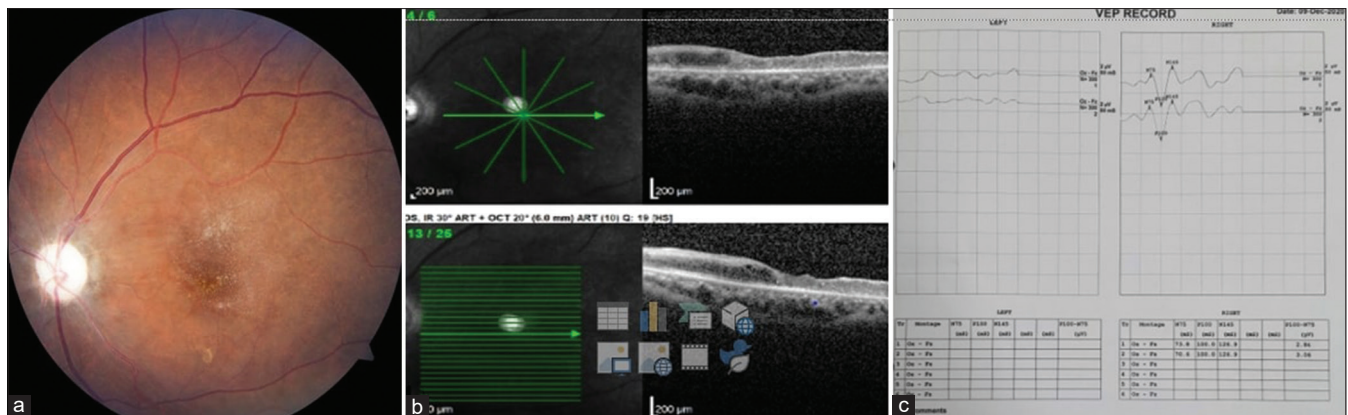
**Cite this article as:** Raj A, Kaur N, Kaur N. Cavernous sinus thrombosis with central retinal artery occlusion in COVID-19: A case report and review of literature. Indian J Ophthalmol 2021;69:1327-9.

COVID-19 which came out to be positive and he was admitted in the hospital. Various investigations such as inflammatory markers erythrocyte sedimentation rate (ESR—160 mm/h normal range 1–13 mm/h), C-reactive protein (CRP—56.50 mg/L normal range 3.0 mg/L), D-dimers (>10,000 ng/mL, normal range <250 ng/mL), ferritin (370 ng/mL, normal range 20–250 ng/mL), interleukin-6 (560 pg/mL, and normal range 1.66 to 5.38 pg/mL) were significantly high. Electrocardiogram was normal. Computed tomography (CT) scan of the chest showed ground-glass opacities with reticulations in bilateral lungs consistent with viral pneumonia. Patient's condition deteriorated on the fifth day of admission and was shifted to the intensive care unit (ICU) and intubated and got treated with

the first intravenous (IV) injection of remdesivir in the dose of 200 mg followed by daily IV maintenance doses of 100 mg for next 5 days, azithromycin 500 mg/day IV infusion, and tocilizumab 400 mg IV once and one unit of plasma transfusion with other supportive care. After 9 days of stay in ICU, the patient recovered from pneumonia and was shifted to the ward where he developed sudden onset of swelling, foreign body sensation, drooping of upper eyelid, and diminution of vision of the left eye. An ophthalmological opinion was sought and records revealed no perception of light along with ptosis, proptosis, and complete ophthalmoplegia in the left eye. On fundus photography, it showed severe optic disc edema with cherry red spot and retinal whitening suggestive of CRAO without cilioretinal sparing [Fig. 1a]. Magnetic resonance imaging (MRI) brain and orbit showed CST with left diffuse pre-septal and retro-orbital edema with swollen optic nerve sheath secondary to CST [Fig. 1b]. CT venography demonstrated asymmetric bulging and filling defect of the left cavernous sinus. Axial images showed thickened and prominent left optic nerve sheath with ill-defined soft tissue infiltration at orbital apex between the medial rectus and optic nerve [Fig. 1c and d]. ESR and CRP were 85 mm and 49.14 mg/L, respectively. Patient was again admitted and managed with intravenous steroids, antibiotics, anticoagulant, and symptomatic care for a week. In the meanwhile, a biopsy was taken from the nasal mucosa to rule out any fungal infection (Aspergillus) by Oto-rhinolaryngologist but reports were unremarkable. Despite this whole treatment, no visual recovery was noticed for left eye and the patient got discharged. Proptosis, ptosis, and ophthalmoplegia recovered completely within 1 month of treatment. Then patient presented to us with complaints of loss of vision in the left eye. On ophthalmological examination, the right eye revealed unaided visual acuity of 20/20 on Snellen's chart with normal color vision. The left eye showed exodeviation of 15° on Hirschberg's test. On swinging flashlight test, the left eye showed grade four relative afferent pupillary defect. Otherwise, anterior segment of both eyes was unremarkable on slit-lamp examination. On slit-lamp-biomicroscopy with 90 D, fundus examination revealed optic disc atrophy with gliosis and macular pucker in the left eye [Fig. 2a] but fundus of right eye was unremarkable. Intraocular pressure was 18 mm Hg and 16 mm Hg in right and left eye, respectively,



**Figure 1:** (a) Fundus photo of left eye showing optic disc edema with retinal whitening and cherry red spot. (b) Coronal T2 weighted MRI image of the brain showing bulky left cavernous sinus with bulging lateral wall with hypointense material filling the left cavernous sinus. (c and d) Axial and coronal CT Venography images showing asymmetrical cavernous sinuses with bulging left cavernous sinus. On axial image left optic nerve sheath appears prominent with minimal retro-orbital fat stranding and soft tissue infiltration at orbital apex



**Figure 2:** (a) Fundus photo showing dirty chalky white disc and macular pucker. (b) Optical coherence tomography of left eye showing loss of foveal contour with thinning and fluid pockets in parafoveal area. (c) Visual evoked potential showing normal latency and amplitude of P100 wave while extinguished P100 in left eye

with applanation tonometry. On spectral domain, optical coherence tomography OS showed loss of foveal contour with thinning measuring 142  $\mu\text{m}$ , hyper-reflective internal limiting membrane with vitreomacular traction and few fluid pockets in parafoveal area [Fig. 2b]. Visual fields examination of right eye were unremarkable. On visual evoked potential (VEP), P100 latency and amplitude was normal in the right eye but it was nearly extinguished and no wave formation were seen in the left eye suggestive of left optic neuropathy [Fig. 2c].

On the basis of the all available records with the patient and the investigations which we did for him, diagnosis of CST with subsequent CRAO and optic neuropathy secondary to COVID 19 infection was made.

## Discussion

The cavernous sinus lying superior to the sphenoid sinuses collects venous drainage from the cranium, orbits, midface, and neck. This predisposes to the spread of infection via thrombophlebitis or septic emboli from these regions. Aseptic or noninfectious CST includes hypercoagulable disorders, malignancy, pregnancy, arteriovenous malformations, and inflammatory conditions such as Tolosa–Hunt syndrome. CST is a complicated diagnosis that often presents with overlapping features with other more common ophthalmic conditions, including orbital cellulitis and orbital apex syndrome. Common symptoms include ptosis, proptosis, chemosis, ophthalmoplegia (cranial nerve III, IV, VI), and loss of sensation in the ophthalmic and maxillary divisions of the trigeminal nerve (V1 and V2). Rarely visual loss can occur in this entity due to optic nerve ischemia, retinal ischemia, and anterior ischemic optic neuropathy.<sup>[3]</sup>

In the current case, the patient was young adult who lost his vision in the left eye due to CRAO secondary to CST within two weeks of getting positive for COVID-19 infection. COVID-19 is well known to increase the risk of developing venous thromboembolism. Therefore, patients with COVID-19 have been reported with cerebral venous sinus thrombosis.<sup>[4,5]</sup> Additional posterior segment involvements in these conditions include retinitis, neuroretinitis, optic neuritis, panuveitis,<sup>[6]</sup> and central retinal vein occlusion.<sup>[7]</sup>

The mechanism responsible for increased risk of thrombosis, both in the venous and arterial circulations, includes excessive inflammation, platelet activation, endothelial dysfunction, and stasis.<sup>[8]</sup> Angiotensin-converting enzyme 2 (ACE 2) receptor facilitates cell entry of SARS-CoV-2 expressed on mucosal surfaces of multiple organ systems (lung, liver, kidney, skin). Furthermore, ACE2 is present in arterial and venous endothelial cells and arterial smooth muscle cells.<sup>[9]</sup> SARS-CoV-2 infection facilitates the induction of endotheliitis in several organs as a direct consequence of viral and of the host inflammatory response.<sup>[10]</sup> Together with cytokine abnormalities, these contribute to vasoconstriction, inflammation, ischemia, and hyper-coagulopathy which eventually can lead to CRAO in COVID-19.<sup>[11]</sup> Acharya *et al.* have reported an elderly case of CRAO secondary to COVID-19.<sup>[12]</sup>

## Conclusion

In view of significantly increasing rates of arterio-venous thrombosis in patients with COVID-19, particularly among those with severe disease requiring intensive care support, it is fundamental to carefully consider visual symptoms in

order to pursue adequate ophthalmological management to avoid irreversible visual loss. Any kind of untoward ophthalmic manifestation without any other confounders should be suspected of COVID-19 whether symptomatic or asymptomatic and proper precautions should be implemented while examining such cases. Knowledge about these novel ocular manifestations should be disseminated among the physicians, health care workers and critical care fraternity to curb the eventual visual morbidity by early interventions.

## Declaration of patient consent

The authors certify that they have obtained all appropriate patient consent forms. In the form the patient(s) has/have given his/her/their consent for his/her/their images and other clinical information to be reported in the journal. The patients understand that their names and initials will not be published and due efforts will be made to conceal their identity, but anonymity cannot be guaranteed.

## Financial support and sponsorship

Nil.

## Conflicts of interest

There are no conflicts of interest.

## References

- Shemer A, Einan-Lifshitz A, Itah A, Dubinsky-Pertzov B, Pras E, Hecht I. Ocular involvement in coronavirus disease 2019 (COVID-19): A clinical and molecular analysis. *Int Ophthalmol* 2020;41:433-40.
- Abdul-Kadir MA, Lim LT. Human coronaviruses: Ophthalmic manifestations. *BMJ Open Ophthalmol* 2020;5:e000630.
- Cavalcanti DD, Raz E, Shapiro M, Dehkharghani S, Yaghi S, Lillemoe K, *et al.* Cerebral venous thrombosis associated with COVID-19. *AJNR Am J Neuroradiol* 2020;41:1370-6.
- Thompson A, Morgan C, Smith P, Jones C, Ball H, Coulthard EJ, *et al.* Cerebral venous sinus thrombosis associated with COVID-19. *Pract Neurol* 2020;8:002678. doi: 10.1136/practneurol-2020-002678.
- Tu TM, Goh C, Tan YK, Leow AS, Pang YZ, Chien J, *et al.* Cerebral venous thrombosis in patients with COVID-19 infection: A case series and systematic review. *J Stroke Cerebrovasc Dis* 2020;29:105379.
- Benito-Pascual B, Gegúndez JA, Díaz-Valle D, Carreno E, Culebras E, Rodríguez-Avial I, *et al.* Panuveitis and optic neuritis as a possible initial presentation of the novel coronavirus disease 2019 (COVID-19). *Ocul Immunol Inflamm* 2020;28:922-5.
- Sheth JU, Narayanan R, Goyal J, Goyal V. Retinal vein occlusion in COVID-19: A novel entity. *Indian J Ophthalmol* 2020;68:2291-3.
- Bikdeli B, Madhavan MV, Jimenez D, Chuich T, Dreyfus I, Driggin E, *et al.* COVID-19 and thrombotic or thromboembolic disease: Implications for prevention, antithrombotic therapy, and follow-up: JACC State-of-the-Art Review. *J Am Coll Cardiol* 2020;75:2950-73.
- Hamming I, Timens W, Bulthuis ML, Lely AT, Navis GJ, Goor HV. Tissue distribution of ACE2 protein, the functional receptor for SARS coronavirus. A first step in understanding SARS pathogenesis. *J Pathol* 2004;203:631-7.
- Varga Z, Flammer AJ, Steiger P, Haberecker M, Andermatt R, Zinkernagel AS, *et al.* Endothelial cell infection and endotheliitis in COVID-19. *Lancet* 2020;395:1417-8.
- Greven CM, Slusher MM, Weaver RG. Retinal arterial occlusions in young adults. *Am J Ophthalmol* 1995;120:776-83.
- Acharya S, Diamond M, Anwar S, Glaser A, Tyagi P. Unique case of central retinal artery occlusion secondary to COVID-19 disease. *IDCases* 2020;21:e00867.