

Aortitis Presenting as Fever of Unknown Origin

Shi-Min Yuan, MD, PhD¹ and Hong Lin, MD²

Patients with aortitis often present with nonspecific constitutional symptoms. Due to the fact that aortitis is associated with inflammatory or infectious courses, patients may manifest fever or fever of unknown origin. Such clinical characteristics of aortitis are unavoidably brought about diagnostic dilemmas and might lead to a series of unnecessary work-ups and maltreatment. Therefore, it is important for the clinical physicians and surgeons to understand aortitis presenting with fever of unknown origin to avoid delayed diagnosis and treatment. In this article, clinical and pathological features of aortitis (giant cell arteritis, Takayasu arteritis and infective aortitis, etc.) with fever of unknown origin are described and the differential diagnosis and management policy are discussed.

Keywords: aortitis, cardiovascular syphilis, fever of unknown origin, giant cell arteritis, Takayasu arteritis

Introduction

Aortitis is an abnormal inflammatory disorder of the aortic wall with or without an extension to the aortic branches. Among the rheumatic diseases including giant cell arteritis (GCA), Takayasu arteritis (TA), long-standing ankylosing spondylitis, Cogan syndrome (interstitial keratitis, iritis, conjunctival or subconjunctival hemorrhage, fever and aortic insufficiency), and relapsing polychondritis, there was a prevalence of aortic involvement up to 10%.¹⁾ The aortic involvement often causes annuloaortic ectasia or aortic aneurysm extending from the ascending aorta into the aortic arch.¹⁾ This entity may include either infectious or noninfectious inflammatory conditions with variable clinical, morphologic and prognostic

features. In GCA, the vascular inflammation may affect a series of arteries, such as the vertebral, coronary and mesenteric arteries, most often the external carotid branches, particularly the superior temporal artery, in addition to the aorta and its branches.¹⁾ The clinical manifestations of aortitis/arteritis are usually vague and nonspecific constitutional presentations, such as pain, fever, malaise, myalgia, and weight loss, etc.²⁾ Laboratory examinations may reveal significantly elevated erythrocyte sedimentation rate and C-reactive protein with leukocytosis and elevated neutrophils.²⁾

Aortitis can be a common cause of fever of unknown origin (FUO), particularly in the patients with the use of a tumor necrosis factor- α inhibitor (represented by infliximab (Remicade))³⁾ or with sepsis.⁴⁾ The incidence of this entity is difficult to assess, and it is often associated with diagnostic dilemma and unnecessary work-ups due to its nonspecific manifestations.¹⁾ The present article is to discuss the diagnostic concerns of aortitis in the presence of FUO.

Aortitis

Giant cell arteritis

GCA is a chronic vasculitis affecting the large- and medium-sized arteries, especially the superficial cranial arteries.¹⁾ Aorta is involved in 15% of the patients.¹⁾

¹⁾Department of Cardiothoracic Surgery, Teaching Hospital, Fujian Medical University, Putian, Fujian, China

²⁾Department of Cardiology, The First Hospital of Putian, Teaching Hospital, Fujian Medical University, Putian, Fujian, China

Received: June 12, 2018; Accepted: July 23, 2018

Corresponding author: Hong Lin, MD. The First Hospital of Putian, Teaching Hospital, Fujian Medical University, 389 Longdejing Street, Chengxiang District, Putian 351100, Fujian, China
Email: linhong0218@126.com

©2018 The Editorial Committee of *Annals of Thoracic and Cardiovascular Surgery*. This work is licensed under a Creative Commons Attribution-NonCommercial-NonDerivatives International License.

Pereira et al.⁵⁾ noted ethnic differences of incidences of GCA, with a 20 times lower incidence in Asians than in Caucasians. Patients with GCA typically present with constitutional symptoms, such as headache, jaw claudication, fever, weight loss, myalgia, arthralgia, or malaise.⁶⁾ Pamuk et al.⁷⁾ compared GCA and polymyalgia rheumatica in terms of constitutional symptoms including fever, and noted a significant higher prevalence in the nonspecific constitutional symptoms in GCA than in polymyalgia rheumatica group (78.9% vs. 49.1%, $p = 0.024$). In 2014, Jokar and Mirfeizi⁸⁾ reported 30 cases of GCA from Iran, from which they noted that fever (20%) was the second most common manifestation of GCA next to headache (96.7%). One of their patients presented with FUO, accounting for 3.3% of the whole group and 16.7% of febrile patients. By comparison, the prevalence of fever was 56.2% in India, 55.4% in Japan, and 42% in Caucasian, respectively.

Zabala López et al.⁹⁾ reported a 78-year-old patient with GCA presented with 5-week FUO before the diagnosis was made with a sign of weakening temporal pulse. His thoracoabdominal computed tomography (CT) showed a thickened abdominal aortic wall, and the diagnosis was made by biopsy of the temporal artery. Temporal artery biopsy is the gold standard for diagnosis of GCA, which reveals diffuse infiltration of the inflammatory cells in the arterial walls, sometimes with giant cells and disruption of the elastic lamina (**Fig. 1**). Pereira et al.⁵⁾ reported the positivities of temporal artery biopsies were 81.6% in Caucasians, 2.6% in Asians, and 15.8% in others. Pamuk et al.⁷⁾ reported 19 GCA patients, 13 (68.4%) of which had pertinent pathological changes of GCA in biopsies of the temporal arteries, and the giant cells were positive in 5 (26.3%) patients. Schäfer et al.¹⁰⁾ described a 79-year-old woman with FUO but negative temporal artery biopsies in whom diagnosis of GCA was therefore delayed. Further CT angiogram and positron emission tomography (PET)-CT scan revealed diffuse extensive active vasculitis.¹¹⁾ Schattner and Klepfish¹²⁾ reported three patients with prolonged fever were diagnosed as chronic aortic dissection, GCA, and TA, respectively. The authors stated that GCA often presented with FUO, but rarely with left pleural effusions, whereas in TA patients, the pleural effusions were probably resulted from aortitis and pulmonary artery involvement.

Takayasu arteritis

TA, also known as pulseless disease, is a chronic inflammatory arteritis, affecting large vessels, predominately in the

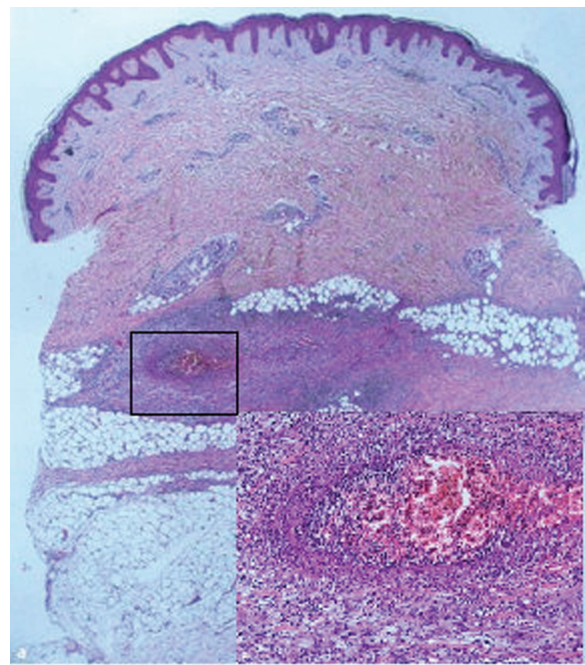


Fig. 1 Histopathology of the biopsies of the temporal arteries from a patients with arteriitis temporalis and polyarteritis nodosa showing multiple inflammatory cell infiltration: Multiple inflammatory cell infiltration around the *vasa vasorum* of the arterial wall. H&E $\times 10$ (insertion H&E $\times 100$).

aorta and its main branches. Although TA is a panarteritis, the initial site of inflammation is around the *vasa vasorum* and at the medioadventitial junction. TA is characterized by arterial stenosis; however, aneurysmal formation can also be seen in such patients. In the acute phase, patients may present with weakness, fever, arthralgias, myalgias, weight loss, and pleuritic pain.¹³⁾ Laboratory findings may include anemia (44%) and elevated erythrocyte sedimentation rate (78%).¹⁴⁾ TA can cause FUO, and is difficult to diagnose and make the patient subjected to multiple unnecessary studies and hospitalizations. The febrile course in an extreme TA patient was as long up to 10 months.¹⁴⁾ However, TA patients rarely presented with FUO.¹⁵⁾ Hall et al.¹⁶⁾ reported 4 of their 32 TA patients had FUO with an incidence of 12.5% of the patient setting. In some patients with FUO, the diagnosis of TA was established only after bruits and pulselessness were present.¹⁷⁻¹⁹⁾ Differential diagnosis from rheumatic heart disease is recommended when TA patient present with FUO associated with mitral valve regurgitation.²⁰⁾

By CT angiography, Tavora et al.¹³⁾ found that 95% (81/85) TA patients had aortic involvement with or without affecting the aortic branches, and 5% (4/85) patients had only aortic branch involvement. As in CT angiography,

magnetic resonance angiography may show arterial stenoses at multiple levels, mural thrombi, thickening of aortic valve cusps, and pericardial effusions.¹⁾

Sueyoshi et al.²¹⁾ reported, of 31 patients with TA, aortic aneurysms were found in 45.2% (14/31), 52.9% (9/17) aneurysms increased in size, and 33.3% (3/9) enlarged aneurysms increased in size rapidly and ruptured during the follow-up period. In a retrospective review, Liang et al.²²⁾ described on 64 patients with aortic aneurysm resection due to noninfectious aortitis. Histologically, giant cells were seen in 71.9%.

The characteristic histological changes of TA are a multifocal lymphoplasmacytic infiltrate around *vasa vasorum* of the adventitia with extension into the media, sometimes with presence of giant cells and endarteritis obliterans.¹³⁾

Imaging techniques including magnetic resonance imaging (MRI), CT, gallium-67 scintigraphy, and ultrasonography that may show circular, hypoechogenic arterial wall thickening are helpful for early diagnosis of TA presenting with FUO.¹⁵⁾ Recently, PET-CT is highly praised for its unique diagnostic values for TA and other rheumatological aortitis by an enhanced uptake value (SUV_{max}) of ¹⁸F-fluorodeoxyglucose (FDG) in the aortic walls.²³⁾ It is also a promising method for the assessment of disease activity.²⁴⁾ A patient with a 2-month FUO, arthralgia and elevated erythrocyte sedimentation rate was diagnosed with TA by PET-CT, which showed enhanced uptake in the affected aorta.²⁵⁾ Moreover, among serum cytokines, tumor necrosis factor- α might be more sensitive than interleukins and matrix metalloproteinases for the purpose of differential diagnosis of TA.²³⁾

Pathologically, the acute phase of TA has not been sufficiently elucidated, but reports documented thickening of the wall based on radiographic investigations, instead. The pathological characteristics of late phase of TA are adventitial fibrosis, medial necrosis, and scarring with chronic inflammation and fibrous intimal thickening, constituting a tree-bark gross appearance, similar to the changes of syphilitic aortitis.¹³⁾ There are edema and mononuclear cell infiltration in the media and adventitia as well as giant cell granulomatous reactions and laminar necrosis.²⁶⁾

Infective aortitis

Infective aortitis is uncommon, with an incidence of 0.3%–0.4% based on autopsy series,²⁷⁾ but it can be lethal. Infective aortitis most often affects the thoracic and abdominal aorta.²⁸⁾ The underlying microorganisms associated with infectious aortitis were most often *Staphylococcus*,

Enterococcus, *Streptococcus*, and *Salmonella* species.²⁸⁾ Aortitis due to *Mycobacterium tuberculosis* or *Campylobacter fetus* have been reported.²⁸⁾ Infective endocarditis and urinary or gastrointestinal infections might be a source of bacteremia responsible for the etiology of infective aortitis.²⁹⁾ Symptoms vary and are usually fever, pains, and a palpable aneurysm.³⁰⁾ A 48-year-old man with bacterial aortitis presenting with a 9-day fever and chills, developed into infective mycotic aneurysm. Excised aortic tissue revealed methicillin-resistant *Staphylococcus aureus* and *Enterococcus faecium*.³¹⁾ Of them, fever was the most common symptom of patients with infective aortitis.³²⁾ FUO can be a major symptom of infective aortitis.²⁷⁾ Leukocytosis and neutrophilia are seen in patients. Erythrocyte sedimentation rate and C-reactive protein will also be elevated. Pentraxin-3 (PTX3), a product of protective response to inflammation, is another promising potential biomarker for infective endocarditis,²⁸⁾ vasculitis, GCA, and TA.³³⁾ PTX3 might be produced within the vascular wall of inflammatory infiltrates by the endothelial cells or macrophages, and a correlation between plasma PTX3 level and TA activity was found.³³⁾ PTX3 is a feature of vascular inflammation in GCA, and it was observed that GCA patients with a disease course of <6 months showed a significant higher PTX3 level.³⁴⁾

In infective aortitis, CT showed focal wall thickening, fluid attenuation, and inflammation changes.²⁸⁾ CT angiogram may show periaortic inflammation, aortic aneurysms, or progressive aortic dilation. Other CT findings include periaortic soft-tissue masses and fluid collections.²⁷⁾ Early stages of aortitis show irregular enhancement of the aortic wall on CT imaging, consistent with mural and early periaortic inflammation.³¹⁾

In syphilitic aortitis, for example, pathological examinations may reveal medial destruction with inflammation, zonal necrosis, and a polymorphic infiltrate of mononuclear inflammatory cells.¹³⁾ In a patient with syphilitic aortitis, ascending aortic aneurysm was formed, and the resected aortic tissues inspected histologically showed multiple inflammatory cell infiltration in the affected aortic wall (**Fig. 2**).

The overall mortality of patients with infectious aortitis was reported to be 21%–44%.³²⁾ Medical treatment alone carries a high mortality, whereas the mortality with surgery combined with antimicrobial treatment is lower. Antimicrobial treatments include cephalosporins, fluoroquinolones, and anti-staphylococcal antibiotics. Surgical therapy (extra-anatomic and *in situ* bypass grafts) and endovascular stent grafts have been used in those

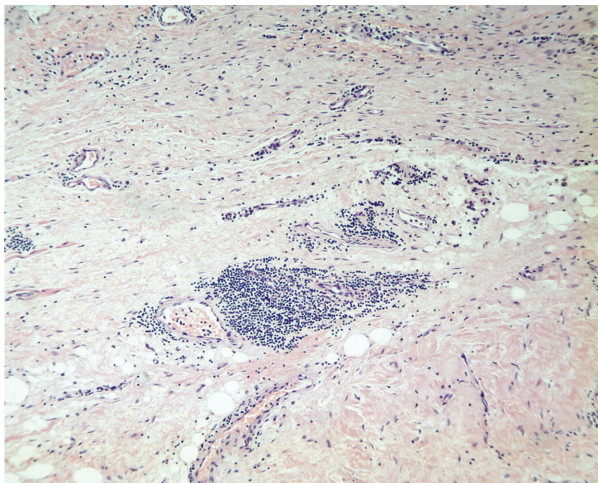


Fig. 2 Histopathology of the aortic sample of a patients with syphilitic aortitis with ascending aortic aneurysm showing multiple inflammatory cell infiltration in the aortic wall, around the *vasa vasorum* of the aortic wall. H&E \times 100.

with ruptured or leaking thoracic aneurysms and in a limited number of patients.³²⁾

Ankylosing spondylitis, Cogan syndrome, and relapsing polychondritis

Ankylosing spondylitis often has mild constitutional symptoms. Fever in such patient is absent or slight, but sometimes can be high.³⁵⁾ The fever was once attributed to the presence of *Klebsiella* infection and human leukocyte antigen B27.³⁵⁾ The diagnosis of ankylosing spondylitis is based on radiography and (or) laboratory tests of C-reactive protein or human leukocyte antigen B27.³⁶⁾ The pathology of the aortitis due to ankylosing spondylitis is characterized by local medial elastic destruction, intimal thickening, and endarteritis obliterans of the adventitia, similar to luetic aortitis.³⁷⁾

Cogan syndrome is a chronic autoimmune disease with an unknown etiology, typically presents with interstitial keratitis and auditory and (or) vestibular dysfunction. The clinical manifestations of Cogan syndrome are often nonspecific, varying among fever, arthralgias, arthritis, cutaneous exanthema, and urticaria, etc. It is occasionally associated with systemic vasculitis and aortitis. Some patients with Cogan syndrome may manifest as a febrile syndrome and thus it makes the diagnosis difficult. Decreased visual and auditory acuity can be helpful for the diagnosis.³⁸⁾ PET/CT may reveal the changes of diffuse aortitis.³⁹⁾ Prednisone treatment can lead to a progressive improvement and disappearance of fever.³⁸⁾

Relapsing polychondritis is a rare immune and inflammatory disorder affecting the cartilage. It can be associated with aortic involvement and present with fever during the disease progression. PET/CT can show a diffuse FDG accumulation in the local site of inflammation. Pathologically, the aortic wall can be infiltrated with lymphocytes and macrophages, and fibrinoid necrosis can be noted. Relapsing polychondritis with severe aortitis has been successfully treated with tocilizumab.⁴⁰⁾

Differential Diagnosis

In the differential diagnosis of aortitis presenting with FUO, rheumatic diseases including adult Still's disease, polymyalgia rheumatica, late onset rheumatoid arthritis, systemic lupus erythematosus, polyarteritis nodosa, and Kikuchi's disease that cause prolonged fever and erythrocyte sedimentation >100 mm/hour should be considered.¹⁴⁾ Rheumatologic serologies, complements (C3, C4, and CH50), cryoglobulins, antineutrophil cytoplasmic antibody (ANCA), skin biopsy, temporal artery biopsy, and medical imaging can be helpful for the differential diagnosis.

There are many similarities between GCA and TA, and they are even considered as different phenotypes of one disease.⁴¹⁾ They affect predominantly female patients and white race, and are likely to relapse after successful treatment.⁴¹⁾ Nevertheless, in patients with TA, 97% of the arterial lesions are stenotic, 3% are aneurysmal and 8% of patients are both stenoses and aneurysms. On the contrary, in patients with GCA, 75% of arterial lesions are stenotic, 62% are aneurysmal involvements of the aorta, and 41% are both stenoses and aneurysms. However, there are no significant differences in regard to fever between the two diseases. In GCA, aneurysmal formation may occur 6–7 years after the diagnosis is made.⁹⁾

Castañer et al.⁴²⁾ found that patients with GCA were 17.3 times more likely to develop a thoracic aortic aneurysm and 2.4 times more likely to develop an abdominal aortic aneurysm in comparison to the general population. Patients with GCA or isolated aortitis had significantly larger proximal descending aortas than TA (GCA: 33.9 ± 8.12 mm; isolated aortitis: 38.1 ± 28.9 mm; TA: 21.1 ± 1.8 mm; $p = 0.0012$) and thoracoabdominal aortas ($p = 0.048$) at discharge.⁴³⁾ Shu et al.³¹⁾ presented the incidence of aortic dissection in GCA (8%, 4/50) and TA (0%, 0/8). However, the incidences of aortic dissection in GCA and TA patients presenting with fever and FUO were unknown. Yuan⁴⁴⁾ published a systematic review

Table 1 A comparison of clinical features of aortitis

Aortitis	Symptom	Fever style	Affected lesion	Imaging	Histological characteristics
Giant cell arteritis	Persistent, severe headache; Jaw pain; Fever; Visual disturbance; Pain and stiffness in the neck, shoulders or hips; Polymyalgia rheumatica; Elevated inflammatory markers	Prolonged low-grade fever	Visual disturbance; Aortic aneurysm	Ultrasound and MRI: vascular wall thickening and stenosis (cranial and extracranial large vessel circulation); CT angiography: aortic aneurysm, large vessel vasculitis; PET-CT: extracranial large vessel vasculitis	Systemic vasculitis of medium-sized and large-sized arteries
Takayasu arteritis	Fatigue; dyspnea; Headache; Memory and thinking disturbances; Visual changes; High blood pressure; Pulselessness; Elevated inflammatory markers	Persistent low-grade fever	Hypertension; Aortic aneurysm; Aortic regurgitation; Myocarditis; Heart failure; Transient ischemic attack	CT and MRI: vascular wall thickening, arterial stenoses (early stage), occlusions, and aneurysms (late stage)	Inflammation of the vascular wall (from the adventitia progressing to the intima); Segmental stenosis, occlusion, dilation, and (or) aneurysmal formation
Infective aortitis	Back, chest, or abdominal pain; Palpable, pulsatile abdominal mass; Elevated sedimentation rate; Leukocytosis; Positive blood or aortic tissue culture	Fever and chills; Prolonged low-grade fever	Aortic aneurysm; Aortic dissection	Echocardiogram: severely dilated ascending aorta, commonly associated with infective endocarditis, aortic valve involvement due to root dilation, periaortic soft tissue or fluid accumulation; PET-CT: any uptake of 18-fludeoxyglucose in the aortic wall;	Degenerate neutrophils suggestive of bacterial endarteritis; Small obliterated artery on the aorta
Ankylosing spondylitis	Pain and stiffness in the lower back, buttocks and hips; Neck pain; Unspecific symptoms (fever, fatigue, loss of appetite and eye inflammation); Positive HLA-B27	Persistent low-grade fever	Uveitis; Heart block; Aortic regurgitation; Aortic aneurysm	Radiography and MRI: structural damage in spine and sacroiliac joints; Ultrasound: peripheral arthritis and enthesitis; CT: structural changes in the spine and sacroiliac joints, aneurysmal dilation of thoracic/abdominal aorta	Hyalinization of the connective tissue, with several lymphocytic infiltrates, conspicuous calcification, and absence of elastic fibers of the aortic wall; Ascending aortitis

Table 1 (Continued)

Aortitis	Symptom	Fever style	Affected lesion	Imaging	Histological characteristics
Cogan syndrome	Eye inflammation; Hearing impairment; Headache; Dizziness; Fever; Elevated inflammatory markers	Prolonged fever	Interstitial keratitis; Iritis; Conjunctival or subconjunctival hemorrhage; Aortic insufficiency;	PET-CT: positive findings compatible with aortitis	Acute necrotizing aortitis; Vasculitis involving small-, medium-sized and (or) large-sized vessels
Relapsing polychondritis	Recurrent pain and swelling of the external ear and nose; Uveitis; Arthropathy of the peripheral joints; Persistently raised inflammatory markers	Prolonged spiking fever	Nonerosive, inflammatory polyarthritis; Nasal chondritis; Ocular inflammation; Hearing dysfunction; Respiratory tract chondritis; Long-term cardiovascular deterioration	CT: subglottic stenosis, tracheobronchial luminal narrowing, aortic root dilation with aortic mural thickening	Auricular chondritis; Subtle cartilage changes; Loss of basophilia, necrotic, vacuolated chondrocytes and perichondrial inflammation; Vasculitis

CT: computed tomography; MRI: magnetic resonance imaging; PET: positron emission tomography

presenting the clinical features of 51 patients with aortic dissection and FUO as a primary symptom, and only one patient was due to GCA.

In patients with aortitis, echocardiography is recommended to determine the associated infective endocarditis and assess valve function under the condition of aortic dilation. In patients with FUO, duplex ultrasonography, MRI of the aortic arch, biopsy of the temporal artery, and FDG-PET were preferred diagnostic means.⁴⁵⁾ The diagnostic value of MRI was noticeable due to its high sensitivity and specificity in etiological diagnosis of FUO.⁴⁵⁾ FDG-PET/CT is praised for its sensitivity and its extreme values in the differential diagnosis of inflammations of patients presenting with FUO, including TA, GCA, and immunoglobulin G4-related disease.⁴⁶⁾ It can provide functional information for disease activity, staging, biopsy guidance, and monitoring response to treatment.²⁾ In patients with FUO with suspected focal infection or inflammation, FDG-PET with intense uptake seems to be a valuable diagnostic evidence of aortitis; however, for early aortitis cases, MRI and PET diagnoses may be discordant.⁴⁷⁾ FDG-PET has been proved superior to gallium-67 scintigraphy in patients with FUO.⁴⁸⁾

Aortitis often manifests fever, usually with prolonged and low-grade fever; however, patients with relapsing polycondritis can have spiking fever, and those with infective aortitis can have high fever. A comparison of symptom, fever style, affected lesion, imaging and histological characteristics comparing GCA, TA, infective and other types of arteritis are shown in **Table 1**.

Management

Management of noninfective aortitis consists of immunosuppression with high-dose corticosteroid therapy. Surgery and percutaneous intervention are best avoided due to the early complications associated with aortic wall fragility, prosthetic valve dehiscence, and refractory inflammation. In patients with GCA presenting with aortic valve incompetence and ascending aortic aneurysm extending to the proximal arch, the patients often warrant total arch replacement and aortic valve replacement or valvoplasty. Endovascular stent grafts with less trauma and diminished organ injury complications in the repair of infectious aortitis, in particular for mycotic aneurysms, have been successful recently.³⁾ A 6-week to lifelong suppressive oral antibiotics is recommended.³⁾

Patients with infective aortitis usually present with nonspecific symptoms and many were FUO. Diagnostic

work-ups could be angiography, CT angiography, and Doppler ultrasonography. FDG-PET may show abnormally increased FDG uptake in the affected aorta and aortic branches. Treatment of choice includes high-dose steroids and steroid-sparing drugs. In patients with infective aortitis, who presented with fever, leukocytosis, back pain, and abdominal mass, the most commonly identified organisms could be *Salmonella* and *Staphylococcus*. The surgical techniques include excision with *in situ* repair, extra-anatomic bypass, and primary lateral closure. Lopes et al.⁴⁹⁾ proposed that infected aorta excision with *in situ* or extra-anatomic graft placement is a golden standard of infective aortitis. Endovascular aortic repair is an alternative treatment of infected aortic aneurysms and has obtained promising results. Patients with combined surgical and conservative treatments are associated with a good survival rate of 75%–100% prior to aneurysmal formation, and a survival rate of 62% after aneurysmal formation. The surgical mortality rate can be up to 65% in cases of ruptured aortic aneurysm, and the mortality rate can be as high as 90% if the patients are treated conservatively only. The application of endovascular aortic repair has led to a significantly decreased postoperative mortality to 10.4%. A meta-analysis on endovascular management of mycotic aorta aneurysms by Kan et al.⁵⁰⁾ showed that the 30-day and 2-year survival rates were 89.6% ± 4.4% and 82.2% ± 5.8%, respectively, and perioperative fever could be a significant predictor of infection. Under such circumstances, patients with infected aortic aneurysms were still with increased mortality and morbidity rates irrespective of aggressive treatments, such as extensive resection and debridement, *in situ* or extra-anatomical graft insertion and broad-spectrum antibiotics.

Conclusion

The inflammatory changes in aortitis, even the lesion was occult could be a cause of FUO. The development of the aortitis may predispose into fatal conditions like aortic aneurysms or dissections, thus prompt diagnosis and further treatment are crucial for promoting the patients' prognosis. FDG-PET/CT is helpful for the differential diagnosis of aortitis presenting with FUO.

Disclosure Statement

The authors declare no conflict of interest.

References

- 1) Restrepo CS, Ocazone D, Suri R, et al. Aortitis: imaging spectrum of the infectious and inflammatory conditions of the aorta. *Radiographics* 2011; **31**: 435-51.
- 2) Obermeier F, Herold T, Schönberger J, et al. Vasculitis of the aortic arch and cardiac valves as the cause of relapsing fever of unknown origin in an elderly, white man. *Clin Rheumatol* 2006; **25**: 923-5.
- 3) Talwar A, George N, Tharian B, et al. An immunosuppressed man with an aortic rupture secondary to Salmonella aortitis successfully treated with endovascular aortic repair. *Ann Vasc Surg* 2015; **29**: 839.e5-8
- 4) Kalaycı B, Öz İİ, İşleyen A, et al. A rare cardiovascular cause of fever of unknown origin: Infected thoracic aortic aneurysm. *Cor et Vasa* 2017; **59**: e208-9.
- 5) Pereira LS, Yoon MK, Hwang TN, et al. Giant cell arteritis in Asians: a comparative study. *Br J Ophthalmol* 2011; **95**: 214-6.
- 6) Cha DM, Lee T, Choe G, et al. Silent giant cell arteritis in an elderly Korean woman. *Korean J Ophthalmol* 2013; **27**: 224-7.
- 7) Pamuk ON, Dönmez S, Karahan B, et al. Giant cell arteritis and polymyalgia rheumatica in northwestern Turkey: clinical features and epidemiological data. *Clin Exp Rheumatol* 2009; **27**: 830-3.
- 8) Jokar M, Mirfeizi Z. The Demographic, Clinical and laboratory profile of patients with giant cell arteritis: case series. *Sch J App Med Sci* 2014; **2**: 1892-5.
- 9) Zabala López S, Yago Escusa D, Sánchez Santos P, et al. [Aortitis in patients with unknown origin fever]. *Rev Clin Esp* 2009; **209**: 146-7. (in Spanish)
- 10) Schäfer VS, Warrington KJ, Williamson EE, et al. Delayed diagnosis of biopsy-negative giant cell arteritis presenting as fever of unknown origin. *J Gen Intern Med* 2009; **24**: 532-6.
- 11) Uchida T, Andou H, Yasutsune T, et al. [Thoracic aortic aneurysm due to giant cell arteritis without any specific symptom]. *Kyobu Geka* 2009; **62**: 324-7. (in Japanese)
- 12) Schattner A, Klepfish A. Left pleural effusion and fever of unknown origin—a clue to thoracic arterial pathology. *J Gen Intern Med* 2012; **27**: 1084-7.
- 13) Tavora F, Burke A. Review of isolated ascending aortitis: differential diagnosis, including syphilitic, Takayasu's and giant cell aortitis. *Pathology* 2006; **38**: 302-8.
- 14) Campaña VR, Armas LS, Silva HR, et al. [Takayasu's arteritis and unknown origin fever]. *Rev Cub Med* 2010; **49**: 105-13. (in Spanish)
- 15) Uthman IW, Bizri AR, Hajj Ali RA, et al. Takayasu's arteritis presenting as fever of unknown origin: report of two cases and literature review. *Semin Arthritis Rheum* 1999; **28**: 280-5.
- 16) Hall S, Barr W, Lie JT, et al. Takayasu arteritis. A study of 32 North American patients. *Medicine (Baltimore)* 1985; **64**: 89-99.
- 17) Wu YJ, Martin B, Ong K, et al. Takayasu's arteritis as a cause of fever of unknown origin. *Am J Med* 1989; **87**: 476-7.
- 18) Yotsuyanagi H, Chikatsu N, Kaneko Y, et al. Takayasu's arteritis in prepulseless stage manifesting lymph node swelling and hepatosplenomegaly. *Intern Med* 1995; **34**: 455-9.
- 19) Vaz RM, Formanek AG, Roach ES. Takayasu's arteritis. Protean manifestations. *J Adolesc Health Care* 1988; **9**: 414-7.
- 20) Karagianni D, Skaragka E, Tzatzagou G, et al. P159 Takayasu's arteritis presented as fever of unknown origin, and associated with mitral regurgitation, stenosis of both renal arteries and purpuric eruption. *Eur J Intern Med* 2003; **14**: S77.
- 21) Sueyoshi E, Sakamoto I, Hayashi K. Aortic aneurysms in patients with Takayasu's arteritis: CT evaluation. *AJR Am J Roentgenol* 2000; **175**: 1727-33.
- 22) Liang KP, Chowdhary VR, Michet CJ, et al. Noninfectious ascending aortitis: a case series of 64 patients. *J Rheumatol* 2009; **36**: 2290-7.
- 23) Arraes AE, de Souza AW, Mariz HA, et al. ¹⁸F-Fluorodeoxyglucose positron emission tomography and serum cytokines and matrix metalloproteinases in the assessment of disease activity in Takayasu's arteritis. *Rev Bras Reumatol* 2016; **56**: 299-308.
- 24) Direskeneli H. Clinical assessment in Takayasu's arteritis: major challenges and controversies. *Clin Exp Rheumatol* 2017; **35**: 189-93.
- 25) Woolley AK, Hedger NA, Veetil RP. Problem based review: the patient with a pyrexia of unknown origin. *Acute Med* 2013; **12**: 107-10.
- 26) Vaideeswar P, Deshpande JR. Pathology of Takayasu arteritis: a brief review. *Ann Pediatr Cardiol* 2013; **6**: 52-8.
- 27) Rondina MT, Raphael K, Pendleton R, et al. Abdominal aortitis due to *streptococcus pneumoniae* and *enterobacter aerogenes*: a case report and review. *J Gen Intern Med* 2006; **21**: C1-3.
- 28) Agrawal A, Sikachi RR. Infective abdominal aortitis due to *Campylobacter fetus* bacteremia: a case report and review of literature. *Intractable Rare Dis Res* 2016; **5**: 290-3.
- 29) Raghoo R, Noeverman MJ, Hoekstra R, et al. Microbial aortitis with aneurysm formation. *World J Cardiovasc Surg* 2014; **4**: 181-5.
- 30) Asthana S, Walker D, Iyengar S, et al. Mycotic aneurysm presenting as fever of unknown origin. *West J Med* 1989; **150**: 694-6.
- 31) Shu KM, Rybicki FJ, Ledbetter S. Bacterial aortitis resulting in rapid development of infective "mycotic" aneurysm. *Emerg Radiol* 2002; **9**: 317-9.
- 32) Foote EA, Postier RG, Greenfield RA, et al. Infectious aortitis. *Curr Treat Options Cardiovasc Med* 2005; **7**: 89-97.
- 33) Tombetti E, Di Chio MC, Sartorelli S, et al. Systemic pentraxin-3 levels reflect vascular enhancement and

- progression in Takayasu arteritis. *Arthritis Res Ther* 2014; **16**: 479.
- 34) Nishimura M, Sato Y, Yoshida K, et al. [A case report of the prosthetic treatment of a patient with a repositioned maxilla due to fracture]. *Nihon Hotetsu Shika Gakkai Zasshi* 1986; **30**: 1106-13. (in Japanese)
 - 35) Kinsella P, Ebringer R, Hooker J, et al. Ankylosing spondylitis presenting as PUO. *Br Med J* 1978; **2**: 19-20.
 - 36) Yuan SM. Cardiovascular involvement of ankylosing spondylitis: report of three cases. *Vascular* 2009; **17**: 342-54.
 - 37) Lautermann D, Braun J. Ankylosing spondylitis-cardiac manifestations. *Clin Exp Rheumatol* 2002; **20**: S11-5.
 - 38) Solé Altarriba E, Garcés Jarque JM, Nogués Solán X, et al. [Fever of unknown origin: unusual form of presentation of Cogan's syndrome]. *An Med Interna (Madrid)* 2008; **25**: 245-6. (in Spanish)
 - 39) Tsuno H, Takahashi Y, Yoshida Y, et al. [Successful early treatment in a case of Cogan's syndrome]. *Nihon Rinsho Meneki Gakkai Kaishi* 2012; **35**: 92-6. (in Japanese)
 - 40) Stael R, Smith V, Wittoek R, et al. Sustained response to tocilizumab in a patient with relapsing polychondritis with aortic involvement: a case based review. *Clin Rheumatol* 2015; **34**: 189-93.
 - 41) Maksimowicz-McKinnon K, Clark TM, Hoffman GS. Takayasu arteritis and giant cell arteritis: a spectrum within the same disease? *Medicine (Baltimore)* 2009; **88**: 221-6.
 - 42) Castañer E, Alguersuari A, Gallardo X, et al. When to suspect pulmonary vasculitis: radiologic and clinical clues. *Radiographics* 2010; **30**: 33-53.
 - 43) Svensson LG, Arafat A, Roselli EE, et al. Inflammatory disease of the aorta: patterns and classification of giant cell aortitis, Takayasu arteritis, and nonsyndromic aortitis. *J Thorac Cardiovasc Surg* 2015; **149**: S170-5.
 - 44) Yuan SM. Fever of unknown origin in aortic dissection. *Z Rheumatol* 2017; **76**: 364-71.
 - 45) Wagner AD, Andresen J, Raum E, et al. Standardised work-up programme for fever of unknown origin and contribution of magnetic resonance imaging for the diagnosis of hidden systemic vasculitis. *Ann Rheum Dis* 2005; **64**: 105-10.
 - 46) Rahman MS, Storrar N, Anderson LJ. FDG-PET/CT in the diagnosis of aortitis in fever of unknown origin with severe aortic incompetence. *Heart* 2013; **99**: 435-6.
 - 47) Meller J, Strutz F, Siefker U, et al. Early diagnosis and follow-up of aortitis with [¹⁸F]FDG PET and MRI. *Eur J Nucl Med Mol Imaging* 2003; **30**: 730-6.
 - 48) Wenger M, Baltaci M, Klein-Weigel P, et al. 18F-FDG-positron emission tomography for diagnosis of large vessel arteritis in Behçet's disease. *Adv Exp Med Biol* 2003; **528**: 435-6.
 - 49) Lopes RJ, Almeida J, Dias PJ, et al. Infectious thoracic aortitis: a literature review. *Clin Cardiol* 2009; **32**: 488-90.
 - 50) Kan CD, Lee HL, Yang YJ. Outcome after endovascular stent graft treatment for mycotic aortic aneurysm: a systematic review. *J Vasc Surg* 2007; **46**: 906-12.