

Partial-thickness rotator cuff tears: clinical and imaging outcomes and prognostic factors of successful nonoperative treatment

Ian K Lo¹
Matthew R Denkers²
Kristie D More¹
Atiba A Nelson¹
Gail M Thornton¹
Richard S Boorman¹

¹Department of Surgery, McCaig Institute for Bone and Joint Health, University of Calgary, Calgary, AB, Canada; ²Division of Orthopaedic Surgery, McMaster University, Hamilton, ON, Canada

Purpose: The purpose of this study was to determine the clinical success rate of nonoperative treatment of partial-thickness rotator cuff tears (PT-RCTs), to determine baseline clinical factors predictive of outcome of nonoperative treatment of PT-RCTs, and to determine the imaging outcome of nonoperative treatment of PT-RCTs.

Patients and methods: All patients with a primary diagnosis of a PT-RCT were eligible for inclusion. Seventy-six patients (48 males, 28 females) with an average age of 52±10 years were included in the study. Patients were evaluated using a standardized format including clinical, imaging, and shoulder specific quality-of-life outcomes. Patients were assessed and treated either successfully nonoperatively or consented to undergo surgical intervention of their PT-RCT. Patients treated nonoperatively underwent follow-up by MRI arthrogram.

Results: Thirty-seven patients (49%) underwent nonoperative treatment. Logistic regression analysis indicated that the baseline variables of side (dominant or nondominant side involved), onset (traumatic or atraumatic), and thickness of tendon tear (<50% or >50%) were significant predictors of outcome. At a mean 46±7 months of follow-up, nonoperatively treated patients demonstrated a mean American Shoulder and Elbow Surgeons score of 85.1±16.0, and a Simple Shoulder Test score of 10.0±2.5. Overall, 76% of tears treated nonoperatively did not show a tear progression on anatomic imaging. Nine patients (24%) demonstrated tear progression, of which three patients (8%) demonstrated full-thickness tearing.

Conclusion: Nonoperative treatment was utilized in ~50% of the patients and resulted in improved clinical outcomes. Onset, shoulder involved, and thickness of the tear were predictive of the success of nonoperative treatment.

Keywords: magnetic resonance imaging follow-up, nonoperative, partial-thickness rotator cuff tears, rotator cuff

Introduction

Partial-thickness rotator cuff tears (PT-RCTs) are a common cause of pain and disability in the adult shoulder. Despite being two or three times more common than full-thickness rotator cuff tears,¹ the published literature regarding PT-RCTs is relatively scarce. Furthermore, most articles related to PT-RCTs focus on the diagnosis or surgical treatment of these lesions.²⁻⁶ However, while some patients may require surgical intervention, many patients may improve with nonoperative treatment.

Nonoperative treatment of PT-RCTs may include rest or activity modification, pain medications, anti-inflammatories, corticosteroid injections, and/or physical therapy. However, the success of nonoperative treatment of PT-RCTs is unclear, and, furthermore, the factors predictive of successful nonoperative treatment are unknown as well.

Correspondence: Ian K Lo
G23 Sports Medicine, 147 Canada
Olympic Way SW, Calgary, AB,
T3B 6B7, Canada
Tel +1 403 284 4040
Email ikylo@ucalgary.ca

A previous study at our institution demonstrated that 75% of patients with chronic symptomatic full-thickness rotator cuff tears could be successfully treated nonoperatively. Furthermore, univariate logistic regression analysis demonstrated that the baseline Rotator Cuff Quality-of-Life questionnaire score was predictive of nonoperative success.⁷

Therefore, the purposes of this study were: 1) to determine the clinical success rate of nonoperative treatment of PT-RCTs; 2) to determine baseline clinical factors predictive of outcome of nonoperative treatment of PT-RCTs; and 3) to determine the anatomic outcome of nonoperative treatment of PT-RCTs. We hypothesized that many patients could be managed successfully with nonoperative treatment, that there would be several factors predictive of clinical success, and that there would be minimal progression of disease on MRI.

Patients and methods

This was a prospective cohort study design which was approved by the Conjoint Health Research Ethics Board at the University of Calgary. All patients referred to a shoulder surgeon's practice between 2004 and 2006 with a primary diagnosis of a PT-RCT were eligible for inclusion. Patients provided written informed consent. The study was conducted in a university-based, sport medicine specialized, tertiary referral center.

Inclusion and exclusion criteria

Inclusion criteria included all patients between the ages of 18 and 85 years, with a primary diagnosis of PT-RCT of the supraspinatus and/or infraspinatus tendons confirmed on MRI or MRI arthrography (MRA), with a minimum duration of symptoms of 3 months. Exclusion criteria included patients with significant concomitant shoulder disorders (ie, glenohumeral osteoarthritis, glenohumeral instability, symptomatic acromioclavicular joint disease, superior labral or other labral pathology, subscapularis tears, adhesive capsulitis), with significant medical issues precluding surgery, involved in worker's compensation-type or litigation-type claims, unable or unwilling to complete study outcomes, unable to provide informed consent, with significant cervical spine pathology, with radiculopathy, and/or elite athletes.

Nonoperative treatment

All patients underwent a nonoperative treatment program as directed by the treating physician. Treatment plans were personalized to each patient and included any combination of rest or activity modification, pain medications, anti-inflammatories,

subacromial steroid injections, and a physiotherapist instituted and supervised home-based rehabilitation program. The program included stretching exercises, and strengthening exercises including posterior capsular stretching and rotator cuff and parascapular muscle strengthening.

Patient oriented outcomes

All patients completed two shoulder specific questionnaires, the American Shoulder and Elbow Surgeons (ASES) evaluation and the Simple Shoulder Test (SST), at baseline and follow-up. Patients were assessed by the senior author, and, based on the criteria of his practice, consented to undergo either surgical repair or continuation of nonoperative treatment of their PT-RCT.

Baseline characteristics were also collected to determine their predictive value to the success or failure of nonoperative treatment. Baseline characteristics included age, gender, dominant/nondominant side affected, traumatic/atraumatic onset of symptoms, duration of symptoms, active forward elevation range of motion, external rotation strength (with arm at side), ASES score, and SST score. In addition, since the benchmark of 50% of the tendon thickness torn is commonly used to direct surgical treatment, percentage of thickness torn (ie, <50%, ≥50%) as determined on MRI or MRA was also evaluated.

Imaging oriented outcomes

Patients treated nonoperatively underwent follow-up MRI or MRA (matched to their baseline imaging) to determine if their tear had healed, remained the same, or progressed (based on T2, fat suppressed coronal oblique views). All MRI and MRA scans were evaluated by a musculoskeletal-trained radiologist who was blinded to the patient's clinical outcome. At final follow-up to determine any disease progression or resolution, the radiologist could view and compare both initial and final MRI/MRA scans. However, the radiologist was blinded to the MRI sequence. In terms of imaging outcomes, an estimated structural deterioration (tear progression) of >25% of the tendon thickness was considered meaningful.

Operational definitions

Grouping

To determine the clinical success rate of nonoperative treatment, we grouped patients into "success" or "failure" groups. Patients who underwent surgery were considered "failures" of nonoperative treatment. Patients who experienced enough relief of their symptoms with the nonoperative program that they were able to avoid surgery were considered "successes."

Analysis

To examine the ability to predict the outcome of nonoperative treatment using the baseline variables identified, patients were grouped based on their outcome (success or failure). With the dichotomous nature of the primary outcome, logistic regression was used for analysis. Each a-priori identified independent variable was examined for association with the dependent variable (outcome of nonoperative treatment) in univariable logistic regression equations using the enter method.

Data analysis

The likelihood of the relationship being due to chance was determined using *P*-values. If the relationship was not likely to be explained by chance (*P*<0.25) it was concluded that the given independent variable accounted for a statistically significant proportion of the variability in the outcome. This was performed separately for each independent variable. *P*=0.25 was selected only for the first step of the analysis so as not to exclude variables too freely and is supported in the literature.⁸⁻¹⁰

Exploratory analysis

All variables that demonstrated significance in the univariable comparisons were analyzed together in a single multivariable logistic regression model as an exploratory analysis.

All data were analyzed using SPSS (IBM Corporation, Armonk, NY, USA).

Results

Seventy-six patients (48 males, 28 females) with an average age of 52±10 years were included in the study. Forty-six (61%) were involved of their dominant arm, while 30 (39%)

had involvement of their nondominant arm. Baseline ASES scores were 54.9±19.6 (out of 100), and baseline SST scores were 5.9±3.1 (out of 12).

Of the 76 patients, 37 (49%) underwent nonoperative treatment while 39 (51%) underwent surgical repair. The baseline demographic characteristics of patients in each group (success or failure) are shown in Table 1. Univariable logistic regression analysis indicated that the baseline variables of side (dominant or nondominant side involved), onset (traumatic or atraumatic), thickness of tear (<50% or ≥50%), and initial ASES score were significant predictors of outcome with the *P*-value set at 0.25 so as not to exclude variables too freely in the primary step of analysis. However, multivariable logistic regression was then performed on the above-identified variables and demonstrated that side, onset, and thickness of the tendon torn were the three most significant variables with a *P*-value set at 0.05.

Successful nonoperatively treated patients

Of the patients successfully treated nonoperatively, all 37 patients underwent clinical and imaging follow-up at a mean of 46±7 months following their initial consult. A blinded research assistant performed all clinical follow-ups. The mean ASES score at follow-up was 85.1±16.9 (out of 100), and the mean SST score was 10.0±2.5 (out of 12) and was significantly different from baseline scores (*P*<0.01). Overall subjective patient satisfaction on a 10-point scale was 7.5±2.3. However, four patients were dissatisfied with their treatment. One patient wished they had done less physical therapy, and three other patients had ongoing symptoms although had not undergone surgical intervention.

Table 1 Baseline clinical variables of patients with successful or failed nonoperative treatment of their partial-thickness rotator cuff tear

Baseline variables	Successful nonoperative treatment (n=37)	Failure of nonoperative treatment (n=39)
Mean age (years)	52.9±9.3	51.3±10.7
Gender	25 males (68%) 12 females (32%)	23 males (59%) 16 females (41%)
Dominant/nondominant	18 dominant (49%) 19 nondominant (51%)	28 dominant (72%) 11 nondominant (28%)
Traumatic/atraumatic onset	6 traumatic (16%) 31 atraumatic (84%)	13 traumatic (33%) 23 atraumatic (59%) 3 unclear (8%)
Symptom duration (months)	23.1±22.7	30.7±35.9
ASES score	64/100±20.1	50/100±18
SST score	6.6/12±2.9	5.4/12±3.0
Thickness	24 patients (65%)<50% 13 patients (35%)≥50%	16 patients (41%)<50% 23 patients (59%)≥50%

Abbreviations: ASES, American Shoulder and Elbow Surgeons, SST, Simple Shoulder Test.

Imaging outcome (MRI or MRA) was performed at an average follow-up of 53.0 ± 8.0 months. Nine patients (24%) demonstrated tear progression, of which three (8%) demonstrated full-thickness tearing (Figure 1). Twenty-four patients (65%) demonstrated no significant difference on their scans, and four patients (11%) showed improved tissue quality or some evidence of healing (Figure 2). Overall, 76% of tears treated nonoperatively did not show a tear progression on anatomic imaging.

When examined by thickness of tear involvement, tears that were $<50\%$ thickness demonstrated tear progression 14% of the time, while tears that were $>50\%$ thickness demonstrated tear progression 55% of the time ($P < 0.05$). There was no significant difference in ASES or SST scores in patients

who had progression of their tear on MRI when compared to patients who had improvement or no significant change ($P = 0.087$, ASES; $P = 0.051$, SST).

Discussion

Despite being one of the most common causes of pain in the adult shoulder, the relative success of nonoperative treatment of rotator cuff tears is largely unknown. Nonoperative treatment for rotator cuff tears may include a number of modalities including physical therapy, steroid injections, and anti-inflammatory or pain medications.

At our institution, a previous study demonstrated that 75% of patients with chronic full-thickness tears of the rotator cuff could be successfully treated nonoperatively⁷

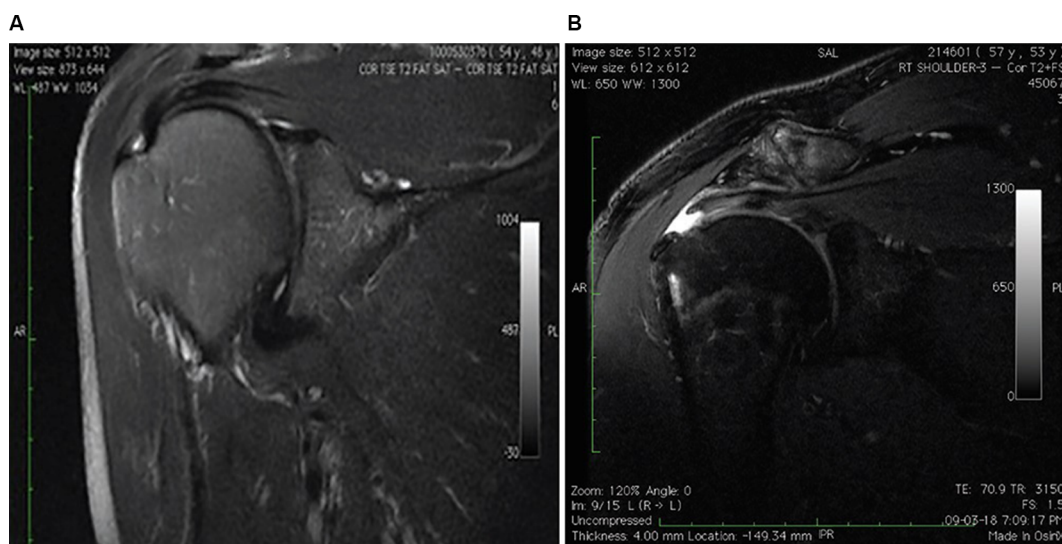


Figure 1 T2-weighted fat-suppressed coronal MRI demonstrating a partial thickness rotator cuff tear: (A) initial MRI; (B) final MRI demonstrating tear progression.

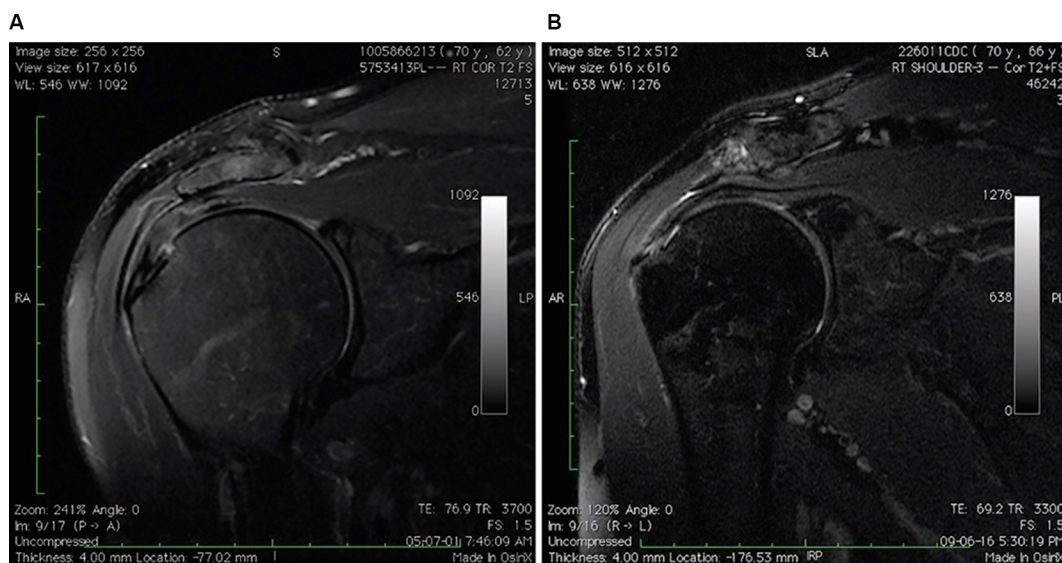

Figure 2 T2-weighted fat-suppressed coronal MRI demonstrating a partial thickness rotator cuff tear: (A) initial MRI; (B) final MRI demonstrating no significant tear progression.

with a home-based physical therapy directed program. Furthermore, a recent study by Kuhn et al¹¹ has also evaluated the effectiveness of a nonoperative treatment program on chronic atraumatic full-thickness rotator cuff tears. In this multicentered study, >90% of patients were successfully treated with a nonoperative physical therapy-based program. Edwards et al,¹² in their 2016 review of the literature, showed that conservative treatment can be effective in those with small (<1 cm) full-thickness tears, as well as older (>65 years) patients with chronic, full-thickness tears and associated muscle atrophy and fatty infiltration. Mathiasen and Hogrefe¹³ suggest a course of conservative therapy for chronic tears in their primary care perspective paper as well. These studies highlight the effectiveness of nonoperative treatment for full-thickness rotator cuff tears.

However, the success of nonoperative treatment for PT-RCTs is relatively unknown. Nonoperative treatment of PT-RCTs may be more acceptable than that for full-thickness rotator cuff tears where the risk of muscular atrophy, fatty infiltration, and catastrophic tear extension are minimal. In our study, ~50% of patients were successfully treated nonoperatively, and 91% of patients were still satisfied with their shoulder ~4 years later. Edwards et al¹² also suggest prolonged conservative treatment for patients with partial thickness tears, based on their review of the literature. A study by Lee et al¹⁴ examined high grade partial thickness tears grouped with medium sized or smaller full thickness tears and concluded that, in patients aged >50 years, effectiveness of conservative treatment was not inferior to arthroscopic repair. Further, Kim et al¹⁵ showed that delayed surgical repair following a course of conservative treatment in partial thickness tears did not yield worse results as compared to immediate arthroscopic repair, and, in fact, those who underwent 6 months of conservative treatment prior to repair showed improved functional results at 6 months post-operative as compared to those who underwent immediate repair. Therefore, at least at short to mid-term follow-up, nonoperative treatment of PT-RCTs can be successful.

Why the success rate is somewhat lower than the success rate for full-thickness rotator cuff tears is unclear. However, a number of different factors may be important. First, the study setting was a tertiary-based sport medicine/shoulder practice and, therefore, many patients already had a prolonged history of symptoms and disability and may have had a preconceived expectation of surgery. A community-based primary care setting may have a higher nonoperative treatment success rate. Second, some patients may have already had some non-operative treatment (whether effective or not) and, therefore,

may have influenced the patient and/or physician treatment decisions. Third, this study included patients with a traumatic history of symptoms with symptom duration as short as 3 months. These patients may be more likely to choose surgical treatment when compared to the patients in the previous studies (of full-thickness rotator cuff tears), where only atraumatic, chronic full-thickness tears were considered.

Finally, PT-RCTs may, in fact, be more painful than full-thickness rotator cuff tears. In a study by Fukuda,¹⁶ patients with subacromial bursitis or PT-RCTs were more likely to describe more severe pain than patients with full-thickness rotator cuff tears. Since the major indication for rotator cuff surgery is pain relief, then PT-RCTs may, in fact, require surgery more often.

Despite this, nonoperative treatment still was successful in ~50% of patients. Importantly, we also detected several clinical predictors of success of nonoperative treatment. In patients with atraumatic PT-RCTs involving <50% of the tendon thickness of the nondominant extremity, nonoperative treatment was more likely to be successful. As discussed above, the atraumatic nature of these lesions may be important (similar to atraumatic full-thickness tears) and more representative of degenerative age-related disease.

In contrast, in patients with traumatic lesions involving >50% of the tendon thickness of the dominant extremity, non-operative treatment was more likely to fail. Although the reasons for this are unclear, cadaveric studies have demonstrated that PT-RCTs can alter the strain behavior of the residual intact rotator cuff tendon. However, significant alterations only occur after >50% of the tendon thickness is torn.¹⁷ This may, therefore, lead to ongoing symptoms or affect long-term tear propagation. Furthermore, dominant extremity disease has previously been demonstrated to be a factor related to symptomatic rotator cuff disease progression.¹⁸

The other important finding in our study was the follow-up MRI/MRA scans of patients treated nonoperatively. Few studies have evaluated the imaging outcome of non-operatively treated PT-RCTs.¹⁸⁻²⁰ In 1994, Yamanaka and Matsumoto²⁰ reported on 40 patients with articular surface rotator cuff tears treated nonoperatively. They demonstrated by follow-up arthrography a mean of 1.1 years later that 80% of their patients had progression of their tear (11 patients full-thickness), 10% reduced in size, and 10% disappeared.

Our study is in distinct contrast to the results of Yamanaka and Matsumoto.²⁰ At a mean follow-up of 4.4 years, only 24% of patients demonstrated progression of their tear with three patients (8%) demonstrating full-thickness tear progression. The large disparity in results is unclear; however,

the disparity may be related to the differences in accuracy of diagnostic imaging. Furthermore, our results are in concordance with more recent studies. Kim et al²¹ showed that tear size increased in only 26% of patients with a partial thickness tear measured via MRI over 6–100 months following nonoperative treatment (compared to 82% of full-thickness tears which interestingly showed progression). In 2010, Mall et al¹⁸ published their results of serial ultrasound evaluation of asymptomatic rotator cuff tears. They evaluated 30 patients with PT-RCTs. Overall, four of 30 patients (13%) had progression of their tear to full-thickness rotator cuff tears on serial ultrasounds, the majority of which developed symptoms. In the subset of patients who continued to be asymptomatic, no PT-RCT progressed to a full-thickness tear. Similarly, Maman et al¹⁹ reported that 26 of 30 patients (86%) with PT-RCTs remained stable during their follow-up period by MRI.

However, in our study, in patients with tears involving $\geq 50\%$ of the tendon thickness, 55% of partial-thickness tears progressed, compared to 14% of partial-thickness tears involving $< 50\%$ of the tendon thickness. This may again be related to the altered strain fields in tendon tears $> 50\%$ of the tendon thickness. In addition, this supports the notion that surveillance monitoring of partial-thickness rotator cuff tendon tears may be indicated particularly in patients with tendon tears involving $\geq 50\%$ of the tendon thickness or if symptoms develop.

The weaknesses of this study are:

- a comparative operative group were not included in the analysis;
- it is unclear what the effect of the tertiary care setting may have been;
- this is an evaluation of a single surgeon's treatment which limits the generalizability of the findings;
- the surgical group did not have MRI follow-up.

Despite these limitations, we believe that the results are interesting and valid in the treatment of PT-RCTs in this setting.

Conclusion

Nonoperative treatment was utilized in $\sim 50\%$ of the patients and resulted in improved clinical outcomes and patient satisfaction. The baseline factors of onset (traumatic vs atraumatic), shoulder involved (dominant vs nondominant), and tendon thickness torn ($< 50\%$ vs $\geq 50\%$) can be used to predict the success of nonoperative treatment. Twenty-four percent of tears demonstrated tear progression on anatomic

imaging follow-up, with the majority of tear progression occurring in tears that were $\geq 50\%$ thickness at presentation.

Acknowledgment

The Workers' Compensation Board – Alberta provided financial support for this work.

Disclosure

The authors report no conflicts of interest in this work.

References

1. Sher JS, Uribe JW, Posada A, Murphy BJ, Zlatkin MB. Abnormal findings on magnetic resonance images of asymptomatic shoulders. *J Bone Joint Surg Am.* 1995;77(1):10–15.
2. Finnan RP, Crosby LA. Partial-thickness rotator cuff tears. *J Shoulder Elbow Surg.* 2010;19(4):609–616.
3. Franceschi F, Papalia R, del Buono A, Maffulli N, Denaro V. Repair of partial tears of the rotator cuff. *Sports Med Arthrosc Rev.* 2011;19(4):401–408.
4. Pegreff F, Paladini P, Campi F, Porcellini G. Conservative management of rotator cuff tear. *Sports Med Arthrosc Rev.* 2011;19(4):348–353.
5. Rudzki JR, Shaffer B. New approaches to diagnosis and arthroscopic management of partial-thickness cuff tears. *Clin Sports Med.* 2008;27(4):691–717.
6. Strauss EJ, Salata MJ, Kercher J, et al. Multimedia article. The arthroscopic management of partial-thickness rotator cuff tears: a systematic review of the literature. *Arthroscopy.* 2011;27(4):568–580.
7. Boorman RS, More KD, Hollinshead RM, et al. The rotator cuff quality-of-life index predicts the outcome of nonoperative treatment of patients with a chronic rotator cuff tear. *J Bone Joint Surg Am.* 2014;96(22):1883–1888.
8. Bendel R, Affifi A. Comparison of stopping rules in forward regression. *J Am Stat Assoc.* 1977;72:46–53.
9. Hosmer D, Lemeshow S. *Applied Logistic Regression.* 2nd ed. New York: John Wiley & Sons; 2000.
10. Mickey RM, Greenland S. The impact of confounder selection criteria on effect estimation. *Am J Epidemiol.* 1989;129(1):125–137.
11. Kuhn JE, Dunn WR, Sanders R, et al. Effectiveness of physical therapy in treating atraumatic full-thickness rotator cuff tears: a multicenter prospective cohort study. *J Shoulder Elbow Surg.* 2013;22(10):1371–1379.
12. Edwards P, Ebert J, Joss B, Bhabra G, Ackland T, Wang A. exercise rehabilitation in the non-operative management of rotator cuff tears: a review of the literature. *Int J Sports Phys Ther.* 2016;11(2):279–301.
13. Mathiasen R, Hogrefe C. Evaluation and Management of Rotator Cuff Tears: a Primary Care Perspective. *Curr Rev Musculoskelet Med.* 2018;11(1):72–76.
14. Lee WH, do HK, Lee JH, et al. Clinical Outcomes of Conservative Treatment and Arthroscopic Repair of Rotator Cuff Tears: A Retrospective Observational Study. *Ann Rehabil Med.* 2016;40(2):252–262.
15. Kim YS, Lee HJ, Kim JH, Noh DY. When Should We Repair Partial-Thickness Rotator Cuff Tears? Outcome Comparison Between Immediate Surgical Repair Versus Delayed Repair After 6-month Period of Nonsurgical Treatment. *Am J Sports Med.* 2018;46(5):1091–1096.
16. Fukuda H. Partial-thickness rotator cuff tears: a modern view on Codman's classic. *J Shoulder Elbow Surg.* 2000;9(2):163–168.
17. Mazzocca AD, Rincon LM, O'Connor RW, et al. Intra-articular partial-thickness rotator cuff tears: analysis of injured and repaired strain behavior. *Am J Sports Med.* 2008;36(1):110–116.

18. Mall NA, Kim HM, Keener JD, et al. Symptomatic progression of asymptomatic rotator cuff tears: a prospective study of clinical and sonographic variables. *J Bone Joint Surg Am.* 2010;92(16):2623–2633.
19. Maman E, Harris C, White L, Tomlinson G, Shashank M, Boynton E. Outcome of nonoperative treatment of symptomatic rotator cuff tears monitored by magnetic resonance imaging. *J Bone Joint Surg Am.* 2009;91(8):1898–1906.
20. Yamanaka K, Matsumoto T. The joint side tear of the rotator cuff. A followup study by arthrography. *Clin Orthop Relat Res.* 1994;304(304):68–73.
21. Kim YS, Kim SE, Bae SH, Lee HJ, Jee WH, Park CK. Tear progression of symptomatic full-thickness and partial-thickness rotator cuff tears as measured by repeated MRI. *Knee Surg Sports Traumatol Arthrosc.* 2017;25(7):2073–2080.

Open Access Journal of Sports Medicine

Publish your work in this journal

The Open Access Journal of Sports Medicine is an international, peer-reviewed, open access journal publishing original research, reports, reviews and commentaries on all areas of sports medicine. The journal is included on PubMed. The manuscript management system is completely online and includes a very quick and fair

Submit your manuscript here: <http://www.dovepress.com/open-access-journal-of-sports-medicine-journal>

peer-review system. Visit <http://www.dovepress.com/testimonials.php> to read real quotes from published authors.

Dovepress