

Uterine Arteriovenous Malformations

Martina Bartolone^{1*}, Enrica Saluzzi¹, Allegra Mazzeo¹, Valentina D'Ambrosio¹, Sara Corno¹, Daniele Di Mascio¹, Lucia Manganaro², Antonella Giaccotti¹

¹Department of Maternal and Child Health and Urogynecological Sciences, Sapienza University of Rome, Umberto I Hospital, Rome, Italy,

²Department of Radiological, Oncological and Pathological Sciences, Policlinico Umberto I, Sapienza University of Rome, Rome, Italy

Abstract

Uterine arteriovenous malformations (AVMs) are an abnormal presence of shunts between myometrial arteries and veins within the myometrium that usually occurs after a traumatic event on the uterus and it is often diagnosed after a miscarriage. In this case report, we propose the case of a woman, gravida 3 para 2, admitted at the emergency department presenting deep vaginal bleeding and suspicion of incomplete miscarriage at 11 weeks of pregnancy. The suspect of AVM was made with noninvasive procedure; transvaginal ultrasound examination with the advantage of color Doppler showed a myometrial hypervascular lesion of the posterior wall. Pulsed Doppler permitted the waveform analysis of uterine arteries and three-dimensional sonography with color Doppler and reconstructions clearly showed dilated and tortuous blood vessels within the context of the myometrium. Magnetic resonance angiography showed multiple tubular structures with tortuous appearance that confirmed the suspicion of AVM. Uterine artery embolization was performed of the right uterine artery. One month after uterine embolization, the ultrasound control confirmed the complete resolution of the AVM.

Keywords: Embolization, magnetic resonance, ultrasound, uterine arteriovenous malformation, vaginal bleeding

INTRODUCTION

Uterine arteriovenous malformations (AVMs) are an abnormal presence of shunts between myometrial arteries and veins within the myometrium.^[1] The incidence of AVMs is still unknown.^[2] They are infrequent and are classified as congenital or acquired. The acquired AVM is usually due to a traumatic event including curettage, cesarean delivery, and myomectomy.^[3] Endometrial carcinoma and gestational trophoblastic disease have also been described as leading causes.^[4] The clinical symptoms are variable, patients can be asymptomatic, most commonly presenting irregular bleeding after miscarriage, with heavy hemorrhage more rarely.^[5]

The diagnosis is made with noninvasive procedures: A tangle of tortuous vessels with multidirectional, high-velocity, and turbulent flow at Doppler ultrasound evaluation is the gold standard for the diagnosis of AVMs; angiography magnetic resonance shed light on the disruption of the junctional zones between the myometrium and the endometrium. Eventually, a computed tomography scan can follow.^[6]

The treatment depends on the patient's pregnancy desire and on her hemodynamic condition.^[7] In asymptomatic women,

expectant management can be considered. In case of mild bleeding in a hemodynamically stable patient who wishes to conceive, conservative radiologic management with uterine artery embolization (UAE) seems to be the safest and most effective intervention.^[8] Surgical hysteroscopy appears to be a good option as well.^[9]

In case of life-threatening bleeding, radical surgery with hysterectomy is mandatory.

Herein, we present the case of a patient diagnosed with uterine AVM, who successfully underwent conservative treatment.

CASE REPORT

A 34-year-old woman, gravida 3 para 2, was admitted at our emergency department, with suspicion of incomplete miscarriage at 11 weeks of pregnancy, with heavy vaginal bleeding. The patient only reported two positive urinary

Address for correspondence: Dr. Martina Bartolone,

Department of Maternal and Child Health and Urogynecological Sciences, Sapienza University of Rome, Umberto I Hospital, Viale Del Policlinico 155, 00161, Rome, Italy.

E-mail: martinabartolone92@gmail.com

Received: 11-10-2022 Revised: 22-01-2023 Accepted: 21-02-2023 Available Online: 03-08-2023

Access this article online

Quick Response Code:



Website:
<https://journals.lww.com/jmut>

DOI:
10.4103/jmu.jmu_103_22

This is an open access journal, and articles are distributed under the terms of the Creative Commons Attribution-NonCommercial-ShareAlike 4.0 License, which allows others to remix, tweak, and build upon the work non-commercially, as long as appropriate credit is given and the new creations are licensed under the identical terms.

For reprints contact: WKHLRPMedknow_reprints@wolterskluwer.com

How to cite this article: Bartolone M, Saluzzi E, Mazzeo A, D'Ambrosio V, Corno S, Mascio DD, *et al.* Uterine arteriovenous malformations. J Med Ultrasound 2024;32:266-70.

pregnancy tests. No previous physical or pelvic examination or blood tests have been performed.

Personal and family's past medical history were negative. She was a nonsmoker, without allergies, and previous abdominal or pelvic surgery.

The patient was hemodynamically stable, heart rate of 100/min, blood pressure of 138/82 mmHg, and temperature of 36°C. Pelvic examination showed a bulky uterus and normal adnexa. Urinary human chorionic gonadotropin (HCG) detection test was negative, while beta-HCG was 26.8 mIU/mL (0–2) in two consecutive tests 12 h apart. Complete blood tests and clotting profile were normal; hemoglobin level was 10.7 g/dL.

Transvaginal ultrasound examination showed a myometrial hypervascular lesion of the posterior uterine wall, up to the endometrium, measuring 33 mm × 26 mm and a 4 mm echogenic spot on the uterine isthmus, suspected for retained tissue in spontaneous expulsion [Figure 1]. The endometrium appeared not homogeneous and irregular (maximum thickness 15 mm), suggesting for blood clots into the uterus cavity. Free fluid of the cul sac was found as well [Figure 2]. The study of the uterus with the color Doppler revealed an intense and hypervascular

lesion with high signal throughout the posterior wall of the myometrium, measuring 21 mm × 18 mm [Figure 3]. A tangle of multiple hypertrophied and tortuous vessels within the myometrium, at the endometrial junction, with multidirectional, high-velocity, and turbulent flow, producing a color mosaic pattern, was found. No active flow was detected into the endometrial cavity [Figure 4]. To better study, the resistance of the vessel found, pulse Doppler was utilized: the waveform analysis of the arteries showed a resistance index of 0, 41 and a pulsatility index of 0, 54 [Figure 5]. To complete the ultrasound evaluation, three-dimensional (3D) power Doppler sonography was performed. This showed numerous dilated and tortuous blood vessels with multidirectional turbulent flow. Color and pulsed wave Doppler mode assessment showed a pulsatile arterial Doppler flow with systolic velocity peak of 34 cm/s [Figure 6a and b].

The use of 3D reconstruction of the uterus with color Doppler demonstrates more clearly a lesion suspicious for an AVM. Three-dimensional surface-rendered reconstruction optimizes visualization of the lesion vascularity [Figure 7a and b]. Based on clinical and imaging findings, a uterine AVM was suspected. Magnetic resonance angiography proved a 4 cm × 3 cm × 3 cm abnormal vascular area throughout the uterine wall, composed by multiple tubular structures with tortuous appearance and “flow-void signal” in T2W sequences, early intense enhancement, and synchronous with adjacent vessels and

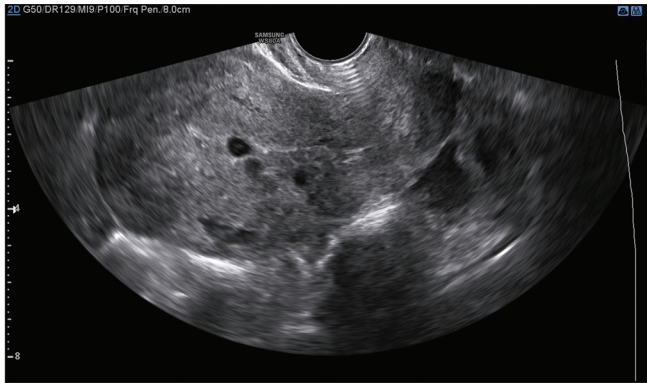


Figure 1: Grayscale bidimensional ultrasound image showing longitudinal view of uterine body with anechoic area suspect for incomplete miscarriage

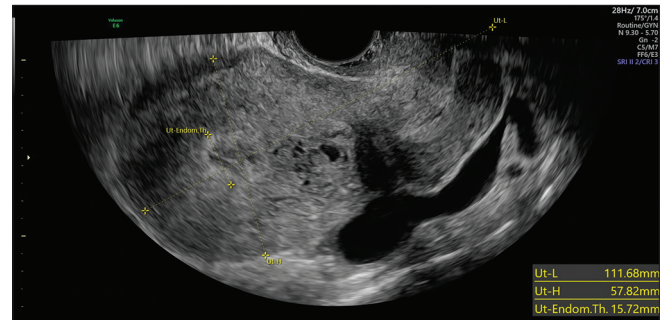


Figure 2: Grayscale bidimensional sonogram showing longitudinal view of uterine body with an inhomogeneous endometrium with multiple anechoic spaces. A free fluid of the cul the sac of Douglas is also visualized

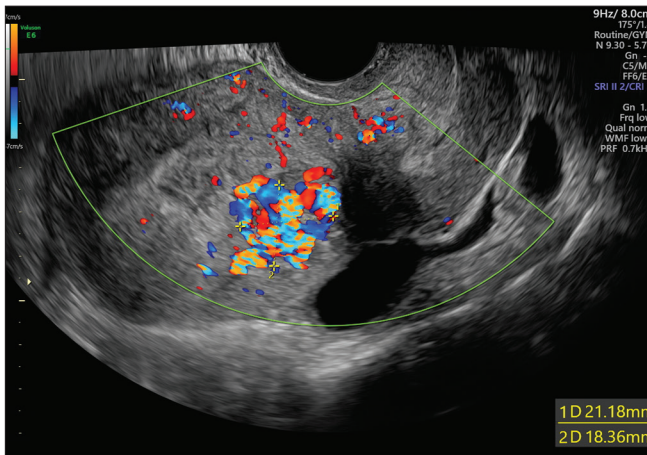


Figure 3: Color Doppler ultrasound sagittal view of the uterus with turbulent flow and aliasing creating a mosaic pattern

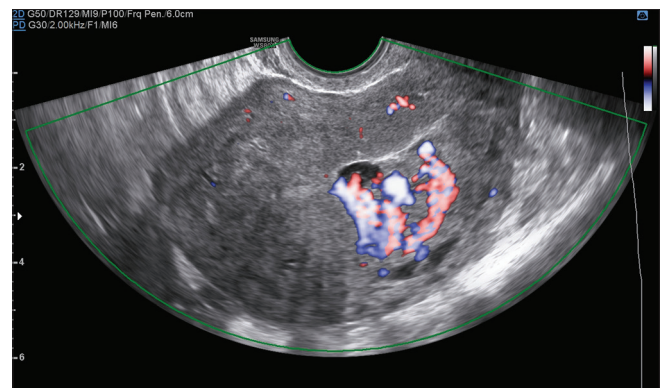


Figure 4: Color mosaic pattern of the myometrium analyzed with High Definition Power Doppler

rapid wash out; it presented several arterial afferences from right uterine artery and venous efferences mostly confluent in homolateral ectasic ovarian plexus [Figure 8]. These findings confirmed the suspicion of AVM.

In consideration of the heavy vaginal bleeding and the fact that the patient would not have wanted another pregnancy, we chose to perform UAE, instead of expecting management.

UAE was performed through femoral access using 20 cc of particles of 500–700 μm after selective catheterization of the intern iliac artery and right uterine artery [Figures 9-11]. The catheterization of the contralateral uterine artery demonstrated no afferences to the AVM. No postoperative complication was described.

During the observation, the patient was asymptomatic and hemodynamically stable, without significant vaginal bleeding. Blood tests were constantly normal, and HCG progressively became negative, in 3 weeks. One month after the UAE, 3D power Doppler ultrasound show no sign of abnormal vascularization, with complete resolution of the AVM [Figure 12], while the menstrual cycle began 40 days after embolization, and it was normal in quantity and duration.

To complete the follow-up of the patient, a control magnetic resonance imaging (MRI) was requested, demonstrating a normal junctional zone architecture with ordinary vascularization of the uterus [Figure 13].

DISCUSSION

AVMs are not so frequent conditions that could be suspected after a miscarriage in the presence of hypervascularized endometrium. The ultrasound examination supported by color Doppler and 3D technology could lead to the diagnosis. The addition of MRI supports the final diagnosis and the noninvasive therapy.

Declaration of patient consent

The authors certify that they have obtained all appropriate patient consent forms. In the form, the patient has given her consent for her images and other clinical information to be reported in the journal. The patient understands that her name and initials will not be published and due efforts will be made to conceal her identity, but anonymity cannot be guaranteed.

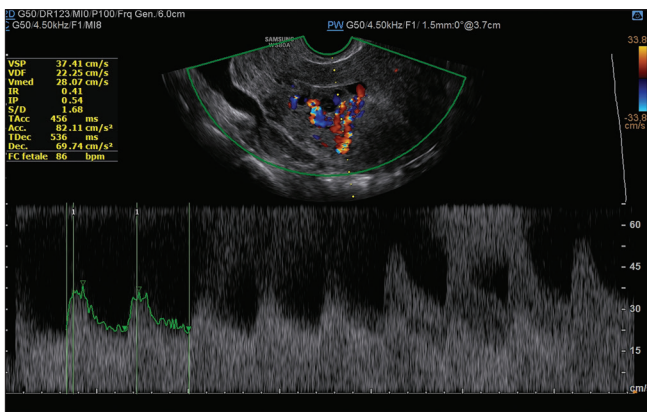


Figure 5: Spectral analysis revealing low-resistance index suggesting arteriovenous malformation

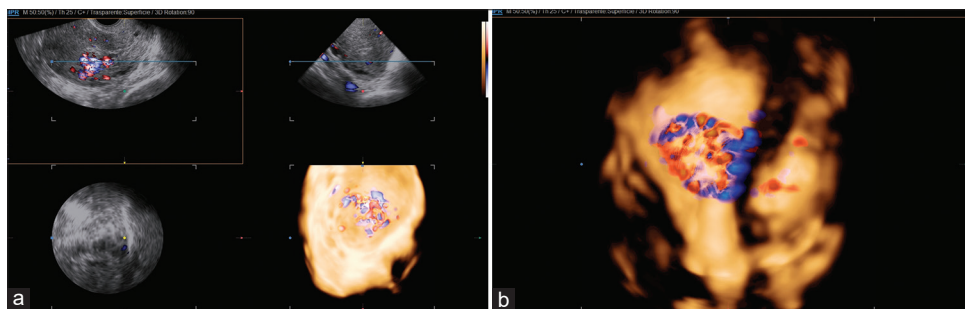


Figure 6: (a and b) Three-dimensional power Doppler ultrasound reconstruction of the uterus using a glass body technique to differentiate tissue and vessels. This method reveals a hypervascular lesion in the myometrium

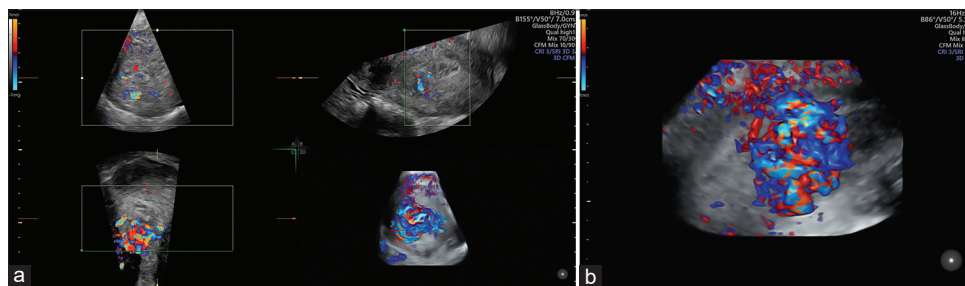


Figure 7: (a and b) Surface-rendered reconstruction showing irregular vessels of arteriovenous malformation in bicolor and monochrome Three-dimensional high-definition flow

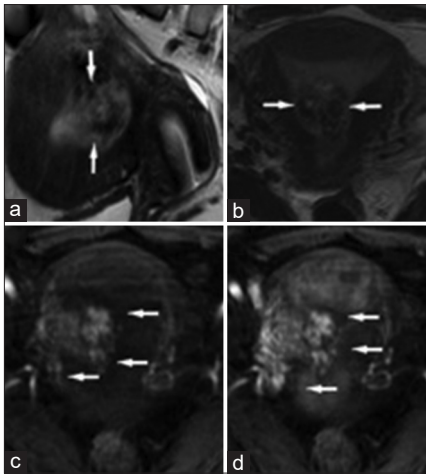


Figure 8: Sagittal and axial T2-weighted sequences (a and b) showing an enlarged uterus with hypointense lesion at the right lateral wall extending into the uterine cavity. After administration of intravenous contrast, marked enhancement is present in the early arterial phase (c and d). Arrows indicate myometrial and endometrial vessels

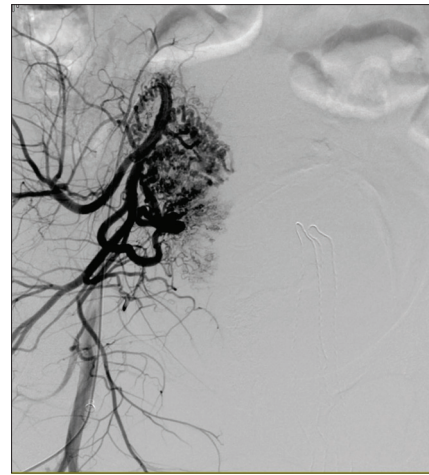


Figure 9: Images of the contrast material injected into the right uterine artery that revealed the enhanced myometrial vascularity/ arteriovenous malformation before (image A and B) and after the uterine artery embolization (image C)

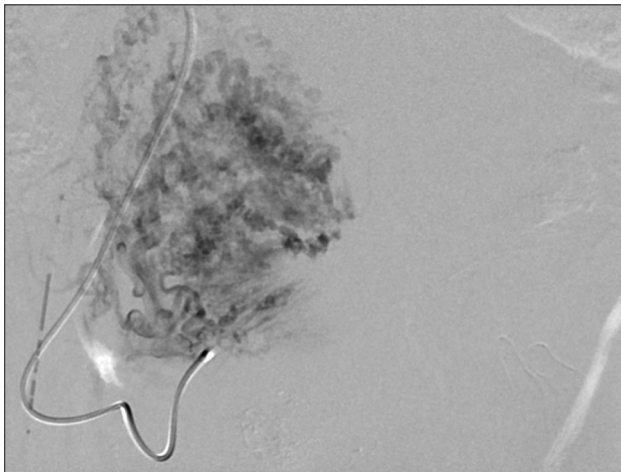


Figure 10: Images of the contrast material injected into the right uterine artery that revealed the enhanced myometrial vascularity/arteriovenous malformation before artery embolization

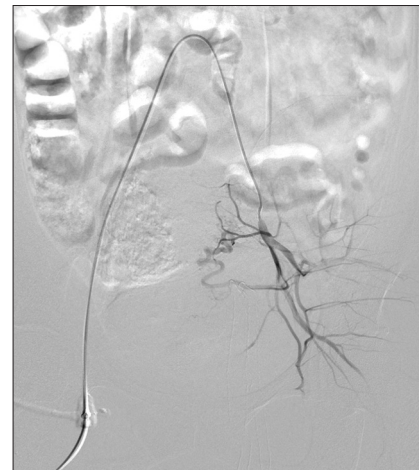

Figure 11: Images of the contrast material injected into the right uterine artery that revealed the enhanced myometrial vascularity/arteriovenous malformation after the uterine artery embolization

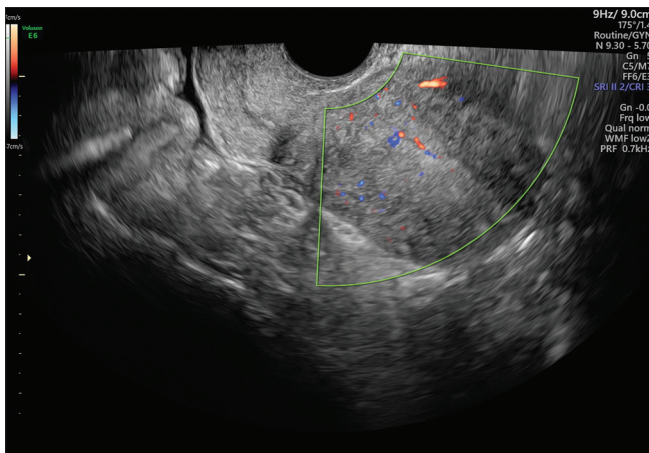


Figure 12: Transvaginal ultrasound image 1 month after embolization

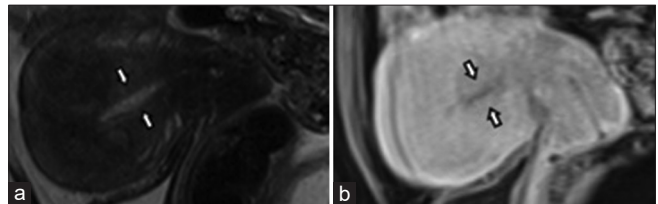


Figure 13: Magnetic resonance performed 1 month after treatment. Sagittal plane on T2 (a) and on T1 (b) after contrast enhancement. Arrows indicate endometrium

Financial support and sponsorship

Nil.

Conflicts of interest

There are no conflicts of interest.

REFERENCES

1. Diwan RV, Brennan JN, Selim MA, McGrew TL, Rashad FA, Rustia MU, *et al.* Sonographic diagnosis of arteriovenous malformation of the uterus and pelvis. *J Clin Ultrasound* 1983;11:295-8.
2. Vogelzang RL, Nemcek AA Jr., Skrtic Z, Gorrell J, Lurain JR. Uterine arteriovenous malformations: Primary treatment with therapeutic embolization. *J Vasc Interv Radiol* 1991;2:517-22.
3. Timor-Tritsch IE, Haynes MC, Monteagudo A, Khatib N, Kovács S. Ultrasound diagnosis and management of acquired uterine enhanced myometrial vascularity/arteriovenous malformations. *Am J Obstet Gynecol* 2016;214:731.e1- 731.e10.
4. Polat P, Suma S, Kantarcý M, Alper F, Levent A. Color Doppler US in the evaluation of uterine vascular abnormalities. *Radiographics* 2002;22:47-53.
5. Yoon DJ, Jones M, Taani JA, Buhimschi C, Dowell JD. A systematic review of acquired uterine arteriovenous malformations: Pathophysiology, diagnosis, and transcatheter treatment. *AJP Rep* 2016;6:e6-14.
6. Delplanque S, Le Lous M, Proisy M, Joueidi Y, Bauville E, Rozel C, *et al.* Fertility, pregnancy, and clinical outcomes after uterine arteriovenous malformation management. *J Minim Invasive Gynecol* 2019;26:153-61.
7. Elia G, Counsell C, Singer SJ. Uterine artery malformation as a hidden cause of severe uterine bleeding. A case report. *J Reprod Med* 2001;46:398-400.
8. Dimassi K, Ben Amor A, Halouani A, Dali N, Ben Farhat L, Triki A. Successful management of acquired uterine arteriovenous malformation. *Tunis Med* 2018;96:445-7.
9. Calzolari S, Cozzolino M, Castellacci E, Dubini V, Farruggia A, Sisti G. Hysteroscopic management of uterine arteriovenous malformation. *JSLs* 2017;21:e2016.00109.