

# Sentinel Pelvic Lymph Node Dissection by Natural Orifices Transvaginal Endoscopic Surgery Approach after Indocyanine Green Dye Detection in Early Endometrial Cancer of Posthysterectomy Patient

Wint Thida Htay<sup>1,2</sup>, Chen-Ying Huang<sup>2</sup>, Chyi-Long Lee<sup>2\*</sup>

<sup>1</sup>Department of Obstetrics and Gynecology, University of Medicine 2, Yangon, Myanmar, <sup>2</sup>Department of Obstetrics and Gynecology, Chang Gung Memorial Hospital at Linkou Kweishan, Taoyuan, Taiwan

## Abstract

There was a case of 57-year-old female who was done the natural orifices transvaginal endoscopic surgery (NOTES) hysterectomy and bilateral salpingo-oophorectomy for benign disease. However, her biopsy result was Grade 1 endometrioid adenocarcinoma, and she was incidentally diagnosed as endometrial cancer. She was uneventful apart from that finding. She underwent the sentinel pelvic lymph node dissection with indocyanine green-guided NOTES approach for complete staging. This technique may be helpful to maximize the complete staging in early endometrial cancer as well as it can minimize the morbidity-related lymphadenectomy. In conclusion, in spite of a new technique for NOTES, it can be safe and cost-effective for patients.

**Keywords:** Endometrial cancer, indocyanine green dye, natural orifices transvaginal endoscopic surgery, sentinel lymph node mapping

## INTRODUCTION

The incidence of endometrial cancer is increasing even in developed countries. In the United States, it was estimated that there are 53,911 new cases of endometrial cancer and 27/100,000 death cases were reported in 2015. Uterine cancer incidence rates increased 0.7%/year during 1999–2015, and death rates increased 1.1%/year during 1999–2016.<sup>[1]</sup> A complete surgical staging, including lymphadenectomy, is the gold standard to evaluate lymph node involvement. Laparoscopic indocyanine green (ICG)-guided sentinel lymph node mapping in endometrial cancer is characterized by high overall (96%) and bilateral (88%) detection rates.<sup>[2]</sup> Recently, gynecologists have increasingly used minimally

invasive technique (MIT) to treat gynecological cancer. Natural orifice transluminal endoscopy is one of the MITs. We have reported the first natural orifices transvaginal endoscopic surgery (NOTES) surgical staging surgery for endometrial cancer.<sup>[3]</sup> In this study, there was discussed a new technique of ICG-guided sentinel pelvic lymph node dissection in posthysterectomy patient by NOTES approach in early endometrial cancer.

## CASE REPORT

This study was approved by Chang Gung Memorial Hospital Institutional Review Board. This case was

**Address for correspondence:** Prof. Chyi-Long Lee,  
No. 5, Fuxing Street, Kweishan, Taoyuan 333, Taiwan.  
E-mail: leechilong@gmail.com

### Article History:

Received 3 December 2018  
Received in revised form 14 January 2019  
Accepted 25 February 2019  
Available online 29 August 2019

### Access this article online

#### Quick Response Code:



**Website:**  
www.e-gmit.com

**DOI:**  
10.4103/GMIT.GMIT\_80\_18

This is an open access journal, and articles are distributed under the terms of the Creative Commons Attribution-NonCommercial-ShareAlike 4.0 License, which allows others to remix, tweak, and build upon the work non-commercially, as long as appropriate credit is given and the new creations are licensed under the identical terms.

**For reprints contact:** reprints@medknow.com

**How to cite this article:** Htay WT, Huang CY, Lee CL. Sentinel pelvic lymph node dissection by natural orifices transvaginal endoscopic surgery approach after indocyanine green dye detection in early endometrial cancer of posthysterectomy patient. *Gynecol Minim Invasive Ther* 2019;8:135-7.

about 57-year-old female, P<sub>3</sub>, her body mass index was 29 kg/m<sup>2</sup>. She was menopause at 55 years of age. She was done NOTES hysterectomy and bilateral salpingo-oophorectomy for myoma uterus. However, pathological report revealed Grade 1 endometrioid adenocarcinoma. There was an incidental finding, and she was uneventful apart from it. Tumor markers were within normal limit. Computed tomography (pelvis) showed that there was no enlarged lymph node in the abdomen, pelvis, and inguinal region. No any metastasis and no ascites were found. She was planned to do ICG dye-guided sentinel pelvic lymph node dissection by NOTES approach for complete staging of endometrial cancer.

At first, ICG solution about 6 mL (the concentration: 2.5 mg/ml) was injected around the vaginal cuff (3, 6, 9, 12 o'clock position) 30 min before the operation. The video was recorded with 0° 10 mm scope equipped with a specific lens and light source emitting both visible and neon infrared light (KARL STORZ GmbH and Co. KG, Tuttlingen, Germany).

After opening the peritoneum under the pedicle of round ligament on the right side, ICG positive lymph node was identified, and dissection was done [Figure 1a and b]. After finishing the right side, the left side was performed in the same technique [Figure 2a and b]. The duration for operation was about 2 h and estimated blood loss was about 50 mL. The peritoneum was smooth without tumor seedling. ICG-positive lymph nodes were found at bilateral internal iliac and obturator areas. Pathology revealed no pelvic lymph node metastasis.

## DISCUSSION

This case was reported about ICG-guided sentinel pelvic lymph node dissection in posthysterectomy patient by NOTES approach for early endometrial cancer. Endometrial cancer is the most frequent tumor in female patients, and the prognosis depends on various factors: histological type of the tumor, the depth of invasion into the myometrium, and lymph node involvement.<sup>[4]</sup> Even in low-risk patients, up to 3%–4% of lymph node metastasis can be present.<sup>[5]</sup> Therefore, lymph

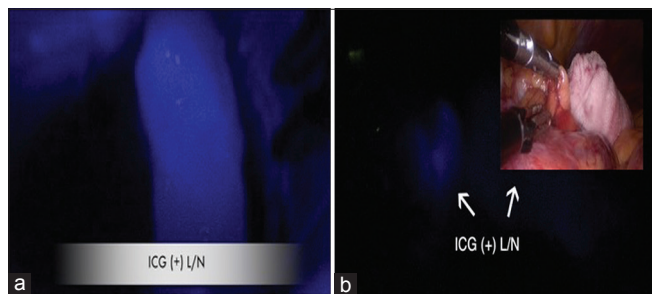
node status is considered the most important prognostic factor.

Preoperative imaging cannot also accurately assess lymph node involvement. A complete surgical staging, including lymphadenectomy is the gold standard to evaluate lymph node involvement.<sup>[4]</sup> Hence, this patient was arranged to perform lymphadenectomy for further management. However, it is important to balance risks and benefits of each surgical option to avoid both over- and under-treatment.

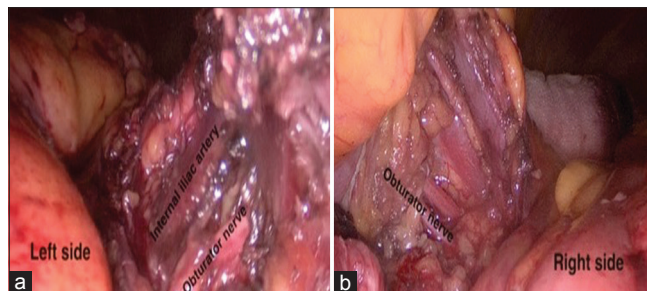
A study showed that the rate of long-term lymphedema directly attributed to lymphadenectomy was reported to be 23%.<sup>[6]</sup> To decrease the morbidity of lymphadenectomy, sentinel lymph node mapping is alternative to comprehensive lymphadenectomy. The decreasing number of removal nodes have a positive impact on the risk of lower extremity lymphedema.<sup>[7]</sup>

The essential point of the sentinel lymph node technique lies within its diagnostic accuracy. In a prospective multicenter study, patients with early-stage underwent sentinel lymph node assessment with a combination of dyes followed by pelvic-node dissection.<sup>[8]</sup> Laparoscopic ICG sentinel lymph node mapping is characterized by high overall (96%) and bilateral (88%) detection rates and low false-negative rate. Compared with full surgical staging, sentinel lymph node biopsy is associated with significantly lower estimated blood loss and shorter operation time, but no difference in intra- and postoperative complication.<sup>[2]</sup> In our case, ICG was used for sentinel lymph node mapping.

According to the sentinel lymph node mapping algorithm in 2008, the rate of complete lymphadenectomy has based on the injection site: uterine subserosal, cervical, and endometrial through hysteroscopy. Cervical ICG injection achieves a higher sentinel lymph node detection rate and a similar anatomic nodal distribution as hysteroscopic endometrial injection.<sup>[9]</sup> There is no specific research paper about the vaginal cuff as the injection site. However, our patient was done hysterectomy previously so ICG solution can only be



**Figure 1:** (a) Indocyanine green positive sentinel pelvic lymph node. (b) Indocyanine green positive and real view in pelvic lymph node



**Figure 2:** (a) After pelvic lymphadenectomy on the left side with natural orifices transvaginal endoscopic surgery approach. (b) After pelvic lymphadenectomy on the right side with natural orifices transvaginal endoscopic surgery approach

injected around the vaginal cuff (3, 6, 9, 12 o'clock position). It was performed 30 min prior to operation to be visible lymph nodes clearly.

In a few years ago, technical improvements have produced a dramatic shift from traditional open surgery toward a minimally invasive approach for the management of early endometrial cancer. In Gynecologic Oncology Group LAP2 and our study, laparoscopy provided similar result in terms of survival compared with laparotomy.<sup>[5,10]</sup>

Laparoscopic surgery is almost scar-free procedure and helps patients cope with a past cancer diagnosis.<sup>[5]</sup> NOTES staging surgery is a new, safe, and feasible minimally invasive surgery for not only benign but also endometrial cancer.<sup>[11,12]</sup> It not only overcomes the limitations but also broadens the indications of NOTES surgery to oncologic surgery.<sup>[3]</sup> In our operation, these positive evidenced methods were used together to get meticulous outcomes. Not only ICG positive but also ICG-negative lymph nodes were sent for histopathology. Pathology revealed there was no pelvic lymph node involvement. In a prospective trial of 268 endometrial carcinoma cases undergoing sentinel lymph node mapping and completing lymphadenectomy, it was noted that metastasis was found in nonsentinel lymph nodes in only 0.6% of cases.<sup>[13]</sup> Thus, it is important to tailor the extent of surgery to decrease morbidity and mortality from unnecessary procedures. In this regard, women with negative nodes have no benefit from unnecessary lymphadenectomy. Hence, our patient did not need to proceed any other procedure.

## CONCLUSION

Although this sentinel lymph node sampling with ICG technique is a new method of NOTES approach, it is a feasible and effective procedure in detecting metastases in early endometrial cancer.

## Declaration of patient consent

The authors certify that they have obtained all appropriate patient consent forms. In the form the patient(s) has/have given his/her/their consent for his/her/their images and other clinical information to be reported in the journal. The patients understand that their names and initials will not be published and due efforts will be made to conceal their identity, but anonymity cannot be guaranteed.

## Acknowledgment

The author would like to thank the Asia-Pacific Association for Gynaecologic Endoscopy and Minimally Invasive Therapy for giving Dr. Wint Thida Htay access to the International Fellowship Endoscopy Training Program at Chang Gung Memorial Hospital, Taiwan and also thanks to IRB number 201801189BOD001 for giving a chance to write it.

## Financial support and sponsorship

Nil.

## Conflicts of interest

There are no conflicts of interest.

## REFERENCES

1. Henley SJ, Miller JW, Dowling NF, Benard VB, Richardson LC. Uterine cancer incidence and mortality – United States, 1999-2016. *MMWR Morb Mortal Wkly Rep* 2018;67:1333-8.
2. Papadia A, Imboden S, Siegenthaler F, Gasparri ML, Mohr S, Lanz S, *et al.* Laparoscopic indocyanine green sentinel lymph node mapping in endometrial cancer. *Ann Surg Oncol* 2016;23:2206-11.
3. Lee CL, Wu KY, Tsao FY, Huang CY, Han CM, Yen CF, *et al.* Natural orifice transvaginal endoscopic surgery for endometrial cancer. *Gynecol Minim Invasive Ther* 2014;3:89-92.
4. Seracchioli R, Solfrini S, Mabrouk M, Facchini C, Di Donato N, Manuzzi L, *et al.* Controversies in surgical staging of endometrial cancer. *Obstet Gynecol Int* 2010;2010:181963.
5. Falcone F, Balbi G, Di Martino L, Grauso F, Salzillo ME, Messalli EM. Surgical management of early endometrial cancer: An update and proposal of a therapeutic algorithm. *Med Sci Monit* 2014;20:1298-313.
6. Lin H, Ding Z, Kota VG, Zhang X, Zhou J. Sentinel lymph node mapping in endometrial cancer: A systematic review and meta-analysis. *Oncotarget* 2017;8:46601-10.
7. Leitao MM Jr. Sentinel lymph node mapping in patients with endometrial carcinoma: Less can be more. *Curr Obstet Gynecol Rep* 2016;5:279-85.
8. Tran AQ, Gehrig P. Recent advances in endometrial cancer. *F1000Res* 2017;6:81.
9. Abu-Rustum NR. Sentinel lymph node mapping for endometrial cancer: A modern approach to surgical staging. *J Natl Compr Canc Netw* 2014;12:288-97.
10. Lee CL, Huang KG, Wu PJ, Lee PS, Yen CF. Long-term survival outcome of laparoscopic staging surgery for endometrial cancer in Taiwanese experience. *Taiwan J Obstet Gynecol* 2014;53:57-61.
11. Lee CL, Wu KY, Su H, Wu PJ, Han CM, Wang CJ, *et al.* Natural orifice transluminal endoscopic surgery in gynecology. *Gynecol Minim Invasive Ther* 2012;1:23-6.
12. Lee CL, Wu KY, Su H, Ueng SH, Yen CF. Transvaginal natural-orifice transluminal endoscopic surgery (NOTES) in adnexal procedures. *J Minim Invasive Gynecol* 2012;19:509-13.
13. Touhami O, Trinh XB, Gregoire J, Sebastianelli A, Renaud MC, Grondin K, *et al.* Predictors of non-sentinel lymph node (non-SLN) metastasis in patients with sentinel lymph node (SLN) metastasis in endometrial cancer. *Gynecol Oncol* 2015;138:41-5.