

Botulinum toxin type A for the treatment of muscle contractures secondary to acute spinal cord injury in a young cat

Journal of Feline Medicine and Surgery Open Reports
1–5

© The Author(s) 2020

Article reuse guidelines:

sagepub.com/journals-permissions

DOI: 10.1177/2055116920922648

journals.sagepub.com/home/jfmsopenreports

This paper was handled and processed by the European Editorial Office (ISFM) for publication in *JFMS Open Reports*



Robert I McGeachan , Tobias Schwarz, Daniëlle A Gunn-Moore and Katia Marioni-Henry

Abstract

Case summary A 4-month-old male entire domestic shorthair cat presented for sudden onset of right thoracic monoparesis following a fall; within 18h, the clinical signs progressed to non-ambulatory right hemiplegia with absent sensation in the distal right thoracic limb and left hemiparesis. MRI revealed changes consistent with a C6–C7 acute non-compressive nucleus pulposus extrusion with suspected secondary C5–C7 spinal cord haemorrhage. Rehabilitation exercises were started immediately after the diagnosis of acute spinal cord trauma. Sensation in the right thoracic limb improved and, with the help of a splint applied to that limb, the cat was ambulatory on all four limbs. Unfortunately, clinical signs started to progress over the course of 10 days. The cat developed progressive discomfort on manipulation of the right elbow and carpus, and a hyperflexion of the right carpus. Radiographs revealed no skeletal abnormalities. Muscle contractures were suspected. Under general anaesthesia the triceps and flexor muscles of the carpus and digits were injected with a total of 100U of botulinum toxin type A (BTX-A). No complications were associated with the procedure and 24h after the injection the carpal hyperflexion resolved.

Relevance and novel information The use of BTX-A to treat muscle contractures in human medicine is an established and increasingly used technique. For example, in subacute stroke patients with a non-functional arm, BTX-A forearm injection appears to prevent disabling finger stiffness, likely by minimising the development of contractures. Here, we demonstrate that intramuscular BTX-A is an effective treatment for acquired muscle contractures in a cat.

Keywords: Spinal cord injury; botulinum toxin; muscle contracture; Botox

Accepted: 2 April 2020

Introduction

Muscle contracture is defined as ‘the abnormal shortening of muscle tissue, rendering the muscle highly resistant to stretching’.¹ Muscle contracture occurs as a result of muscle fibrosis, often the result of injury. In veterinary patients, acquired muscle contracture most commonly develops secondary to a traumatic event.² Other causes of muscle contracture include, but are not limited to, compartment syndrome, infection, immune-mediated disease, circulatory insufficiency, eosinophilic myositis and myositis ossificans.³ Theoretically, any muscle can become affected, but canine and feline muscle contracture most commonly affects the quadriceps and infraspinatus. Less commonly affected muscles include the supraspinatus, teres minor, sartorius, gracilis and

semitendinosus.⁴ Contracture can cause permanent disability and is often associated with pain and lameness.

Treatment options and prognosis depend on the severity of the contracture and the muscle(s) affected. Conservative management involving physiotherapy and splinting can be effective in mild cases. However, severe cases of muscle contracture often require

Royal (Dick) School of Veterinary Studies and Roslin Institute, The University of Edinburgh, Hospital for Small Animals, Roslin, UK

Corresponding author:

Robert I McGeachan BVM&S, MScR, AFHEA, MRCVS, Royal (Dick) School of Veterinary Studies and Roslin Institute, The University of Edinburgh, Easter Bush, Roslin, Midlothian EH25 9RG, UK
Email: rmcgeach@ed.ac.uk



Creative Commons Non Commercial CC BY-NC: This article is distributed under the terms of the Creative Commons

Attribution-NonCommercial 4.0 License (<https://creativecommons.org/licenses/by-nc/4.0/>) which permits non-commercial use, reproduction and distribution of the work without further permission provided the original work is attributed as specified on the SAGE and Open Access pages (<https://us.sagepub.com/en-us/nam/open-access-at-sage>).

treatments with a higher degree of morbidity and/or recurrence, such as tenectomy, myectomy, arthrodesis and amputation.⁴ There is therefore a demand for lower-risk treatments for severe muscle contracture in veterinary patients.

Clostridium botulinum produces seven serotypes of the neurotoxin: botulinum toxin (BTX) type A–G. These toxins inhibit acetylcholine exocytosis at the synaptic cleft in cholinergic nerve terminals preventing muscle contraction.⁵ However, there are some variations in their potency, duration of action and intracellular protein targets. BTX-A reduces muscular activity in a dose-dependent manner, making it safe and predictable for therapeutic use.^{6,7}

In this case report we describe the first successful use of intramuscular BTX-A to treat severe muscle contractures in a cat, where the alternative treatment option was amputation.

Case description

A 4-month-old male entire indoor-only domestic shorthair cat was referred to the Royal (Dick) School of Veterinary Studies' Neurology Service for acute onset of right thoracic monoparesis following a fall from a chair. Clinical signs progressed rapidly and within 18h the cat was unable to walk, with right hemiplegia, left hemiparesis and right Horner's syndrome. At this stage the patient was referred.

On presentation the cat was quiet, alert and responsive; vitals were within normal limits; and a large, firm bladder was evident on abdominal palpation. Neurological examination revealed anisocoria with a miotic right pupil, cervical hyperaesthesia, right hemiplegia, left hemiparesis, thoracic limb hypotonia, pelvic limb hypertonia, right thoracic limb areflexia, absent deep pain in the right thoracic limb below the elbow and pelvic limb hyperreflexia. Neurolocalisation was to the C6–T2 spinal segments, with lateralisation to the right. Differential diagnoses were trauma, vascular event and infectious/inflammatory disease (feline infectious peritonitis/toxoplasmosis).

An emergency CT scan (64-row multi-slice CT scanner; Somatom Definition AS) of the head and spine was performed shortly after admission; no structural abnormalities were identified to explain the clinical signs. Serum biochemistry and haematology identified no significant findings. An echocardiogram revealed trivial tricuspid regurgitation, no left atrial enlargement, no thrombus formation and good contractility. Activated partial thromboplastin time (APTT) and prothrombin time (PT) were within their respective reference intervals (RIs), and serum fibrinogen concentration was not increased: APTT 13.4 s (RI 10–20s); PT 10.2 s (RI 5–12 s); and fibrinogen 3.2 g/l (RI 2–4 g/l). Testing for serum feline leukaemia virus antigen and feline

immunodeficiency virus antibody was negative (SNAP FIV/FeLV Combo Test; IDEXX). Serum IgG and IgM antibody titre testing for *Toxoplasma gondii* was negative (<50 [Biobest Laboratories, Edinburgh]). Serum analysis for feline coronavirus antibody titre by immunofluorescence assay (<10) and alpha1-acid glycoprotein by radial immunodiffusion assay (0.5 g/l; RI 0.124–0.878 g/l) were both negative (Biobest Laboratories). Analysis of the cerebrospinal fluid (CSF) showed a total cell count of 39.6/ μ l (RI <5/ μ l) and a total protein concentration of 1.28 g/l (RI <0.45 g/l). Cytology of the CSF fluid revealed increased red blood cells (RBCs) and scattered platelets. The nucleated cells were approximately 8/1000 RBCs and they comprised 30% non-degenerate neutrophils, 46% small and a few medium lymphocytes, 23% large mononuclear cells (monocytes and macrophages) and 1% eosinophils. One macrophage showed erythrophagocytosis; otherwise, cell morphology was unremarkable. No aetiological agents were seen. These findings were consistent with either local haemorrhage or blood contamination.

Based on history, neurological examination and investigations, a presumptive diagnosis of spinal cord trauma was made. Daily physiotherapy was initiated included passive range of motion (PROM) exercises. The patient was managed symptomatically with buprenorphine (20 μ g/kg IV q8h), dexamethasone (0.1 mg/kg IV q24h, increased to 0.2 mg/kg on result of negative *T gondii*), clindamycin (25 mg/kg PO q8h, withdrawn on result of negative toxoplasma), ranitidine (2 mg/kg IV q12h) and prazosin (250 μ g/kg PO q8h) to aid frequent bladder expressions. Lactulose and enemas containing sodium citrate (450 mg) and sodium alkylsulfoacetate (45 mg [Miralax; RPH Pharmaceuticals]) were used to manage faecal retention.

Seven days after the initial trauma the patient failed to show significant signs of improvement and appeared to have persistent cervical hyperaesthesia, despite analgesia and physiotherapy. Pre- and post-contrast MRI (3Philips Intera 1.5-T Pulsar System; Philips Medical Systems) study of the cervical and thoracic spine and brain was performed. All visible intervertebral discs showed normal T2 fluid intensity (Figure 1a). At C6–C7 the intervertebral disc was protruding into the mid-ventral vertebral canal, causing thinning of the subarachnoid space circumferentially and mild dorsal cord deviation (Figure 1b,c). Extending from C5–C6 to cranial C7, the spinal cord contained a large area of T1, T2 and T2* hyperintensity, with only the left dorsolateral aspect of the cord unaffected. In the same area, there was marked contrast enhancement of the right lateral aspect of the spinal cord (Figure 1d). MRI findings were therefore consistent with a C6–C7 acute non-compressive nucleus pulposus extrusion with secondary C5–C7 spinal cord chronic haemorrhage. The contrast enhancement was considered to be most likely due to vascular

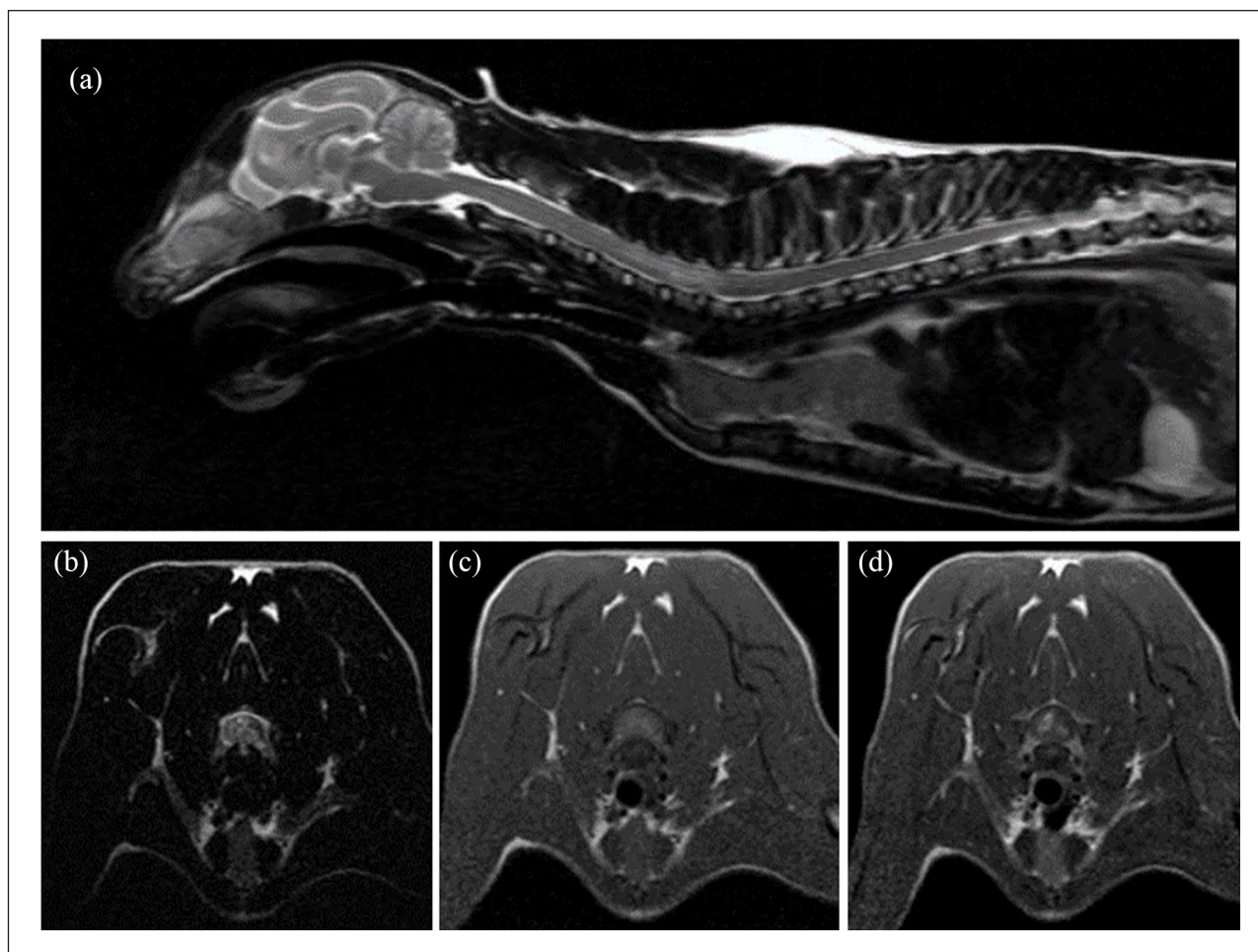


Figure 1 MRI study of the cervical spine. (a) T2-weighted (T2W) sagittal image demonstrates that all visible intervertebral discs have normal T2 fluid intensity and a T2 hyperintensity extending from C5–C6 to cranial C7. (b) T2W and (c) T1-weighted (T1W) transverse images demonstrate the C6–C7 intervertebral disc protruding into the mid-ventral vertebral canal, causing thinning of the subarachnoid space circumferentially and mild dorsal spinal cord deviation. (d) T1W transverse image post-contrast demonstrates marked contrast enhancement of the right lateral aspect of the spinal cord in the area of T2 hyperintensity

damage, inflammation secondary to the trauma and chronic haemorrhage. CSF analysis was repeated 7 days post-trauma and was consistent with normal CSF: total cell count 0 (RI $<5/\mu\text{l}$) and total protein concentration 0.35 g/l (RI <0.45 g/l), suggesting resolution of the previously suspected subarachnoid haemorrhage.

Following MRI, a splint was applied to the right thoracic limb to prevent knuckling and abrasion of the dorsal paw, and to assist ambulation. By 10 days post-trauma the anisocoria, cervical hyperaesthesia, left-sided paresis and postural deficits, pelvic limb hypertonus, and faecal and urinary retention had resolved. The kitten was able to run, jump and climb. However, the distal right thoracic limb was still paralysed, and over the preceding 10 days progressive contracture of the right carpus developed. PROM exercises elicited pain on extension of the carpus and flexion of the elbow, preventing the physiotherapy from being performed effectively. Splints were trialled, but they also

elicited discomfort. Radiographs of the thoracic limbs were taken. No soft tissue abnormalities were detected. An 18° lateral deviation of the right carpus was evident, causing narrowing of the radiocarpal joint space affecting primarily the intermedioradial carpal bone. This was consistent with suspected contracture of the triceps and flexor muscles of the carpus and digits.

The contracture resulted in the development of a non-weightbearing carpal hyperflexion (Figure 2). Amputation of the limb or a therapeutic trial with BTX were discussed; the owners elected for the latter. Under general anaesthesia, 90 units of BTX type A (BTX-A [Botox Cosmetic; Allergan]) were injected into the flexor muscles of carpus and digits, and 10 units into the triceps. The dose was similar to what has previously been shown to be safe in cats in an experimental study.⁸ The aim of the treatment was to alleviate discomfort and reduce the muscle spasticity, allowing the use of a brace and physiotherapy to be performed.

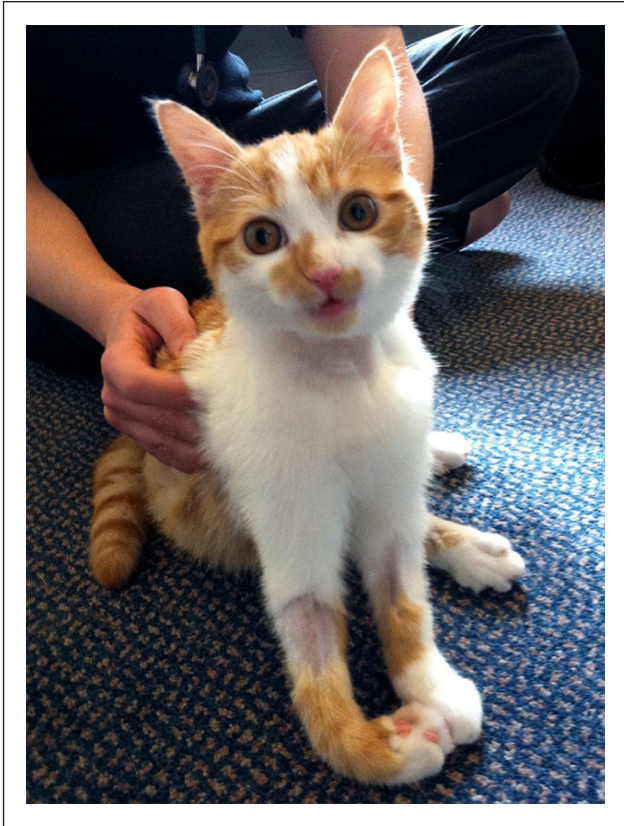


Figure 2 Photograph demonstrating non-weightbearing carpal hyperflexion, secondary to severe muscle contracture

The patient was monitored in hospital for 48 h after the treatment; there were no adverse clinical reactions. The cat was discharged with a splint to aid ambulation; the owners were instructed to change the splint daily and perform daily physiotherapy.

At a re-check 8 days post-BTX-A treatment the owners perceived the cat to be pain-free and ambulating well with support from the splint. The owners were managing well with the daily splint changes and rehabilitation exercises, although they reported that the cat resented the removal of the tape that kept the splint in place. Examination showed erythema where the tape was applied. The tape was replaced with a custom-made brace made with a spoon splint and Velcro straps. Repeat neurological examination showed that in the right thoracic limb postural reactions were still absent, sensation was decreased but now present at the second and fifth digit, and the muscle contractions had resolved but muscle tone was decreased. The postural reactions and tone in the other limbs were now normal. Mild hyperaesthesia of the cervical, epaxial and shoulder muscles was present, but there was a greatly improved level of comfort on manipulation of neck, right shoulder, elbow and carpus vs before BTX-A treatment. The owners reported that the cat was very active; we suspected that the neck and shoulder muscles were subjected to an increased

load secondary to the reduced tone and function of the injected muscles of the right thoracic limb.

The cat continued to make a clinical improvement. At 6 months post-BTX-A treatment, sensation was present but still decreased on the distal right thoracic limb. The right triceps brachii muscle was atrophied and a mild increase in muscle tone had returned. However, normal mobility was not impeded and the cat was pain free and able to place its right thoracic paw in a normal position when ambulating, only requiring support from the splint after prolonged periods of exercise (see the video in the supplementary material). The residual clinical signs did not appear to be affecting its quality of life.

Discussion

The first published report documenting the therapeutic use of BTX-A was in 1981, to treat strabismus in human patients.⁹ Since then, the use of BTX-A as a therapeutic agent in human medicine has grown dramatically and has been shown to successfully treat a range of diseases. Most relevant to this case report, BTX-A is now a relatively well-established technique to treat spasticity and contracture in human medicine. For example, in subacute human stroke patients, early intramuscular BTX-A injection has been shown to prevent the development of disabling finger flexor stiffness over a 6-month period, most likely by attenuating the development of muscle contractures.¹⁰ Furthermore, in children with cerebral palsy, BTX-A injections into spastic or dystonic muscles have been shown to reduce pain and deformity and decrease the need for surgical intervention.¹¹

The therapeutic use of BTX-A in veterinary medicine is less well documented, with limited literature. A randomised, double-blind, placebo-controlled clinical trial by Heikkilä et al demonstrated that intra-articular injection of BTX-A may reduce pain in dogs with chronic osteoarthritis.¹² However, these results were unrepeatable in a recent and similarly designed study.¹³ Injection of BTX-A into the muscularis layer of the pylorus has been shown to improve gastric emptying in a Toy Australian Shepherd dog with a functional pyloric outflow obstruction that was refractory to prokinetic therapy.¹⁴ Furthermore, radiation therapy-induced myokymia and neuromyotonia in a Maltese was well controlled with BTX-A injections into the affected muscles.¹⁵ Most comparable to this case report, Bright et al describe a case where an 11-week-old domestic shorthair cat presented with tarsal arthrogryposis and 20 U of BTX-A was injected into the gastrocnemius.¹⁶ However, 14 days later there was minimal improvement in range of motion ($\sim 5^\circ$) and partial tarsal arthrodesis and calcaneal tendon lengthening was subsequently performed. Two factors may have contributed to the failure of treatment in this previous case report. First, a lower dose of BTX-A was used when compared with this current case (20 U vs

100 U). Second, this was a congenital contracture in contrast to an acquired contracture and therefore the pathology contributing to the contracture would likely be more permanent. To our knowledge, this case report describes the first successful use of BTX-A to treat muscle contracture in the veterinary literature.

The success of BTX-A treatment in human patients is dependent on the adjunctive use of regular physiotherapy and splinting or casting.¹⁷ Assuming that the same would be true for veterinary patients, case selection is important as a significant investment of time and money is required from the owner. The only complication following treatment in the current case was erythema and discomfort caused by the tape that held the splint in place, which quickly resolved following the replacement of the tape with Velcro straps.

Conclusions

Here we demonstrate, for the first time, that intramuscular BTX-A is an effective and safe treatment for acquired muscle contractures in a juvenile cat. The goal of BTX-A treatment should be to maintain a pain-free and functional limb, and where that fails, surgical intervention would likely be the treatment of choice. Based on the results of this case report, and the established and growing use in human medicine, we believe that the use of BTX-A to treat muscle contracture in the veterinary field warrants further investigations.

Acknowledgements We would like to thank all of the nurses who assisted with the management of this case and performed physiotherapy sessions during the recovery period.

Conflict of interest The authors declared no potential conflicts of interest with respect to the research, authorship, and/or publication of this article.

Funding The authors received no financial support for the research, authorship, and/or publication of this article.

Ethical approval This work involved the use of non-experimental animals only (including owned or unowned animals and data from prospective or retrospective studies). Established internationally recognised high standards ('best practice') of individual veterinary clinical patient care were followed. Ethical approval from a committee was therefore not necessarily required.

Informed consent Informed consent (either verbal or written) was obtained from the owner or legal custodian of all animal(s) described in this work for the procedure(s) undertaken. For any animals or humans individually identifiable within this publication, informed consent (either verbal or written) for their use in the publication was obtained from the people involved.

Supplemental material

The following file is available online: Video demonstrating that the cat is ambulatory, without the splint, 6 months post BTX-A injection.

ORCID ID Robert I McGeachan  <https://orcid.org/0000-0003-1647-8642>

References

- 1 Studdert VP, Gay CC, Blood DC, et al. Saunders comprehensive veterinary dictionary. St Louis, MO: Saunders Elsevier, 2012.
- 2 Canapp SO and Saunders DG. **Common conditions and physical rehabilitation of the athletic patient.** In: Mills D and Levine D (eds). Canine rehabilitation and physical therapy. 2nd ed. St Louis, MO: Elsevier, 2013, pp 582–608.
- 3 Leighton RL. **Muscle contractures in the limbs of dogs and cats.** *Vet Surg* 1981; 10: 132–135.
- 4 Taylor J and Tangner CH. **Acquired muscle contractures in the dog and cat. A review of the literature and case report.** *Vet Comp Orthop Traumatol* 2007; 20: 79–85.
- 5 Dressler D, Adib Saheri F and Reis Barbosa E. **Botulinum toxin: mechanisms of action.** *Arq Neuropsiquiatr* 2005; 63: 180–185.
- 6 Moreno-López B, Pastor AM, De La Cruz RR, et al. **Dose-dependent, central effects of botulinum neurotoxin type A: a pilot study in the alert behaving cat.** *Neurology* 1997; 48: 456–464.
- 7 Aoki KR and Guyer B. **Botulinum toxin type A and other botulinum toxin serotypes: a comparative review of biochemical and pharmacological actions.** *Eur J Neurol* 2001; 8: 21–29.
- 8 Misiaszek JE and Pearson KG. **Adaptive changes in locomotor activity following botulinum toxin injection in ankle extensor muscles of cats.** *J Neurophysiol* 2002; 87: 229–239.
- 9 Scott AB. **Botulinum toxin injection of eye muscles to correct strabismus.** *Trans Am Ophthalmol Soc* 1981; 79: 734–770.
- 10 Hesse S, MacH H, Fröhlich S, et al. **An early botulinum toxin a treatment in subacute stroke patients may prevent a disabling finger flexor stiffness six months later: a randomized controlled trial.** *Clin Rehabil* 2012; 26: 237–245.
- 11 Pavone V, Testa G, Restivo DA, et al. **Botulinum toxin treatment for limb spasticity in childhood cerebral palsy.** *Front Pharmacol* 2016; 7. DOI: 10.3389/fphar.2016.00029.
- 12 Heikkilä HM, Hielm-Björkman AK, Morelius M, et al. **Intra-articular botulinum toxin A for the treatment of osteoarthritic joint pain in dogs: a randomized, double-blinded, placebo-controlled clinical trial.** *Vet J* 2014; 200: 162–169.
- 13 Nicácio GM, Luna SPL, Cavaleti P, et al. **Intra-articular botulinum toxin A (BoNT/A) for pain management in dogs with osteoarthritis secondary to hip dysplasia: a randomized controlled clinical trial.** *J Vet Med Sci* 2019; 81: 411–417.
- 14 Rinaldi ML, Fransson BA and Barry SL. **Botulinum toxin A as a treatment for delayed gastric emptying in a dog.** *Can Vet J* 2014; 55: 673–677.
- 15 Rogatko CP, Glass EN, Kent M, et al. **Use of botulinum toxin type a for the treatment of radiation therapy-induced myokymia and neuromyotonia in a dog.** *J Am Vet Med Assoc* 2016; 248: 532–537.
- 16 Bright SR, Girling SL, O'Neill T, et al. **Partial tarsal arthrodesis and botulinum toxin A injection for correction of tarsal arthrogyrosis in a cat.** *J Small Anim Pract* 2007; 48: 39–42.
- 17 Ramachandran M and Eastwood DM. **Botulinum toxin and its orthopaedic applications.** *J Bone Joint Surg* 2006; 88: 981–987.