

COVID-19 presenting as persistent hiccups: a case report

Diogo Ribeiro de Sene¹, Diego Moreno Watashi², Isabella de Oliveira Bilitardo¹, Carlos Eduardo Campos Moreno², Mariella Freire de Freitas Moreno³

ABSTRACT

Hiccups are involuntary, spasmodic contractions of the diaphragm and intercostal muscles and can be classified as acute (< 48 h), persistent (48 h to a month) or intractable (> 1 month). A previously healthy 29-year-old man sought the Emergency Department with flu-like symptoms and a two-day history of persistent hiccups. His physical examination was otherwise unremarkable and vital signs were within normal limits. An unenhanced computed tomography scan of the chest showed small focal ground-glass opacities scattered throughout 25% of the lungs. A COVID-19 test was positive. Chlorpromazine was prescribed for the hiccups with improvement over 10 h. The patient was discharged home on the same day without hiccups and no other complications.

KEYWORDS: COVID-19. Hiccups. SARS-CoV-2. Chlorpromazine. Atypical presentation.

INTRODUCTION

Hiccups are diaphragmatic and intercostal muscle contractions with early glottis closure terminating the inspiration. They are involuntary and spasmodic, and are controlled by a complex reflex arc between peripheral receptors and the brainstem. Any disruption along this pathway may produce hiccups. Hiccups can be classified as acute (< 48 h), persistent (48 h to a month) or intractable (> 1 month). Most acute hiccups are transient, benign and self-limited. However, persistent and intractable hiccups may be considered a sign of underlying pathology and although the most common cause is gastroesophageal reflux disease (GERD), atypical causes as COVID-19 are now identified in rare reports in the literature^{1,2}.

CASE REPORT

A 29-year old man sought the Emergency Department complaining of hiccups in the last 2 days. The patient reported one febrile episode of 37.8 °C which improved after the use of acetaminophen, and a 3-day history of cough, rhinorrhea and mild shortness of breathe. Upon admission, he denied feeling tightness in his chest or a sore throat. The patient had no previous history of chronic diseases or allergies and denied abuse of alcohol, other drugs and was not a smoker. His blood pressure was 132/74 cmHg, the respiratory rate was 20 breaths/min, his heart rate was 73 beats/min and regular, the body temperature was 36.4 °C and the oxygen saturation was 94% in room air. There were bilateral scattered crackles during the auscultation of the lungs and no signs of respiratory insufficiency. The head and the neurological examination were normal. Routine blood test results were as

¹Hospital Doutor Arnaldo Pezzuti Cavalcanti, Departamento de Medicina Intensiva, Mogi das Cruzes, São Paulo, Brazil

²Universidade de Mogi das Cruzes, Mogi das Cruzes, São Paulo, Brazil

³Universidade Estadual de Londrina, Londrina, Paraná, Brazil

Correspondence to: Diego Moreno Watashi
Universidade de Mogi das Cruzes, Av. Dr. Cândido Xavier de Almeida e Souza, 200, CEP 08780-911, Mogi das Cruzes, SP, Brazil
Tel: +55 11 98414-3888

E-mail: diegowatashi@hotmail.com

Received: 30 June 2021

Accepted: 12 July 2021

follows: red blood cells 4.74×10^6 cells/uL; white blood cells 7.75×10^3 cells/uL; neutrophils 81.2%; lymphocytes 13.4%; total number of lymphocytes 1.039×10^3 cells/uL; platelets 194×10^3 cells/uL; C-reactive protein (CRP) 32 mg/L; potassium 4.2 mEq/L; sodium 137 mEq/L; BUN 15.4 mg/dL; serum creatinine (Cr) 1.04 mg/dL; D-dimer 142 ng/mL; lactate dehydrogenase (LDH) 179 U/L; ferritin 245 ng/mL; troponin 1.4 pg/mL. His arterial blood gas analysis was as follows: pH 7.41; $p\text{CO}_2$ 36 mmHg; $p\text{O}_2$ 83 mmHg; Oxygen saturation 96%; HCO_3^- 22.8 mEq/L; Base excess -2.1 mEq/L.

The chest computed tomography (CT) was performed and small subpleural ground-glass opacities, as well as small sparse areas of atelectasis were observed scattered across the two lungs and affecting less than 25% of lung parenchyma, suggesting the presence of a viral pneumonia (Figure 1). A real-time reverse transcription-polymerase chain reaction (RT-PCR) analysis of the patient's throat swab sample confirmed the SARS-Cov-2 infection. The Valsalva maneuver used in an attempt to stop the hiccups was unsuccessful. As the patient did not meet the Centers for Disease Control and Prevention (CDC) established criteria for COVID-19 severe illness, he was discharged home with symptomatic medication³. The patient was followed-up by phone for 10 days and treated with chlorpromazine for the resistant hiccups, which disappeared 10 h after starting treatment. The chlorpromazine treatment was continued for three days, for a total of five days, and there was no relapse after treatment discontinuation.

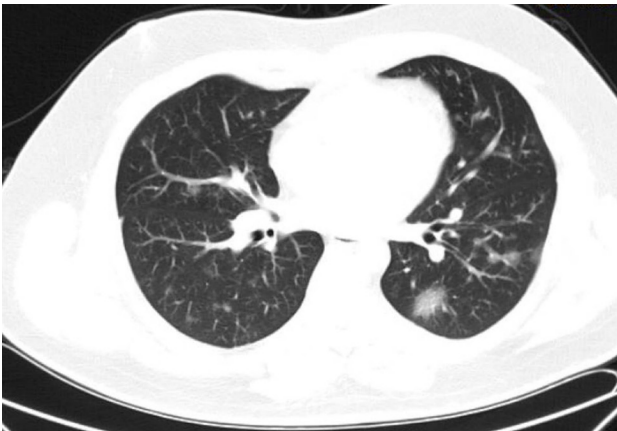


Figure 1 - A chest computed tomography scan showing peripheral ground-glass opacities in lungs.

DISCUSSION

Since the first COVID-19 report, clinical manifestations were described in most cases as fever, nonproductive cough, dyspnea, myalgia, fatigue, normal or decreased leukocyte

count, in addition to radiographic evidence of pneumonia in the chest CT scan.

The severe presentation of COVID-19 included organ dysfunction, clinically presenting as shock, acute respiratory distress syndrome (ARDS), acute cardiac injury, acute kidney injury and death⁴. However, with the growing COVID-19 data around the world, different presentations have been reported, highlighting the clinical heterogeneity of this disease. This case reports a patient with an atypical presentation: persistent hiccups⁵.

The correlation between COVID-19 and hiccups still remains unclear, but other infectious conditions such as influenza, herpes zoster, neurosyphilis and tuberculosis have been related to hiccups^{6,7}.

The severity and treatment of hiccups depend on their temporal classification. Acute hiccups are usually benign and self-limited, not requiring intervention or etiological investigation in the majority of cases. However, patients whose hiccups interfere with their quality of life may attempt physical maneuvers to relieve their symptoms. These maneuvers are harmless to the patient and they work by increasing the vagal stimulus, interrupting the normal respiratory rhythm and the nasopharynx stimulus. There are several methods: breath holding, Valsalva's maneuver, eyeball compression, drinking cold water, pulling out the tongue, among others^{6,8}.

Persistent hiccups usually interfere with the patient's daily activities and they often hide a pathological etiology, therefore the underlying cause should be investigated. Some common causes are gastroesophageal reflux (GERD), malignancies, myocardial infarction, cerebrovascular diseases, medications, toxic metabolites, infectious agents, among others. Physical maneuvers may be initially attempted in order to relieve the symptoms, but in contrast to acute hiccups, persistent and intractable hiccups are less likely to be terminated by physical therapy.

The treatment should always be focused on the underlying cause, but an empiric treatment can be used while the etiology is under investigation. The first empiric option should be a proton pump inhibitor, as the most common cause of persistent hiccups is GERD. In the absence of symptoms improvement or the diagnosis of a serious etiology, a wide variety of medications can be used. The most common options are baclofen, gabapentin, metoclopramide and chlorpromazine⁶. In our case, chlorpromazine was used as the first option due to the drug availability. Similar case reports of COVID-19 associated with hiccups are presented in Table 1. Briefly, including the case reported here, there are 10 cases of COVID-19 (confirmed by RT-PCR) associated with hiccups in the literature, all of them in male patients aged 29-68 years,

Table 1 - Similar case reports of COVID-19 associated with hiccups.

	Gender and age of the patient (years)	Presentation	Laboratory tests and imaging	Treatment	Outcome
Our case	Male 29	Persistent hiccups Two-day history	Chest CT scan with ground-glass opacities and small sparse areas of atelectasis Positive RT-PCR for SARS-CoV-2	Chlorpromazine	Symptoms improved after 10 h
Dorgalaleh <i>et al.</i> ⁹	Male 52	Persistent hiccups	Chest CT scan with ground-glass in the left lower lobe Positive RT-PCR for SARS-CoV-2	Metoclopramide Chlorpromazine	Symptoms improved after 5 days
Ikitimur <i>et al.</i> ¹⁰	Male 60	Persistent hiccups Three-day history	Chest CT scan with ground-glass in the left lower lobe Positive RT-PCR for SARS-CoV-2	Chlorpromazine	Symptoms improved after 12 h
	Male 68	Persistent hiccups	Chest CT scan with ground-glass in the left lower lobe Positive RT-PCR for SARS-CoV-2	Chlorpromazine	Symptoms improved after 3 days
Prince and Serge ⁵	Male 62	Persistent hiccups Four-day history	Chest CT scan with ground-glass opacities Positive RT-PCR for SARS-CoV-2	None	Symptoms improved
Bakheet <i>et al.</i> ¹¹	Male 48	Persistent hiccups Seven-day history	Chest CT scan with ground-glass opacities Positive RT-PCR for SARS-CoV-2	Baclofen	Symptoms improved
Alvarez-Cisneros <i>et al.</i> ¹²	Male 48	Persistent hiccups Four-day history	Chest CT scan with ground-glass opacities Positive RT-PCR for SARS-CoV-2	Metoclopramide, omeprazol, ondansetron and oral frappe megaldrate/dimeticone	No improvement Patient refused hospital admission and was lost to follow-up
Totomoch-Serra <i>et al.</i> ¹³	Male 60	Persistent hiccups	Chest X-ray showing lung parenchyma with decreased radiolucency of images with poorly defined irregular edges	Clonazepam Haloperidol	Symptoms improved after 3 days
Sangamesh <i>et al.</i> ¹⁴	Male 72	Persistent hiccups Five-day history	Chest X-ray with bilateral lower lobe infiltrates Positive RT-PCR for SARS-CoV-2	Baclofen	Symptoms improved after 2 days
Atiyat <i>et al.</i> ¹⁵	Male 61	Persistent hiccups Two-day history	Chest X-ray with bilateral middle lung opacities Positive RT-PCR for SARS-CoV-2	Metoclopramide	-
Chiquete <i>et al.</i> ¹⁶	Male 62	Persistent hiccups Five-day history	Chest CT scan with viral pneumonia Positive RT-PCR for SARS-CoV-2	Levomopromazine Levosulpiride	Symptoms improved after 3 days

RT-PCR = real-time reverse transcription-polymerase chain reaction

with abnormal chest CT scan or chest X-rays of the lungs, all patients but one received medications to stop the hiccups, and according to the follow-up description, eight patients evolved with improvement of symptoms, including ours, one case was lost to follow-up, and in one case data were not available in the medical record.

CONCLUSION

During the COVID-19 pandemic, health care workers must maintain a high clinical suspicion of COVID-19 examining patients with atypical presentations of this disease, such as persistent hiccups.

REFERENCES

1. Woelk CJ. Managing hiccups. *Can Fam Physician*. 2011;57:672-5,e198-201.
2. Reichenbach ZW, Piech GM, Malik Z. Chronic hiccups. *Curr Treat Options Gastroenterol*. 2020 In Press.
3. Centers for Disease Control and Prevention. Interim clinical guidance for management of patients with confirmed Coronavirus disease (COVID-19). [cited 2021 Jul 12]. Available from: <https://www.cdc.gov/coronavirus/2019-ncov/hcp/clinical-guidance-management-patients.html>
4. Huang C, Wang Y, Li X, Ren L, Zhao J, Hu Y, et al. Clinical features of patients infected with 2019 novel coronavirus in Wuhan, China. *Lancet*. 2020;395:497-506.
5. Prince G, Sergel M. Persistent hiccups as an atypical presenting complaint of COVID-19. *Am J Emerg Med*. 2020;38:1546.e5-6.
6. Jeon YS, Kearney AM, Baker PG. Management of hiccups in palliative care patients. *BMJ Support Palliat Care*. 2018;8:1-6.
7. Cole JA, Plewa MC. Singultus. *Treasure Island: StatPearls*; 2021.
8. Steger M, Schneemann M, Fox M. Systemic review: the pathogenesis and pharmacological treatment of hiccups. *Aliment Pharmacol Ther*. 2015;42:1037-50.
9. Dorgalaleh A, Dabbagh A, Tabibian S, Bahraini M, Rafieemehr H. Persistent hiccups in a patient with mild congenital factor V deficiency and COVID-19; clinical and laboratory finding of a rare bleeding disorder. *Int J Lab Hematol*. 2021;43:e87-8.
10. Ikitimur H, Borku Uysal B, Ikitimur B, Umihanic S, Smajic J, Jahic R, et al. Two cases of persistent hiccups complicating COVID-19. *Am J Trop Med Hyg*. 2021;104:1713-5.
11. Bakheet N, Fouad R, Kassem AM, Hussin W, El-Shazly M. Persistent hiccup: a rare presentation of COVID-19. *Respir Investig*. 2021;59:263-5.
12. Alvarez-Cisneros T, Lara-Reyes A, Sansón-Tinoco S. Hiccups and psychosis: two atypical presentations of COVID-19. *Int J Emerg Med*. 2021;14:8.
13. Totomoch-Serra A, Ibarra-Miramón CB, Manterola C. Persistent hiccups as main COVID-19 symptom. *Am J Med Sci*. 2021;361:799-800.
14. Sangamesh S, Gosavi S, Shastry S, Johny SM. Hiccups and hyponatremia: unusual co-presentation in COVID-19. *J Family Med Prim Care*. 2021;10:1040-3.
15. Atiyat R, Veeraballi S, Al-Atiyat N, Chan KH, Slim J. A rare case report of persistent hiccups as an atypical presentation of COVID-19. *Cureus*. 2021;13:e13625.
16. Chiquete E, Toapanta-Yanchapaxi L, Aceves-Buendía JJ, Ruiz-Ruiz E, Rodríguez-Perea E, Durán-Coyote S, et al. Levosulpiride relieved persistent hiccups in a patient With COVID-19 and vascular cognitive impairment. *Clin Neuropharmacol*. 2021 In Press.