

Available online at www.sciencedirect.com

ScienceDirect

journal homepage: www.elsevier.com/locate/radcr

Case Report

Creation of a neoinfundibulum and serial balloon dilations for the treatment of the excluded calyx: Two cases describing a novel technique

Prajna Chopra, MD^{a,b,*}, Curtis H. Cleveland, MD^a, Mark Johnson, MD^a, Hans Michell, MD^{a,b}, Peter Holoch, MD^a, Brian Irwin, MD^a, Geoffrey M. Scriver, MD^{a,b}, Christopher S. Morris, MD^{a,b}

^a University of Vermont College of Medicine, Burlington, VT, USA

^b Interventional Radiology, Department of Radiology, University of Vermont Medical Center, 111 Colchester Ave., Burlington, VT 05401, USA

ARTICLE INFO

Article history:

Received 13 April 2020

Revised 15 April 2020

Accepted 15 April 2020

Keywords:

Excluded calyx

Sharp recanalization

PowerWire recanalization

Hydrocalyx

Minimally invasive

ABSTRACT

An excluded calyx is a rare, acquired urologic condition where there is discontinuity between a portion of the renal collecting system with the remainder of the collecting system. Re-establishment of reliable long-term communication between the excluded calyx and the remaining collecting system is crucial for preservation of renal function and possible relief of symptoms. In this manuscript, we discuss two such cases where a previously undescribed novel procedure is used for treatment of this uncommon condition, where percutaneous antegrade transcatheter techniques were used to establish long-term urinary drainage. The first case discusses an excluded calyx in a 17-year-old male who suffered left renal injury after a high speed motor vehicle accident, where the kidney was divided by the injury and subsequently required creation of a neoinfundibulum in order to maintain continuity of the collecting system. The second case involves a 39-year-old female who underwent resection of a renal cell carcinoma, later developing an excluded calyx where radiofrequency wire recanalization was performed and the neoinfundibular track underwent serial retrograde balloon dilation, resulting in a continuous collecting system. Both patients have done well for more than 2 years after neoinfundibulum creation, showing that this novel technique should be considered a viable and safe procedure in the treatment of this rare condition.

© 2020 The Authors. Published by Elsevier Inc. on behalf of University of Washington.

This is an open access article under the CC BY-NC-ND license.

(<http://creativecommons.org/licenses/by-nc-nd/4.0/>)

* Corresponding author.

E-mail addresses: prajna.chopra@uvmhealth.org (P. Chopra), curtis.cleveland@uvmhealth.org (C.H. Cleveland), barnettjohnson@mac.com (M. Johnson), hans.michell@uvmhealth.org (H. Michell), peter.holoch@uvmhealth.org (P. Holoch), brian.irwin@uvmhealth.org (B. Irwin), geoffrey.scriver@uvmhealth.org (G.M. Scriver), christopher.morris@uvmhealth.org (C.S. Morris).

<https://doi.org/10.1016/j.radcr.2020.04.038>

1930-0433/© 2020 The Authors. Published by Elsevier Inc. on behalf of University of Washington. This is an open access article under the CC BY-NC-ND license. (<http://creativecommons.org/licenses/by-nc-nd/4.0/>)

Introduction

An excluded calyx is an acquired, rare urologic diagnosis where a functional portion of the renal collecting system has lost continuity with the remainder of the collecting system [1–3]. Multiple potential etiologies exist for this condition—including infection, trauma, urinary tract calculi, malignancy, and iatrogenic causes [1,4]. A hydrocalyx is similar, can be congenital or acquired, and includes a narrowed infundibulum that maintains continuity to the collecting system [3]. Both conditions can present with pain, recurrent urinary tract infections, or hematuria and could reflect a continuum where a stenotic infundibulum obstructs over time [1,3,4]. Calyceal diverticula, another congenital pathology, can present similarly when symptomatic, but do not have functional capacity [2]. The diagnosis of an excluded calyx, hydrocalyx or calyceal diverticula can be made with cross sectional imaging but is more accurately made with antegrade or retrograde pyelography [1]. Treatment for these 3 conditions has evolved from comparable open surgical procedures to more minimally invasive techniques, given their similarities [1–5].

Establishment of long term and reliable urinary drainage is crucial as it can prevent loss of renal function, recurrent urinary tract infection, persistent hematuria, and possibly relieve pain. Currently, there is no algorithm or standardized treatment approach for the treatment of an excluded calyx or hydrocalyx, unlike for a symptomatic calyceal diverticulum [1,3]. The treatment approach for a calyceal diverticulum has been used to guide the treatment of an excluded calyx or hydrocalyx with a shift from invasive procedures to minimally invasive ureteroscopic or percutaneous techniques [1,4]. Available literature identifies reestablishment of pelvicalyceal communication by creating a neoinfundibulum as an important principle in treatment of these conditions which can be approached using a combination of antegrade and retrograde techniques [1,4,6]. The treatment process can involve neoinfundibular creation with track dilation and stent placement, though infundibulotomy and stenting has also been described [1,3,4,6–8]. Both treatment options are viable when using either a ureteroscopic or percutaneous antegrade approach [1,3,4,6–8].

At our institution, we have diagnosed an excluded calyx in 2 separate patients and offer a previously undescribed, novel technique for treatment. Both patients underwent minimally invasive procedures to create a neoinfundibulum with subsequent repeat balloon dilations of the new track by Interventional Radiology (IR) or Urology.

Case reports

Case 1

Patient 1 is a 17-year-old male who presented in transfer as the restrained backseat passenger in a high speed motor vehicle accident. His initial injuries included a traumatic ventral hernia, left hemopneumothorax, grade IV left kidney injury, grade II–III splenic injury, liver laceration, multiple left rib fractures,

and coccygeal fracture. Following presentation, he was taken emergently to the operating room with general surgery for an exploratory laparotomy, and among other findings, was noted to have a nonexpansile left retroperitoneal hematoma.

Urology was consulted the following day. His past urologic history is significant for a right ureteropelvic junction obstruction treated by a pyeloplasty as an infant. The initial urologic recommendation was to obtain a CT scan with delays, which revealed a grade IV left renal laceration with urinary leak.

Due to persistent fevers, he was taken to the operating room for a left ureteral stent placement. A retrograde pyelogram demonstrated a urine leak from his left kidney. Over the next several days, he had persistent fevers and leukocytosis. Repeat imaging demonstrated an enlarging left perinephric fluid collection, and he subsequently underwent percutaneous drainage of the fluid collection by IR.

He continued to exhibit fevers with leukocytosis, and repeat delayed imaging demonstrated persistent urinary leak. He therefore underwent percutaneous nephrostomy tube placement by IR to divert urine from the leak. A percutaneous antegrade urogram revealed that the left upper pole collecting system had separated from the remainder of the collecting system and become isolated due to the trauma with no opacification of the left renal pelvis upon contrast media instillation into the upper pole collecting system. IR placed 8Fr nephrostomy tubes into both the upper and lower pole separated collecting systems of the left kidney, which were left to bag drainage. Following the procedure, he was discharged home in improved condition.

Approximately 1 month after discharge, the patient presented to another institution with pyelonephritis. A CT scan revealed a central hematoma dividing the left kidney (Fig. 1), with both upper and lower pole nephrostomy tubes in place. Because he was failing conservative management of his injury, he was transferred to our institution, where he underwent ureteroscopy. Retrograde ureteroscopy was unsuccessful at accessing the upper pole collecting system from the left renal pelvis. Attempts at passing a wire retrograde into the isolated left upper pole collecting system were also unsuccessful. Therefore, through the upper pole nephrostomy tube access, using sharp recanalization, a connection between the upper pole collecting system and the renal pelvis of the left kidney was established (Fig. 2). The track was dilated and a nephrostomy tube was left across the neoinfundibulum. A separate nephrostomy tube was left behind to drain the excluded calyces. After several more weeks, he underwent conversion of the upper left nephrostomy tube to a left nephrostomy tube with extended sideholes, with the proximal side-holes located within the upper pole collecting system of the left kidney, and the pigtail placed across the previously dilated track of the neoinfundibulum and into the pelvis of the left kidney.

He was seen in outpatient urology clinic for follow-up approximately 2 weeks after discharge and began discussions about the possibility of requiring a left upper pole heminephrectomy or left radical nephrectomy. The goal at this point was to preserve as much renal function as possible without the morbidity of repeated episodes of left pyelonephritis. A renal scan showed the split function was 63% from the injured left kidney and 37% from the right kidney. Because of the

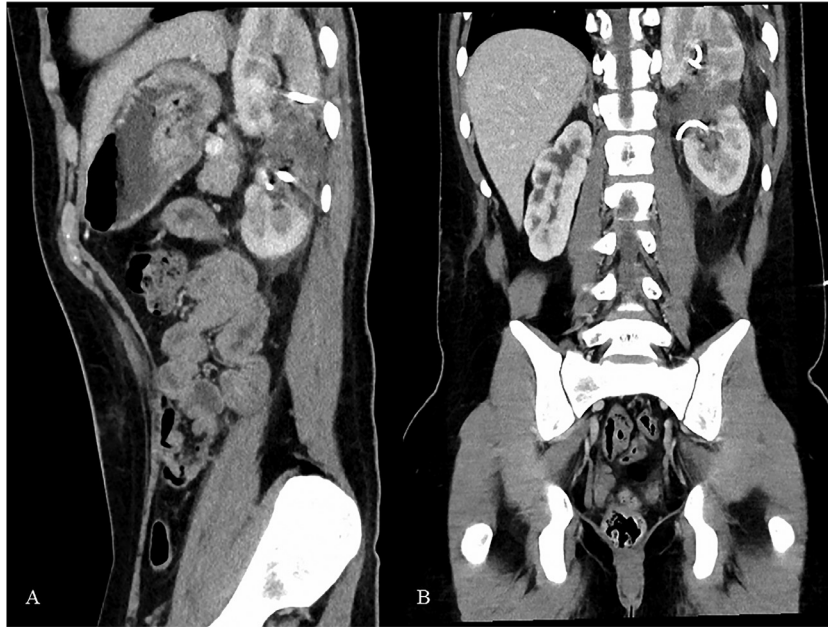


Fig. 1 – Sagittal (A) and coronal (B) CT images demonstrate a central hematoma separating the upper and lower moieties of the left kidney. Linear hyperdensities in the upper and lower moieties, best seen on image B, are upper and lower nephrostomy tubes present at the time of imaging.

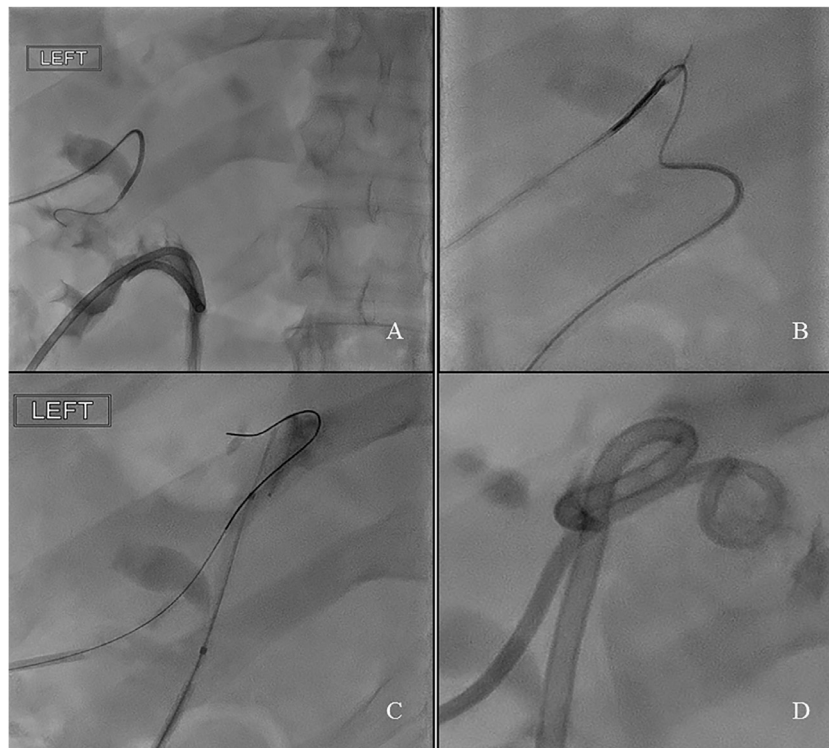


Fig. 2 – Percutaneous wire access was established to the upper moiety of the kidney, with a catheter advanced over the wire in to the collecting system. Contrast was injected through the existing lower moiety nephrostomy (A). The nephrostomy tube was then removed and replaced with a catheter. A wire was advanced through the catheter in the lower moiety which was then snared to establish access between both upper and lower moieties (B). Balloon dilation was then performed along the track (C), with a nephrostomy tube placed across the newly dilated track to maintain patency (D). The lower moiety nephrostomy tube was also replaced.

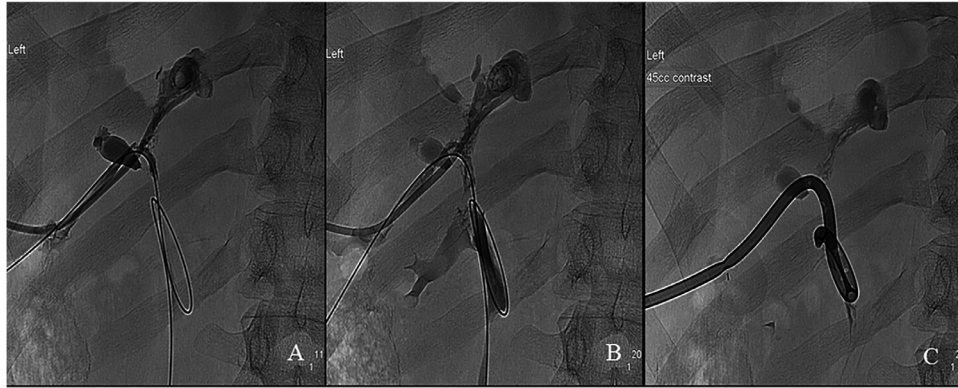


Fig. 3 – Repeat evaluation of the previously established connection (as described in [Fig. 2](#)) demonstrated near complete obliteration of the tract. Using a similar wire, catheter, snare technique as described in [Figure 2](#), access was re-established (A), as proven with contrast injection (B). A nephrostomy tube was again placed across the freshly dilated track (C).

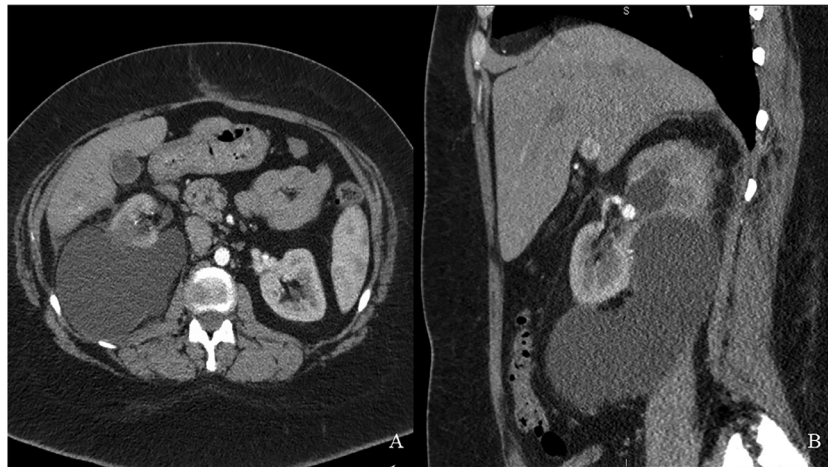


Fig. 4 – Axial (A) and sagittal (B) images showing the large right perinephric fluid collection. Hydronephrosis of the upper moiety can also be seen in the sagittal image (B).

patient's age and significant contribution of the left kidney to his overall kidney function, aggressive techniques were warranted to save the left kidney. He therefore underwent repeat balloon dilatation, and a new nephrostomy tube was placed across the dilated neoinfundibulum track, and the second, lower left nephrostomy tube was removed.

He underwent 3 subsequent balloon dilatation procedures over a 3-month period ([Fig. 3](#)). The neoinfundibulum remained patent. The left nephrostomy tube was removed as the patient had repeated urinary tract infections. Follow-up ultrasounds have shown no left hydronephrosis. He has done well clinically to date. He has remained free of a urinary tract infection since the left nephrostomy tube was removed 14 months ago.

Case 2

Patient 2 is a 39-year-old woman who presented with subxyphoid pain. Ultimately, a CT scan was obtained, which showed a 3.5 cm heterogeneous, solid enhancing renal tumor in the lower pole of the right kidney, located posteriorly, with no obvious regional lymphadenopathy. After work-up and dis-

cussion, she elected to proceed with a robotic-assisted laparoscopic right partial nephrectomy. She had an uncomplicated hospital course. Her pathology returned as clear cell renal cell carcinoma, pT1a, pNx. The surgical resection margins were negative.

A CT scan was obtained 3 months after surgery. It revealed a very large right perinephric fluid collection ([Fig. 4a](#)). It also demonstrated a right upper pole calyx with hydronephrosis ([Fig. 4b](#)). The right kidney had a mildly delayed nephrogram. She was asymptomatic and the serum creatinine was normal.

She elected to proceed with percutaneous drainage with IR. A urinoma drain was left in place, and there was significant output. A fluid creatinine was elevated, consistent with urine.

The concern at this point was that a functional upper pole calyx of the right kidney had been excluded at the time of partial nephrectomy. She underwent right ureteroscopy for diagnostic and potentially therapeutic purposes. A retrograde pyelogram showed total exclusion of the upper pole calyx ([Fig. 5a](#)). The flexible ureteroscope was passed into the renal pelvis, but urology was unsuccessful at accessing the excluded upper pole calyx. IR was consulted and the patient

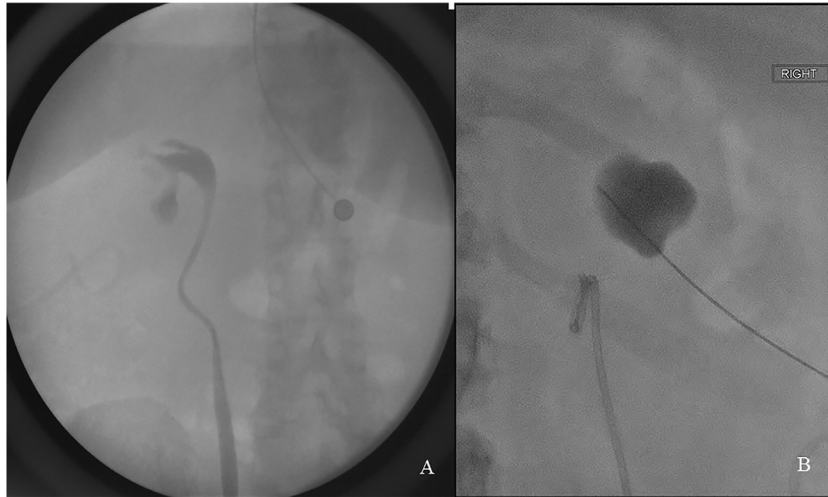


Fig. 5 – Retrograde pyelogram (A) performed via ureteral access and antegrade nephrostogram (B) via percutaneous access showing excluded calyces in both patients.

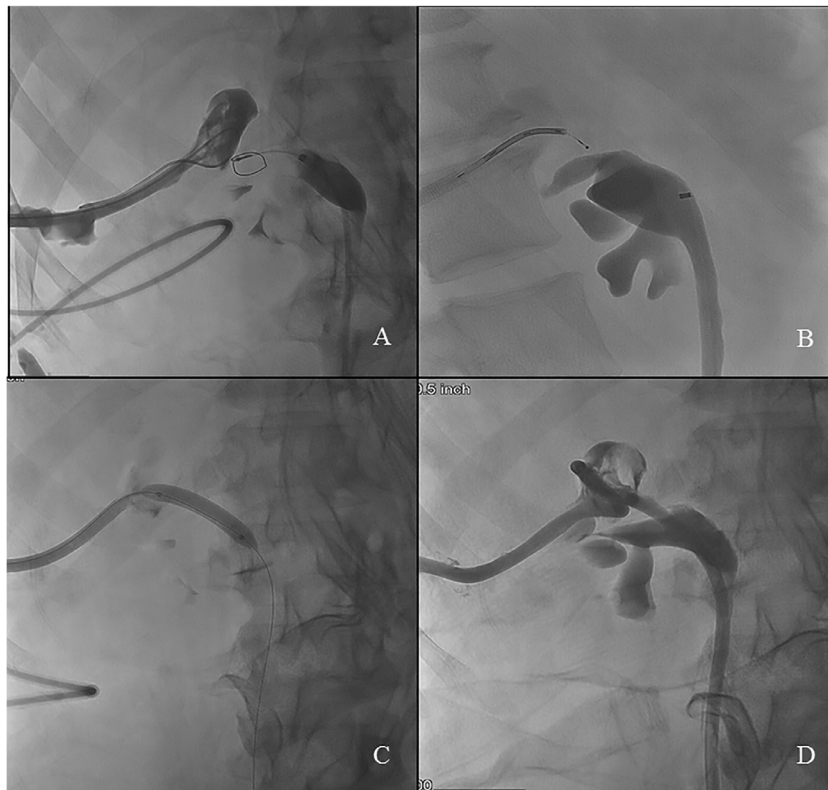


Fig. 6 – Initially continuity between the excluded calyx and renal pelvis was attempted using the back end of a stiff wire for the purposes of sharp recanalization, with the intent of snaring the end of the wire once a connection was established (A). When this was unsuccessful, a radiofrequency wire was used to establish continuity via a neoinfundibulum (B). The wire was advanced in an antegrade fashion down the ureter and the neoinfundibulum between the excluded calyx and renal pelvis was then dilated using a balloon (C). A nephroureteral stent was then placed across the neoinfundibulum in order to maintain patency (D). The stent was later internalized, with multiple repeat balloon dilations also performed over a period of 6 months.

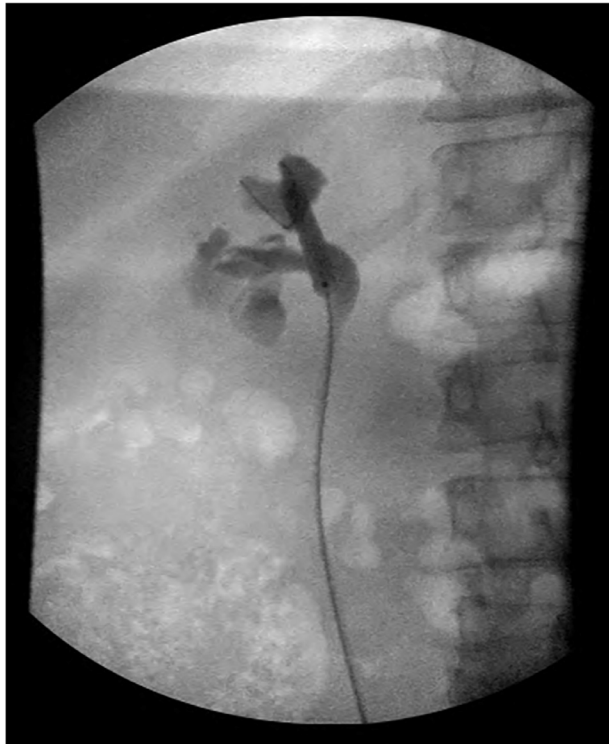


Fig. 7 – Balloon dilation of the neoinfundibulum using retrograde access.

had a right nephrostomy tube placed into the excluded calyx. The subsequent nephrostogram showed no communication with the renal pelvis (Fig. 5b).

The first attempt by IR at restoring continuity between the excluded calyx and the renal pelvis with sharp recanalization was unsuccessful (Fig. 6a). Continuity between the excluded upper pole calyx and the pelvis of the right kidney was subsequently successfully performed by IR using a radiofrequency wire (Fig. 6b; PowerWire RF Guidewire, Baylis Medical Company Inc., Montreal, QC Canada). The track was dilated with a balloon (Fig. 6c). A right internal-external nephroureteral stent was left in place across the dilated track of the neoinfundibulum (Fig. 6d). One month later, a repeat balloon dilatation was performed and the nephroureteral stent was internalized to a 10Fr x 28 cm double J ureteral stent. Subsequent balloon dilatations and ureteral stent exchanges were performed in retrograde fashion by the urology service (Fig. 7). She underwent a total of 6 balloon dilatation procedures of the neoinfundibulum, of which 4 were performed in a retrograde fashion by Urology. Balloon dilatations were performed on a monthly basis, for a total duration of 6 months. The nephroureteral stent was then removed 3 weeks after the final balloon dilation.

She has done well over the past 2 years without flank pain, infections, or complications from the procedures.

Results

Our patients developed their pathology due to either trauma or undergoing partial nephrectomy for a renal tumor. Our 2 pa-

tients underwent several repeat balloon dilations of the track of the neoinfundibulum. Dilatations were completed by both IR and Urology. Both patients have remained free of symptoms since treatment and continue to maintain serum creatinine levels that are within normal limits.

Patient 1 had several episodes of pyelonephritis between balloon dilatation procedures, while his nephrostomy tube remained in place. After completion of balloon dilatation procedures and removal of tubes, he has done well clinically over the past 27 months. He has had no further episodes of pyelonephritis and no left flank pain. His most recent imaging was a renal ultrasound obtained 6 months after the last balloon dilatation. This showed no left hydronephrosis. His most recent serum creatinine was 1.4 mg/dl and he has been asymptomatic without urinary tract infection for 27 months after removal of his nephrostomy tubes.

Patient 2 did well during her series of balloon dilatations and did not experience complications. After completing balloon dilatations, she has done well clinically over the past 26 months. She has had no episodes of pyelonephritis or right flank pain. The most recent imaging was a renal ultrasound obtained 12 months after the last balloon dilatation. This showed a chronically dilated upper pole calyx. The most recent serum creatinine was normal at 1.04 mg/dl. Just prior to initiation of treatment with serial balloon dilatations, a nuclear medicine renal scan showed that the right kidney had a T 1/2 of 52 minutes. After completion of the serial balloon dilatations, the T 1/2 improved to 15 minutes.

Discussion and conclusions

The excluded calyx and hydrocalyx are rare urologic diagnoses characterized by functional, urine-producing units of the kidney that have lost normal continuity with the remainder of the collecting system [1,3]. However, consequences of untreated obstructed calyces can be very problematic for the patient [1,3,4]. Treatment re-establishing normal collecting system anatomy has largely been based on the existing surgical management of symptomatic calyceal diverticula. Minimally invasive techniques are now routinely utilized, with IR and Urology often collaborating. It is key to re-establish reliable urinary drainage between the calyx in question and the remainder of the urinary tract [1]. Upon review of the literature, there are only case reports and small case series that describe management options for the excluded calyx and hydrocalyx.

Re-establishing reliable urinary drainage between excluded calyces and in the setting of hydrocalyx, as in our case series, makes use of established IR techniques. Recanalization with the stiff, back end of a guidewire for the purposes of “sharp” recanalization is a modified technique that is more commonly used for vascular occlusion [9–13]. A more common method is to use a guiding catheter/needle or coaxial needle/stylet combination [10]. The use of radiofrequency wires for recanalization of vascular occlusion is also supported by a large body of work and can be applied to urologic problems [9,11–14]. Radiofrequency wires can potentially be used to re-establish continuity between soft tissue structures in a similar fashion to re-establishing arterial or venous flow. The

main concern arising with either technique is that damage to surrounding soft tissue structures can occur quite easily [11]. Careful catheter guidance and high-resolution imaging are necessary for the use of these techniques to prevent procedure related complications.

Our 2 cases contribute to the body of literature on the endourologic treatment of the excluded calyx or hydrocalyx. We describe a novel technique, with either sharp or radiofrequency wire recanalization, creation of neoinfundibulum followed by serial balloon dilations of the neoinfundibulum every 1-2 months over a period of 3-6 months by IR or Urology. We believe that this technique should be considered as a safe option for the management of patients who present with this rare urologic entity.

REFERENCES

- [1] Mues AC, Landman J, Gupta M. Endoscopic management of completely excluded calices: a single institution experience. *J Endourol* 2010;24(8):1241–5.
- [2] Keeling AN, Wang TT, Lee MJ. Percutaneous balloon dilatation of stenotic calyceal diverticular infundibula in patients with recurrent urinary tract infections. *Eur J Rad* 2011;77:335–9.
- [3] Kieran K, Nelson CP, Wolf JS. Ureteroscopy for symptomatic hydrocalices: a case series. *J Endourol* 2006;20(6):413–17.
- [4] Elashry OM, Nakada SY, Pearle MS, Clayman RV. Endourologic management of stone-bearing excluded calices: contrasting case reports. *J Endourol* 1996;10(1):21–6.
- [5] Auge BK, Munver R, Kourambas J, Newman GE, Wu NZ, Preminger GM. Neoinfundibulotomy for the management of symptomatic caliceal diverticula. *J Urol* 2002;167:1616–20.
- [6] Bellman GC, Brock WA, Smith AD. Endourologic management of obstructed hydrocalyx after blunt renal trauma. *Urology* 1994;43(4):546–8.
- [7] Hwang TK, Park YH. Endoscopic infundibulotomy in tuberculous renal infundibular stricture. *J Urol* 1994;151:852–4.
- [8] Yip SK, Peh WC, Li JH, Cheung MC. Case report: percutaneous balloon dilatation and ureteral stenting for tuberculous renal infundibular and ureteral strictures. *Ann Acad Med Singapore* 1999;28:284–7.
- [9] Keller Eric J, Gupta Suraj SA, Bondarev S, Sato KT, Vogelzang RL, Resnick SA. Single-center retrospective review of radiofrequency wire recanalization of refractory central venous occlusions. *J Vasc Intervent Radiol* 2018;29(11):1571–7.
- [10] Farrel T, et al. Sharp recanalization of central venous occlusions. *J Vasc Intervent Radiol* 1997;10(2):149–54.
- [11] Sivananthan G, et al. Radiofrequency wire recanalization of chronic central venous occlusions is effective but not without the potential for complications. *J Vasc Intervent Radiol* 2014;25(3):S16.
- [12] Salaskar, A., Ferra, M., Narayanan, H. et al. Radiofrequency wire ‘power wire’ recanalization of calcified chronically occluded inferior vena cava. *CVIR Endovasc* 2018: 1, 24.
- [13] Guimaraes Marcelo, et al. Radiofrequency wire for the recanalization of central vein occlusions that have failed conventional endovascular techniques. *J Vasc Intervent Radiol* 2012;23(8):1016–21.
- [14] Cisu T, Cleveland C, Morris CS, Plante M. Creation of a duplicated collecting system ureteric neoanastomosis in a transplanted cadaveric kidney with the use of a radiofrequency guide wire. *Urol Case Rep* 2017;16:38–40.