

# Vascular air embolism during percutaneous nephrolithotomy without pneumopyelogram: a case report of successful rescue

Journal of International Medical Research

50(6) 1–5

© The Author(s) 2022

Article reuse guidelines:

[sagepub.com/journals-permissions](https://sagepub.com/journals-permissions)

DOI: 10.1177/03000605221102096

[journals.sagepub.com/home/imr](https://journals.sagepub.com/home/imr)

Junlong Zhang<sup>1</sup>, Hongle He<sup>2</sup>, Chengqiang Mo<sup>1</sup>,  
Zhenhua Chen<sup>1</sup> and Shuangjian Jiang<sup>1</sup> 

## Abstract

Vascular air embolism (VAE) is a rare complication of percutaneous nephrolithotomy. Paradoxical air embolization resulting from VAE may be more likely to occur in patients with an atrial-septal defect, such as patent foramen ovale. Here, the case of a female patient with VAE that occurred during percutaneous nephrolithotomy is presented. Although the patient was diagnosed with patent foramen ovale, she recovered well without any severe paradoxical air embolization symptoms. To our knowledge, this is the first report of VAE with paradoxical air embolization that occurred in a patient with patent foramen ovale during percutaneous nephrolithotomy that was conducted without pneumopyelography.

## Keywords

Percutaneous nephrolithotomy, patent foramen ovale, paradoxical air embolization, vascular air embolism, upper urinary tract stones, holmium laser lithotripsy

Date received: 6 February 2022; accepted: 3 May 2022

## Introduction

Percutaneous nephrolithotomy (PCNL) is one of the main treatments for upper urinary tract stones.<sup>1</sup> Very few cases of vascular air embolism (VAE) during the PCNL process have been reported in the published literature.<sup>2–4</sup> Among the few published

<sup>1</sup>Department of Urology, The First Affiliated Hospital of Sun Yat-Sen University, Guangzhou, China

<sup>2</sup>Department of Medical College, Sun Yat-Sen University, Guangzhou, China

### Corresponding authors:

Zhenhua Chen, Department of Urology, The First Affiliated Hospital of Sun Yat-Sen University, No. 58 Second Zhongshan Road, Guangzhou 510080, China.  
Email: [chenzh75@mail.sysu.edu.cn](mailto:chenzh75@mail.sysu.edu.cn)

Shuangjian Jiang, Department of Urology, The First Affiliated Hospital of Sun Yat-Sen University, No. 58 Second Zhongshan Road, Guangzhou 510080, China.  
Email: [jiangshj3@mail.sysu.edu.cn](mailto:jiangshj3@mail.sysu.edu.cn)



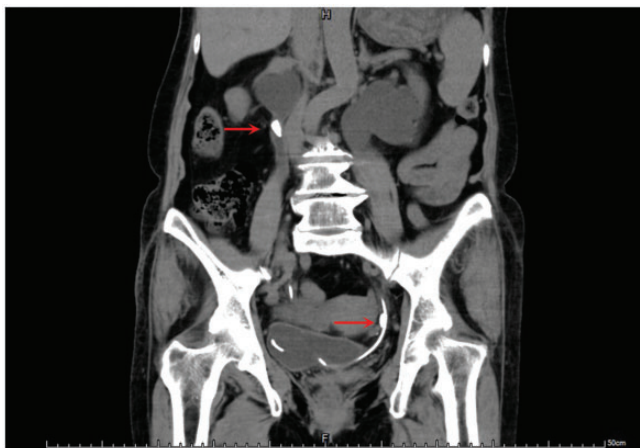cases, paradoxical air embolization was reported during PCNL in a patient with patent foramen ovale that provided a right to left shunt.<sup>2</sup> To the best of our knowledge, the current case represents the first report of VAE during PCNL that was performed without gas pyelography, in which the patient was rescued successfully, avoiding severe cerebral air embolization complications.

## Case report

A 62-year-old female patient presented to the Department of Urology, The First Affiliated Hospital of Sun Yat-Sen University, Guangzhou, China in February 2019, with hydronephrosis and calculus detected in bilateral ureters by computed tomography (CT; Figure 1). Her medical history included rapid atrial fibrillation and occasional syncope for the previous 5 months that was treated with 40 mg simvastatin, orally, four times daily, and 5 mg levamlodipine, orally, four times daily. Echocardiography showed the existence of patent foramen ovale, but the ejection fraction (72%) was acceptable for surgery. Results from laboratory tests and anaesthesia evaluation before surgery were within

normal limits. The patient was placed in the Galdakao-modified supine Valdivia (GMSV) position, considering the atrial-septal defect in the heart. General anaesthesia was induced using 4 µg/ml target-controlled infusion of propofol, 0.3 mg fentanyl, i.v., and 14 mg cisatracurium, i.v., and maintained with 2 µg/ml target-controlled infusion of propofol, 1% inhaled sevoflurane and 2 µg/ml target-controlled infusion of remifentanyl. Stones in the left ureter were then crushed with a ureteroscope.

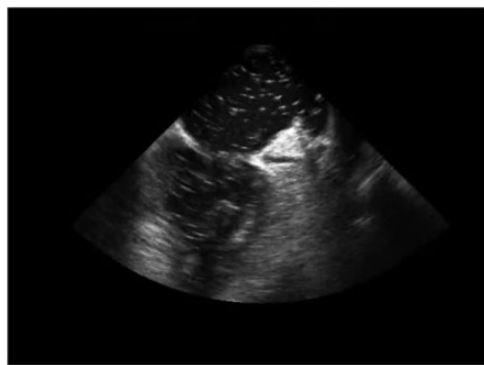
Percutaneous nephrolithotomy was performed to treat stones in the right ureter. Direct puncture was attempted twice due to bleeding in the first tract. A second F16 percutaneous tract was created for the surgeon to break the stone using a holmium laser (VersaPulse™ PowerSuite™ 80/100 W Holmium Laser, Boston Scientific, Marlborough, MA, USA). The stone crusher and power of the laser was set at 1.0 J/20 Hz, and a perfusion fluid pump was used with pressure set to no more than 300 mmHg. Affected by bleeding in the first channel, a high perfusion pump flow rate was applied to ensure clear vision.



**Figure 1.** Representative coronal computed tomography scan image demonstrating hydronephrosis and calculus detected in bilateral ureters. The arrows mark the stone locations.

At 15 min after initiation of lithotripsy, when the stone was almost cleared, serious hypoxemia and hypotension suddenly developed. Arterial pressure dropped from 120/80 mmHg to 70/40 mmHg, and functional oxygen saturation was 80% on oxygen at 100%. Pneumothorax or tracheal intubation obstruction was initially considered, during the operation, but auscultation of both lungs showed no abnormalities. The patient was turned to the Trendelenburg position and more oxygen was administered through mechanical ventilation. After administration of 0.05–0.15 µg/kg/min norepinephrine, by i.v. pumping, her arterial pressure returned to almost 120/80 mmHg and functional oxygen saturation returned to 100%. Transoesophageal echocardiography confirmed multiple small bubbles in the whole heart (Figure 2), therefore, VAE was considered to be the cause of drop in blood pressure and oxygen saturation.

The total duration of surgery was 105 min and intraoperative blood loss was 150 ml. The patient was transferred to the intensive care unit of The First Affiliated Hospital of Sun Yat-Sen University, and treated accordingly. A CT scan was performed the next day, which showed no sign of air bubbles or embolus. The patient



**Figure 2.** Transoesophageal echocardiogram demonstrating air bubbles within the heart chambers following holmium laser lithotripsy.

recovered well, without any symptoms of cerebral air embolism.

The study complied with the Declaration of Helsinki and written informed consent to publish the clinical details and accompanying images were obtained from the patient. The reporting of this study conforms to CARE guidelines.<sup>5</sup>

## Discussion

Several complications have been reported since PCNL was applied to clinical use, the most common being haemorrhage, with the incidence of VAE being relatively rare. To our knowledge, the first case of VAE complicating PCNL was reported by Miller et al.,<sup>6</sup> in 1984.

Vascular air embolism is caused by the entry of gas into the cardiovascular system, which is mainly an iatrogenic problem, and VAE during PCNL usually happens after pyelography using air, which seems to be the most relevant factor.<sup>2,4,7,8</sup> The holmium laser can induce cavitation during ablation of the stone, as the high power of the laser lowers the pressure of the fluid, thus causing release of the air that is dissolved in it.<sup>9</sup> In the present case, the gas was probably generated from cavitation induced by the holmium laser. Haemorrhage in the first punctuation tract created an opening in the vein that may also have provided an entry site for air bubbles.

Although VAE is a rare complication, it may lead to serious consequences and is sometimes fatal. The mortality and morbidity associated with VAE depends on the volume of air that enters the vessel, the rate of air entrainment, and the position of the patient when it occurs.<sup>2,4</sup> Patients with septal heart defects often present with systemic air embolization syndrome during the occurrence of VAE.<sup>3</sup> In the present case, the gas passed through the patent foramen ovale and filled the whole heart with multiple bubbles. However, there was

no associated paradoxical systemic air embolization syndrome. The successful rescue and good recovery might have been related to a number of factors, including the fact that the volume of air may have been relatively low in the present case. In a previously published case,<sup>3</sup> pneumopyelography was performed by injecting 25 ml of air into the pelvic system, resulting in the patient experiencing weakness of his right leg and tonic seizure. The air in the present case, induced by laser lithotripsy, may have comprised small bubbles and a small volume, avoiding a large amount of gas entering the blood vessel in a short time. Another factor may have been that the present patient was in a GMSV position and was treated in a timely fashion. In a GMSV position, the right part of the heart is not lower than the renal pelvis, which may have helped prevent the air being drawn into the blood vessel by negative pressure.<sup>10</sup> Additionally, in a GMSV position, the patient could be treated faster without the problem of changing position.

Because VAE may have fatal consequences, prompt diagnosis and treatment is important. Transoesophageal echocardiography is advised to detect VAE, even though it is an invasive procedure compared with precordial Doppler ultrasonography. Suggested treatments for VAE include: (1) changing the patient's position and keeping the right atrium above the surgical site; (2) increasing oxygen uptake; (3) starting cardiopulmonary resuscitation if the heart stops beating; and (4) administering norepinephrine, epinephrine, and dopamine, depending on the heart status of the patient. Furthermore, the Trendelenburg position may help reduce the chance of cerebral air embolism in patients with a right to left shunt.

In conclusion, although VAE is a rare complication of PCNL performed without gas pyelography, urologists must remain vigilant of this possibility. All practical

steps during the surgical procedure should ensure minimizing air that may enter the blood vessel.

### Author contributions

JLZ collected and analysed the data; HLH, CQM and SJJ treated the patient and performed the follow-up; and ZHC provided guidance on drafting the manuscript, and revised the manuscript. All authors have read and approved the manuscript.

### Data accessibility

The data and materials of this study are available from the corresponding author on reasonable request.


### Declaration of conflicting interest

The authors declare that there is no conflict of interest.

### Funding

The authors disclosed receipt of the following financial support for the research, authorship, and/or publication of this article: This work was financed by grants from the National Natural Science Foundation of China (81902576).

### ORCID iD

Shuangjian Jiang  <https://orcid.org/0000-0001-6910-7859>

### References

1. Chen Y, Wen Y, Yu Q, et al. Percutaneous nephrolithotomy versus flexible ureteroscopic lithotripsy in the treatment of upper urinary tract stones: a meta-analysis comparing clinical efficacy and safety. *BMC Urol* 2020; 20: 109.
2. Song SH, Hong B, Park HK, et al. Paradoxical air embolism during percutaneous nephrolithotomy: a case report. *J Korean Med Sci* 2007; 22: 1071–1073.
3. Turillazzi E, Pomara C, Bisceglia R, et al. Vascular air embolism complicating percutaneous nephrolithotomy: medical malpractice or fatal unforeseeable complication? *Urology* 2009; 73: 681.e1–681.e4.

4. Chahal D, Ruzhynsky V, McAuley I, et al. Paradoxical air embolism during percutaneous nephrolithotomy due to patent foramen ovale: case report. *Can Urol Assoc J* 2015; 9: E658–E660.
5. Gagnier JJ, Kienle G, Altman DG, et al. The CARE guidelines: consensus-based clinical case reporting guideline development. *Headache* 2013; 53: 1541–1547.
6. Miller RA, Kellett MJ and Wickham JE. Air embolism, a new complication of percutaneous nephrolithotomy. What are the implications? *J Urol (Paris)* 1984; 90: 337–339.
7. Hegland DL, Canales BK and Katz RI. Quadripareisis from air emboli during percutaneous nephrolithotomy. *J Clin Anesth* 2014; 26: 318–320.
8. Parikh G, Sonde SR and Kadam P. Venous air embolism: a complication during percutaneous nephrolithotomy. *Indian J Urol* 2014; 30: 348–349.
9. Ho DS, Scialabba D, Terry RS, et al. The role of cavitation in energy delivery and stone damage during laser lithotripsy. *J Endourol* 2021; 35: 860–870.
10. Droghetti L, Giganti M, Memmo A, et al. Air embolism: diagnosis with single-photon emission tomography and successful hyperbaric oxygen therapy. *Br J Anaesth* 2002; 89: 775–778.