

Immune reconstitution inflammatory syndrome in HIV-infected patients

Naomi F Walker¹⁻³
James Scriven²⁻⁴
Graeme Meintjes¹⁻³
Robert J Wilkinson^{1,2,5}

¹Department of Medicine, Imperial College London, London, UK;

²Clinical Infectious Diseases Research Initiative, Institute of Infectious Disease and Molecular Medicine, University of Cape Town, Cape Town, South Africa; ³Department of Medicine, University of Cape Town, Cape Town, South Africa; ⁴Liverpool School of Tropical Medicine, Liverpool, UK; ⁵MRC National Institute of Medical Research, London, UK

Abstract: Access to antiretroviral therapy (ART) is improving worldwide. Immune reconstitution inflammatory syndrome (IRIS) is a common complication of ART initiation. In this review, we provide an overview of clinical and epidemiological features of HIV-associated IRIS, current understanding of pathophysiological mechanisms, available therapy, and preventive strategies. The spectrum of HIV-associated IRIS is described, with a particular focus on three important pathogen-associated forms: tuberculosis-associated IRIS, cryptococcal IRIS, and Kaposi's sarcoma IRIS. While the clinical features and epidemiology are well described, there are major gaps in our understanding of pathophysiology and as a result therapeutic and preventative strategies are suboptimal. Timing of ART initiation is critical to reduce IRIS-associated morbidity. Improved understanding of the pathophysiology of IRIS will hopefully enable improved diagnostic modalities and better targeted treatments to be developed.

Keywords: antiretroviral therapy, tuberculosis, IRIS, diagnosis, complications

Introduction

Antiretroviral therapy (ART) has dramatically reduced HIV-associated mortality, which decreased from a peak of 2.3 million in 2005 to 1.6 million in 2012.¹⁻³ This reflects improvement in access to ART in the last decade, especially for HIV-infected patients in low- and middle-income countries, where the number of patients receiving ART has increased more than 30-fold (from 300,000 in 2002 to 9.7 million in 2012) and life expectancy is increasing.^{3,4} It is now recognized that commencement of ART earlier in HIV infection improves outcomes, and international guidelines have been updated to reflect this.⁵ Tuberculosis (TB) is now considered to be an indication for ART irrespective of CD4 count, as ART reduces mortality in TB patients.⁶

However, ART initiation is not without risk of complications, particularly in the first 6 months.^{7,8} HIV-associated immune reconstitution inflammatory syndrome (IRIS) has emerged as an important early complication of ART initiation, associated with considerable morbidity and mortality, particularly in patients who commence ART with advanced immunosuppression.⁹ In this condition, immune recovery following ART initiation associates with a pathological inflammatory response, usually directed toward microbial antigens. Although there is considerable clinical and pathophysiological heterogeneity, key features include clinical deterioration in the first weeks to months of ART, with evidence of localized tissue inflammation with or without a systemic inflammatory response.

In this review, we provide an overview of clinical and epidemiological features of HIV-associated IRIS, current understanding of pathophysiological mechanisms, available

Correspondence: Robert J Wilkinson
Clinical Infectious Diseases
Research Initiative, Room 3.03.05,
Wolfson Pavilion, Institute of Infectious
Diseases and Molecular Medicine (IDM),
Faculty of Health Sciences, University
of Cape Town, Observatory 7925,
Cape Town, South Africa
Tel +27 21 406 6084
Fax +27 21 406 6796
Email r.j.wilkinson@imperial.ac.uk

therapy, and preventive strategies, with a particular focus on three important pathogen-associated forms: TB-associated IRIS (TB-IRIS), cryptococcal IRIS (C-IRIS), and Kaposi's sarcoma (KS) IRIS. A key message is that while IRIS-associated morbidity may be considerable, ART is key to survival in HIV and timing of initiation of ART is critical. Rarely should ART be interrupted or discontinued because of IRIS.

Our discussion is limited to HIV-associated forms of IRIS. However, IRIS has been described following reversal of other forms of immunosuppression, including after reversal of iatrogenic immunosuppression in transplant recipients, following bone marrow recovery after chemotherapy for hematological malignancies, and following discontinuation of anti-tumor necrosis factor- α (TNF- α) therapy for rheumatoid arthritis or treatment with the monoclonal antibody natalizumab for multiple sclerosis.^{10–13}

Historical perspective and case definitions

Among the first accounts of IRIS-type phenomena were reports of zidovudine-induced fever associated with lymphadenitis in patients with nontuberculous mycobacterial infections.^{14,15} French et al reported a case series of unusually localized *Mycobacterium avium-intracellulare* (MAI) infections presenting with fevers and lymphadenitis without mycobacteraemia, which developed soon after commencement of zidovudine monotherapy.¹⁶ These presentations were accompanied by the emergence of delayed-type hypersensitivity reactivity to purified protein derivative (PPD) in patients who had previously been PPD unresponsive.

IRIS has emerged as a highly heterogeneous condition, with features differing according to the associated pathogen. However, two distinct temporal patterns of disease were commonly described and are now recognized as “paradoxical IRIS” and “unmasking IRIS” (see Figure 1).^{17–19} In paradoxical forms of IRIS, symptoms and signs associated with a known opportunistic infection (OI), for which treatment is under way, recur or become acutely worse, despite an earlier favorable response to therapy prior to ART. In unmasking IRIS, a new OI presents with a pronounced inflammatory component following ART initiation. Responding to clinical and research needs, the International Network for the Study of HIV-associated IRIS (INSHI) published consensus case definitions for C-IRIS and TB-IRIS.^{18,19} Such definitions are suitable for use in low-resource settings, as CD4 count and HIV viral load responses are not included as criteria. Consensus case definitions for other forms of IRIS are lacking although much needed.²⁰ The main challenge with all

proposed definitions of paradoxical IRIS is the requirement to adequately exclude other causes of clinical deterioration. There is no definitive diagnostic test for IRIS. In resource-constrained settings, clinicians may find themselves treating multiple conditions concurrently in a sick patient, being uncertain of the definitive diagnosis due to limited laboratory support, with IRIS as a diagnosis of exclusion following unsuccessful treatment of other conditions.

The concept of unmasking IRIS is less well defined than that of paradoxical IRIS. The broader term of an “ART-associated OI” is proposed to encompass all OI diagnosed during early ART, as unmasking IRIS may be difficult to differentiate from development of an OI in a patient who is still immunocompromised during early ART and which progresses along a typical clinical course (see Figure 1). Some recent reports have defined all new OI in the first 6 months of ART as cases of unmasking IRIS.^{21,22} This approach may reduce comparability with earlier studies and increase heterogeneity of IRIS cases, complicating efforts to precisely define IRIS immunopathology.²³

Epidemiology and risk factors

Numerous infective and noninfective conditions are associated with IRIS in HIV infection (see Table 1).^{15,24–34} A meta-analysis of 54 studies (published between 1998 and 2009) of 13,103 HIV-infected patients starting ART, reported 1,699 (13%) cases of IRIS.⁹ The incidence was slightly higher (16.1%) in studies of unselected HIV-infected patients, and reported incidence varied widely depending on study design, population, and associated pathogen. For example, 37.7% of patients with a diagnosis of cytomegalovirus (CMV) retinitis prior to ART initiation developed IRIS, compared to 6.4% patients with a diagnosis of KS.⁹

The epidemiology of IRIS reflects the epidemiological distribution of HIV-associated OI and the prevalence of various key risk factors in a given population. Table 2 reports the proportion of IRIS attributable to different OI/inflammatory conditions in recently published studies of unselected patients commencing ART, demonstrating that reported incidence varies according to geographic region and by study design.^{7,21,35–38} Risk factors for IRIS include an advanced state of immunosuppression (low CD4 count) and high infective antigen burden/disseminated OI at ART initiation (see Table 3). These characterize a substantial proportion of patients with newly diagnosed HIV in developing countries where suboptimal access to HIV care and health services in general, and stigma associated with HIV, contribute to late presentation.³⁹ While advanced immunosuppression and late presentation are also

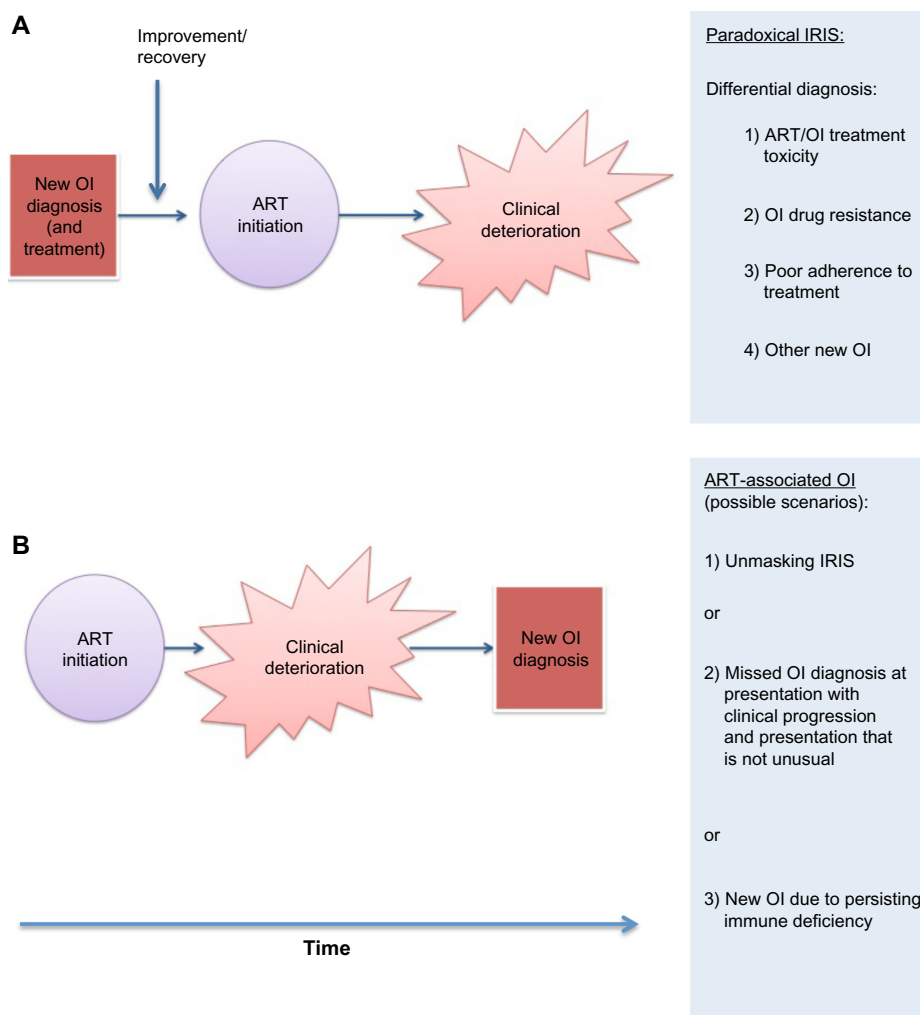


Figure 1 Schematic demonstrating sequence of key events in paradoxical immune reconstitution inflammatory syndrome (IRIS) (**A**) and unmasking IRIS (**B**).

Note: Unmasking IRIS is one possible presentation of an antiretroviral therapy (ART)-associated opportunistic infection (OI), and is characterized by an atypically inflammatory or localized presentation, unlike other forms of ART-associated OI (points 2 and 3 in **[B]**).

encountered in patients presenting to ART services in higher-resource settings, in low-resource settings IRIS incidence and associated mortality appear to be higher.^{8,40}

Overall mortality in IRIS is reported to be between 0% and 15%, with variability attributed to geography, associated OI, baseline morbidity, and degree of immunosuppression.^{9,40,41} IRIS affecting the central nervous system (CNS) confers a particularly high mortality. In patients with cryptococcal meningitis (CM)-associated IRIS, mortality is reported at 20.8% and CNS TB-IRIS mortality rates are up to 75%.^{9,42,43} Where space is limited around a critical organ, such as the brain, excess inflammation with associated cerebral edema has severe effects. Establishing an accurate cause of death and correctly attributing it to IRIS is difficult in many circumstances and reported mortality rates may therefore be under- or overestimates. High rates of mortality occur in the first 6 months of ART in resource-limited settings, even

in patients without an IRIS diagnosis. There is difficulty determining from available data sources what the exact contribution of IRIS to these deaths is.^{8,38,44}

Pathophysiology

In both C-IRIS and TB-IRIS, at the time of IRIS onset, elevated concentrations of proinflammatory mediators, including C-reactive protein (CRP) and cytokines (eg, interleukin [IL]-6, IL-12, TNF- α) are detectable in serum and may also be elevated in cerebrospinal fluid (CSF) in CM-IRIS and TB meningitis (TBM) IRIS.^{45–49} A proinflammatory cytokine cascade may be a final common pathway by which IRIS inflammation occurs.^{45,50}

The increased incidence of IRIS in patients with lower pre-ART CD4 counts and disseminated OI suggests that more advanced immunodeficiency prior to ART initiation may lead to a higher pathogen load, resulting in excessive inflammation, once the immune system starts to recover. For

Table 1 Pathogens and key clinical features of associated IRIS

Condition	Clinical features of IRIS
Pathogen-associated	
Bacteria	
<i>Mycobacterium tuberculosis</i>	Fever, lymphadenitis, new/ worsening pulmonary infiltrates, pleural effusions, hepatomegaly, paradoxical or unmasking TBM/ tuberculoma
NTM	Fever, lymphadenitis (painful/suppurative), pulmonary infiltrates and cavitation, inflammatory masses
<i>Mycobacterium avium-intracellulare</i>	
<i>Mycobacterium genavense</i>	
<i>Mycobacterium kansasii</i>	
<i>Mycobacterium scrofulaceum</i>	
<i>Mycobacterium xenopi</i>	
BCG	Pediatric, vaccine associated; local reaction, lymphadenitis
<i>Mycobacterium leprae</i>	Typically tuberculoid or borderline forms, type I reactions, neuritis
Other	
<i>Bartonella spp.</i>	Granulomatous splenitis
<i>Chlamydia trachomatis</i>	Reiter's syndrome
Viral	
Herpes viruses	
CMV	Immune recovery uveitis (usually following previous history of retinitis), retinitis (typically unmasking)
VZV	Dermatologic reactivation (shingles), encephalitis, transverse myelitis, stromal keratitis
HSV-1, HSV-2	Mucocutaneous ulceration, encephalomyelitis
EBV	New presentation of non-Hodgkins's lymphoma, Burkitt's lymphoma
HHV-8	Kaposi's sarcoma- IRIS, multicentric Castleman's disease
Hepatitis B, Hepatitis C	Hepatitis flare, rapidly progressive cirrhosis
Polyomaviruses	
JC virus	Paradoxical PML (clinical deterioration, progression of lesions) or unmasking PML (new diagnosis)
BK virus	Meningoencephalitis
Molluscumcontagiosum virus	Acute new or recurrent cutaneous papules with florid/ extensive distribution
Parvovirus B19	Pure red cell aplasia, encephalitis
HPV	Warts (acute recurrence/ relapse or enlargement)
Fungal	
<i>Cryptococcus neoformans</i>	Meningitis with raised intracranial pressure, lymphadenitis, pneumonitis, ocular and soft tissue inflammation
<i>Pneumocystis jirovecii</i>	Unmasking PCP, paradoxical deterioration during or shortly after treatment with worsening hypoxia and new pulmonary infiltrates, organizing pneumonia (rare)
<i>Histoplasma spp</i>	Acute fistulous lymphadenopathy
<i>Candida spp</i>	Typically unmasking; mucocutaneous (oral/oesophageal)
<i>Tinea corporis</i>	Inflammatory cutaneous presentation
Parasitic	
<i>Toxoplasma gondii</i>	New or enlarging intracerebral lesions (ring-enhancing appearance on contrast neuroimaging)
<i>Schistosoma mansoni</i>	Eosinophilia, enteritis, colitis/polyposis
<i>Leishmania sp</i>	
<i>Leishmania major</i>	Cutaneous, uveitis
<i>Leishmania infantum</i>	Post-kala-azar dermal leishmaniasis, visceral leishmaniasis
<i>Leishmania braziliensis</i>	Cutaneous, mucosal
<i>Strongyloidesstercoralis</i>	Gastrointestinal or disseminated presentation; pneumonitis, enteritis, eosinophilia, hepatitis
<i>Cryptosporidium spp</i>	Terminal ileitis, duodenitis, cholangitis, gastrointestinal ulceration
<i>Microsporidium spp</i>	Keratoconjunctivitis
Non-pathogen-associated	
Autoimmune	
Grave's disease	May occur as a new presentation, or an exacerbation of existing autoimmune condition
Guillain -Barré Syndrome	
Rheumatoid arthritis	
Polymyositis	
SLE	
Relapsing polychondritis	

(Continued)

Table 1 (Continued)

Condition	Clinical features of IRIS
Dermatological	Inflammatory presentation
Eosinophilic folliculitis	
Seborrheic dermatitis	
Pruritic papular eruption	
Acne	
Other	
Sarcoidosis	New or recurrent granulomatous inflammation, typically late (around 12 months post-ART initiation) in patients with CD4 counts >200 cells/mm ³ ; typically pulmonary presentation, but may be cutaneous (erythema nodosum, papular lesions) and/or intra-abdominal
Lymphoid interstitial pneumonitis	Fever, respiratory distress, negative microbiological tests (may mimic PCP)
CNS IRIS	Leukoencephalopathy, demyelination, cerebral edema

Abbreviations: ART, anti-retroviral therapy; BCG, Bacillus Calmette–Guérin; CMV, cytomegalovirus; CNS, central nervous system; EBV, Epstein–Barr virus; HSV, Herpes simplex virus; HHV-8, Human herpes virus-8 (Kaposi's sarcoma virus); HPV, human papilloma virus; IRIS, immune reconstitution inflammatory syndrome; JC, John Cunningham; NTM, nontuberculous mycobacteria; OI, opportunistic infection; PCP, *Pneumocystis jirovecii* pneumonia; PML, progressive multifocal leukoencephalopathy; SLE, systemic lupus erythematosus; TBM, tuberculosis meningitis; VZV, Varicella zoster virus.

example, individuals who develop C-IRIS have significantly reduced CSF inflammation during the initial episode of CM compared to non-IRIS patients (lower CSF white cell count, interferon- γ [IFN- γ], IL-6, IL-8, and TNF- α) and higher pre-ART serum cryptococcal antigen titers.^{46,49} In TBM-IRIS, CSF culture positivity for *Mycobacterium tuberculosis* (M.tb) at TBM diagnosis confers a ninefold greater risk of IRIS, compared to those with culture-negative TBM, also suggesting that antigen load at OI diagnosis is important. However, in TBM, prior to ART initiation, higher TNF- α levels and raised CSF neutrophil counts were observed in IRIS patients compared to those that did not develop IRIS, suggesting that a pro- rather than anti-inflammatory milieu precedes TBM IRIS onset.⁵¹

As ART initiation leads to a rapid increase in peripheral blood CD4 T lymphocyte count in most patients, the recovery of pathogen-specific cell-mediated immune responses has been studied in TB and other OI, in HIV-infected patients following ART initiation. In HIV-infected patients, increased CD4 Th1 responses to mycobacterial antigens have been reported following ART initiation.^{16,52–55} Studies indicate these increased responses associate with IRIS.^{16,52,53,55} However, a detailed longitudinal study of CD4 T-cell responses to a range of M.tb recombinant antigens found that highly dynamic IFN- γ responses occurred in both TB-IRIS patients and patients who did not develop IRIS and did not clearly differentiate the two groups.⁵⁴ This finding has been supported by the results of two further studies of Th1 responses to mycobacterial antigens in TB-IRIS, which also call into question a causal link.^{56,57}

While a disturbance of regulatory T-cell number or function could explain excessive inflammation, this has not been convincingly demonstrated. A few studies have demonstrated

an increased rather than decreased number of regulatory CD4 T-cells in mycobacterial and C-IRIS.^{54,58,59} Reduced IL-10 has been associated with IRIS in some studies, suggesting that regulatory function may be impaired.^{58,60} However, a recent comparison of 20 TB-IRIS patients and 20 non-IRIS control patients found increased IL-10 concentrations in serum of TB-IRIS patients, and increased IL-10 transcript in peripheral blood mononuclear cells of TB-IRIS patients compared to controls, after restimulation with M.tb.⁶¹ One study demonstrated reduced numbers of inhibitory natural killer (NK) receptors on mycobacteria-specific V δ 2 TCR $\gamma\delta$ T-cells.⁵³ Further studies of regulatory cell types and function in IRIS are required.

Barber et al (studying a murine model of MAI-IRIS) argue that because IRIS is not specific to CD4 T-cell depletion in HIV (and occurs following reversal of HIV-unrelated immunosuppression, eg, post-TNF- α treatment), it is unlikely that CD4 T-cell responses are the central contributory factor.⁶² Rather, they propose that an uncoupling of innate and adaptive immunity is responsible. They hypothesize that in HIV infection, CD4 deficiency and thus deficiency of CD4 co-stimulation impairs full activation of innate immune cells, particularly macrophages in TB and MAI infection. The resultant antigen accumulation and excessive priming of innate immune cells lead to an excessive inflammatory response, once activation does occur following immune restoration.⁶²

Given their importance in antigen processing and pathogen trafficking, cells of the innate immune system such as monocytes, macrophages, and neutrophils are of increasing interest in IRIS pathophysiology. Favoring a role for innate immunity is the formation of organized tissue granulomas in IRIS (such as granulomatous hepatitis in TB-IRIS). Granulomatous

Table 2 Recently published studies reporting IRIS incidence rates in unselected cohorts

Population and reference	Overall incidence, %	IRIS-associated condition/opportunistic infection, proportion of total IRIS cases, %
USA ³⁵ n=196	11 (reported on paradoxical IRIS only)	KS, 57 TB, 19 PCP, 14 Disseminated cryptococcosis, 5 MAI, 5
USA ²¹ n=2,610	10.6 (reported on unmasking IRIS only)	Candidiasis, 23 Folliculitis, 13.8 HSV, 12.4 Warts, 12.2 Tinea, 11.1
Mexico ³⁶ n=390	27	VZV, 32 TB, 11 MAI, 9 PCP, 6 <i>Cryptococcus neoformans</i> , 5
India ³⁷ n=97	35	Mucocutaneous (combined), 35.2 TB, 29.4 PCP, 17.6 CMV retinitis, 5.9 CM, 5.9 MAI, 5.9
Mozambique ³⁸ n=136	26.5	Tinea, 25 KS, 22.2 TB, 16.7 PCP/pneumonitis, 8.3 HSV, 8.3
South Africa ⁷ n=498	22.9	Folliculitis, 27.3 TB, 24.4 HSV, 9.4 VZV, 6.5 Warts, 7.2

Note: The most common IRIS-associated conditions are listed, with proportion of IRIS attributed.

Abbreviations: CM, cryptococcal meningitis; CMV, Cytomegalovirus; HSV, herpes simplex virus; IRIS, immune reconstitution inflammatory syndrome; KS, Kaposi's sarcoma; MAI, *Mycobacterium avium-intracellulare*; PCP, *Pneumocystis jirovecii* pneumonia; TB, tuberculosis; VZV, Varicella zoster virus.

inflammation, which is notably absent in untreated advanced HIV, suggests enhanced macrophage activity during immune reconstitution.⁶³ A fatal case of unmasking TB-IRIS associated with a pronounced macrophage-dominated pulmonary infiltrate on postmortem has been reported.⁶⁴ Suppurative inflammation may develop in IRIS, which suggests heightened neutrophil activity.^{60,65} Several studies have reported increased inflammatory cytokines and chemokines of myeloid origin present at, and prior to, IRIS development, evident in serum and on restimulation of cells *ex vivo* with antigen.^{45,66,67} A cross-sectional study of peripheral blood mononuclear cell responses reported elevated matrix metalloproteinase (MMP) transcripts in TB-IRIS patients compared to controls, accompanied by elevated serum concentrations of MMP-7.⁶⁸ MMPs are host

Table 3 Risk factors for HIV-associated IRIS

	Risk factor
Host-related	Low CD4 count at initiation of ART Opportunistic infection or TB prior to ART initiation Genetic predisposition: eg, <i>HLA-A, -B44, -DR4</i> (associated with herpes virus IRIS); <i>TNFA-308*I, IL6-174*G</i> (associated with mycobacterial IRIS) Paucity of immune response at OI diagnosis (in the case of C-IRIS)
Pathogen-related	Degree of dissemination of OI/burden of infection (eg, TB, KS, cryptococcosis) High pre-ART HIV viral load
Treatment-related	Shorter duration of OI treatment prior to starting ART (paradoxical IRIS) Rapid suppression of HIV viral load

Abbreviations: ART, antiretroviral therapy; C-IRIS, cryptococcal-associated IRIS; IRIS, immune reconstitution inflammatory syndrome; KS, Kaposi's sarcoma; OI, opportunistic infection; TB, tuberculosis.

enzymes that are upregulated in response to TB infection, mainly myeloid and epithelial cell derived and activated by proinflammatory cytokines.⁶⁹⁻⁷² They are capable of breaking down and remodeling extracellular matrix, and may contribute to tissue damage in IRIS.

Two studies have examined NK cell function in TB-IRIS. In a study of unmasking IRIS, these cells were found to express increased activation markers.⁷³ In a longitudinal study, NK cells isolated from paradoxical TB-IRIS patients had higher expression of CD107a, a degranulation marker, than non-IRIS controls, prior to IRIS onset.⁷⁴ The authors hypothesized that increased NK cell-mediated lysis of *M.tb*-infected cells may increase antigen load.⁷⁴

In summary, recent evidence suggests that innate immune dysfunction in the context of high antigen load plays a role in driving pathological proinflammatory responses in IRIS. The role of pathogen-specific cell-mediated immunity and regulatory mechanisms are less clear (see Figure 2). Studies of patients are frequently limited by small sample size and examination of peripheral blood rather than tissue immune responses. Development of animal models of IRIS may better allow dissection of precise pathophysiological mechanisms, which may differ for paradoxical and unmasking IRIS, and for different forms of pathogen-associated IRIS.⁷⁵

Clinical manifestations

The time of onset of IRIS symptoms is variable, but is typically from a few days to 6 months after ART initiation. Although presentation varies by associated pathogen, a common feature is that onset is usually acute and there are features of inflammation, which may be generalized (eg, fever, tachycardia) or

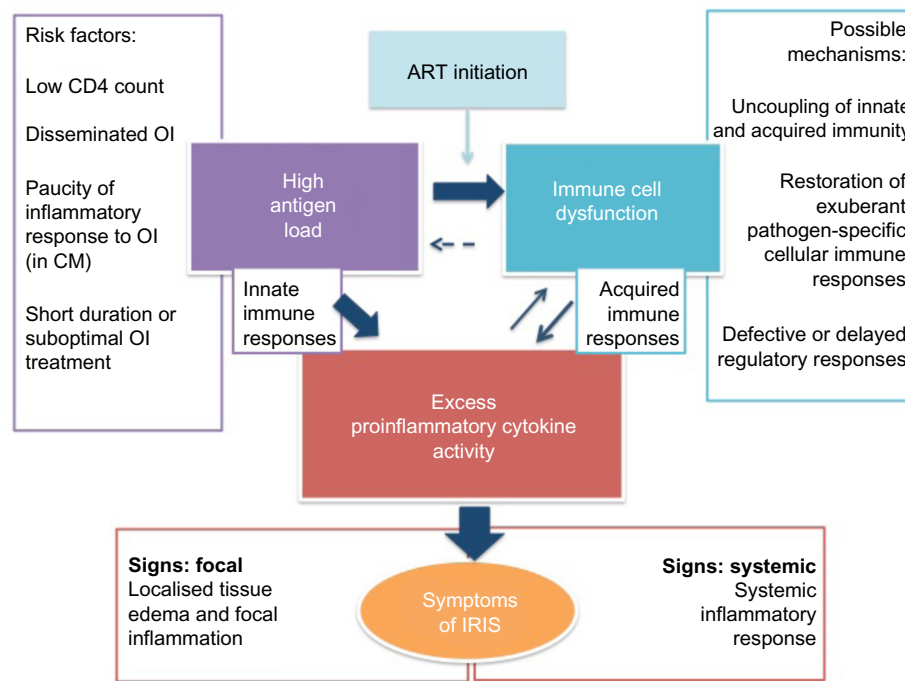


Figure 2 A conceptual model of immune reconstitution inflammatory syndrome (IRIS) pathophysiology with three key features represented in central rectangles.

Notes: Excess antigen is a feature of tuberculosis (TB) IRIS, cryptococcal IRIS and Kaposi's sarcoma IRIS. This may result from extreme immunosuppression prior to antiretroviral therapy (ART) initiation, which increases the risk of opportunistic infection (OI) dissemination (in TB), and is associated with paucity of inflammation in cryptococcal meningitis (CM), especially in those patients who go on to develop IRIS. Antigen is likely to be more abundant if the OI is untreated, or if treatment has recently started. Immune cell dysfunction following ART has been described in IRIS, although the mechanism of this is incompletely understood. It may involve uncoupling of innate and acquired immune responses, restoration of exuberant pathogen-specific cellular responses, and defective or delayed regulatory responses. An excess of proinflammatory cytokines has been associated with TB-IRIS, and cryptococcal IRIS, in blood and cerebrospinal fluid. Possible relationships between the three key components are depicted by differentially weighted arrows. However, the direction of causality is not clear. It is probable that the presence of high antigen in IRIS drives proinflammatory cytokine responses directly through stimulation of innate immune responses and indirectly when adaptive immunity recovers. Further studies are required to improve understanding of these interactions.

localized (eg, lymphadenitis). In paradoxical IRIS, symptoms of the previously diagnosed OI may recur or worsen, but a clear improvement is usually reported after the start of OI treatment prior to starting ART (see Figure 1). The original descriptions of MAI-IRIS reported that mycobacteraemia, which was typical of MAI in advanced HIV pre-ART, was not typical of MAI-IRIS, which was characterized by focal lymphadenitis and paucity of bacteria. In severe forms of IRIS (eg, TB-IRIS, CMV immune restoration uveitis, and C-IRIS), paucity of viable pathogen is characteristic at the time of IRIS, despite severe inflammation. Clinical features associated with different forms of IRIS are summarized in Table 1 and described in more detail in subsequent sections.

Management and prevention of IRIS

As IRIS is antigen-driven, optimization of treatment of the underlying OI is an important aspect of treatment in many forms of IRIS (see following sections on KS-IRIS and C-IRIS), in order to quickly reduce pathogen load.⁷⁶ Supportive management may be required, including intravenous fluids and oxygen.⁷⁷ ART is key to eventual immune recovery

and we recommend that ART should not be interrupted unless there is concern about concurrent drug toxicity, in which case ART substitution is preferable. There has been no trial of ART cessation in management of IRIS. ART interruption may also be considered in severe, life-threatening cases of CNS IRIS, in patients with a depressed level of consciousness. However, the undesirable effects of stopping ART include a risk of further OI and the emergence of ART resistance.

Various anti-inflammatory agents have been used in treatment of paradoxical and unmasking IRIS, including corticosteroids and nonsteroidal anti-inflammatory drugs (NSAIDs). A randomized controlled trial of oral prednisone for paradoxical TB-IRIS showed benefit, and this is discussed in more detail in the section on TB-IRIS. Use of corticosteroids in other forms of IRIS is based solely on expert opinion. Systemic corticosteroid use is associated with a number of potential adverse effects in HIV, including infective complications, such as reactivation of herpes virus infections, KS progression, and mucocutaneous candidiasis.^{76,78,79} Additionally, noninfective conditions are associated with chronic oral corticosteroid use, including hyperglycemia, hypertension,

Table 4 Clinical characteristics of TB-IRIS and C-IRIS

	TB-IRIS	C-IRIS
Incidence	2%–54%	13%–45%
Key risk factors	Shorter duration from TB treatment initiation to ART initiation Disseminated TB at diagnosis Low CD4 count prior to ART	Markers of fungal burden <ul style="list-style-type: none"> • Fungemia • Higher CrAg titer Lack of CNS inflammation prior to ART
Onset	<3 months Median 14 days	<12 months Median 4–9 weeks
Differential diagnosis	Drug-resistant TB Drug toxicity Another OI Poor adherence to therapy	Relapse of CM Fluconazole resistance Another OI
Key investigations	Cultures/molecular testing for drug resistance (eg, GeneXpert on sputum, CSF culture if CNS symptoms) Consider other infections (eg, unmasking OI)	CSF fungal culture: CSF may not be culture-negative, especially where fluconazole monotherapy is used for treatment of CM Positive fungal culture after 3 months of antifungal therapy likely indicates treatment failure rather than IRIS Note: CrAg titers (serum or CSF) are not helpful
Treatment	Prednisone 1.5 mg/kg for 14 days, followed by 0.75 mg/kg for 14 days or reduced according to clinical response	No evidence to support steroid use Optimize/strengthen antifungal therapy Therapeutic lumbar punctures to relieve raised intracranial pressure Steroids if severe or refractory

Abbreviations: ART, antiretroviral therapy; C-IRIS, cryptococcal-associated IRIS; CM, cryptococcal meningitis; CNS, central nervous system; CrAg, cryptococcal antigen; CSF, cerebrospinal fluid; IRIS, immune reconstitution inflammatory syndrome; OI, opportunistic infection; TB, tuberculosis; TB-IRIS, tuberculosis-associated IRIS.

osteoporosis, and gastrointestinal ulceration. Therefore, aside from cases of TB-IRIS, systemic corticosteroids are recommended for more severe forms of IRIS inflammation, in the absence of contraindications, and more commonly for mycobacterial and fungal-associated IRIS than for viral-associated IRIS. Periocular or intravitreal corticosteroids have been used to treat immune restoration uveitis.⁸⁰ NSAIDs are used in milder forms of IRIS, and are not associated with reactivation of other infections, but their efficacy has not been tested by clinical trials. Gastrointestinal irritation and nephrotoxicity are a concern in chronic NSAID usage.

Adjunctive oral corticosteroids are routinely prescribed with TB treatment for certain forms of TB (pericardial and CNS TB). TBM-IRIS may develop despite corticosteroid therapy.⁵¹ The principles of IRIS prevention include optimal prophylaxis of OI in advanced HIV (eg, cotrimoxazole to prevent *Pneumocystis jirovecii* pneumonia [PCP]), optimal screening for subclinical OI prior to ART initiation (eg, for serum cryptococcal antigen in patients with CD4 <100), reduction of risk factors for IRIS where possible (see Table 3), and optimal timing of ART initiation informed by clinical trial data for that pathogen (see discussion on TB-IRIS and C-IRIS in following sections).

In the next section, we examine in more detail three common and clinically important forms of IRIS, highlighting clinical features, pathophysiology, and management

issues. We then briefly discuss other common forms of IRIS. Reviews of pulmonary and CNS manifestations of IRIS and IRIS management have recently been published.^{25,76,81,82} The clinical characteristics of TB-IRIS and C-IRIS are summarized in Table 4.

TB-IRIS

TB-IRIS is among the commonest forms of IRIS given the global distribution of TB infection (Table 2). Paradoxical TB-IRIS was reported to occur in 15.7% (95% credibility interval 9.7%–24.5%) of TB patients starting ART in the previously described meta-analysis by Müller et al,⁹ which reported on 16 studies of TB-IRIS, although higher rates are reported in some settings.^{9,83} For example, in a recent Indian study, an incidence of 54.2% was reported in patients with culture-confirmed pulmonary TB and a South African study reported 47% incidence of paradoxical TB-IRIS in patients with TBM.^{51,84} In South Africa, where more than 60% of TB patients are HIV coinfecting, this translates into a considerable disease burden.⁸⁵

Both paradoxical and unmasking forms of TB-IRIS are now widely reported, although paradoxical IRIS has been more extensively studied.^{28,83,86} Paradoxical TB-IRIS typically presents in pulmonary TB cases as a recurrence or worsening of respiratory symptoms (cough or shortness of breath), associated with a recurrence or worsening of

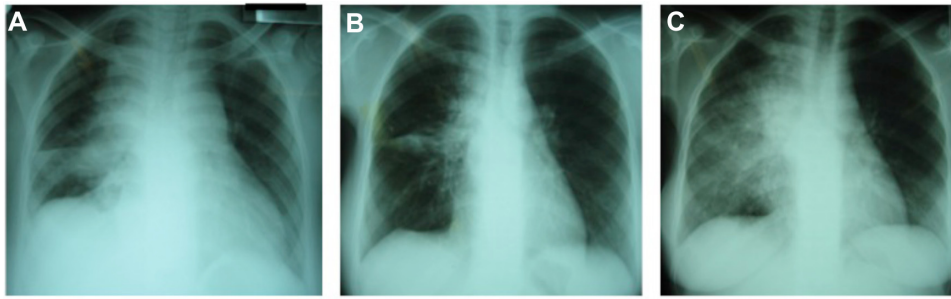


Figure 3 This series of three chest radiographs demonstrates features of paradoxical tuberculosis (TB) immune reconstitution inflammatory syndrome in a 21-year-old antiretroviral therapy (ART)-naïve patient, with CD4 count 34 cells/mm³, who was diagnosed with drug-sensitive pulmonary TB on sputum culture.

Notes: At TB diagnosis, chest radiograph showed bilateral hilar and mediastinal lymphadenopathy, right middle and right upper lobe infiltrates, and a right-sided pleural effusion (A). These abnormalities improved with TB therapy (B) and 10 weeks later ART was initiated. Nine days following ART initiation, she presented with recurrence of cough, right-sided chest pain, fatigue, and weight loss. On examination, tachycardia, tachypnea, and tender hepatomegaly were observed. CD4 count had increased to 161 cells/mm³. Chest radiograph showed a marked deterioration, particularly of the right-sided pulmonary infiltrates, which became more extensive than at the time of initial presentation with TB (C).

constitutional symptoms (weight loss, night sweats, fever), and not uncommonly new or expanding infiltrates on chest radiograph, as shown in Figure 3.⁸⁷ Paradoxical IRIS may occur at any disease site, including lymph nodes, which typically manifests with rapid enlargement followed by suppuration.⁷⁶ CNS TB-IRIS typically presents with new or worsening meningitis and/or features of raised intracranial pressure, due to enlarging cerebral tuberculomas or intracranial abscesses, with a high mortality.^{42,82,88} It may also present with epidural abscesses, spondylitis, and radiculomyelopathy.^{51,88} Hepatosplenic (typically granulomatous disease leading to hepatitis and/or appearance of microabscesses), abdominal (eg, lymphadenopathy, peritonitis), and musculoskeletal (eg, mono- or polyarthritides) features are not infrequent.⁸³ Extrapulmonary TB-IRIS manifestations may occur in patients who originally presented with pulmonary TB, and vice versa. Accompanying laboratory features usually include a raised CRP, and may include worsening anemia.

The differential diagnosis of TB-IRIS includes other new infections (eg, pneumonia, influenza), unmasking of other OI (eg, PCP), drug reactions (eg, pyrazinamide arthropathy), and multidrug-resistant TB.⁸⁹ In resource-limited settings, where *M.tb* drug-susceptibility testing is not routinely available, the latter is difficult to exclude. Additionally, TB-IRIS may occur in cases of drug-resistant TB.⁸⁹ There is no laboratory test for TB-IRIS and exclusion of differential diagnoses with certainty can be very challenging in practice.

The only randomized placebo-controlled trial of treatment of IRIS was conducted in patients with paradoxical TB-IRIS, in South Africa.⁹⁰ One hundred and ten patients were enrolled with a median CD4 count of 116 cells/mm³ and paradoxical TB-IRIS diagnosed according to INSHI criteria¹⁹, limited to those with increasing infiltrates on chest radiograph, enlarging

lymph nodes, serous effusion, or cold abscess. Patients with immediately life-threatening manifestations of TB-IRIS (respiratory failure, altered level of consciousness, new focal neurological sign/s, or compression of a vital structure) were excluded from the study. The intervention arm (n=55) consisted of prednisone 1.5 mg/kg/day for 14 days, reduced to 0.75 mg/kg/day for a further 14 days. This led to a reduction in the composite primary endpoint of days of hospitalization and outpatient therapeutic procedures (median per patient 0 versus 3 in placebo arm, $P=0.04$). There was also more rapid improvement in symptom scores and chest radiographs in prednisone, compared to placebo-treated, patients. There were more mild infections (eg, oral candidiasis) in the prednisone-treated arm, but no excess of severe infections. There were no significant differences in possible drug-related side effects reported in each arm. These data support use of prednisone in TB-IRIS, for moderate and severe cases. Unfortunately, TB-IRIS symptoms may recur following steroid withdrawal, requiring longer courses of treatment.^{90,91} Other immunomodulatory therapies have been considered in management of TB-IRIS, with case reports of favorable outcomes with thalidomide and montelukast, but none has been tested in randomized controlled trials (RCTs).^{76,77,92,93}

Strategies for TB-IRIS prevention have focused on optimizing the timing of ART initiation, after it was observed that a shorter time between TB treatment initiation and ART initiation increased TB-IRIS risk. Three RCTs that studied the optimal timing of ART in TB patients have informed practice.^{94–96} These trials demonstrated that in patients with a CD4 count <50 cells/mm³, starting ART around 2 weeks after TB treatment reduced mortality or a combined endpoint of mortality and AIDS progression. Thus, while commencing ART earlier is associated with increased IRIS risk, the survival benefit in these patients with low CD4 counts overrides this. However,

in patients with CD4 >50 cells/mm³, ART can be commenced between 2 and 8 weeks post-TB treatment, and delaying to 8 weeks is not associated with excess mortality, but may reduce IRIS risk. A recent placebo-controlled study of ART timing in smear-positive pulmonary TB patients with CD4 count >220 cells/mm³ demonstrated no benefit in a combined endpoint of TB treatment failure, TB recurrence, and mortality, when ART was commenced at 2 weeks post-TB treatment initiation, compared to delaying until after TB treatment was completed. IRIS rates were similar in the early and late arms (10%).⁹⁷ A single RCT of ART timing in TBM demonstrated no survival benefit from starting ART within 7 days of commencing TB therapy, compared to following 2 months of TB treatment, and an increased probability of serious adverse events.⁹⁸ As a result, it is recommended that ART initiation be delayed until 8 weeks after TB therapy is commenced in TBM patients.⁴³

In environments with a high incidence of both TB infection and HIV infection, a significant proportion of undiagnosed TB may be diagnosed by routine screening of all HIV-infected patients entering care, by sputum culture or GeneXpert (the latter being less sensitive), even those who are asymptomatic. Isoniazid preventive therapy may be indicated for those who do not have active disease. Strategies such as these are likely to reduce the prevalence of undiagnosed TB in patients starting ART and thus may reduce risk of unmasking TB-IRIS.⁶⁵ This could be performed alongside ART counseling, but should not unnecessarily delay commencement of ART in immunosuppressed patients. There are considerable logistic and financial challenges to implementing such a strategy in programmatic settings. The World Health Organization currently recommends an approach based on symptom screening, to identify active TB in HIV-infected individuals, in resource-constrained settings.⁸⁵ However, the performance of this strategy varies across different clinical settings.⁹⁹

There have been no successful trials of preventive strategies for paradoxical TB-IRIS, although two randomized placebo-controlled trials for paradoxical TB-IRIS prevention are currently under way in South Africa. A randomized placebo-controlled trial of prednisone for TB-IRIS prevention in high-risk patients is recruiting patients in Cape Town (NCT01924286). The TB-IRIS NSAID Cox-2 Inhibitor Prevention Trial is investigating meloxicam for TB-IRIS prevention (NCT02060006).

Cryptococcal IRIS

Paradoxical C-IRIS is reported to occur in 13%–45% of HIV-infected persons who start ART after treatment for CM. It occurs a median of 4–9 weeks following ART initiation but

delayed cases have been reported up to a year after initiation of ART.^{46,100–102} The usual presentation is a recurrence of meningitis symptoms (headache, nuchal rigidity, visual disturbance, and vomiting) along with other CNS signs, such as raised intracranial pressure, impaired consciousness, seizures, and focal neurology. Non-neurological presentations are less commonly described but include lymphadenitis, pneumonitis, and eye and soft tissue disease.¹⁸

As with other neurological forms of IRIS, C-IRIS causes substantial morbidity and mortality (13%–36%) and is an independent predictor of death in CM patients starting ART.⁴⁶ The risk of developing C-IRIS is increased in individuals who have high CSF fungal burdens during the initial episode of CM, and in those who fail to clear the infection prior to the initiation of ART.¹⁰³ In one study, lower pre-ART CD4 count was also associated with increased risk of C-IRIS.¹⁰⁴

Diagnosis of paradoxical C-IRIS is based on INSHI criteria with diagnostic workup targeted at excluding other causes.¹⁸ In patients presenting with recurrent meningitis symptoms, a lumbar puncture should be performed and the opening pressure measured; CSF should be sent for bacterial, mycobacterial, and fungal culture to exclude relapsed CM and an alternative cause of meningitis.⁷⁶

As there have been no clinical trials, management of suspected paradoxical C-IRIS is based solely on expert opinion. Reduction of pathogen load is an underlying objective and cryptococcal treatment should be optimized. Raised intracranial pressure can be controlled with therapeutic CSF drainage by lumbar puncture (repeated daily if necessary). Corticosteroids can be considered in severe cases, preferably once other etiologies are excluded and CSF fungal culture result is known to be negative. In patients with life-threatening neurological deterioration, steroids should be started immediately while simultaneously treating with amphotericin B to cover the possibility of a cryptococcal relapse.⁷⁶

The timing of ART initiation in patients with CM has been examined in four trials to date.^{105,107–109} The first recruited 282 patients, mainly from USA, with a variety of AIDS-related OI, of which 12% had CM.¹⁰⁵ The overall trial result showed that early ART (within 14 days of OI treatment) was associated with a reduced likelihood of AIDS progression or death, compared to ART initiation after OI treatment completion, with no excess risk of IRIS. When the CM patients were analyzed separately, the point estimate showed a trend toward improved outcome in the early arm.^{105,106} A small study of CM patients in Botswana (n=27) compared early ART (within 7 days) with deferred ART (after 28 days), using intravenous amphotericin

B as antifungal treatment. Similar to the US study, no difference in mortality was noted; however, early ART was associated with significantly increased IRIS risk.¹⁰⁷

An open-label randomized trial in Zimbabwe was conducted comparing ART within 72 hours of CM treatment initiation (fluconazole 800 mg per day) with ART initiation after 10 weeks.¹⁰⁸ The trial was stopped early by the data safety monitoring board after excess deaths were noted in the early treatment arm, mainly during the first 2 weeks of ART. The authors suggested IRIS to be the likely cause.¹⁰⁸

The Cryptococcal Optimal ART Timing (COAT) trial was conducted to definitively address the question of when to start ART in CM, using amphotericin B-based anticytotoxic therapy.¹⁰⁹ This was an open-label randomized trial conducted in Uganda and South Africa. ART-naïve patients with a first episode of CM were randomized to early ART initiation (7–14 days after starting amphotericin), or deferred (after 5 weeks). This trial was also stopped early by the data safety monitoring board after significantly increased mortality was noted in the early ART arm (6-month mortality 45% versus 30%, hazard ratio 1.7; 95% confidence interval [CI]: 1.1–2.8; $P=0.03$).¹⁰⁹ The explanation for this excess mortality was not clear; excess deaths all occurred within a month of starting ART, but reported rates of IRIS were not statistically different between the two study arms, nor was drug toxicity. Specific risk factors for death during early ART included altered mental status at time of randomization (hazard ratio 3.0; 95% CI: 1.0–8.8) and failure to mount a cellular response in the CSF (CSF white cell count <5 cells/mm³) (hazard ratio 3.3; 95% CI: 1.3–8.4).¹⁰⁹ Given that paucity of CSF inflammatory response has previously been associated with failure to sterilize the CSF and increased risk of IRIS, it seems plausible that immunopathology may underlie these excess deaths. Following these trials, guidelines for CM now suggest clinicians wait 4–6 weeks after commencing amphotericin B-based CM treatment, before ART is initiated in CM patients.¹¹⁰

In addition to paradoxical C-IRIS, presentation with a new diagnosis of CM shortly after starting ART is also well described, occurring in up to 1% of patients starting ART and in up to 33% of those who have a cryptococcal antigenemia at time of ART initiation.^{17,111–116} However, whether this occurs due to a persisting immune deficiency or an unmasking C-IRIS can be difficult to determine and has not been widely studied. INSHI provide case definitions for both ART-associated CM and unmasking C-IRIS and suggest unmasking C-IRIS should be considered if there are “unusual, exaggerated, or heightened

inflammatory manifestations” (eg, CSF white cell count >50 cells/ μ L, persistently raised intracranial pressure refractory to therapy, rapidly expanding CNS lesion, painful or suppurating lymphadenopathy, pneumonitis, granulomatous inflammation on histology).¹⁸

Persons who develop such ART-associated cryptococcosis should be managed in the same way as patients not taking ART: potent antifungal therapy to reduce antigen load seems intuitive, and therapeutic lumbar puncture to control raised intracranial pressure is frequently required for the life-threatening complication of raised intracranial pressure.¹¹⁷

KS-related IRIS

KS is an HIV-associated malignancy that is driven by replication of human herpes virus-8 (HHV-8), occurring most commonly in regions where there is high prevalence of HHV-8. It is the commonest malignancy associated with HIV infection.¹¹⁸ Patients typically present with localized or extensive mucocutaneous, hyperpigmented lesions, often with edema, most commonly affecting the skin but also frequently the oral mucosa. As a malignancy of lymphatic endothelium, it is capable of causing disseminated disease and may affect the lungs and gastrointestinal tract.¹¹⁹ No specific anti-HHV-8 agent has been shown to be effective, so treatment is limited to reversal of immune suppression with ART and cytotoxic chemotherapeutic agents when disease is extensive.

Paradoxical KS-IRIS occurs when ART is initiated in 7%–31% of cases. This variation is probably related to differences in severity of KS, degree of immunosuppression, and treatment availability in different settings.^{40,120,121} KS-IRIS frequently presents with inflammation or enlargement of an existing KS lesion and/or worsening edema. Alternatively, during IRIS, KS may extend or appear rapidly at new anatomical sites. Symptoms and signs vary according to the site of the KS lesion. Acute airway obstruction may occur and can be life-threatening.⁷⁹ Significant gastrointestinal bleeding may occur. Rapid extension of pulmonary lesions, may mimic an infective pulmonary process.²⁵ Onset is between 1 and 22 weeks, and usually in the first 12 weeks post-ART initiation.^{40,120,122}

Little is known about the pathogenesis of KS-IRIS. Proinflammatory and Th1 cytokines are considered to be important in KS pathogenesis.¹²³ Increased KS-IRIS risk is associated with use of ART alone as initial KS treatment, more extensive baseline KS tumor stage, baseline plasma HIV-1 RNA more than 10^5 copies/mL, and baseline detectable plasma HHV-8 DNA.⁴⁰

Treatment for KS-IRIS includes systemic chemotherapy and supportive measures, eg, radiotherapy should airway obstruction occur. Liposomal anthracyclines (eg, doxorubicin) are the preferred first-line chemotherapeutic agents for KS and may be indicated in KS-IRIS where available. Corticosteroids may be harmful as there is an association with acute progression of KS lesions, possibly due to a permissive effect on HHV-8 viral replication.⁷⁹ ART should be continued. Use of systemic chemotherapy for extensive disease prior to ART initiation may help prevent KS-IRIS, but this has not been systematically studied.

Mucocutaneous IRIS

Mucocutaneous conditions caused by viruses, such as herpes simplex virus causing genital ulceration, varicella zoster virus reactivation, molluscum contagiosum virus, and human papilloma virus, in addition to mucocutaneous fungal infections (eg, candida, tinea) collectively form the most common type of IRIS reported in many series (see Table 2).^{21,36–38} Other cutaneous manifestations include worsening of pruritic papular eruption and acne flares.^{7,21} Management typically involves targeting the causative organism where a treatment is available (eg, acyclovir for herpes simplex virus) and symptomatic treatment. No evidence-based guidelines are available. Although common and distressing for patients, these forms of IRIS are rarely severe.

CNS IRIS

CNS IRIS contributes the bulk of IRIS mortality.⁸¹ In addition to C-IRIS and TBM-IRIS (discussed above), progressive multifocal leukoencephalopathy (PML) IRIS and, less commonly, IRIS-associated with cerebral toxoplasmosis, have been described.^{24,26} PML-IRIS has been reviewed in detail recently by Post et al, who highlight a role for neuroimaging in PML-IRIS diagnosis, with contrast enhancement of lesions and mass effect due to interstitial edema in PML-IRIS, not typically found in PML.¹²⁴ Neuroimaging is not available in many settings and autopsy studies suggest that PML is underdiagnosed, so it is probable that PML-IRIS is also underdiagnosed.¹²⁵ Corticosteroids are used in cases of PML-IRIS, although there are no RCT data to support this. A recently published case report described use of maraviroc, a CCR5 antagonist, in an HIV-uninfected patient with PML-IRIS, with a favorable outcome, but efficacy has not yet been assessed in a clinical trial.¹²⁶

CNS IRIS has also been described in cases with no evidence of an OI, where it is hypothesized that the reconstituting immune response targets CNS HIV proteins or alternatively

host antigens, the latter an autoimmune process.^{127,128} A CD8 (rather than a CD4) lymphocyte infiltration in the perivascular spaces characterizes this condition. Significant mortality is reported. Corticosteroids have been used in some cases, with favorable outcome.¹²⁹

HIV-associated IRIS – other infectious causes

A wide variety of infectious pathogens have been linked to HIV-associated IRIS (Table 1). CMV reactivation is associated with advanced immune suppression (CD4 count below 50 cells/mm³), most commonly causing retinitis, which may lead to permanent visual impairment. Immune restoration uveitis may occur following ART initiation in such patients and can be sight-threatening. In HIV–hepatitis B virus coinfecting patients, an acute hepatitis flare (with potentially fulminant course) may occur post-ART initiation, and may be difficult to distinguish from ART drug toxicity.¹³⁰ *P. jirovecii* is a common fungal cause of IRIS. Calligaro et al have reviewed PCP-IRIS and other pulmonary IRIS manifestations in more detail.²⁵ Lawn has reviewed 24 cases of IRIS associated with parasitic infections, including *Schistosoma mansoni*, *Strongyloides stercoralis*, *Leishmania* spp., and *Toxoplasma gondii*.²⁶

Summary and conclusion

Access to ART is improving worldwide, but because many patients still commence ART with low CD4 counts, IRIS remains a common complication. IRIS is a heterogeneous condition with a number of case definitions in use. Clinical manifestations and epidemiology are well described for some forms of IRIS, but specific diagnostic tests and evidence-based treatment strategies are lacking. CNS IRIS is associated with a high mortality and requires more effective interventions. While ART initiation causes IRIS, it is key to recovery of immune function and improved health outcomes, therefore delay or discontinuation of ART due to IRIS is not usually recommended. A notable exception is in patients with CM, in whom ART should be delayed until 4–6 weeks after CM treatment initiation. Prevention strategies include: 1) treatment of HIV before advanced immunosuppression develops; 2) OI prevention in advanced HIV; 3) screening for and treatment of OI prior to ART initiation; and 4) optimal timing of ART initiation (this varies according to pathogen and CD4 count and takes into account mortality and IRIS risk). Treatment of IRIS involves optimal treatment of the underlying pathogen to reduce antigen load; supportive measures; and, in some cases, immunosuppression with corticosteroids.

Key knowledge gaps in the diagnosis and treatment of IRIS exist. There are no standardized clinical case definitions for many forms of IRIS (TB-IRIS and C-IRIS being the exceptions). Confirmatory diagnostic tests are lacking for all forms of IRIS. Most forms of IRIS lack evidence-based management strategies, the use of prednisone in TB-IRIS being the exception. For all forms of IRIS, other immunomodulatory therapies have not been systematically studied. The specific cell phenotypes and inflammatory and regulatory pathways that are central in the development of IRIS, in the context of an abundance of foreign antigen, need to be more clearly defined. Improved understanding of the pathophysiology of IRIS will hopefully enable improved diagnostic modalities and better targeted treatments to be developed.

Acknowledgments

This work was supported by the Medical Research Council (U1175.02.002.00014.01), Wellcome Trust (references 084323, 088316, 094000, 094013, and 098316), and the European Union (PIRSES-GA-2011-295214, and FP7 HEALTH-F3-2012-305578). Graeme Meintjes was supported in part by the National Research Foundation (NRF) of South Africa [UID: 85858]. The grant holders acknowledge that opinions, findings, and conclusions or recommendations expressed in any publication generated by the NRF-supported research are those of the authors, and that the NRF accepts no liability whatsoever in this regard.

Disclosure

The authors report no conflicts of interest in this work.

References

1. Palella FJ Jr, Delaney KM, Moorman AC, et al. Declining morbidity and mortality among patients with advanced human immunodeficiency virus infection. HIV Outpatient Study Investigators. *N Engl J Med*. 1998;338(13):853–860.
2. Jacobson MA, French M. Altered natural history of AIDS-related opportunistic infections in the era of potent combination antiretroviral therapy. *AIDS*. 1998;12 Suppl A:S157–S163.
3. World Health Organization. *Global update on HIV treatment 2013: Results, impact and opportunities*. Geneva: World Health Organization; 2013. Available from: <http://www.who.int/hiv/pub/progressreports/update2013/en/>. Accessed December 3, 2013.
4. Bor J, Herbst AJ, Newell ML, Barnighausen T. Increases in adult life expectancy in rural South Africa: valuing the scale-up of HIV treatment. *Science*. 2013;339(6122):961–965.
5. World Health Organization. *March 2014 supplement to the 2013 consolidated guidelines on the use of antiretroviral drugs for treating and preventing HIV infection*. Geneva: World Health Organization; 2014. Available from: http://www.who.int/hiv/pub/guidelines/arv2013/arvs2013update_march2014/en/. Accessed February 28, 2014.

6. World Health Organization. *Treatment of tuberculosis: guidelines for national programmes*. Geneva: World Health Organization; 2010. Available from: http://www.who.int/tb/features_archive/new_treatment_guidelines_may2010/en/. Accessed February 22, 2014.
7. Haddow LJ, Moosa MY, Mosam A, Moodley P, Parboosing R, Easterbrook PJ. Incidence, clinical spectrum, risk factors and impact of HIV-associated immune reconstitution inflammatory syndrome in South Africa. *PLoS One*. 2012;7(11):e40623.
8. Braitstein P, Brinkhof MW, Dabis F, et al; Antiretroviral Therapy in Lower Income Countries (ART-LINC) Collaboration; ART Cohort Collaboration (ART-CC) groups. Mortality of HIV-1-infected patients in the first year of antiretroviral therapy: comparison between low-income and high-income countries. *Lancet*. 2006;367(9513):817–824.
9. Müller M, Wandel S, Colebunders R, Attia S, Furrer H, Egger M; IeDEA Southern and Central Africa. Immune reconstitution inflammatory syndrome in patients starting antiretroviral therapy for HIV infection: a systematic review and meta-analysis. *Lancet Infect Dis*. 2010;10(4):251–261.
10. Sun HY, Singh N. Opportunistic infection-associated immune reconstitution syndrome in transplant recipients. *Clin Infect Dis*. 2011;53(2): 168–176.
11. Fine AJ, Sorbello A, Kortepeter C, Scarazzini L. Progressive multifocal leukoencephalopathy after natalizumab discontinuation. *Ann Neurol*. 2014;75(1):108–115.
12. Cadena J, Thompson GR 3rd, Ho TT, Medina E, Hughes DW, Patterson TF. Immune reconstitution inflammatory syndrome after cessation of the tumor necrosis factor alpha blocker adalimumab in cryptococcal pneumonia. *Diagn Microbiol Infect Dis*. 2009;64(3):327–330.
13. Miceli MH, Maertens J, Buvé K, et al. Immune reconstitution inflammatory syndrome in cancer patients with pulmonary aspergillosis recovering from neutropenia: proof of principle, description, and clinical and research implications. *Cancer*. 2007;110(1):112–120.
14. Jacobson MA, McGrath MS, Joseph P, Molaghan JB, Tadealli S, Quinn R. Zidovudine-induced fever. *J Acquir Immune Defic Syndr*. 1989;2(4):382–388.
15. French MA, Price P, Stone SF. Immune restoration disease after antiretroviral therapy. *AIDS*. 2004;18(12):1615–1627.
16. French MA, Mallal SA, Dawkins RL. Zidovudine-induced restoration of cell-mediated immunity to mycobacteria in immunodeficient HIV-infected patients. *AIDS*. 1992;6(11):1293–1297.
17. Haddow LJ, Easterbrook PJ, Mosam A, et al. Defining immune reconstitution inflammatory syndrome: evaluation of expert opinion versus 2 case definitions in a South African cohort. *Clin Infect Dis*. 2009;49(9):1424–1432.
18. Haddow LJ, Colebunders R, Meintjes G, et al; International Network for the Study of HIV-associated IRIS (INSHI). Cryptococcal immune reconstitution inflammatory syndrome in HIV-1-infected individuals: proposed clinical case definitions. *Lancet Infect Dis*. 2010;10(11): 791–802.
19. Meintjes G, Lawn SD, Scano F, et al; International Network for the Study of HIV-associated IRIS. Tuberculosis-associated immune reconstitution inflammatory syndrome: case definitions for use in resource-limited settings. *Lancet Infect Dis*. 2008;8(8):516–523.
20. Letang E, Naniche D, Bower M, Miro JM. Kaposi sarcoma-associated immune reconstitution inflammatory syndrome: in need of a specific case definition. *Clin Infect Dis*. 2012;55(1):157–158.
21. Novak RM, Richardson JT, Buchacz K, et al; HIV Outpatient Study (HOPS) Investigators. Immune reconstitution inflammatory syndrome: incidence and implications for mortality. *AIDS*. 2012;26(6):721–730.
22. Huruy K, Mulu A, Mengistu G, et al. Immune reconstitution inflammatory syndrome among HIV/AIDS patients during highly active antiretroviral therapy in Addis Ababa, Ethiopia. *Jpn J Infect Dis*. 2008;61(3):205–209.
23. Meintjes G, Boule A. Immune reconstitution inflammatory syndrome in a large multicenter cohort study: case definition and comparability. *Expert Rev Anti Infect Ther*. 2012;10(7):737–741.
24. Huis in't Veld D, Sun HY, Hung CC, Colebunders R. The immune reconstitution inflammatory syndrome related to HIV co-infections: a review. *Eur J Clin Microbiol Infect Dis*. 2012;31(6):919–927.

25. Calligaro G, Meintjes G, Mendelson M. Pulmonary manifestations of the immune reconstitution inflammatory syndrome. *Curr Opin Pulm Med*. 2011;17(3):180–188.
26. Lawn SD. Immune reconstitution disease associated with parasitic infections following initiation of antiretroviral therapy. *Curr Opin Infect Dis*. 2007;20(5):482–488.
27. Dhasmana DJ, Dheda K, Ravn P, Wilkinson RJ, Meintjes G. Immune reconstitution inflammatory syndrome in HIV-infected patients receiving antiretroviral therapy: pathogenesis, clinical manifestations and management. *Drugs*. 2008;68(2):191–208.
28. Balkhair A, Ahamed S, Sankhla D. Unmasking immune reconstitution inflammatory syndrome (IRIS): a report of five cases and review of the literature. *Sultan Qaboos Univ Med J*. 2011;11(1):95–103.
29. Passos L, Talhari C, Santos M, Ribeiro-Rodrigues R, Ferreira LC, Talhari S. Histoplasmosis-associated immune reconstitution inflammatory syndrome. *Ann Bras Dermatol*. 2011;86(4 Suppl 1):S168–S172. English, Portuguese.
30. Lee CH, Tzao C, Chang TH, et al. Case of pulmonary cryptococcosis mimicking hematogenous metastases in an immunocompetent patient: value of absent 18F-fluorodeoxyglucose uptake on positron emission tomography/CT scan. *Korean J Radiol*. 2013;14(3):540–543.
31. Dets PD, Lockwood DN. Leprosy occurring as immune reconstitution syndrome. *Trans R Soc Trop Med Hyg*. 2008;102(10):966–968.
32. Fukunaga A, Iwamoto Y, Inano S, et al. Immune reconstitution inflammatory syndrome mimics a relapse of AIDS-related Burkitt lymphoma. *Intern Med*. 2013;52(19):2265–2269.
33. Lin RJ, Song J. An unusual cause of chest pain: Mycobacterium avium complex and the immune reconstitution inflammatory syndrome. *J Hosp Med*. 2011;6(5):309–311.
34. Intalaporn P, Poovorawan Y, Suankratay C. Immune reconstitution syndrome associated with parvovirus B19-induced pure red cell aplasia during highly active antiretroviral therapy. *J Infect*. 2006;53(2):e79–e82.
35. Achenbach CJ, Harrington RD, Dhanireddy S, Crane HM, Casper C, Kitahata MM. Paradoxical immune reconstitution inflammatory syndrome in HIV-infected patients treated with combination antiretroviral therapy after AIDS-defining opportunistic infection. *Clin Infect Dis*. 2012;54(3):424–433.
36. Hoyo-Ulloa I, Belauzarán-Zamudio PF, Crabtree-Ramirez B, Galindo-Fraga A, Pérez-Aguinaga ME, Sierra-Madero JG. Impact of the immune reconstitution inflammatory syndrome (IRIS) on mortality and morbidity in HIV-infected patients in Mexico. *Int J Infect Dis*. 2011;15(6):e408–e414.
37. Kumar SR, Gopalan N, Patrawalla P, Menon P, Mayer K, Swaminathan S. Immune reconstitution inflammatory syndrome in HIV-infected patients with and without prior tuberculosis. *Int J STD AIDS*. 2012;23(6):419–423.
38. Letang E, Miró JM, Nhampossa T, et al. Incidence and predictors of immune reconstitution inflammatory syndrome in a rural area of Mozambique. *PLoS One*. 2011;6(2):e16946.
39. Abdool Karim SS. Stigma impedes AIDS prevention. *Nature*. 2011;474(7349):29–31.
40. Letang E, Lewis JJ, Bower M, et al. Immune reconstitution inflammatory syndrome associated with Kaposi sarcoma: higher incidence and mortality in Africa than in the UK. *AIDS*. 2013;27(10):1603–1613.
41. Ablanedo-Terrazas Y, Alvarado-De La Barrera C, Reyes-Terán G. Towards a better understanding of Kaposi sarcoma-associated immune reconstitution inflammatory syndrome. *AIDS*. 2013;27(10):1667–1669.
42. Agarwal U, Kumar A, Behera D, French MA, Price P. Tuberculosis associated immune reconstitution inflammatory syndrome in patients infected with HIV: meningitis a potentially life threatening manifestation. *AIDS Res Ther*. 2012;9(1):17.
43. Török ME, Farrar JJ. When to start antiretroviral therapy in HIV-associated tuberculosis. *N Engl J Med*. 2011;365(16):1538–1540.
44. Pepper DJ, Marais S, Wilkinson RJ, Bhaijee F, De Azevedo V, Meintjes G. Barriers to initiation of antiretrovirals during antituberculosis therapy in Africa. *PLoS One*. 2011;6(5):e19484.
45. Tadokera R, Meintjes G, Skolimowska KH, et al. Hypercytokinaemia accompanies HIV-tuberculosis immune reconstitution inflammatory syndrome. *Eur Respir J*. 2011;37(5):1248–1259.
46. Boulware DR, Meya DB, Bergemann TL, et al. Clinical features and serum biomarkers in HIV immune reconstitution inflammatory syndrome after cryptococcal meningitis: a prospective cohort study. *PLoS Med*. 2010;7(12):e1000384.
47. Conesa-Botella A, Meintjes G, Coussens AK, et al. Corticosteroid therapy, vitamin D status, and inflammatory cytokine profile in the HIV-tuberculosis immune reconstitution inflammatory syndrome. *Clin Infect Dis*. 2012;55(7):1004–1011.
48. Barber DL, Andrade BB, McBerry C, Sereti I, Sher A. Role of IL-6 in Mycobacterium avium – associated immune reconstitution inflammatory syndrome. *J Immunol*. 2014;192(2):676–682.
49. Boulware DR, Bonham SC, Meya DB, et al. Paucity of initial cerebrospinal fluid inflammation in cryptococcal meningitis is associated with subsequent immune reconstitution inflammatory syndrome. *J Infect Dis*. 2010;202(6):962–970.
50. Ruhwald M, Ravn P. Immune reconstitution syndrome in tuberculosis and HIV-co-infected patients: Th1 explosion or cytokine storm? *AIDS*. 2007;21(7):882–884.
51. Marais S, Meintjes G, Pepper DJ, et al. Frequency, severity, and prediction of tuberculous meningitis immune reconstitution inflammatory syndrome. *Clin Infect Dis*. 2013;56(3):450–460.
52. Bourgarit A, Carcelain G, Martinez V, et al. Explosion of tuberculin-specific Th1-responses induces immune restoration syndrome in tuberculosis and HIV co-infected patients. *AIDS*. 2006;20(2):F1–F7.
53. Bourgarit A, Carcelain G, Samri A, et al. Tuberculosis-associated immune restoration syndrome in HIV-1-infected patients involves tuberculin-specific CD4 Th1 cells and KIR-negative gammadelta T cells. *J Immunol*. 2009;183(6):3915–3923.
54. Meintjes G, Wilkinson KA, Rangaka MX, et al. Type 1 helper T cells and FoxP3-positive T cells in HIV-tuberculosis-associated immune reconstitution inflammatory syndrome. *Am J Respir Crit Care Med*. 2008;178(10):1083–1089.
55. Mahnke YD, Greenwald JH, DerSimonian R, et al. Selective expansion of polyfunctional pathogen-specific CD4(+) T cells in HIV-1-infected patients with immune reconstitution inflammatory syndrome. *Blood*. 2012;119(13):3105–3112.
56. Elliott JH, Vohith K, Saramony S, et al. Immunopathogenesis and diagnosis of tuberculosis and tuberculosis-associated immune reconstitution inflammatory syndrome during early antiretroviral therapy. *J Infect Dis*. 2009;200(11):1736–1745.
57. Tieu HV, Ananworanich J, Avihingsanon A, et al. Immunologic markers as predictors of tuberculosis-associated immune reconstitution inflammatory syndrome in HIV and tuberculosis coinfecting persons in Thailand. *AIDS Res Hum Retroviruses*. 2009;25(11):1083–1089.
58. Seddiki N, Sasson SC, Santner-Nanan B, et al. Proliferation of weakly suppressive regulatory CD4+ T cells is associated with over-active CD4+ T-cell responses in HIV-positive patients with mycobacterial immune restoration disease. *Eur J Immunol*. 2009;39(2):391–403.
59. Tan DB, Yong YK, Tan HY, et al. Immunological profiles of immune restoration disease presenting as mycobacterial lymphadenitis and cryptococcal meningitis. *HIV Med*. 2008;9(5):307–316.
60. Lim A, D'Orsogna L, Price P, French MA. Imbalanced effector and regulatory cytokine responses may underlie mycobacterial immune restoration disease. *AIDS Res Ther*. 2008;5:9.
61. Tadokera R, Wilkinson KA, Meintjes GA, et al. Role of the interleukin 10 family of cytokines in patients with immune reconstitution inflammatory syndrome associated with HIV infection and tuberculosis. *J Infect Dis*. 2013;207(7):1148–1156.
62. Barber DL, Andrade BB, Sereti I, Sher A. Immune reconstitution inflammatory syndrome: the trouble with immunity when you had none. *Nat Rev Microbiol*. 2012;10(2):150–156.
63. Walker NF, Meintjes G, Wilkinson RJ. HIV-1 and the immune response to tuberculosis. *Future Virol*. 2013;8(1):57–80.

64. Lawn SD, Wainwright H, Orrell C. Fatal unmasking tuberculosis immune reconstitution disease with bronchiolitis obliterans organizing pneumonia: the role of macrophages. *AIDS*. 2009;23(1):143–145.
65. Lawn SD, Meintjes G. Pathogenesis and prevention of immune reconstitution disease during antiretroviral therapy. *Expert Rev Anti Infect Ther*. 2011;9(4):415–430.
66. Oliver BG, Elliott JH, Price P, et al. Mediators of innate and adaptive immune responses differentially affect immune restoration disease associated with Mycobacterium tuberculosis in HIV patients beginning antiretroviral therapy. *J Infect Dis*. 2010;202(11):1728–1737.
67. Boulware DR, Hullsiek KH, Puroton CE, et al; INSIGHT Study Group. Higher levels of CRP, D-dimer, IL-6, and hyaluronic acid before initiation of antiretroviral therapy (ART) are associated with increased risk of AIDS or death. *J Infect Dis*. 2011;203(11):1637–1646.
68. Tadokera R, Meintjes GA, Wilkinson KA, et al. Matrix metalloproteinases and tissue damage in HIV-tuberculosis immune reconstitution inflammatory syndrome. *Eur J Immunol*. 2014;44(1):127–136.
69. Walker NF, Clark SO, Oni T, et al. Doxycycline and HIV infection suppress tuberculosis-induced matrix metalloproteinases. *Am J Respir Crit Care Med*. 2012;185(9):989–997.
70. Elkington PT, Ugarte-Gil CA, Friedland JS. Matrix metalloproteinases in tuberculosis. *Eur Respir J*. 2011;38(2):456–464.
71. Elkington PT, Green JA, Friedland JS. Analysis of matrix metalloproteinase secretion by macrophages. *Methods Mol Biol*. 2009;531: 253–265.
72. Volkman HE, Pozos TC, Zheng J, Davis JM, Rawls JF, Ramakrishnan L. Tuberculous granuloma induction via interaction of a bacterial secreted protein with host epithelium. *Science*. 2010;327(5964):466–469.
73. Conradie F, Foulkes AS, Ive P, et al. Natural killer cell activation distinguishes Mycobacterium tuberculosis-mediated immune reconstitution syndrome from chronic HIV and HIV/MTB coinfection. *J Acquir Immune Defic Syndr*. 2011;58(3):309–318.
74. Pean P, Nerrienet E, Madec Y, et al; Cambodian Early versus Late Introduction of Antiretroviral Drugs (CAMELIA) study team. Natural killer cell degranulation capacity predicts early onset of the immune reconstitution inflammatory syndrome (IRIS) in HIV-infected patients with tuberculosis. *Blood*. 2012;119(14):3315–3320.
75. Lai RP, Nakiwala JK, Meintjes G, Wilkinson RJ. The immunopathogenesis of the HIV tuberculosis immune reconstitution inflammatory syndrome. *Eur J Immunol*. 2013;43(8):1995–2002.
76. Meintjes G, Scriven J, Marais S. Management of the immune reconstitution inflammatory syndrome. *Curr HIV/AIDS Rep*. 2012;9(3): 238–250.
77. Marais S, Wilkinson RJ, Pepper DJ, Meintjes G. Management of patients with the immune reconstitution inflammatory syndrome. *Curr HIV/AIDS Rep*. 2009;6(3):162–171.
78. Leshe E. Evidence base for using corticosteroids to treat HIV-associated immune reconstitution syndrome. *Expert Rev Anti Infect Ther*. 2006;4(3):469–478.
79. Volkow PF, Cornejo P, Zinser JW, Ormsby CE, Reyes-Terán G. Life-threatening exacerbation of Kaposi's sarcoma after prednisone treatment for immune reconstitution inflammatory syndrome. *AIDS*. 2008;22(5): 663–665.
80. Stewart MW. Optimal management of cytomegalovirus retinitis in patients with AIDS. *Clin Ophthalmol*. 2010;4:285–299.
81. Mateen FJ, Nath A. Central nervous system-immune reconstitution inflammatory syndrome in resource-limited settings: current burden and future needs. *AIDS*. 2012;26(15):1851–1855.
82. Bahr N, Boulware DR, Marais S, Scriven J, Wilkinson RJ, Meintjes G. Central nervous system immune reconstitution inflammatory syndrome. *Curr Infect Dis Rep*. 2013;15(6):583–593.
83. Meintjes G, Rabie H, Wilkinson RJ, Cotton MF. Tuberculosis-associated immune reconstitution inflammatory syndrome and unmasking of tuberculosis by antiretroviral therapy. *Clin Chest Med*. 2009;30(4):797–810.
84. Narendran G, Andrade BB, Porter BO, et al. Paradoxical tuberculosis immune reconstitution inflammatory syndrome (TB-IRIS) in HIV patients with culture confirmed pulmonary tuberculosis in India and the potential role of IL-6 in prediction. *PLoS One*. 2013;8(5):e63541.
85. World Health Organization. *Global Tuberculosis Report 2013*. Geneva: World Health Organization; 2013. Available from: http://apps.who.int/iris/bitstream/10665/91355/1/9789241564656_eng.pdf?ua=1. Accessed August 29, 2014.
86. Wilkinson KA, Meintjes G, Seldon R, Goliath R, Wilkinson RJ. Immunological characterisation of an unmasking TB-IRIS case. *S Afr Med J*. 2012;102(6):512–517.
87. Luetkemeyer AF, Kendall MA, Nyirenda M, et al; Adult AIDS Clinical Trials Group A5221 Study Team. Tuberculosis immune reconstitution inflammatory syndrome in A5221 STRIDE: timing, severity, and implications for HIV-TB programs. *J Acquir Immune Defic Syndr*. 2014;65(4):423–428.
88. Pepper DJ, Marais S, Maartens G, et al. Neurologic manifestations of paradoxical tuberculosis-associated immune reconstitution inflammatory syndrome: a case series. *Clin Infect Dis*. 2009;48(11): e96–e107.
89. Meintjes G, Rangaka MX, Maartens G, et al. Novel relationship between tuberculosis immune reconstitution inflammatory syndrome and anti-tubercular drug resistance. *Clin Infect Dis*. 2009;48(5):667–676.
90. Meintjes G, Wilkinson RJ, Morroni C, et al. Randomized placebo-controlled trial of prednisone for paradoxical tuberculosis-associated immune reconstitution inflammatory syndrome. *AIDS*. 2010;24(15): 2381–2390.
91. Breen RA, Smith CJ, Bettinson H, et al. Paradoxical reactions during tuberculosis treatment in patients with and without HIV co-infection. *Thorax*. 2004;59(8):704–707.
92. Brunel AS, Reynes J, Tuailon E, et al. Thalidomide for steroid-dependent immune reconstitution inflammatory syndromes during AIDS. *AIDS*. 2012;26(16):2110–2112.
93. Hardwick C, White D, Morris E, Monteiro EF, Breen RA, Lipman M. Montelukast in the treatment of HIV-associated immune reconstitution disease. *Sex Transm Infect*. 2006;82(6):513–514.
94. Abdool Karim SS, Naidoo K, Grobler A, et al. Timing of initiation of antiretroviral drugs during tuberculosis therapy. *N Engl J Med*. 2010;362(8):697–706.
95. Havlir DV, Kendall MA, Ive P, et al; AIDS Clinical Trials Group Study A5221. Timing of antiretroviral therapy for HIV-1 infection and tuberculosis. *N Eng J Med*. 2011;365(16):1482–1491.
96. Blanc FX, Sok T, Laureillard D, et al; CAMELIA (ANRS 1295–CIPRA KH001) Study Team. Earlier versus later start of antiretroviral therapy in HIV-infected adults with tuberculosis. *N Eng J Med*. 2011;365(16): 1471–1481.
97. Mfinanga SG, Kirenga BJ, Chanda DM, et al. Early versus delayed initiation of highly active antiretroviral therapy for HIV-positive adults with newly diagnosed pulmonary tuberculosis (TB-HAART): a prospective, international, randomised, placebo-controlled trial. *Lancet Infect Dis*. 2014;14(7):563–571.
98. Török ME, Yen NT, Chau TT, et al. Timing of initiation of antiretroviral therapy in human immunodeficiency virus (HIV) – associated tuberculous meningitis. *Clin Infect Dis*. 2011;52(11):1374–1383.
99. Getahun H, Kittikraisak W, Heilig CM, et al. Development of a standardized screening rule for tuberculosis in people living with HIV in resource-constrained settings: individual participant data meta-analysis of observational studies. *PLoS Med*. 2011;8(1):e1000391.
100. Bicanic T, Meintjes G, Rebe K, et al. Immune reconstitution inflammatory syndrome in HIV-associated cryptococcal meningitis: a prospective study. *J Acquir Immune Defic Syndr*. 2009;51(2): 130–134.
101. Shelburne SA, Visnegarwala F, Darcourt J, et al. Incidence and risk factors for immune reconstitution inflammatory syndrome during highly active antiretroviral therapy. *AIDS*. 2005;19(4):399–406.
102. Sungkanuparph S, Filler SG, Chetchotisakd P, et al. Cryptococcal immune reconstitution inflammatory syndrome after antiretroviral therapy in AIDS patients with cryptococcal meningitis: a prospective multicenter study. *Clin Infect Dis*. 2009;49(6):931–934.
103. Chang CC, Dorasamy AA, Gosnell BI, et al. Clinical and mycological predictors of cryptococcosis-associated immune reconstitution inflammatory syndrome. *AIDS*. 2013;27(13):2089–2099.

104. Chang CC, Lim A, Omarjee S, et al. Cryptococcosis-IRIS is associated with lower cryptococcus-specific IFN-gamma responses before antiretroviral therapy but not higher T-cell responses during therapy. *J Infect Dis.* 2013;208(6):898–906.
105. Zolopa A, Andersen J, Powderly W, et al. Early antiretroviral therapy reduces AIDS progression/death in individuals with acute opportunistic infections: a multicenter randomized strategy trial. *PLoS One.* 2009;4(5):e5575.
106. Grant PM, Komarow L, Andersen J, et al. Risk factor analyses for immune reconstitution inflammatory syndrome in a randomized study of early vs deferred ART during an opportunistic infection. *PLoS One.* 2010;5(7):e11416.
107. Bisson GP, Molefi M, Bellamy S, et al. Early versus delayed antiretroviral therapy and cerebrospinal fluid fungal clearance in adults with HIV and cryptococcal meningitis. *Clin Infect Dis.* 2013;56(8):1165–1173.
108. Makadzange AT, Ndhlovu CE, Takarinda K, et al. Early versus delayed initiation of antiretroviral therapy for concurrent HIV infection and cryptococcal meningitis in sub-saharan Africa. *Clin Infect Dis.* 2010;50(11):1532–1538.
109. Boulware DR, Meya DB, Muzoora C, et al. Timing of antiretroviral therapy after diagnosis of cryptococcal meningitis. *N Engl J Med.* 2014;370(26):2487–2498.
110. Govender NP, Meintjes G, Bicanic T, et al. Guideline for the prevention, diagnosis and management of cryptococcal meningitis among HIV-infected persons: 2013 update. *South Afr J HIV Med.* 2013;14(2):76–86.
111. Lawn SD, Bekker LG, Myer L, Orrell C, Wood R. Cryptococcal immune reconstitution disease: a major cause of early mortality in a South African antiretroviral programme. *AIDS.* 2005;19(17):2050–2052.
112. Murdoch DM, Venter WD, Feldman C, Van Rie A. Incidence and risk factors for the immune reconstitution inflammatory syndrome in HIV patients in South Africa: a prospective study. *AIDS.* 2008;22(5): 601–610.
113. Meya DB, Manabe YC, Castelnovo B, et al. Cost-effectiveness of serum cryptococcal antigen screening to prevent deaths among HIV-infected persons with a CD4+ cell count < or = 100 cells/microL who start HIV therapy in resource-limited settings. *Clin Infect Dis.* 2010;51(4):448–455.
114. Parkes-Ratanshi R, Wakeham K, Levin J, et al; Cryptococcal Trial Team. Primary prophylaxis of cryptococcal disease with fluconazole in HIV-positive Ugandan adults: a double-blind, randomised, placebo-controlled trial. *Lancet Infect Dis.* 2011;11(12):933–941.
115. Pongsai P, Atamasirikul K, Sungkanuparph S. The role of serum cryptococcal antigen screening for the early diagnosis of cryptococcosis in HIV-infected patients with different ranges of CD4 cell counts. *J Infect.* 2010;60(6):474–477.
116. Jarvis JN, Lawn SD, Vogt M, Bangani N, Wood R, Harrison TS. Screening for cryptococcal antigenemia in patients accessing an antiretroviral treatment program in South Africa. *Clin Infect Dis.* 2009;48(7):856–862.
117. Perfect JR, Dismukes WE, Dromer F, et al. Clinical practice guidelines for the management of cryptococcal disease: 2010 update by the infectious diseases society of america. *Clin Infect Dis.* 2010;50(3): 291–322.
118. Dal Maso L, Serraino D, Franceschi S. Epidemiology of HIV-associated malignancies. *Cancer Treat Res.* 2001;104:1–18.
119. Di Lorenzo G, Konstantinopoulos PA, Pantanowitz L, Di Trolio R, De Placido S, Dezube BJ. Management of AIDS-related Kaposi's sarcoma. *Lancet Oncol.* 2007;8(2):167–176.
120. Bower M, Nelson M, Young AM, et al. Immune reconstitution inflammatory syndrome associated with Kaposi's sarcoma. *J Clin Oncol.* 2005;23(22):5224–5228.
121. Letang E, Almeida JM, Miró JM, et al. Predictors of immune reconstitution inflammatory syndrome-associated with kaposi sarcoma in mozambique: a prospective study. *J Acquir Immune Defic Syndr.* 2010;53(5):589–597.
122. Leidner RS, Abouafia DM. Recrudescence Kaposi's sarcoma after initiation of HAART: a manifestation of immune reconstitution syndrome. *AIDS Patient Care STDS.* 2005;19(10):635–644.
123. Mesri EA. Targeting AIDS-Kaposi's sarcoma. *Nat Med.* 1999;5(7): 738–739.
124. Post MJ, Thurnher MM, Clifford DB, et al. CNS-immune reconstitution inflammatory syndrome in the setting of HIV infection, part 1: overview and discussion of progressive multifocal leukoencephalopathy-immune reconstitution inflammatory syndrome and cryptococcal-immune reconstitution inflammatory syndrome. *AJNR Am J Neuroradiol.* 2013;34(7):1297–1307.
125. Shankar SK, Satishchandra P, Mahadevan A, et al. Low prevalence of progressive multifocal leukoencephalopathy in India and Africa: is there a biological explanation? *J Neurovirol.* 2003;9 Suppl 1:59–67.
126. Giacomini PS, Rozenberg A, Metz I, Araujo D, Arbour N, Bar-Or A; Maraviroc in Multiple Sclerosis-Associated PML-IRIS (MIMSAPI) Group. Maraviroc and JC virus-associated immune reconstitution inflammatory syndrome. *N Engl J Med.* 2014;370(5):486–488.
127. Post MJ, Thurnher MM, Clifford DB, et al. CNS-immune reconstitution inflammatory syndrome in the setting of HIV infection, part 2: discussion of neuro-immune reconstitution inflammatory syndrome with and without other pathogens. *AJNR Am J Neuroradiol.* 2013;34(7):1308–1318.
128. Johnson T, Nath A. Immune reconstitution inflammatory syndrome and the central nervous system. *Curr Opin Neurol.* 2011;24(3):284–290.
129. Ringelstein A, Oelschlaeger C, Saleh A, et al. Severe aseptic leukoencephalopathy as immune reconstitution inflammatory syndrome in Caucasian and African patients. *AIDS.* 2009;23(11):1435–1437.
130. Anderson AM, Mosunjac MB, Palmore MP, Osborn MK, Muir AJ. Development of fatal acute liver failure in HIV-HBV coinfecting patients. *World J Gastroenterol.* 2010;16(32):4107–4111.
131. World Health Organization. *Improving the diagnosis and treatment of smear-negative pulmonary and extra-pulmonary tuberculosis among adults and adolescents: recommendations for HIV-prevalent and resource-constrained settings.* Geneva: World Health Organization; 2006. Available from: http://www.who.int/tb/publications/2006/tbhiv_recommendations.pdf. Accessed September 01, 2014.

HIV/AIDS - Research and Palliative Care

Publish your work in this journal

HIV/AIDS - Research and Palliative Care is an international, peer-reviewed open-access journal focusing on advances in research in HIV, its clinical progression and management options including antiviral treatment, palliative care and public healthcare policies to control viral spread. The journal welcomes original research, basic science,

Submit your manuscript here: <http://www.dovepress.com/hivaidr---research-and-palliative-care-journal>

clinical & epidemiological studies, reviews & evaluations, expert opinion & commentary, case reports & extended reports. The manuscript management system is completely online and includes a very quick and fair peer-review system. Visit <http://www.dovepress.com/testimonials.php> to read real quotes from published authors.

Dovepress