



CASE REPORT

Two distinct cases with COVID-19 in kidney transplant recipients

Yaerim Kim^{1,2}  | Ohyun Kwon¹ | Jin H. Paek^{1,2} | Woo Y. Park^{1,2} | Kyubok Jin^{1,2} | Miri Hyun³ | Ji Y. Lee³ | Hyun A. Kim³ | Seungyeup Han^{1,2} 

¹Division of Nephrology, Department of Internal Medicine, Keimyung University School of Medicine, Daegu, Korea

²Keimyung University Kidney Institute, Daegu, Korea

³Division of Infectious Disease, Department of Internal Medicine, Keimyung University School of Medicine, Daegu, Korea

Correspondence

Seungyeup Han
Email: hansy@dsmc.or.kr

The fatality of novel coronavirus disease 2019 (COVID-19) is precipitously increased in patients with underlying comorbidities or elderly people. Kidney transplant (KT) recipients are one of the vulnerable populations for infection. COVID-19 infection in KT recipients might be a complicated and awkward situation, but there has been a lack of reports concerning this group. Herein, we demonstrated two distinct cases with different clinical progress. The first case was a 36-year-old man who underwent KT 3 years ago. He was diagnosed with COVID-19 expressing relevant symptoms. Following administration of lopinavir/ritonavir and hydroxychloroquine with reduced immunosuppressant, he recovered from COVID-19. However, the unexpected fluctuations in tacrolimus trough levels needed to be managed because of drug-to-drug interaction. The second case was developed in a 56-year-old man without any symptoms. He received a second KT from an ABO-incompatible donor 8 years ago. He was diagnosed with COVID-19 by screening due to exposure history. During the hospitalization period, the chest infiltrative lesion showed a wax and wane, but he successfully recovered by administration of hydroxychloroquine with azithromycin. These apparently different cases suggest that assertive screening and management could improve the clinical course. In addition, antiviral agents should be used cautiously, especially in patients on calcineurin inhibitors.

KEYWORDS

clinical research/practice, immunosuppressant, infection and infectious agents – viral, infectious disease, kidney (allograft) function/dysfunction, kidney transplantation/nephrology

1 | INTRODUCTION

Outbreaks of novel coronavirus disease (COVID-19) began in Wuhan, China, in December 2019.¹⁻⁴ South Korea experienced one

of the earliest outbreaks of COVID-19. Until April 4, 2020, 455 032 people were tested, and 10 156 were diagnosed as COVID-19 positive. It is rapidly spreading regardless of nation, but there is still no specific treatment regimen, especially for the immunocompetent population.

South Korea ranked second in the average yearly change in kidney transplantation (KT) rate with a 2.1% increase per year.⁵ KT is the best treatment strategy for patients with end-stage renal disease (ESRD). However, balancing between infection and rejection is

Abbreviations: AMR, antibody-mediated rejection; COVID-19, coronavirus disease 2019; CRP, C-reactive protein; CT, computed tomography; eGFR, estimated glomerular filtration rate; ESRD, end-stage renal disease; KT, kidney transplant; MMF, mycophenolate mofetil; RT-PCR, real-time polymerase chain reaction; SCr, serum creatinine; uPCR, urine protein to creatinine ratio.

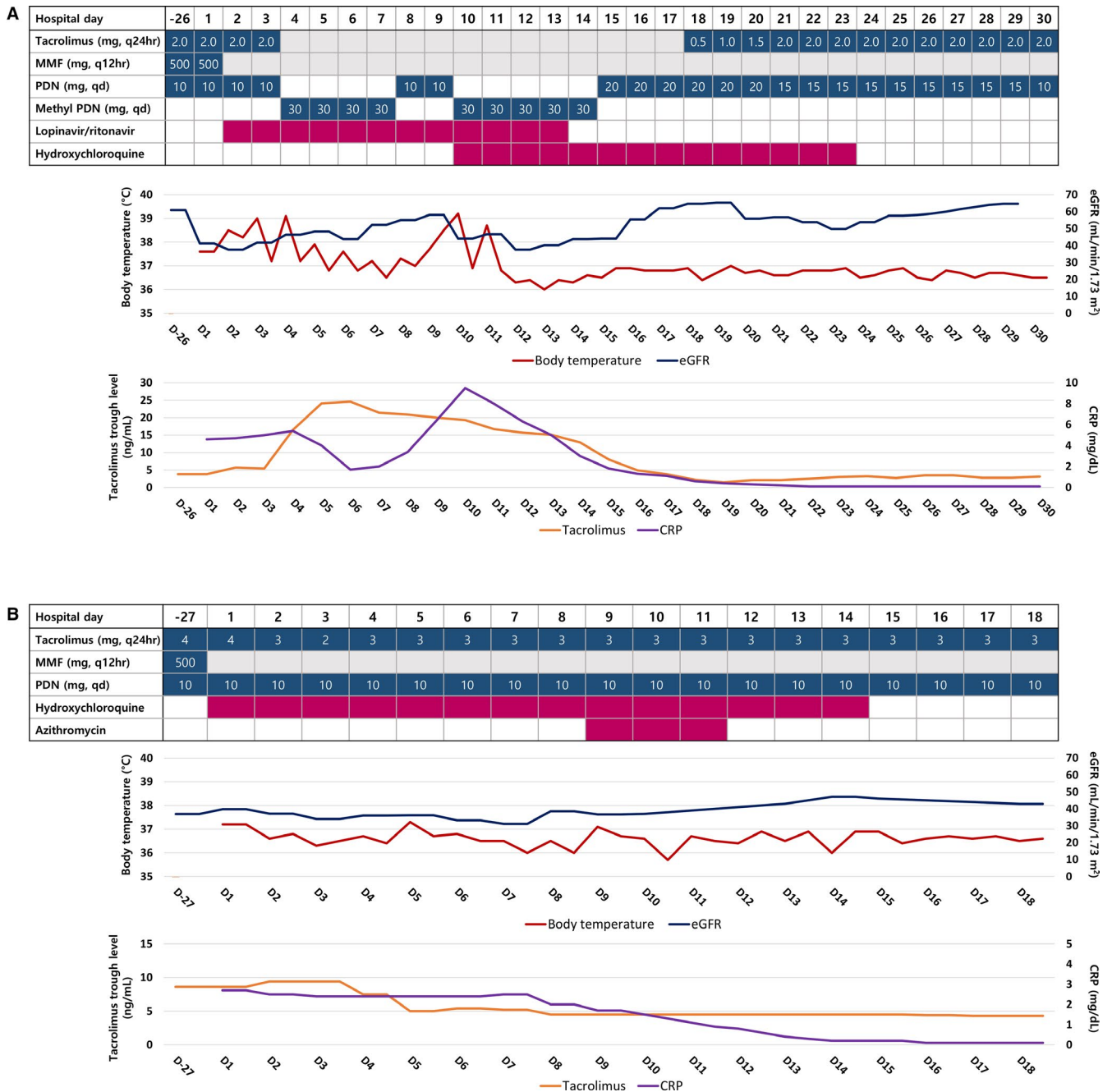


FIGURE 1 Changes in the clinical parameters, laboratory results, and drug administrations. The blue-colored boxes show the use of immunosuppressants with dosages. The red-colored boxes show the antiviral agents used in each day. The gray-colored boxes show a skipped day for immunosuppressants. In the line plot, the left-sided vertical axis represents body temperature and tacrolimus trough level in top and bottom plots, respectively. The right-sided vertical axis represents the estimated glomerular filtration rate (eGFR) and C-reactive protein (CRP) level in the top and bottom plots, respectively. The horizontal axis represents the days in hospital, in common. The admission date is represented as hospital day 1. The latest day before admission was demonstrated by -26 and -27 in Case 1 and Case 2, respectively. Case 1 is shown in the (A) plot, and case 2 in the (B) plot. MMF, mycophenolate mofetil; PDN, prednisolone; eGFR, estimated glomerular filtration rate; CRP, C-reactive protein [Color figure can be viewed at wileyonlinelibrary.com]

a critical issue for improving long-term outcomes in KT. Because the overall immunity is decreased due to lifelong use of immunosuppressant drugs, KT recipients are vulnerable to infections.⁶ In addition, all recipients show different clinical manifestations with various underlying diseases and immunosuppressant regimens. Therefore, it is more

challenging to propose proper management guidelines for infectious diseases in these patients than in the general population. However, the accumulation of diverse experiences could help to improve the overall outcomes; thus, we aimed to share our experience with two recipient cases with COVID-19 showing distinct clinical courses.

2 | CASE 1

A 36-year-old man was admitted to our hospital with fever, cough, rhinorrhea, diarrhea, and decreased urine output. He was diagnosed with ESRD due to focal segmental global sclerosis and received living unrelated donor KT in April 2016. The donor-recipient HLA-A, -B, -DR mismatch grade was 5. The maintenance immunosuppressants were long-acting tacrolimus (2 mg, q24hours), mycophenolate mofetil (MMF) (500 mg, q12hours), and prednisolone (10 mg, qd) (Figure 1A). At the latest follow-up date on February 19, 2020, the level of serum creatinine (sCr), estimated glomerular filtration rate (eGFR), and tacrolimus trough were 1.47 mg/dL, 54.5 mL/min/1.73 m², and 3.8 ng/mL, respectively. In addition, there was no proteinuria.

On March 12, 2020, he felt a febrile sensation with coughing and rhinorrhea. After 2 days, diarrhea occurred, and urine volume decreased. He reported no history of travels abroad or exposure to infected or suspected patients of contagious COVID-19. On March 16, 2020, he visited the hospital and real-time polymerase chain reaction (RT-PCR) for COVID-19 was performed by nasopharyngeal swab. After 1 day, he was diagnosed with COVID-19 and was admitted to the hospital. His vital signs were stable, with mild fever at 37.6°C when he was admitted. The initial laboratory findings showed

decreased lymphocyte count, increased C-reactive protein (CRP), sCr level, and urine protein-to-creatinine ratio (uPCR) (Table 1). Chest radiograph showed subsegmental atelectasis on both lower lung field and peribronchial infiltration in the left upper lobe (Figure 2). On hospital day 2, the fever spiked to 38.5°C, and we decided to discontinue the MMF and to start lopinavir/ritonavir (400/100 mg, bid). Two days later, the tacrolimus trough level abruptly increased to 16.5 ng/mL. Thus, we discontinued tacrolimus and changed prednisolone to intravenous methylprednisolone (30 mg, qd). After discontinuation of tacrolimus, the trough level peaked at 24.6 ng/mL and started to decrease, and it took 10 days to reach the therapeutic range (Figure 1A). From hospital day 5, diarrhea and chest discomfort were relieved, and kidney function was recovered with decreased uPCR. We reduced the dose of prednisolone by changing from intravenous to per-oral administration on hospital day 8. Two days later, fever and diarrhea redeveloped, and deterioration of allograft function and chest infiltrate were reaggavated (Figure 2). Following the rechallenge of methylprednisolone with increased dose and hydroxychloroquine, the symptoms were relieved, and kidney function was stabilized again (Table 1). On hospital day 13, we discontinued lopinavir/ritonavir. The next day we changed methylprednisolone to prednisolone. From hospital day 18, we resumed

TABLE 1 Changes in laboratory findings of both cases

	Case 1				Case 2		
	On admission	D 7	D 18	D 29	On admission	D 7	D 17
Complete blood cells							
White blood cell, / μ L	6630	13 910	13 840	4980	3950	4680	5850
Hemoglobin, g/dL	14.5	12.5	11.9	10.6	14.1	15.0	13.1
Platelet, 10 ³ / μ L	313	371	323	324	111	129	207
Neutrophil, / μ L (%)	5417 (81.7)	12 157 (87.4)	10 740 (77.6)	1668 (33.5)	2090 (52.9)	2434 (52.0)	2469 (42.2)
Lymphocyte, / μ L (%)	643 (9.7)	654 (4.7)	1882 (13.6)	2092 (42.0)	1339 (33.9)	1470 (31.4)	2469 (42.2)
Monocyte, / μ L (%)	557 (8.4)	1085 (7.8)	1024 (7.4)	891 (17.9)	521 (13.2)	679 (14.5)	801 (13.7)
Sodium, mEq/L	130	134	143	143	133	133	137
Potassium, mEq/L	5.0	4.3	4.3	4.9	4.9	5.2	4.4
BUN, mg/dL	26	23	33	21	33	47	34
Creatinine, mg/dL	2.02	1.59	1.39	1.39	1.85	2.27	1.74
eGFR, mL/min/1.73 m ²	41.2	55.0	64.7	64.7	39.8	31.1	42.9
Albumin, g/dL	4.2	3.3	3.4	3.8	3.7	3.7	3.7
AST, U/L	32	12	16	20	14	16	15
ALT, U/L	35	21	30	45	10	9	11
CRP, mg/dL	4.6	3.4	0.6	0.1	2.7	2.5	0.1
Urine albumin	2+	1+	Negative	Trace	2+	1+	Trace
uPCR, g/g Cr	1.25	0.87	0.21	0.09	ND	0.75	0.58
COVID-19							
Nasopharyngeal swab	Positive	Positive	Positive	Negative	Positive	Positive	Negative
Sputum	Positive	Positive	Positive	Negative	Positive	Positive	Negative

Abbreviations: ALT, alanine transaminase; AST, aspartate transaminase; BUN, blood urea nitrogen; COVID-19, coronavirus disease 2019; CRP, C-reactive protein; D, admission date; eGFR, estimated glomerular filtration rate; ND, not done; uPCR, urine protein to creatinine ratio.

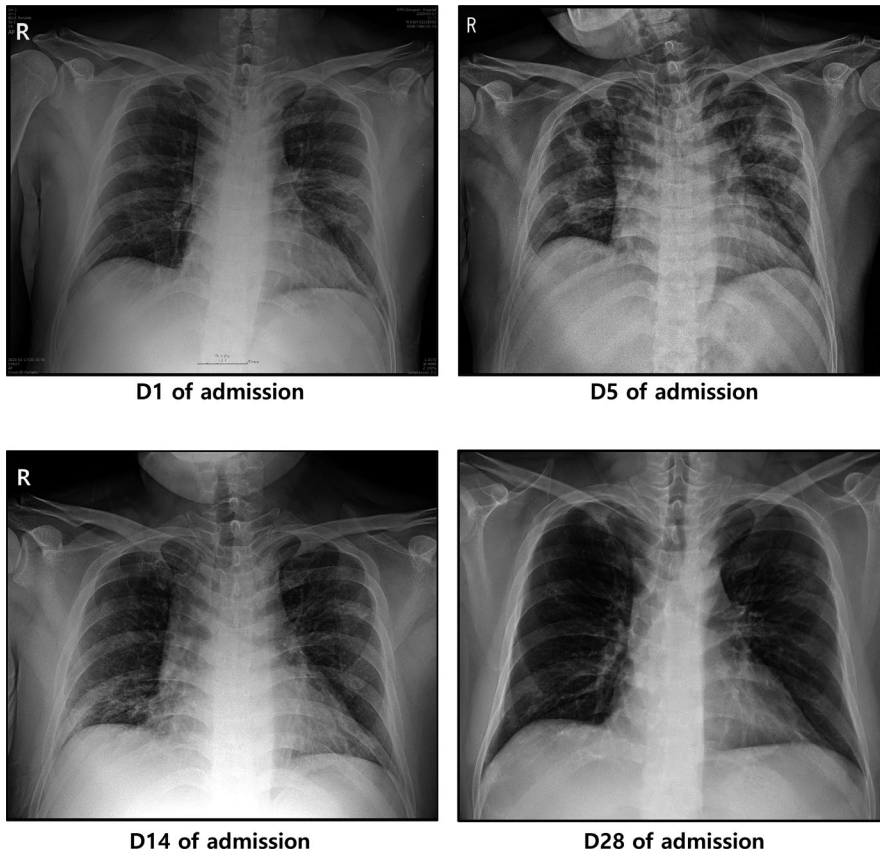


FIGURE 2 Changes in chest radiograph findings in Case 1. The admission date was represented as day 1 (D1). The infiltrative lesion was aggravated on D5. It started to improve from D14 and further improved on D28

tacrolimus from 0.5 mg q24hours. After that, the clinical course was maintained stable; hydroxychloroquine was discontinued on hospital day 23. During in-hospital days, he did not show hypoxia in room air, and peripheral capillary oxygen saturation was maintained above 95%. Finally, chest lesion was significantly improved with stable kidney function; COVID-19 was not detected in RT-PCR in two consecutive days.

3 | CASE 2

A 56-year-old man was transferred from a local hospital with cough and sputum. He was diagnosed with ESRD due to type 2 diabetes mellitus in 2003. He underwent deceased donor KT in October 2004. After 4 years, allograft dysfunction progressed to ESRD and he returned to hemodialysis. In December 2011, he received an ABO-incompatible KT from his wife. The donor-recipient HLA-A, -B, -DR mismatch grade was 6. Three months posttransplant, he developed candida esophagitis and cytomegalovirus gastritis. In addition, 1 year posttransplant, he was diagnosed with acute antibody-mediated rejection (AMR) and treated with steroid pulse therapy, plasma exchange, and rituximab 375 mg/1.73 m². Thereafter, he regularly followed up with stable kidney function, and the latest sCr and eGFR values were 1.97 mg/dL and 36.9 mL/min/1.73 m², respectively. The maintenance immunosuppressants used were long-acting tacrolimus (4 mg, q24hours), MMF (500 mg, q12hours), and

prednisolone (10 mg, qd) (Figure 1B). The latest tacrolimus trough level was 8.6 ng/mL.

On March 1, 2020, he visited a screening hospital owing to contact history with a COVID-19 confirmed patient. He did not have any symptoms, but the result of RT-PCR assay via nasopharyngeal swab for COVID-19 was positive. He was admitted to the regional hospital and took supportive care without taking any antiviral agents or antibiotics. However, during the in-hospital period, he experienced flank pain with vesicles and was diagnosed with herpes zoster. He took famciclovir for a week. After discontinuation of the drug, he had cough and sputum. Because ground-glass opacity was newly developed in the chest computed tomography (CT) (Figure 3) with an increased level of CRP, he was transferred to our hospital. On March 18, 2020, he was admitted with stable vital signs, and laboratory results were not significantly different from the latest follow-up data before the diagnosis of COVID-19 (Table 1). The day after admission, we discontinued MMF and maintained tacrolimus and prednisolone. On the same day, hydroxychloroquine (400 mg, qd) was administered (Figure 1B). On hospital day 9, his vital signs were stable, coughing was relieved, but the chest infiltrative lesion was slightly aggravated (Figure 3) and he was still positive for COVID-19 on RT-PCR assay. We added azithromycin (500 mg, qd) to hydroxychloroquine.⁷ During in-hospital days, he often suffered from coughing; his peripheral oxygen saturation was maintained above 95% without oxygen supply. Finally, the respiratory symptoms were relieved and lung lesions

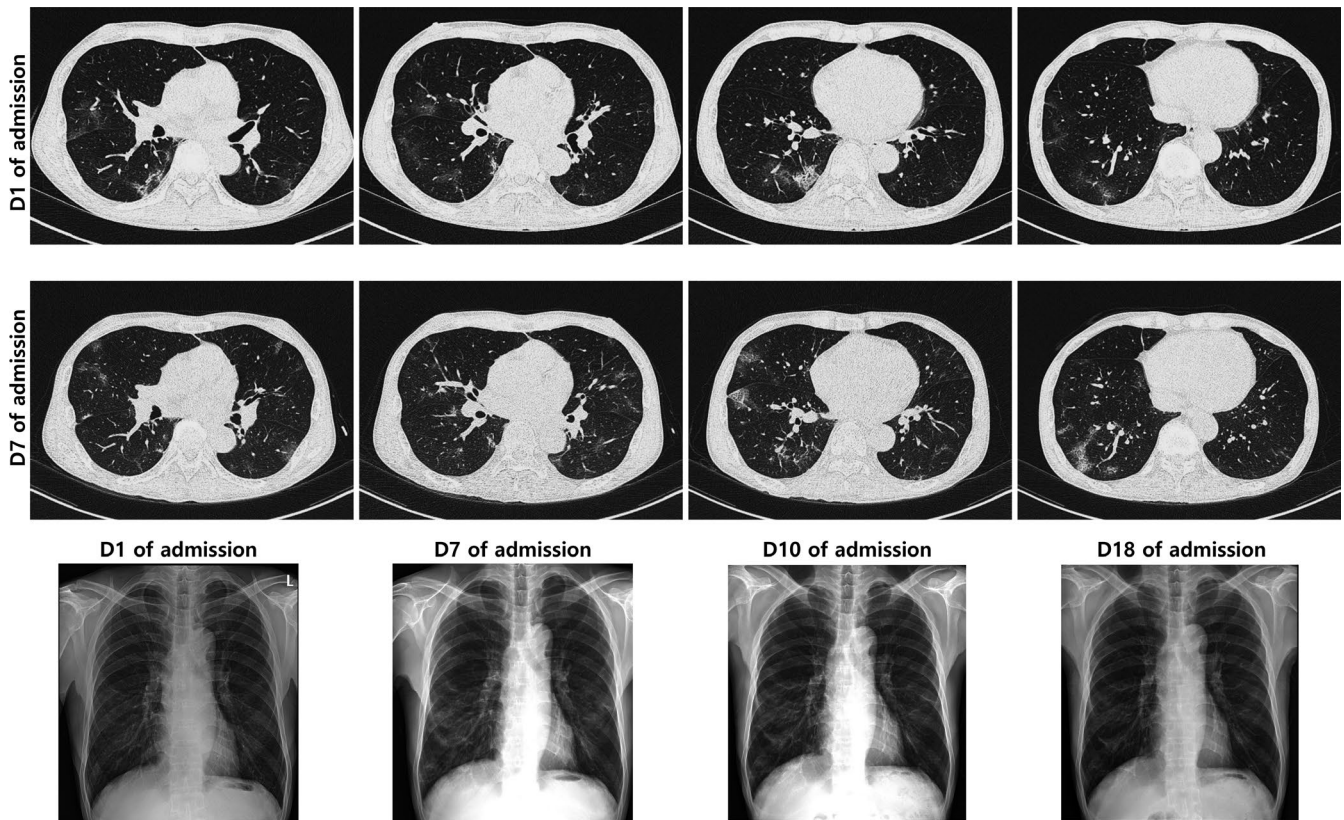


FIGURE 3 Changes in the findings of chest radiograph and chest computed tomography (CT) in Case 2. The first row shows chest CT findings on admission date (D1), and the second row shows chest CT in hospital day (D) 7. The same columns between the first and second rows show the same plane in the CT. The infiltrative lesion in both lower lung field in the chest CT was more aggravated on D7 than on D1. The last row shows the changes in the findings of chest radiograph from admission day to hospital day 18. The infiltrative lesion was aggravated in the image on D7, but it was improved on D18

were slightly improved on chest radiograph (Figure 3); COVID-19 was not detected in RT-PCR assay in two consecutive times at hospital day 17 and 18.

4 | DISCUSSION

COVID-19 infection in KT recipients is rarely reported, but it raises a number of considerations. We diagnosed 2 recipients with COVID-19 using an aggressive screening strategy. The first case showed typical clinical features, including cough, rhinorrhea, and diarrhea. Meanwhile, the second case did not show any clinical symptoms when he was diagnosed with COVID-19. Although there is no established treatment strategy, we used lopinavir/ritonavir and hydroxychloroquine for the first case and hydroxychloroquine with azithromycin for the second case. Finally, both cases were fully recovered from COVID-19.

Following the enormous advance in the understanding of the immune responses to a transplanted organ, KT outcomes were significantly improved.⁸ Nevertheless, infectious disease, which was one of the challenging issues in this population, should be cautiously monitored in light of the suppressed immunity. Although

the second case did not experience any symptoms at the time of diagnosis, his clinical feature was eventually aggravated, and he needed medical intervention. This suggests that assertive screening and proper management might have a positive effect on improving the clinical outcome, especially for immunocompromised patients.

Infection and rejection are the most complicated factors to manage in KT recipients. Each of the antithetical complications could arise alone, but sometimes they happen simultaneously. Indeed, the second case had not only various histories of infectious diseases such as cytomegalovirus and herpes zoster virus, but also acute AMR. Moreover, he had been treated for herpes zoster virus reactivation during the asymptomatic period with supportive care. At the same time, he still had a donor-specific antibody with a high melt flow index (15 108) in HLA-DR. Similarly, the first case also had a history of acute AMR. There was no specific sign of rejection, but considering the risk, we maintained two major immunosuppressants.

Interestingly, both cases showed not only kidney function deterioration but also proteinuria. Previous coronavirus infections, severe acute respiratory syndrome (SARS) and Middle East respiratory syndrome (MERS), developed acute kidney

injury in 5%-15% cases and showed high mortality rate.^{9,10} On the contrary, COVID-19 was associated with a high incidence of proteinuria. A recent report showed that 34% of patients showed albuminuria on admission date.¹¹ Likewise, both cases also showed significant proteinuria when they admitted to the hospital. In addition, with improving the clinical course, proteinuria was subsided.

Unfortunately, there is no specific treatment guideline for COVID-19. Lopinavir is an agent used during SARS and MERS epidemics. Because COVID-19 shares 79.5% of sequence identity with SARS-coronavirus,¹² it has been suggested that the treatment strategy could be shared.¹³ Also, several cases recovered from COVID-19 after using lopinavir.¹⁴⁻¹⁶ However, drug interactions with calcineurin inhibitors should be considered when lopinavir is initiated in KT recipients. Lopinavir can inhibit the metabolism of tacrolimus,¹⁷ which is a substrate of CYP3A4, thereby increasing the blood level of tacrolimus.¹⁸ Although the dosage of tacrolimus was only 2 mg per day and the trough level was around 5 ng/dL, 2 days after starting the lopinavir/ritonavir, the tacrolimus trough level abruptly increased in the first case. In addition, it took 10 days to normalize the concentration within the acceptable range. This finding was similar to other cases of liver transplantation;¹⁹ thus, physicians should consider indispensable and alternative options before starting this agent. Moreover, after the decision to use this agent, tacrolimus should be skipped before or at the time of start of administration, and the trough level should be cautiously monitored.

We demonstrated two distinct KT recipient cases diagnosed with COVID-19. They had different comorbidities and medical histories and showed different clinical manifestations. By early detection with screening strategy, the second case needed more in-hospital days (17 and 18 days before and after admission to our hospital) than the first case (30 days). However, considering the more vulnerable immunologic background, such as a second KT, ABO-incompatible KT, and various histories of viral infections, early diagnosis with assertive screening could lead to favorable clinical courses. It is difficult to suggest the efficacy of the treatment regimen, but lopinavir/ritonavir should be cautiously used in KT recipients with tacrolimus. On the basis of these few cases, it is necessary to provide baseline information of better outcomes by accumulating multiple new experiences.

ACKNOWLEDGMENTS

We would like to respect and appreciation to all medical staff around the world who are making a dedicated sacrifice against COVID-19. This study was approved by the institutional review board of Keimyung University Dongsan Hospital (IRB No. 2020-04-002). The study was conducted in accordance with the principles of the Declaration of Helsinki.

DISCLOSURE

The authors of this manuscript have no conflicts of interest to disclose as described by the *American Journal of Transplantation*.

DATA AVAILABILITY STATEMENT

The data that support the findings of this study are available from the corresponding author upon reasonable request.

ORCID

Yaerim Kim  <https://orcid.org/0000-0003-1596-1528>

Seungyeup Han  <https://orcid.org/0000-0002-7561-6534>

REFERENCES

- Huang C, Wang Y, Li X, et al. Clinical features of patients infected with 2019 novel coronavirus in Wuhan, China. *Lancet*. 2020;395(10223):497-506.
- Wu Z, McGoogan JM. Characteristics of and important lessons from the coronavirus disease 2019 (COVID-19) outbreak in China: summary of a report of 72314 cases from the Chinese Center for Disease Control and Prevention. *JAMA*. 2020;323(13):1239.
- Rothe C, Schunk M, Sothmann P, et al. Transmission of 2019-nCoV infection from an asymptomatic contact in Germany. *N Engl J Med*. 2020;382(10):970-971.
- Bialek S, Boundy E, Bowen V, et al. Severe outcomes among patients with coronavirus disease 2019 (COVID-19) - United States, February 12-March 16, 2020. *MMWR Morb Mortal Wkly Rep*. 2020;69(12):343-346.
- Saran R, Robinson B, Abbott KC, et al. US renal data system 2017 annual data report: epidemiology of kidney disease in the United States. *Am J Kidney Dis*. 2018;71(3 Suppl 1):A7.
- Vanichanan J, Udomkarnjananun S, Avihingsanon Y, Jutivorakool K. Common viral infections in kidney transplant recipients. *Kidney Res Clin Pract*. 2018;37(4):323-337.
- Gautret P, Lagier J-C, Parola P, et al. Hydroxychloroquine and azithromycin as a treatment of COVID-19: results of an open-label non-randomized clinical trial. *Int J Antimicrob Agents*. 2020;105949. <https://doi.org/10.1016/j.ijantimicag.2020.105949>
- Shrestha BM. Immune system and kidney transplantation. *JNMA J Nepal Med Assoc*. 2017;56(208):482-486.
- Eckerle I, Muller MA, Kallies S, Gotthardt DN, Drosten C. In-vitro renal epithelial cell infection reveals a viral kidney tropism as a potential mechanism for acute renal failure during Middle East Respiratory Syndrome (MERS) Coronavirus infection. *Virology*. 2013;10:359.
- Chu KH, Tsang WK, Tang CS, et al. Acute renal impairment in coronavirus-associated severe acute respiratory syndrome. *Kidney Int*. 2005;67(2):698-705.
- Cheng Y, Luo R, Wang K, et al. Kidney disease is associated with in-hospital death of patients with COVID-19. *Kidney Int*. 2020;97(5):829-838.
- Zhou P, Yang X-L, Wang X-G, et al. A pneumonia outbreak associated with a new coronavirus of probable bat origin. *Nature*. 2020;579(7798):270-273.
- Yao TT, Qian JD, Zhu WY, Wang Y, Wang GQ. A systematic review of lopinavir therapy for SARS coronavirus and MERS coronavirus—a possible reference for coronavirus disease-19 treatment option. *J Med Virol*. 2020;92(6):556-563.
- Wang Z, Chen X, Lu Y, Chen F, Zhang W. Clinical characteristics and therapeutic procedure for four cases with 2019 novel coronavirus pneumonia receiving combined Chinese and Western medicine treatment. *Biosci Trends*. 2020;14(1):64-68.
- Li H, Wang YM, Xu JY, Cao B. Potential antiviral therapeutics for 2019 novel coronavirus. *Zhonghua Jie He He Hu Xi Za Zhi*. 2020;43(3):170-172.
- Lu H. Drug treatment options for the 2019-new coronavirus (2019-nCoV). *Biosci Trends*. 2020;14(1):69-71.
- Kumar GN, Dykstra J, Roberts EM, et al. Potent inhibition of the cytochrome P-450 3A-mediated human liver microsomal metabolism

- of a novel HIV protease inhibitor by ritonavir: a positive drug-drug interaction. *Drug Metab Dispos.* 1999;27(8):902-908.
18. Zuo X-C, Ng CM, Barrett JS, et al. Effects of CYP3A4 and CYP3A5 polymorphisms on tacrolimus pharmacokinetics in Chinese adult renal transplant recipients: a population pharmacokinetic analysis. *Pharmacogenet Genomics.* 2013;23(5):251-261.
 19. Schonder KS, Shullo MA, Okusanya O. Tacrolimus and lopinavir/ritonavir interaction in liver transplantation. *Ann Pharmacother.* 2003;37(12):1793-1796.

How to cite this article: Kim Y, Kwon O, Paek JH, et al. Two distinct cases with COVID-19 in kidney transplant recipients. *Am J Transplant.* 2020;20:2269-2275. <https://doi.org/10.1111/ajt.15947>