



## Oncology

## Papillary Renal Cell Carcinoma Revealed by Renal Traumatism: A Case Report in Lomé



Tchilabalo Matchonna Kpatcha<sup>a,\*</sup>, Kodjo Tengué<sup>a</sup>, Gnimdou Botcho<sup>a</sup>, Tchinn Darré<sup>b</sup>, Kossi Akomola Sabi<sup>c</sup>, Komi Hola Sikpa<sup>a</sup>, Essomendedou Léloua<sup>a</sup>, Edoé Viyomé Séwa<sup>a</sup>, Obube Amegayibor<sup>a</sup>, Tsipa Anoukoum<sup>a</sup>, Koffi Amégbor<sup>b</sup>, Ekoue David Dosseh<sup>d</sup>

<sup>a</sup> Department of Urology, The University Teaching Hospital of Lomé, BP: 57 Lomé, Togo

<sup>b</sup> Department of Pathology, The University Teaching Hospital of Lomé, BP: 57 Lomé, Togo

<sup>c</sup> Department of Nephrology, The University Teaching Hospital of Lomé, BP: 57 Lomé, Togo

<sup>d</sup> Department of Surgery, The University Teaching Hospital of Lomé, BP: 57 Lomé, Togo

## ARTICLE INFO

## Article history:

Received 19 August 2016

Received in revised form

28 November 2016

Accepted 30 November 2016

## Keywords:

Renal papillary carcinoma

Renal trauma

Nephrectomy

Lomé

## ABSTRACT

This study is a report on a case of papillary carcinoma of the kidney revealed by an abdominal contusion. The results of radiological investigations were discordant with the low intensity of the shock. The treatment consisted of radical nephrectomy because of the suspicion of a pre-existing malignancy. Histological analysis revealed a papillary carcinoma pT3N0M0. We focus on the need for performing diagnostic tests in order to avoid missing a pre-existing anomaly to the kidney trauma.

© 2016 Published by Elsevier Inc. This is an open access article under the CC BY-NC-ND license (<http://creativecommons.org/licenses/by-nc-nd/4.0/>).

## Introduction

Kidney traumatism are often unrecognized clinical entity or late diagnosed, especially in a context of poly traumatism. The hematuria occurring after an abdominal contusion is typically the revealing symptom of the urinary tract injury, but this symptom can be deficient thus increasing the risk of underestimating a kidney injury. The relatively high frequency of renal traumatism in children is related to the anatomical particular nature of the body which is less protected by an underdeveloped musculature and a scarce perirenal fat.<sup>1</sup> In the adult, renal injury often occurs after a violent traumatism, which explains why the renal traumatism is rarely isolated. About 10% of abdominal contusions are related to the kidney and the impact of pre-existing renal abnormalities in blunt traumatism of the kidney is estimated at 19%.<sup>2</sup> We report the case of a large renal papillary carcinoma discovered as a result of a minor abdominal contusion and treated with a radical nephrectomy.

## Observation

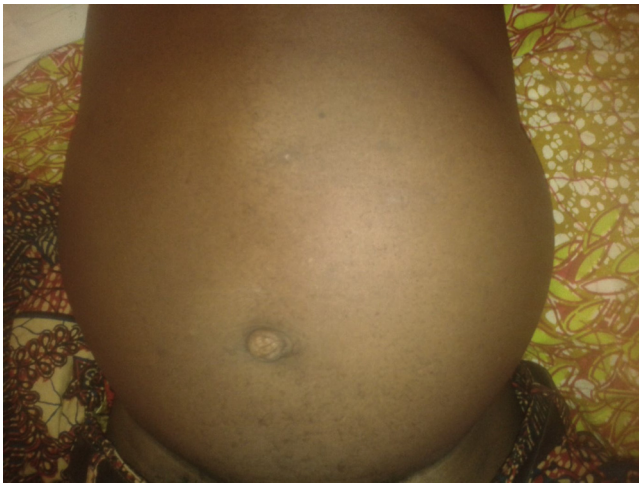Mr. T.K aged 72, without any previous medical and surgical history was admitted for a left abdominal and lumbar pain as a consequence of a fall during a traffic accident. The patient had lost control of his motorcycle while traveling at low speed (about 20 km/h). The shock was made on the left side of the body. During first hours after the accident, nothing was reported by the patient. The presentation to emergency occurred 18 h after the accident and was motivated by a left lumbar pain with a gradual increasing intensity.

The examination of the patient at admission showed a general good condition, a clear conscience, pallor of the conjunctiva and normal hemodynamic constants (TA = 12/8 cmHg, pulse = 84 ppm). The abdomen was distended, distorted by a mass of the left flank but without skin lesions as shown in Fig. 1. The urine was clear and limpid. Abdominal palpation helped to highlight a painful solid mass of the left lumbar region which presented regular contours.

Biologically, there was a severe normochromic normocytic anemia (hemoglobin rate = 5.5 g/dl), a hyper leukocytosis with a polynucleosis neutrophilia (PNN 10,160 mm<sup>-3</sup>), thrombocytosis 886 × 10<sup>3</sup> μl<sup>-1</sup>. The level of creatinine was 25 mg/l and glucose at 1.31 g/l.

\* Corresponding author.

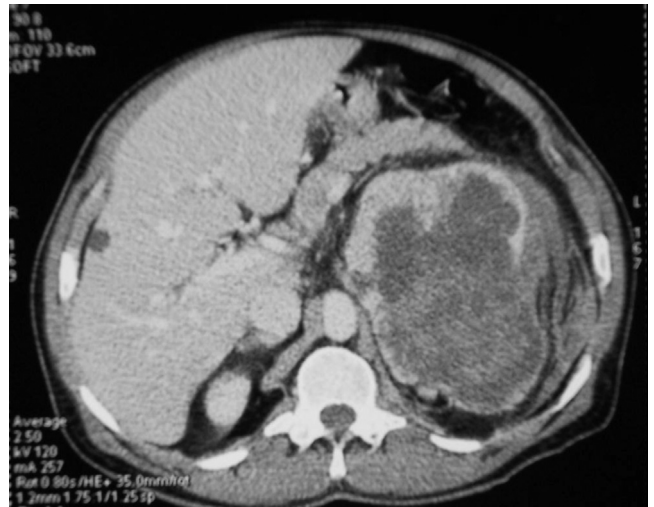E-mail address: [fakpatcha@yahoo.fr](mailto:fakpatcha@yahoo.fr) (T.M. Kpatcha).



**Figure 1.** Abdomen distended and distorted by a mass of the left flank in 72 years old man.

Abdominal ultrasonography showed heterogeneous tissue formation of the left renal lodge displacing neighboring structures. At the CT scan the mass was enhanced heterogeneously and was located in the upper pole of the left kidney; measuring 79 mm × 85 mm. On the series without injection, we observed a relatively discrete peripheral hyperdense area surrounding the gland which corresponded to a perirenal hematoma (Figs. 2 and 3). Neither thrombus image in the renal vein and the vena cava nor transfer lesions were observed. The massive deglobulization in our patient and the suspicion of a pre-existing renal tumor motivated the decision to nephrectomy in order to preserve the patient's vital prognosis.

To correct the bleeding, the patient received a transfusion of whole iso group iso rhesus blood. We then performed a left radical nephrectomy with ganglionic dredging by median laparotomy. The postoperative features were simple. Pathological examination of the surgical specimen revealed a papillary renal cell carcinoma grade 2 (type 1) according to Fühman (Fig. 4). The classification according to UICC 2009 was pT3N0M0.

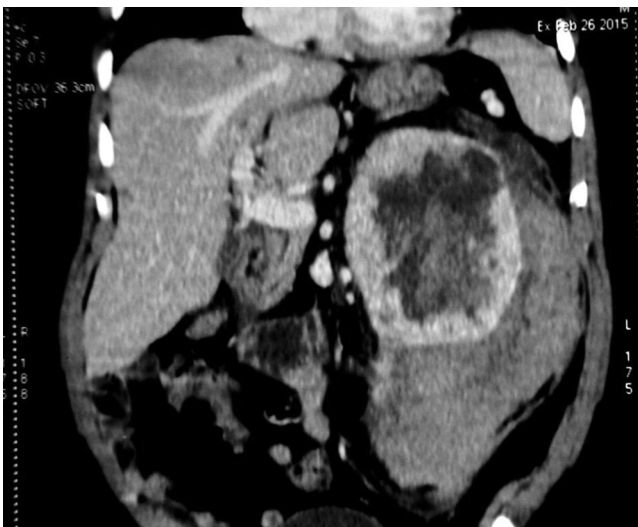

**Figure 3.** Axial view showing large mass of the left kidney.

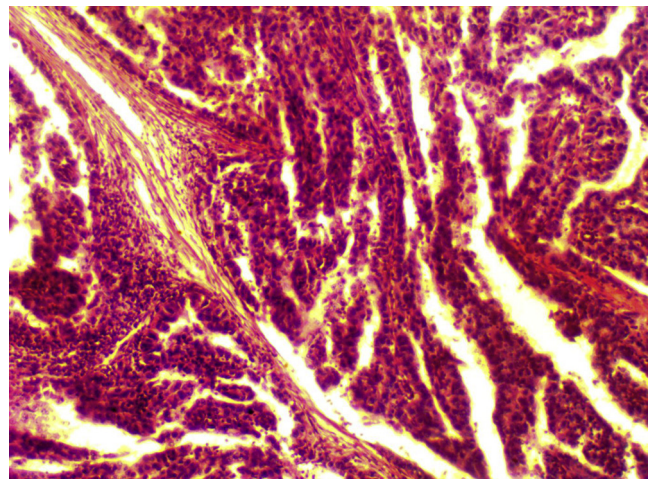
## Discussion

The association between traumatism and renal tumor poses two problems: a diagnostic problem and that of therapeutic. The diagnostic difficulty lies in the differential diagnosis often difficult to be made between perirenal hematoma and intrarenal one the hand and tumor tissue which may show signs of bleeding on the other hand. Abdominal Computer Tomography scan permits to draw up a balance sheet caused by a lesion through injected series; however, these results may seem insufficient for a formal diagnosis. The nature and velocity of the traumatism are important parameters in the interpretation of ultrasound images and scanner especially in cases of discrepancy between the results of the two explorations.<sup>1</sup> More sensitive explorations such as magnetic resonance imaging (MRI) can be important in the lesional characterization and the evaluation of peri lesional tissue.

Papillary carcinoma has the particular nature of being a necrotizing tumor especially when it is type 2; while type 1 papillary masses can take the appearance of a cystic formation. This explains the fragility of papillary tumors, and spontaneous breaking-offs have been reported.<sup>3</sup> This fragility explains the large hematoma occurred in our patient as a result of a minor traumatism.



**Figure 2.** Necrotic tumor of the left kidney and perirenal hematoma.



**Figure 4.** Papillary carcinoma on histological examination of surgical specimen.

Therapeutically, the gold standard of kidney trauma's management is a conservative treatment<sup>4,5</sup>; but this therapeutic modality poses the problem of evolutionary prognosis in cases of a tumorous kidney. The conservative attitudes adopted in kidney injuries should be discussed especially when imaging explorations are not formal with regards to the state of the gland. Therefore, it seems essential to eliminate any pre-existing renal disease before opting for a conservative treatment of kidney traumatism.

### Conclusion

The renal papillary carcinoma is a fragile tumor which can be revealed by a slight abdominal and lumbar contusion. It must be sought through appropriate investigations adapted to any case of kidney trauma.

### Conflict of interest

The authors declared no conflict of interest.

### References

1. De Campos Vieira Abib S, Torii Corrêa Leite M, Chaves Ribeiro R, et al. Renal tumor and trauma: a pitfall for conservative management. *Clin Urol*. 2011;37(4): 514–518.
2. Schmidlin FR, Iselin CE, Naimi A, et al. The higher injury risk of abnormal kidneys in blunt renal trauma. *Scand J Urol Nephrol*. 1998;32:388–392.
3. Hora M, Hes O, Klecka J, et al. Rupture of papillary renal cell carcinoma. *Scand J Urol Nephrol*. 2004;38(6):481–484.
4. Henderson CG, Sedberry-Ross S, Pickard R, et al. Management of high grade renal trauma: 20-year experience at a pediatric level I trauma center. *J Urol*. 2007;178: 246–250.
5. Broghammer JA, Langenburg SE, Smith SJ, Santucci RA. Pediatric blunt renal trauma: its conservative management and patterns of associated injuries. *Urology*. 2006;67:823–827.