

Sprengel's deformity as congenital scapular asymmetry on bone scintigraphy

ABSTRACT

Bone scintigraphy is a valuable imaging modality for a diverse range of skeletal abnormalities. Incidental findings and congenital skeletal anomalies are not uncommonly encountered. Therefore, having a substantial knowledge of these findings, even rare ones, is essential for interpreting physicians. Here, we present a case of previously diagnosed malignancy referred for a bone scintigraphy for skeletal metastatic survey, in which Sprengel's deformity as congenital scapular asymmetry and cervicothoracic scoliosis was noted.

Keywords: Bone scintigraphy, congenital skeletal anomaly, Sprengel's deformity

INTRODUCTION

Bone scintigraphy is a valuable and attractive imaging modality for a wide range of skeletal abnormalities. Incidental findings and congenital skeletal anomalies are not uncommonly encountered. Here, we present a case of previously diagnosed malignancy referred for a bone scintigraphy for skeletal metastatic survey, in which Sprengel's deformity (SD) as congenital scapular asymmetry and cervicothoracic scoliosis was noted.

CASE REPORT

A 59-year-old male with a history of concomitant laryngeal squamous cell carcinoma and lung adenocarcinoma referred to our laboratory for a whole-body bone scintigraphy for the evaluation of bone metastasis. During history taking and physical examination, we realized that shoulders were asymmetric in size, left side seemed to be smaller than opposite side. The left upper limb was weak and to some extent abnormally positioned. The patient stated that these skeletal abnormalities were congenital and did not use much his left upper limb. The patient has also been limping since his previous motor accident. A planar whole-body bone scintigraphy and spot view [Figures 1 and 2] were performed at 2 h after intravenous injection of 740 MBq of ^{99m}Tc -methylene

diphosphonate. As shown in Figure 1, significant asymmetric size of scapulae but the normal-appearing shape and slightly higher position of the left scapula are detected. Other findings were mild cervicothoracic scoliosis as well as slightly asymmetric upper limbs. Focal uptake at midshaft of the right tibia was compatible with a recent trauma.

DISCUSSION

There are a number of congenital or developmental musculoskeletal anomalies, among which some are related to scapula and shoulder.^[1-5] Although the bone scintigraphy is not the primary modality for evaluating congenital skeletal abnormalities, these findings are occasionally present or incidentally discovered.

MOHSEN QUTBI

Department of Nuclear Medicine, School of Medicine, Taleghani Educational Hospital, Shahid Beheshti University of Medical Sciences, Tehran, Iran

Address for correspondence: Dr. Mohsen Qutbi, Department of Nuclear Medicine, Taleghani Hospital, Yaman St., Velenjak, Tehran 1985711151, Iran.
E-mail: mohsen.qutbi@sbmu.ac.ir

This is an open access journal, and articles are distributed under the terms of the Creative Commons Attribution-NonCommercial-ShareAlike 4.0 License, which allows others to remix, tweak, and build upon the work non-commercially, as long as appropriate credit is given and the new creations are licensed under the identical terms.

For reprints contact: reprints@medknow.com

How to cite this article: Qutbi M. Sprengel's deformity as congenital scapular asymmetry on bone scintigraphy. World J Nucl Med 2019;18:61-2.


Access this article online	
Website: www.wjnm.org	Quick Response Code 
DOI: 10.4103/wjnm.WJNM_1_18	

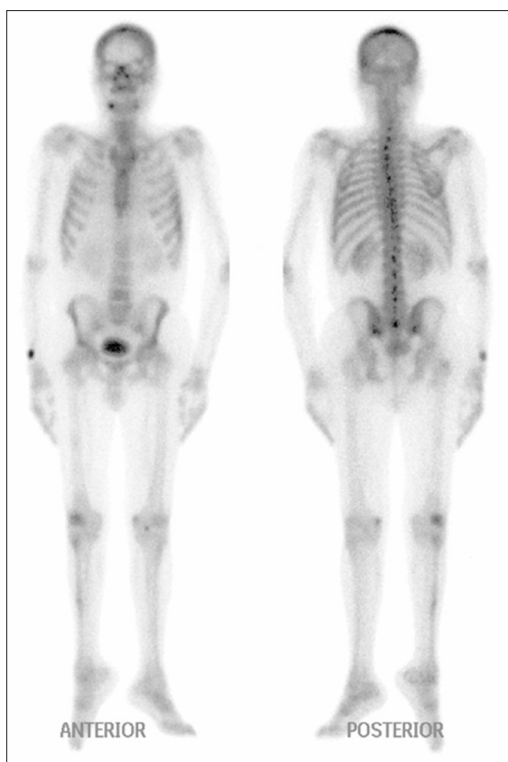

Figure 1: Anterior (left) and posterior (right) projections of whole-body bone scintigraphy. The scan demonstrates a congenital anomaly of the scapula, as called Sprengel's deformity. Otherwise, the study was negative for bone metastasis

Although congenital anomalies of the scapula are rare, the most common of which is which can be associated with other skeletal deformities (e.g., vertebral and rib deformities, spinal scoliosis, and spina bifida).^[2,6,7] To date, the embryogenic etiology of SD has not been convincingly elucidated.^[2,8] SD has been classified as low- to high-grade according to the severity of deformity.^[2,3,8] Scapula is usually hypoplastic or dysplastic with abnormally elevated position.^[2,3,6,8] The scapula on opposite side is usually normal, therefore shoulders appear asymmetric.^[2]

Since there is an increasing role for bone scintigraphy in daily practice for assessment of wide range of skeletal disorders, physicians should be familiar with many incidental and rare findings, including skeletal anomalies, on bone scintigraphy. Likewise, these abnormalities with abnormal uptake of radiotracer (either increased or decreased) may pose a significant challenge to interpretation and may mimic serious lesions particularly in patients suspected of metastatic skeletal diseases. To the best of our knowledge, no case of SD on bone scintigraphy has been reported.

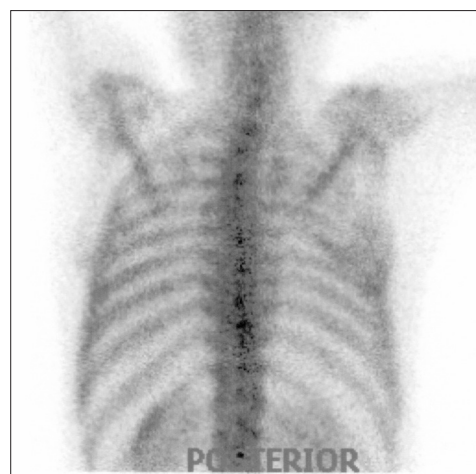


Figure 2: Posterior spot view of the thoracic region with arms raised over the heads that reveals asymmetric size and uptake (especially in borders) of scapulae. Here, with elevation of arms, the hypoplastic scapula shows its normal movement

Declaration of patient consent

The authors certify that they have obtained all appropriate patient consent forms. In the form the patient(s) has/have given his/her/their consent for his/her/their images and other clinical information to be reported in the journal. The patients understand that their names and initials will not be published and due efforts will be made to conceal their identity, but anonymity cannot be guaranteed.

Financial support and sponsorship

Nil.

Conflicts of interest

There are no conflicts of interest.

REFERENCES

1. McClure JG, Raney RB. Anomalies of the scapula. *Clin Orthop Relat Res* 1975;110:22-31.
2. Guillaume R, Nectoux E, Bigot J, Vandenbussche L, Fron D, Mézel A, *et al.* Congenital high scapula (Sprengel's deformity): Four cases. *Diagn Interv Imaging* 2012;93:878-83.
3. Cavendish ME. Congenital elevation of the scapula. *J Bone Joint Surg Br* 1972;54:395-408.
4. Currarino G, Sheffield E, Twickler D. Congenital glenoid dysplasia. *Pediatr Radiol* 1998;28:30-7.
5. Simanovsky N, Hiller N, Simanovsky N. Partial duplication of the scapula. *Skeletal Radiol* 2006;35:696-8.
6. Ozsahin M, Uslu M, Inanmaz E, Okur M. Bilateral congenital undescended scapula (sprengel deformity). *Am J Phys Med Rehabil* 2012;91:374.
7. Williams MS. Developmental anomalies of the scapula-the "omo"st forgotten bone. *Am J Med Genet A* 2003;120A: 583-7.
8. Kadavkolan AS, Bhatia DN, Dasgupta B, Bhosale PB. Sprengel's deformity of the shoulder: Current perspectives in management. *Int J Shoulder Surg* 2011;5:1-8.