

# Concomitant Avulsion Injury of the Subclavian Vessels and the Main Bronchus Caused by Blunt Trauma

Dongsub Noh, M.D.<sup>1,2</sup>, Chan-kyu Lee, M.D.<sup>1</sup>,  
Jung Joo Hwang, M.D., Ph.D.<sup>1,2</sup>, Hyun Min Cho, M.D., Ph.D.<sup>1</sup>

<sup>1</sup>Department of Trauma and Surgical Critical Care, Pusan National University Hospital,

<sup>2</sup>Department of Thoracic and Cardiovascular Surgery, Eulji University Hospital

Concomitant rupture of the subclavian vessels and the left main bronchus caused by blunt trauma is a serious condition. Moreover, the diagnosis of a tracheobronchial injury with rupture of the subclavian vessels can be difficult. This report describes the case of a 33-year-old man who suffered from blunt trauma that resulted in the rupture of the left subclavian artery and vein. The patient underwent an operation for vascular control. On postoperative day 3, the left main bronchus was found to be transected on a computed tomography scan and bronchoscopy. The transected bronchus was anastomosed in an end-to-end fashion. He recovered without any notable problems. Although the bronchial injury was not detected early, this case of concomitant rupture of the great vessels and the airway was successfully treated after applying extracorporeal membrane oxygenation.

*Key words:* 1. Blunt trauma  
2. Bronchus  
3. Vessels

## Case report

The left shoulder of a 33-year-old man was jammed between large rollers. His left shoulder was dislocated and swollen. The blood pressure and pulse rate in the right arm was <60 mm Hg and 139 beats/min, but no pressure or pulse was detected in the left arm. A computed tomography (CT) scan showed bilateral hemopneumothorax, extravasation from the left subclavian artery, imprecise findings of the left subclavian vein (Fig. 1A), and possible complete transection of the left main bronchus (Fig. 1B). Emergency surgery began with a left infraclavicular incision, extending to a median sternotomy to expose the proximal portion of the left subclavian vessels.

The left subclavian artery was dissected for about 5 cm and the left subclavian vein was unidentifiable. After careful consideration, we decided to attempt vessel reconstruction. The proximal and distal parts of the ruptured subclavian artery were resected and replaced with a 7-mm Gore-Tex graft anatomically, in an end-to-end fashion. The vein was sacrificed due to its unrecognizable vascular shape (Fig. 2). There were no specific findings on a postoperative chest X-ray. For sustained hypoxemia, the patient received veno-venous extracorporeal membrane oxygenation (ECMO) via both femoral veins. Due to severe edema of the mediastinum, the sternotomy incision could not be closed. On the following day, the sternum was closed without complications.

Received: August 14, 2017, Revised: October 12, 2017, Accepted: October 23, 2017, Published online: April 5, 2018

Corresponding author: Hyun Min Cho, Division of Trauma and Surgical Critical Care, Department of Thoracic and Cardiovascular Surgery, Pusan National University Hospital, 179 Gudeok-ro, Seo-gu, Busan 49241, Korea (Tel) 82-51-240-7369 (Fax) 82-51-240-7719 (E-mail) [csking1@daum.net](mailto:csking1@daum.net)

© The Korean Society for Thoracic and Cardiovascular Surgery. 2018. All right reserved.

© This is an open access article distributed under the terms of the Creative Commons Attribution Non-Commercial License (<http://creativecommons.org/licenses/by-nc/4.0>) which permits unrestricted non-commercial use, distribution, and reproduction in any medium, provided the original work is properly cited.

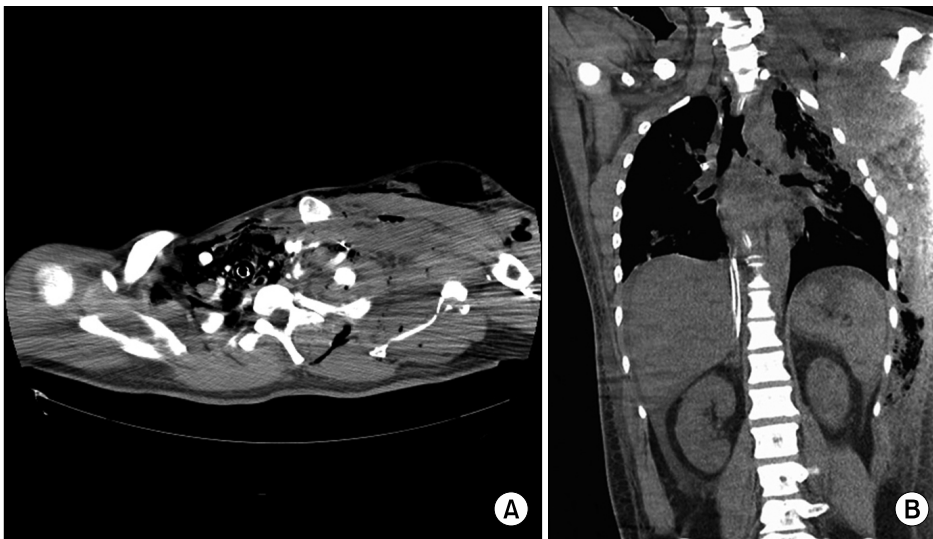


Fig. 1. (A) A CT scan showed extravasation from the left subclavian artery and imprecise findings of the left subclavian artery and vein. (B) A chest CT scan showed complete transection of the left main bronchus. CT, computed tomography.

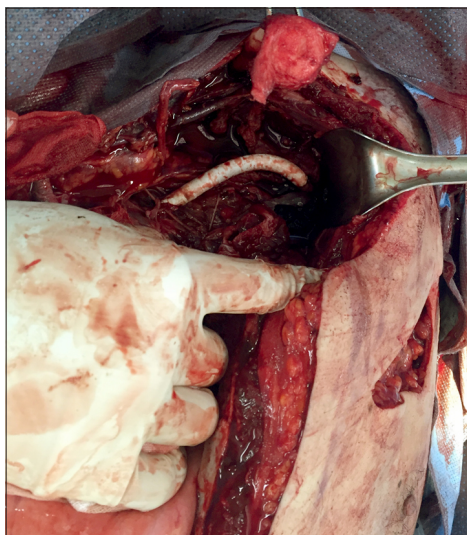


Fig. 2. The proximal and distal parts of the ruptured subclavian artery were resected and replaced with a 7-mm Gore-Tex graft anatomically in an end-to-end fashion. The vein was sacrificed due to its unrecognizable vascular shape.

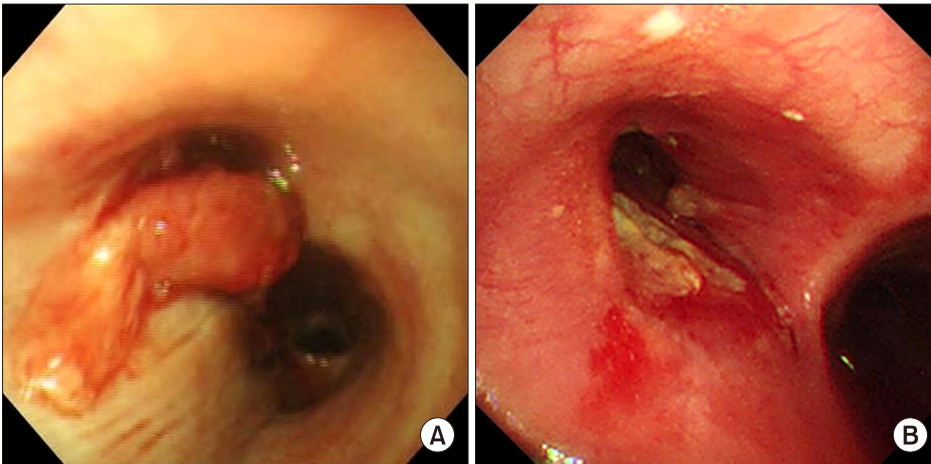
On post-trauma day 3, we performed bronchoscopy for pulmonary toilet because of total atelectasis of his left lung. An obstructing piece of soft tissue was found in the left main bronchus (Fig. 3A). We performed primary repair of the transected bronchus through a left lateral thoracotomy. Both ends of the transected bronchus were anastomosed in an end-to-end fashion. The patient was weaned from ECMO on postoperative day 7 and from the mechanical ventilator on postoperative day 23. Bronchoscopy

showed a well-healed and nearly intact left main bronchus on postoperative day 25 (Fig. 3B). The patient recovered without any notable problems.

## Discussion

Cases of tracheobronchial avulsion or subclavian vessel injury have been described [1,2]; however, no case of concomitant bronchial avulsion and subclavian vessel injury from blunt chest trauma has yet been reported. This type of injury from blunt trauma to the thorax is rare, and is caused by neck hyperextension along with the movement of the heart movement to pressure between the sternum and thoracic vertebrae [1]. We cannot explain the exact mechanism of the bronchial rupture. We suggest that the cause of bronchial rupture may be not only the pulling force on his left arm and shoulder stretched the subclavian vessels but also the crushing injury to his left chest caused the alteration of intrathoracic pressure.

The diagnosis of a tracheobronchial injury is difficult [3]. A bronchial injury is suspected when continuous air leakage is present. Bronchial injuries are diagnosed through bronchoscopy, and CT scans can localize the level of the rupture [2,3]. In this case, the bronchial injury could not be found due to severe swelling of the mediastinal tissue, and bronchial patency was observed on the first CT scan. We adopted a damage control strategy due to the patient's unstable vital signs, and the sternum was



**Fig. 3.** (A) On bronchoscopy, soft tissue was found in the left main bronchus, obstructing the distal bronchus. (B) Postoperative bronchoscopy showed a healed and intact left main bronchus.

opened due to mediastinal edema. The bronchial injury was identified later via bronchoscopy due to total atelectasis of the left lung on a chest X-ray. The early detection of bronchial injuries is crucial, as delayed diagnoses can be lethal [3]. In this case, although the bronchial injury was not found immediately, the patient survived due to the application of ECMO.

The early repair of bronchial injuries results in good outcomes, with an almost complete recovery of pulmonary function. Delayed repair attempts may have complications such as poorer lung function, an increased risk of empyema, and hilar abscesses [3]. Furthermore, the mortality of pneumonectomy for patients in shock approaches 100% due to uncontrolled hemorrhage or acute right heart failure [4]. During surgery, we considered a left pneumonectomy; however, we eventually decided to perform bronchial repair to promote early postoperative recovery and prevent post-pneumonectomy problems. The patient's lung function quickly recovered without any problems after the operation. Fortunately, neither dehiscence nor stricture of the anastomosis site took place.

Injured arteries can be reconstructed using autologous blood vessels, such as the saphenous vein, or commercial Gore-Tex grafts [5]. The advantages of using autologous blood vessels include resistance to infection and the absence of a need for anticoagulation. However, we could not use autologous

blood vessels in this case since the patient was hemodynamically unstable.

Despite the extensive damage to the left subclavian artery and vein, we were able to save the patient's life and left arm. Although the bronchial injury was not detected early, the patient's left lung was saved after ECMO application. We report this successfully-treated concomitant bronchial avulsion and left subclavian vessel injury.

### Conflict of interest

No potential conflict of interest relevant to this article was reported.

### References

1. Hirose H, Gill IS. *Blunt injury of proximal innominate artery*. Ann Thorac Cardiovasc Surg 2004;10:130-2.
2. Mahmoulou R, Sepehrvand N. *Tracheobronchial injury due to blunt chest trauma*. Int J Crit Illn Inj Sci 2015;5:116-8.
3. Vantroyen B, De Baetselier H. *Tracheal rupture after blunt trauma*. Eur J Trauma Emerg Surg 2008;34:410-3.
4. Alfici R, Ashkenazi I, Kounavsky G, Kessel B. *Total pneumonectomy in trauma: a still unresolved problem: our experience and review of the literature*. Am Surg 2007;73:381-4.
5. Noh DS, Park NH, Kim JB, Kim HT, Yoon KC, Choi SY. *Innominate artery rupture after blunt chest trauma*. Korean J Thorac Cardiovasc Surg 2007;40:871-3.