

# Indocyanine-based near-infrared lymphography for real-time detection of lymphatics in a cat with multiple mast cell tumours

*Journal of Feline Medicine and Surgery Open Reports*  
1–7

© The Author(s) 2022

Article reuse guidelines:

sagepub.com/journals-permissions

DOI: 10.1177/20551169221074961

journals.sagepub.com/home/jfmsopenreports

This paper was handled and processed by the European Editorial Office (ISFM) for publication in *JFMS Open Reports*



Raphael Arz<sup>1</sup> , Frauke Seehusen<sup>2</sup>,  
Valeria S Meier<sup>3,4</sup> and Mirja C Nolff<sup>1</sup>

## Abstract

**Case summary** An 11-year-old female domestic shorthair cat was presented with cutaneous mast cell tumours (MCTs) localised at the right temporal region, the left buccal region and on the third digit of the right thoracic limb. Staging was negative and locoregional lymph nodes appeared normal, based on clinical findings. During surgery, real-time indocyanine green (ICG)-based lymphography was performed to detect the cutaneous draining pattern of all the primary MCTs. ICG was injected intracutaneously in four quadrants around each tumour, and a clear lymphogram was visible shortly after injection. Using near-infrared lymphography (NIR-L) for guidance, all lymphadenectomies were performed in 12 mins or less, with a maximal incision length of 3.5 cm. The smallest resected node was 0.9 cm in diameter. All MCTs were classified as low-grade cutaneous MCT. All four ICG-positive lymph nodes were considered premetastatic or metastatic. The only ICG-negative resected node was also negative for tumour cells. No complications related to NIR-L were recorded.

**Relevance and novel information** This is the first description of NIR-L in a cat with MCT. Application was straightforward and ICG enrichment only occurred in the metastatic nodes, suggesting correct identification of lymphatic draining patterns. Of note, as previously described in dogs, we did detect nodal metastasis, despite low-grade primary tumours. The clinical relevance should be evaluated in future studies.

**Keywords:** Feline MCT; lymph node metastasis; lymph node mapping; indocyanine green; sentinel lymph node

**Accepted:** 4 January 2022

## Introduction

Cutaneous mast cell tumour (MCT) is assumed to be the second most common cutaneous tumour in cats, accounting for 20% of all cutaneous tumours.<sup>1,2</sup> Although cutaneous MCTs are common, little is known about their biological behaviour.<sup>2,3</sup> Most cutaneous MCTs are currently considered benign with possible local recurrence.<sup>4–6</sup> Surgical excision is the treatment of choice.<sup>7,8</sup> Unlike in canine MCT, there are no well-established recommendations regarding surgical dosage. Currently, lymph nodes are only excised if staged positive or enlarged.<sup>9</sup> Owing to a lack of larger studies evaluating the issue of nodal metastasis in cats, little is known about the frequency and impact of nodal metastasis in this species. In contrast to this, the role of

lymph node management has become increasingly evident in canine patients.<sup>10–14</sup>

One problem in the treatment of nodal disease in tumour-bearing patients is the identification of the

<sup>1</sup>Clinic for Small Animal Surgery, Department for Small Animals, Vetsuisse Faculty, University of Zurich, Switzerland

<sup>2</sup>Institute of Veterinary Pathology, Vetsuisse Faculty, University of Zurich, Switzerland

<sup>3</sup>Clinic for Oncology and Radiation Oncology, Department for Small Animals, Vetsuisse Faculty, University of Zurich, Switzerland

<sup>4</sup>Department of Physics, University of Zurich, Switzerland

### Corresponding author:

Raphael Arz DVM, Clinic for Small Animal Surgery, Department for Small Animals, Winterthurerstrasse 260, Zürich 8057, Switzerland

Email: rarz@vetclinics.uzh.ch



Creative Commons Non Commercial CC BY-NC: This article is distributed under the terms of the Creative Commons

Attribution-NonCommercial 4.0 License (<https://creativecommons.org/licenses/by-nc/4.0/>) which permits non-commercial use, reproduction and distribution of the work without further permission provided the original work is attributed as specified on the SAGE and Open Access pages (<https://us.sagepub.com/en-us/nam/open-access-at-sage>).

draining nodes (also called sentinel nodes). The sentinel lymph node (SLN) is the first lymph node for a tumour to drain.<sup>10</sup> Unfortunately, this node is not always the nearest node to the tumour.<sup>11</sup> In order to determine which node should be considered the draining node and removed, different mapping techniques to detect draining patterns have been developed. Of these, lymphoscintigraphy is still considered to be the gold standard.<sup>12</sup> Unfortunately, owing to legal restrictions and limited access to lymphoscintigraphy in veterinary medicine, this technique is not broadly available. Other techniques for SLN detection have been developed and validated in human medicine. Among these, near-infrared lymphography (NIR-L) after indocyanine green (ICG) injection has been proven to have a very high sensitivity and specificity to detect SLN compared with lymphoscintigraphy. Owing to its good performance, this technique is now frequently used to detect the SLN in humans.

For NIR-L, a fluorescent dye – ICG – is injected into four quadrants around the tumour. As the dye is transported by the lymphatics (within minutes), the lymphatics can be seen using an NIR camera system. This technique can then guide the surgeon to more precise and faster excision of the SLN.<sup>13,14</sup>

So far, the application of ICG-based NIR fluorescence has only been reported for visualisation of the vasculature during reconstructive surgery in two cats.<sup>15</sup> The present report describes the first application of ICG NIR-L in a cat with MCT.

## Case description

An 11-year-old spayed female domestic shorthair cat was presented with three firm masses on the right temporal region, the left buccal region and on the third digit of the right thoracic limb. Each mass was 2–3 mm in diameter and cytology of the masses revealed the presence of mast cells suggestive of MCTs. Staging of the cat, a chemistry profile, complete blood count, thoracic radiographs and abdominal ultrasonography were performed. To complete staging, a fine-needle aspiration of the liver, spleen, and the left and right mandibular lymph nodes were submitted for cytological evaluation. The left and right mandibular lymph nodes showed reactive hyperplasia, the spleen was cytologically unremarkable and the aspiration of the liver was non-diagnostic. The aspiration of the liver was not repeated. No further abnormalities were detected.

Owing to the mildly enlarged mandibular node and low sensitivity of cytology to detect potential metastasis, lymphadenectomy was recommended. Real-time ICG-based NIR-L was offered to detect the draining patterns of the tumours and guide lymphadenectomy; the owners elected for this procedure to be performed.

Anaesthesia was induced and maintained by a board-certified anaesthetist (DECVAA). The cat was clipped and washed to allow visualisation of the suspected

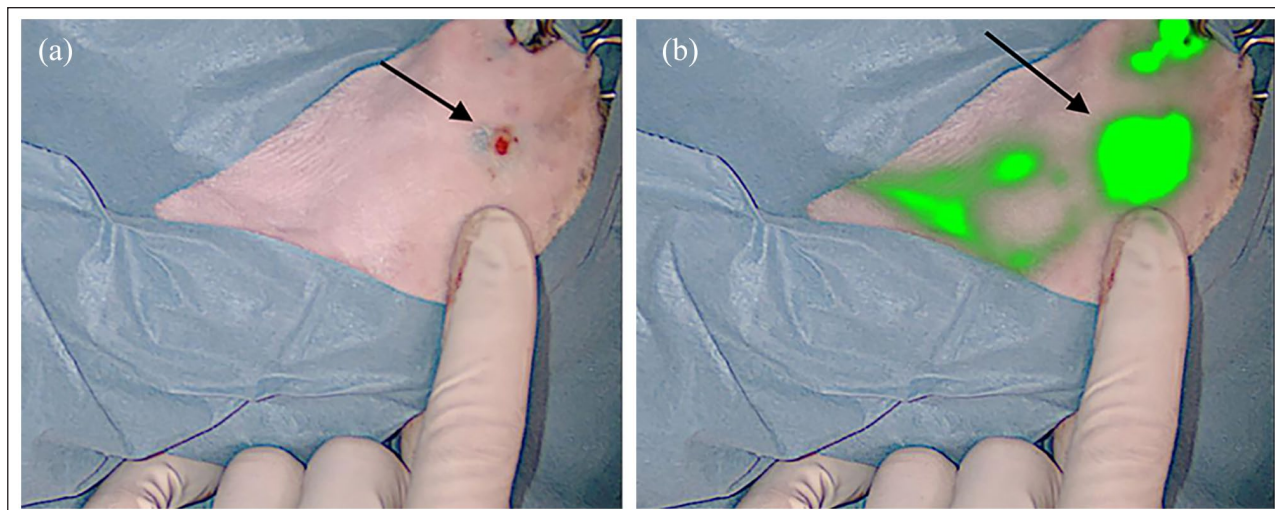
draining tracts and all primary surgical fields. This included the head, the entire cervical region and the right thoracic limb, as well as the pre-scapular and axillary area bilaterally. After positioning the patient, a total of 1.5 ml of ICG (Verdye 5 mg/ml; Diagnostic Green) was injected in four quadrants around each tumour (0.5 ml volume per tumour) under sterile conditions. Care was taken to aspirate each before withdrawing the needle after each skin injection to minimise skin contamination with the dye. Routine skin disinfection was completed thereafter and the cat was draped for surgery. Through manipulation of the skin during disinfection, ICG travelled within the lymphatics and was then visualised with an EleVision near-infrared camera system (Medtronic) at a predefined lymphography setting. To find the node of interest, the lymphatics were followed until the point at which where they were no longer visible in the skin. A skin incision was made at this point and the node was visualised by dissecting the subcutaneous tissue until the direct signal of the node became directly visible. Intraoperative pictures were taken with the NIR camera system.

The MCT of the left buccal region drained to a non-enlarged ipsilateral mandibular node, as well as the ipsilateral superficial cervical node (Figure 1). The MCT of the right temporal region drained to the ipsilateral superficial cervical node. The MCT at the right third digit of the thoracic limb drained to the right axillary lymph node (Figure 2). Lymphadenectomy of all positive nodes was performed under NIR guidance (Figure 3). The time from skin incision until complete lymph node excision, length of the incision required and size of each lymph node were recorded (Table 1).

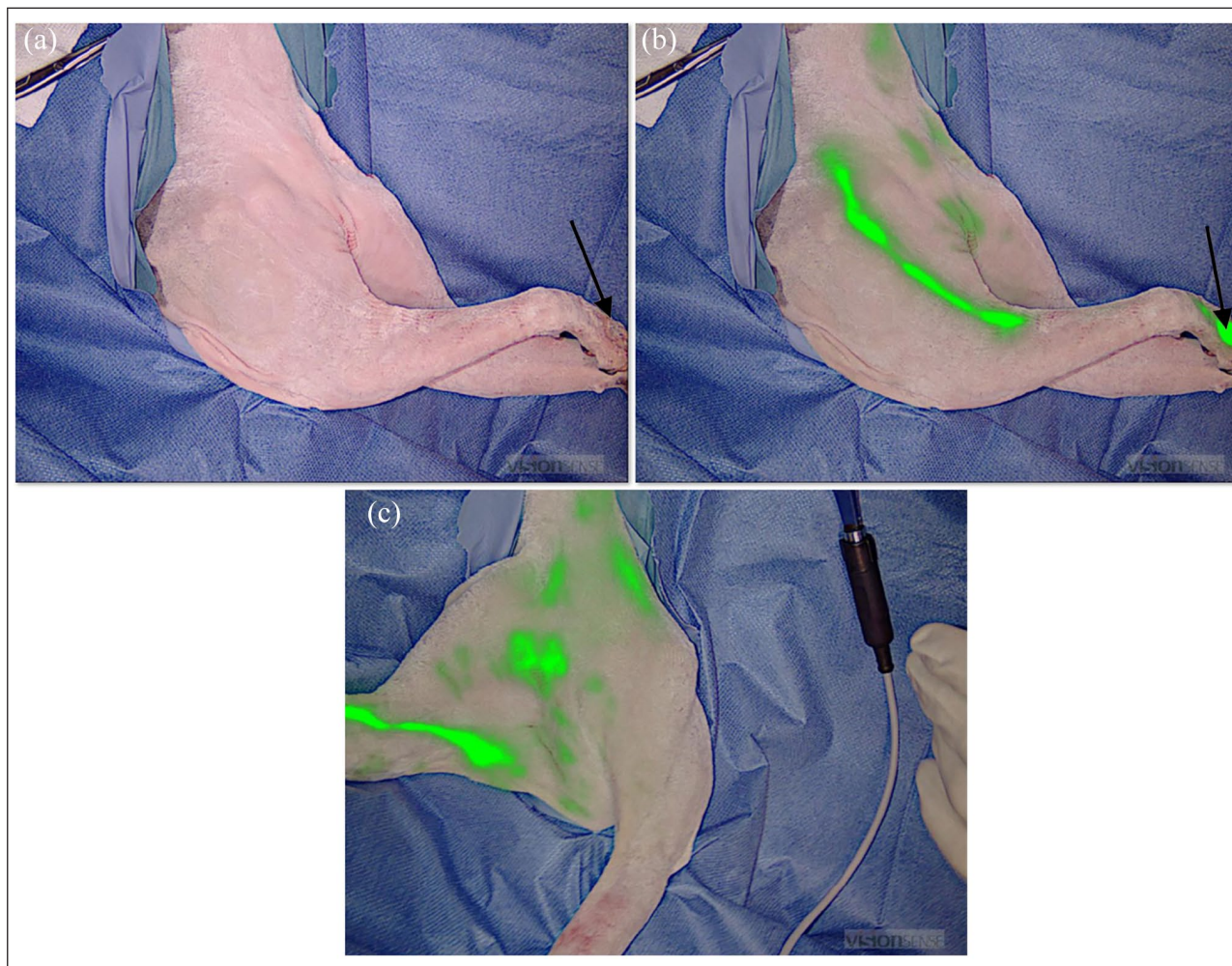
During the approach to the left mandibular node, a second non-enhancing node was also detected and resected. The wounds were routinely closed using polyglyconate 3-0 material (Monosyn; B Braun) and polyamid 4-0 material (Supramid; B Braun). After lymphadenectomy, the MCTs were excised. To reach margins, the third digit of the right thoracic limb was amputated at the base of the first phalanx. The MCT of the buccal region was excised en bloc, including the skin and oral mucosa. The MCT of the temporal region was excised using a simple elliptic incision with 5 mm margins and a deep fascia as deep margins. Routine wound closure was completed.

Margins were stained and the resected masses, as well as the lymph nodes, were sent for histopathological evaluation. The cat recovered uneventfully and was discharged the following day. Postoperative analgesia was obtained using buprenorphine (buprenorphine 0.025 mg/kg; Universitätsapotheke) 0.02 mg/kg PO for 5 days.

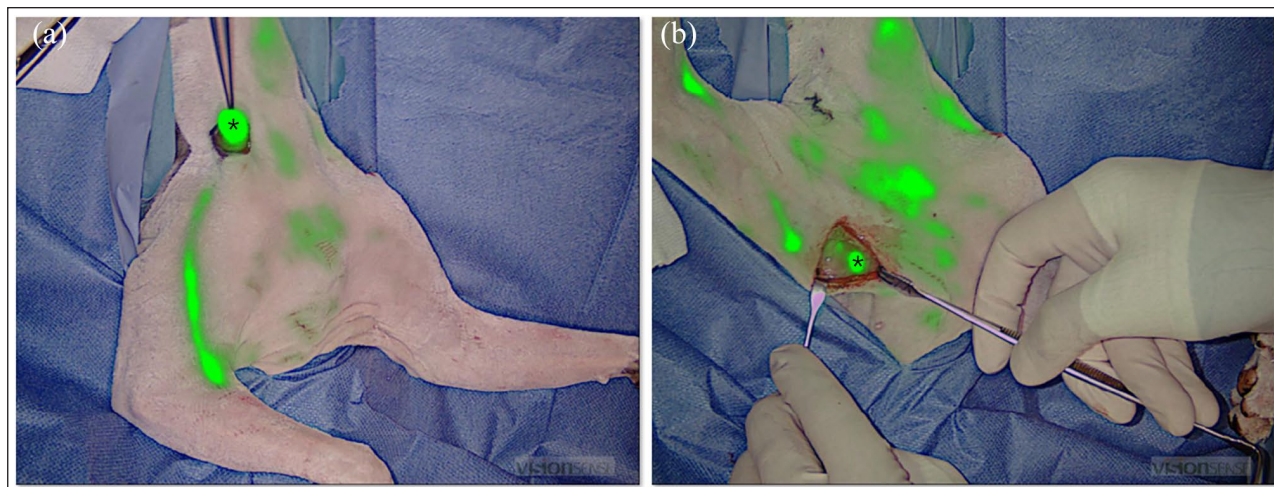
Pathohistological evaluation was carried out by a board-certified pathologist (FS). MCTs were graded according to the grading scheme of Sabattini and Bettini<sup>17</sup>



**Figure 1** Intraoperative pictures of the mandibular lymph nodes. The arrows indicate the location of the lymph node (a) without and (b) with activated the fluorescein camera



**Figure 2** Intraoperative images showing the lymphatic pathway of the mast cell tumour at the digit (indicated by the black arrows in [a] and [b]). The camera is deactivated in (a) and activated in (b) and (c). Following the green line, the tumour drains in the direction of the (b) right superficial cervical and (c) right axillary lymph nodes



**Figure 3** Intraoperative images showing fluorescein enrichment in (a) the right pre-scapular and (b) the right axillary lymph nodes. The lymph node is indicated with an asterisk in both pictures

**Table 1** Summary of all excised lymph nodes (LNs), including the length of the skin incision, time from skin incision until LN excision, grading according to Weishaar et al,<sup>16</sup> size and whether the indocyanine green (ICG) signal was positive or negative

Lymph node	Length of skin incision (cm)	Time taken for skin incision until lymph node excision (mins)	Grading	Size (cm)	ICG signal
Superficial cervical left	2.5	2.3	HN1	0.9 × 0.5 × 0.5	Yes
Superficial cervical right	1.5	1.3	HN2	1 × 0.8 × 0.4	Yes
Axillaris	3.5	12	HN1	0.9 × 0.5 × 0.5	Yes
Mandibularis 1	No additional incision	5	HN1	1 × 0.6 × 0.3	Yes
Mandibularis left 2	No additional incision	5	HN0	0.9 × 0.5 × 0.4	No

In the absence of a grading scheme for lymph nodes in cats, nodes were graded based on Weishaar et al;<sup>16</sup> however, it should be noted that this system has not been validated in cats

**Table 2** Summary of the masses, including grading according to Sabattini and Bettini,<sup>17</sup> size and completeness of excision

Region	Size (mm)	Grading	Complete excision
Digit	2.2	Low grade	Yes
Temporal	2.6	Low grade	Yes
Buccal	5.1	Low grade	Yes

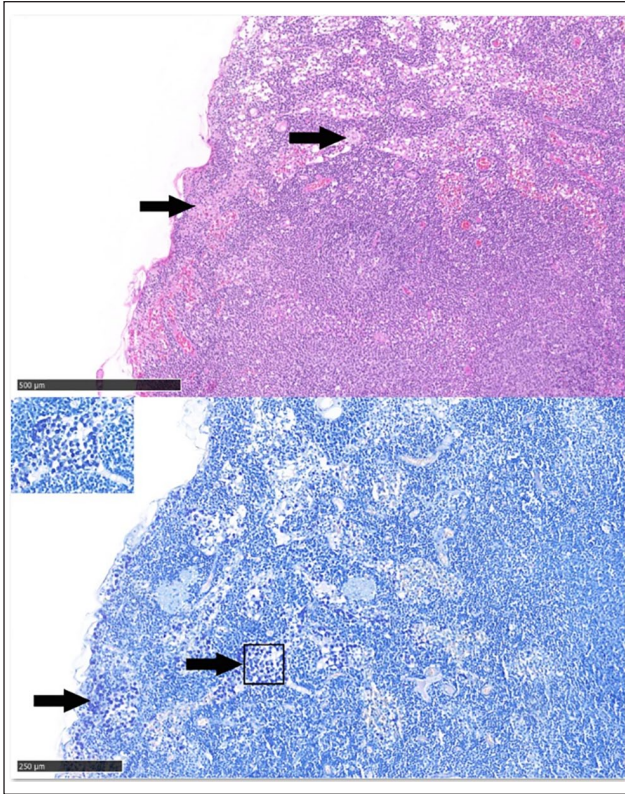
and came back as completely excised low-grade tumours (Table 2). Owing to the absence of a grading scheme for lymph nodes in cats, the nodes were graded according to Weishaar et al (Table 1, Figure 4).<sup>16</sup> All ICG-positive nodes came back graded as HN1 or HN2, while the non-enhancing node was graded HN0.

At recheck, 6 days postoperatively, an intraoral dehiscence was observed at the resection site of the buccal MCT, which was debrided intraorally, cleaned with saline and left to heal by second intention. All other sites were unremarkable and skin sutures were

removed 10 days after surgery. No other complications were detected. Based on the results of surgery, no adjuvant treatment was started. At the time of writing, 5 months after surgery, the cat had no recurrence or progression of the disease.

## Discussion

NIR-L was easy to perform and resulted in clear delineation of the lymphatics and associated lymph nodes in this cat. In addition, the NIR-L led to precise identification of positive nodes, and thereby greatly



**Figure 4** Histopathological images of the right pre-scapular lymph node (HN2, according to Weishaar et al<sup>16</sup>). The top image shows haematoxylin and eosin staining of the lymph node (scale bar = 500 µm). The bottom image shows a Giemsa staining of the same lymph node (scale bar = 250 µm). In both images, the arrows indicate neoplastic mast cells within the lymph node sinuses. The inset shows a higher magnification of aggregated neoplastic mast cells ( $\times 200$  magnification)

facilitated the removal of small, non-palpable nodes. This is underlined by the short duration per lymphadenectomy. Without intraoperative enhancement of the lymphatics, it can be hard to identify a lymph node during surgery, as small portions of fat can look alike. NIR-L resulted in fast lymphadenectomy (a maximum of 12 mins per lymph node) and did not add considerable time to surgery per se. As longer surgery duration correlates with higher surgery-related morbidity, this is an important finding.<sup>18</sup>

ICG travels within the lymphatics and this can be visualised using NIR-L through the skin and followed. The node of interest can be found where the lymphatic seems to stop (as it dives deep towards the node). A skin incision is made at this point and the node is visualised by following the tract towards the expected anatomical location until it becomes directly visible.

ICG applications in cats have rarely been reported. Application of the drug at an intravenous (IV) dose of 1.5 mg/kg is safe in cats. Plasma clearance in cats is

faster than in dogs (mean  $8.6 \pm 4.1$  ml/min/kg). The substance is exclusively cleared via the hepatic route.<sup>19</sup>

So far, applications have mainly been published in ophthalmology where IV ICG is applied to allow angiography of the choroidal arteries (dosing 1–1.5 mg/kg IV).<sup>20</sup> In addition, a recent case report described IV application of ICG at a dose of 2.5 mg per cat for visualisation of the caudal auricular artery in two cats undergoing reconstruction after tumour resections.<sup>15</sup>

Of note, in the single case of this report the ICG signal also corresponded with the presence of mast cell metastasis. As this is a single case, and only one non-enhancing node had been resected as a control, this finding must not be overrated. In dogs and humans, it has been shown that scarring or overt metastasis can disrupt lymphatic flow and result in ICG-negative nodes, despite metastatic disease being present.<sup>21,22</sup> As ICG is non-tumour-specific, we consider it unlikely that the dye is specific for the detection of metastatic disease in cats. Nevertheless, we found two lymph nodes (left mandibular) directly adjacent to each other with two different signal patterns, with a positive signal related to the presence of mast cells and a negative signal found in a node that had no mast cell infiltration. For us, this fact strengthens the theory that ICG NIR-L could be effective in the detection of draining patterns in cats.

Several other studies have previously recorded a high sensitivity and specificity of ICG in the detection of SLN in human medicine. Two large meta-analyses in human medicine that included patients with breast cancer, as well as oncological patients irrespective of cancer type, concluded that the technique is equivalent to the gold standard of lymphoscintigraphy and superior to methylene blue mapping in human patients.<sup>23,24</sup> Comparable studies or meta-analyses are currently lacking in veterinary medicine. However, a study performed in dogs with oral neoplasia recently underlined the superior performance of ICG to methylene blue and CT lymphography.<sup>25</sup> Applications in cats have so far not been published. This case has shown that NIR-L is easy to perform in a cat and two clear lymphograms could be generated. Further studies should be conducted to validate this technique in feline patients.

Finally, the cat was presented with three MCTs, all considered low grade on histopathology. Despite this, nodal metastasis was present in four nodes (ranging from pre-metastatic to early metastasis if graded based on Weishaar et al<sup>16</sup>).

Feline MCTs are usually considered to be benign. Recently, Sabattini and Bettini proposed a two-tier grading scheme for feline MCT.<sup>17</sup> In this study, low-grade cutaneous MCT in cats did not reach the median survival time, whereas high grades had a median survival time of 349 days.<sup>17,26</sup> Grading schemes for nodal metastasis are currently not available for cats. In

contrast to this, a grading scheme for lymph node metastasis has been developed for dogs by Weishaar et al.<sup>16</sup> The authors have proven a predictive value with respect to survival time.<sup>16,27,28</sup> Based on the impact on survival, adjunctive chemotherapy is recommended in dogs with HN3 metastatic nodes, irrespective of the grade of the primary tumour.<sup>29</sup> In addition, Marconato et al have demonstrated that surgical resection of metastatic nodes improves survival.<sup>30</sup>

In cats, information about the role of nodal metastasis is largely missing. Studies evaluating splenic MCTs have demonstrated a poorer prognosis in cats with affected lymph nodes; with respect to cutaneous tumours, the role remains unknown.

Nevertheless, there is a chance that the observations made in dogs might also be relevant in cats. In order to prove this, additional studies will be needed.

## Conclusions

NIR lymph node mapping was a safe procedure that helped to identify and resect normal-sized metastatic lymph nodes in a cat with MCT. To evaluate the possible overall impact, further investigations and evaluation of the prognostic and therapeutic value of lymph node staging in cats are needed.

**Conflict of interest** The authors declared no potential conflicts of interest with respect to the research, authorship, and/or publication of this article.

**Funding** The authors received no financial support for the research, authorship, and/or publication of this article.

**Ethical approval** The work described in this manuscript involved the use of non-experimental (owned or unowned) animals. Established internationally recognised high standards ('best practice') of veterinary clinical care for the individual patient were always followed and/or this work involved the use of cadavers. Ethical approval from a committee was therefore not specifically required for publication in *JFMS Open Reports*. Although not required, where ethical approval was still obtained it is stated in the manuscript.

**Informed consent** Informed consent (verbal or written) was obtained from the owner or legal custodian of the animal(s) described in this work (experimental or non-experimental animals, including cadavers) for all procedure(s) undertaken (prospective or retrospective studies). No animals or people are identifiable within this publication, and therefore additional informed consent for publication was not required.

**ORCID iD** Raphael Arz  <https://orcid.org/0000-0001-8894-5209>

Valeria S Meier  <https://orcid.org/0000-0003-0793-9005>

## References

- 1 Miller MA, Nelson SL, Turk JR, et al. **Cutaneous neoplasia in 340 cats.** *Vet Pathol* 1991; 28: 389–395.
- 2 Blackwood L, Murphy S, Buracco P, et al. **European consensus document on mast cell tumours in dogs and cats.** *Vet Comp Oncol* 2012; 10: e1–e29.
- 3 Molander-McCrary H, Henry CJ, Potter K, et al. **Cutaneous mast cell tumors in cats: 32 cases (1991–1994).** *J Am Anim Hosp Assoc* 1998; 34: 281–284.
- 4 Litster AL and Sorenmo KU. **Characterisation of the signalment, clinical and survival characteristics of 41 cats with mast cell neoplasia.** *J Feline Med Surg* 2006; 8: 177–183.
- 5 Sabattini S and Bettini G. **Prognostic value of histologic and immunohistochemical features in feline cutaneous mast cell tumors.** *Vet Pathol* 2010; 47: 643–653.
- 6 Johnson TO, Schulman FY, Lipscomb TP, et al. **Histopathology and biologic behavior of pleomorphic cutaneous mast cell tumors in fifteen cats.** *Vet Pathol* 2002; 39: 452–457.
- 7 Rassnick KM, Williams LE, Kristal O, et al. **Lomustine for treatment of mast cell tumors in cats: 38 cases (1999–2005).** *J Am Vet Med Assoc* 2008; 232: 1200–1205.
- 8 Henry C and Herrera C. **Mast cell tumors in cats: clinical update and possible new treatment avenues.** *J Feline Med Surg* 2013; 15: 41–47.
- 9 Oliveira MT, Campos M, Lamego L, et al. **Canine and feline cutaneous mast cell tumor: a comprehensive review of treatments and outcomes.** *Top Companion Anim Med* 2020; 41: 100472.
- 10 Tanis PJ, Nieweg OE, Valdes Olmos RA, et al. **History of sentinel node and validation of the technique.** *Breast Cancer Res* 2001; 3: 109–112.
- 11 Lapsley J, Hayes GM, Janvier V, et al. **Influence of loco-regional lymph node aspiration cytology vs sentinel lymph node mapping and biopsy on disease stage assignment in dogs with integumentary mast cell tumors.** *Vet Surg* 2021; 50: 133–141.
- 12 Beer P, Pozzi A, Rohrer Bley C, et al. **The role of sentinel lymph node mapping in small animal veterinary medicine: a comparison with current approaches in human medicine.** *Vet Comp Oncol* 2018; 16: 178–187.
- 13 Favril S, Stock E, Hernot S, et al. **Sentinel lymph node mapping by near-infrared fluorescence imaging and contrast-enhanced ultrasound in healthy dogs.** *Vet Comp Oncol* 2019; 17: 89–98.
- 14 Schrenk P, Rieger R, Shamiyeh A, et al. **Morbidity following sentinel lymph node biopsy versus axillary lymph node dissection for patients with breast carcinoma.** *Cancer* 2000; 88: 608–614.
- 15 Quinlan ASF, Wainberg SH, Phillips E, et al. **The use of near infrared fluorescence imaging with indocyanine green for vascular visualization in caudal auricular flaps in two cats.** *Vet Surg* 2021; 50: 677–686.
- 16 Weishaar KM, Thamm DH, Worley DR, et al. **Correlation of nodal mast cells with clinical outcome in dogs with mast cell tumour and a proposed classification system for the evaluation of node metastasis.** *J Comp Pathol* 2014; 151: 329–338.

- 17 Sabattini S and Bettini G. **Grading cutaneous mast cell tumors in cats.** *Vet Pathol* 2019; 56: 43–49.
- 18 Stetter J, Boge GS, Gronlund U, et al. **Risk factors for surgical site infection associated with clean surgical procedures in dogs.** *Res Vet Sci* 2021; 136: 616–621.
- 19 Center SA, Bunch SE, Baldwin BH, et al. **Comparison of sulfobromophthalein and indocyanine green clearances in the cat.** *Am J Vet Res* 1983; 44: 727–730.
- 20 Pirie CG and Alario A. **Use of indocyanine green and sodium fluorescein for anterior segment angiography in ophthalmologically normal cats.** *Am J Vet Res* 2015; 76: 897–903.
- 21 Hlusko KC, Cole R, Tillson DM, et al. **The effect of surgery on lymphoscintigraphy drainage patterns from the canine brachium in a simulated tumor model.** *Vet Surg* 2020; 49: 1118–1124.
- 22 Goyal A, Newcombe RG, Chhabra A, et al. **Factors affecting failed localisation and false-negative rates of sentinel node biopsy in breast cancer – results of the ALMANAC validation phase.** *Breast Cancer Res Treat* 2006; 99: 203–208.
- 23 Kedrzycki MS, Leiloglou M, Ashrafian H, et al. **Meta-analysis comparing fluorescence imaging with radioisotope and blue dye-guided sentinel node identification for breast cancer surgery.** *Ann Surg Oncol* 2021; 28: 3738–3748.
- 24 Jeremiasse B, van den Bosch CH, Wijnen M, et al. **Systematic review and meta-analysis concerning near-infrared imaging with fluorescent agents to identify the sentinel lymph node in oncology patients.** *Eur J Surg Oncol* 2020; 46: 2011–2022.
- 25 Wan J, Oblak ML, Ram A, et al. **Determining agreement between preoperative computed tomography lymphography and indocyanine green near infrared fluorescence intraoperative imaging for sentinel lymph node mapping in dogs with oral tumours.** *Vet Comp Oncol* 2021; 19: 295–303.
- 26 Andreoni AA, Guerrero TG, Hurter K, et al. **Revision of an unstable HELICA endoprosthesis with a Zurich cementless total hip replacement.** *Vet Comp Orthop Traumatol* 2010; 23: 177–181.
- 27 Patnaik AK, Ehler WJ and MacEwen EG. **Canine cutaneous mast cell tumor: morphologic grading and survival time in 83 dogs.** *Vet Pathol* 1984; 21: 469–474.
- 28 Kiupel M, Webster JD, Bailey KL, et al. **Proposal of a 2-tier histologic grading system for canine cutaneous mast cell tumors to more accurately predict biological behavior.** *Vet Pathol* 2011; 48: 147–155.
- 29 Worley DR. **Incorporation of sentinel lymph node mapping in dogs with mast cell tumours: 20 consecutive procedures.** *Vet Comp Oncol* 2014; 12: 215–226.
- 30 Marconato L, Polton G, Stefanello D, et al. **Therapeutic impact of regional lymphadenectomy in canine stage II cutaneous mast cell tumours.** *Vet Comp Oncol* 2018; 16: 580–589.