

## Cardiovascular Changes and Lumbar Spine Surgery: A Neglected Entity

### Abstract

Cardiovascular changes following lumbar spine surgeries in the prone position have been less commonly described. Here, we report a case of an elderly male patient undergoing lumbar spine decompression and transforaminal interbody fusion who developed multiple but transient episodes of hypotension and bradycardia. Anesthesiologist should be vigilant while monitoring such patients and should use invasive blood pressure monitoring if possible, so as to detect transient cardiovascular episodes which may progress and results in a dreadful outcome.

**Keywords:** Bradycardia, hypotension, lumbar spine

### Introduction

The interaction between the spine and the heart is complex. Despite the absence of coronary artery disease, lumbosacral spine surgery can result in cardiovascular changes under adequate levels of anesthesia intraoperatively. Significant cardiovascular changes are frequently reported in cervical and upper dorsal spine surgeries in traumatic and nontraumatic conditions.<sup>[1]</sup> However, such cardiovascular changes are infrequently reported following lumbosacral spine surgery.

### Case Report

A 72-year-old male, 70 kg and 167 cm height, who underwent L2–L5 decompression and transforaminal interbody fusion presented with chief complaints of pain in the lower back and bilateral lower limbs for the past 1 month. During preoperative anesthesia workup, it was found that patient was on irregular medications for hypertension. The preoperative blood investigations were within normal limits, and electrocardiography showed normal sinus rhythm. As a part of the protocol in our hospital, echocardiography was done and there was no regional wall motion abnormality seen and ejection fraction was 55%. Premedication was given to the patient, and antihypertensives were continued as per schedule. Standard general anesthesia was given. Routine

This is an open access journal, and articles are distributed under the terms of the Creative Commons Attribution-NonCommercial-ShareAlike 4.0 License, which allows others to remix, tweak, and build upon the work non-commercially, as long as appropriate credit is given and the new creations are licensed under the identical terms.

For reprints contact: reprints@medknow.com

monitors (electrocardiogram, noninvasive blood pressure, pulse oximetry, and capnography) were attached, and intravenous glycopyrrolate 0.2 mg was given. Induction of anesthesia was done using titrated doses of propofol, and muscle relaxation achieved using rocuronium 50 mg. Intravenous morphine 7 mg was used to provide analgesia. Intubation response was prevented using fentanyl 100 mcg. The maintenance of anesthesia was carried out using oxygen/air mixture and sevoflurane along with intermittent boluses of atracurium. Volume control mode of ventilation was used intraoperatively, and a target end-tidal carbon dioxide of 32–35 mmHg was kept. Vascular cannulation in the left radial artery was performed for continuous blood pressure monitoring. In addition to the routine monitors, temperature and urine output were monitored. In order to facilitate surgery, after induction of anesthesia patient was made to lie in the prone position. Postprone positioning, all pressure points including eye pressure were checked, the neck was kept in the neutral position, vitals were stable, and surgery was started. During the middle of surgery when transforaminal dilatation near the lumbar vertebra (L3) was being performed, there was a sudden onset of bradycardia (heart rate (HR) dropped to 38 beats per min) with a simultaneous fall in arterial blood pressure (72/34 mmHg), with no change in end-tidal carbon dioxide levels and oxygen saturation [Figure 1]. The surgeon was informed about the event, and the surgical

**How to cite this article:** Mahajan S, Swami AC, Kumar A. Cardiovascular changes and lumbar spine surgery: A neglected entity. Asian J Neurosurg 2019;14:1253-5.

**Shalvi Mahajan,  
Adarsh Chandra  
Swami<sup>1</sup>,  
Amit Kumar<sup>1</sup>**

*Department of Anesthesia and Intensive Care, Postgraduate Institute of Medical Education and Research, Chandigarh,*

*<sup>1</sup>Department of Anaesthesia and Intensive Care, Fortis Hospital, Mohali, Punjab, India*

#### Address for correspondence:

*Dr. Shalvi Mahajan,  
Department of Anaesthesia and Intensive Care, Postgraduate Institute of Medical Education and Research, Chandigarh, India.*

*E-mail: drshalvimahajan@gmail.com*

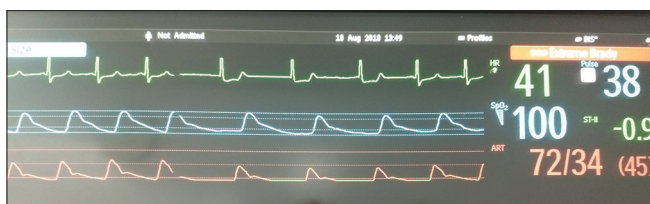
#### Access this article online

**Website:** www.asianjns.org

**DOI:** 10.4103/ajns.AJNS\_224\_19

#### Quick Response Code:





**Figure 1: Cardiovascular changes during lumbar spine surgery**

stimulus was released immediately. Within few minutes following the release of surgical stimulus, HR and arterial blood pressure came to baseline. There was a recurrence of similar episodes twice during the surgery which again responded to the removal of surgical stimulus. Towards the end of surgery, the patient's trachea was extubated in the supine position after reversal of neuromuscular blockade once the patient became fully awake, conscious, and was following commands. Furthermore, the patient's stay in the postoperative anesthesia care unit was uneventful and there was no neurological deficit. Consequently, the patient was shifted to the ward for further management.

## Discussion

During lumbar spine surgeries, cardiac changes have been infrequently noticed and reported. Ours is one of the rare reports, where we noticed episodes of bradycardia (HR went up to 38/min) along with hypotension (invasive blood pressure dropped up to 72/34 mmHg) during lumbar spine surgery. Once the surgical stimulus has been released by the surgeon, there was a gradual increase in HR and invasive blood pressure over a few minutes. This event occurred multiple times (three) during the surgery.

Hemodynamic alterations intraoperatively during lumbar spine surgery could be multifactorial- use of anesthetic agents, preoperative hypertensive patient on drug therapy (beta-blockers and angiotensin-converting enzyme inhibitors), venous air embolism, excessive blood loss, acid-base disturbances, hypothermia, administration of the wrong medication, anaphylactic reaction, prone positioning, and surgical stimulus. Anesthetic agents cause myocardial depression and vasodilation. Hypertensive patients have increased parasympathetic activity, resulting in contracted blood volume and exaggerated atrial stretch reflex response (Bezold-Jarisch reflex).<sup>[2]</sup> Hypothermia is a physiological myocardial depressant. The prone position is known to cause decreased left ventricular compliance (secondary to raised intrathoracic pressure) and decreased venous return (pooling of blood in the lower limbs). In our case, we have excluded the above-mentioned factors resulting in hemodynamic disturbances intraoperatively, as there were no drop in oxygen saturation, end-tidal carbon dioxide, and temperature along with normal acid-base balance, and blood loss was around 200 ml.

In our case, repeated episodes of bradycardia and hypotension coincide with the surgical stimulus, i.e.,

manipulation of dura mater during transforaminal dilation. The neuronal connection (lumbar spine-brainstem-heart loop) has some associations with negative hemodynamic changes. The exact mechanism how dura mater manipulation results in cardiovascular changes is not known although different mechanisms have been proposed. It was found in human anatomical studies that spinal dura mater consists of extrinsic and intrinsic innervation.<sup>[3]</sup> The extrinsic component of the nerve supply of ventral spinal dura mater is from primary ramifications of thick sino-vertebral nerves, thin branches of the posterior longitudinal ligament nerve plexus, and minute branches of the perivascular nerve plexus of the radicular ramus of the segmental arteries. During transforaminal lumbar interbody fusion, once the posterior bone elements are resected and decompression is complete, the dura mater and neural elements are mobilized. Hence, traction on the duramater causes activation of afferent parasympathetic nerve fibers and inhibition of sympathetic fibers. The activation of afferent parasympathetic nerve fibers cause vasovagal (reflex coeliac) reaction. Reflex coeliac reaction is similar to Buer-Lochkard reflex. BuerLockhard reflex is a neuro physiological reflex seen following stimulation of afferent parasympathetic nerve fibers seen during anal/perianal stimulation, resulting in bradycardia, hypotension, and even, cardiac arrest. Inhibition of sympathetic fibers results in hypotension.

The dura mater supplying nerves has been described as nociceptive due to their small size, naked nerve endings, and release of substance P. In our case, no tachycardia and hypertension were present since the depth of anesthesia and analgesia was adequate.

The cardiovascular changes in our case report were similar to the cardiovascular changes reported by various authors during lumbar spine surgery.<sup>[4-7]</sup> In a systemic review by Chowdhury and Schaller spinal-cardiac reflex, a new entity has been described for the negative chronotropic effects during lumbar spine surgery.<sup>[8]</sup> In almost all case scenarios, bradycardia was noted, but hypotension was less frequently reported. In our case cardiovascular changes reverted after withdrawal of the surgical stimulus over few minutes without any medication, while in the rest of the five cases, anticholinergic and sympathomimetic drugs were administered.

Hemodynamic changes during lumbar spine surgery, i.e., episodes of bradycardia and hypotension. sometime require treatment with fluids, anticholinergics, and vasopressors. If these cardiovascular changes are not detected well in time, they may progress to asystole which is difficult to treat in the prone position.<sup>[9]</sup> Hence, these events may be rarely reported and overlooked as transient changes, but they can have ominous outcomes.

## Conclusion

In conclusion, our case report highlights the fact that lumbar spine surgery in the prone position may have transient cardiovascular changes secondary to activation of unidentified neural pathways and physiological reflexes during dura mater manipulation. Whenever bradycardia and hypotension occur, the first step is to inform the operating surgeon so as to withhold the stimulus and simultaneously rule out rest of the causes. Thus, cardiovascular changes mandate careful watch of hemodynamics by an anesthesiologist along with the readily available emergency drugs. In future, more studies are required to further investigate these changes and develop insight into the neuronal pathways involved in the cardiac changes during lumbar spine surgery.

## Declaration of patient consent

The authors certify that they have obtained all appropriate patient consent forms. In the form the patient(s) has/have given his/her/their consent for his/her/their images and other clinical information to be reported in the journal. The patients understand that their names and initials will not be published and due efforts will be made to conceal their identity, but anonymity cannot be guaranteed.

## Financial support and sponsorship

Nil.

## Conflicts of interest

There are no conflicts of interest.

## References

1. Partida E, Mironets E, Hou S, Tom VJ. Cardiovascular dysfunction following spinal cord injury. *Neural Regen Res* 2016;11:189-94.
2. Kinsella SM, Tuckey JP. Perioperative bradycardia and asystole: Relationship to vasovagal syncope and the bezold-jarisch reflex. *Br J Anaesth* 2001;86:859-68.
3. Groen GJ, Baljet B, Drukker J. The innervation of the spinal dura mater: Anatomy and clinical implications. *Acta Neurochir (Wien)* 1988;92:39-46.
4. Deschamps A, Carvalho G. Lumbo-sacral spine surgery and severe bradycardia. *Can J Anaesth* 2004;51:277.
5. Mandal NG. More on lumbo-sacral spine surgery and bradycardia. *Can J Anaesth* 2004;51:942-3.
6. Chowdhury T, Sapra H, Dubey S. Severe hypotension in transforaminal lumbar interbody fusion surgery: Is it vasovagal or? *Asian J Neurosurg* 2017;12:149-50.
7. Chowdhury T, Narayanasamy S, Dube SK, Rath GP. Acute hemodynamic disturbances during lumbar spine surgery. *J Neurosurg Anesthesiol* 2012;24:80-1.
8. Chowdhury T, Schaller B. The negative chronotropic effect during lumbar spine surgery: A systemic review and aggregation of an emerging model of spinal cardiac reflex. *Medicine (Baltimore)* 2017;96:e5436.
9. Dooney N. Prone CPR for transient asystole during lumbosacral spinal surgery. *Anaesth Intensive Care* 2010;38:212-3.