





Comparison of the Self-Adjusting File and Hedström File Used as Supplementary Instruments for the Remaining Filling Material Removal During Retreatment of C-Shaped Canals: A Micro-CT Study

 Pablo Amoroso SILVA,  Murilo Priori ALCALDE,  Rodrigo Ricci VIVAN,
 Marco Antonio Hungaro DUARTE

ABSTRACT

Objective: The aim of this study was to evaluate the use of Self-adjusting file (SAF) system and Hedström (H) file for removing remaining filling material (RFM) from C-shaped canals.

Methods: 20 C-shaped mandibular second molars with C1 configurations were instrumented, filled with tagger's hybrid technique. Samples were divided into 2 groups (n=10). Reciproc R25 and a Mtwo 35/04 file were used for retreatment in both groups. Then, a 2.0 SAF file (group I) and a #35 H file (group II) were used as supplementary steps for RFM removal. Micro-CT scanning was performed after every procedure. Total volumes were calculated and converted into percentages. Also, the minimum wall thickness at 3, 5, 7 mm from apex was calculated. The Prism 7.0 software was used as the analytical tool with a significance of 5%.

Results: Initial obturation removal was approximately 64% in group I and 67% in Group II. The apical third had the highest values of RFM. The use of a H file significantly reduced the RFM compared to SAF in the total canal length respectively (30% vs 18%) and at 1-3 mm and 3-6 mm when compared to the use of SAF. A statistically significant decrease of RFM and minimum wall thickness were observed in both groups (P<0.05).

Conclusion: None of the retreatment techniques completely removed RFM. The apical region was the more unaffected area. Also, the SAF file was less effective than the H file in removing the RFM. Although C-shaped canals possesses thinner dentinal wall thickness, no excessive dentine removal was observed after each instrument use.

Keywords: C-shaped canals, Hedström file, micro-CT, root canal retreatment, reciproc, self-adjusting file

Please cite this article as: Silva PA, Alcalde MP, Vivan RR, Duarte MAH. Comparison of the Self-Adjusting File and Hedström File Used as Supplementary Instruments for the Remaining Filling Material Removal During Retreatment of C-Shaped Canals: A Micro-Ct Study. Eur Endod J 2020; 2: 112-7

From the Department of Restorative Dentistry (P.A.S. ✉ pabloamoroso@usp.br) Londrina State University, Londrina, Paraná, Brazil; Department of Endodontics (M.A.H.D., M.P.A., R.R.V.) Faculdade de Odontologia de Bauru, São Paulo University, Bauru, São Paulo, Brazil

Received 15 July 2019,
Accepted 23 March 2020

Published online: 11 June 2020
DOI 10.14744/eej.2019-07-067

This work is licensed under a Creative Commons Attribution-NonCommercial 4.0 International License.



HIGHLIGHTS

- This Micro-CT study evaluated the remaining wall thickness and filling material removal of C-shaped canals using SAF and H file.
- 30% and 18% of the RFM still was left inside when using SAF and H file respectively.
- The mean wall thickness after all procedures ranged between 0.8 and 1.01 mm for the SAF group and 0.7 to 0.9 mm with H-file.

achieve initial bacterial decontamination allowing further intracanal dressing insertion. After the infection has been controlled new obturation material can be inserted inside the root canals (5).

During retreatment procedures, numerous techniques are used to remove the filling material from root canals. However, previous studies (6-11) showed that due to the circumferential design of retreatment instruments (12), and variability of root canal anatomy, remaining filling material (RFM) could still be left inside the root canal. Thus, in a complex canal anatomy, the retreatment procedure will be challenging. Therefore, to improve the removal of the RFM several authors recommend the use of supplementary steps such as Hedström (H) files (13), motor-driven instrumentation systems (14), the use of solvents and passive ultrasonic activation (15, 16), the Xp-Endo

INTRODUCTION

Failure of endodontic treatment can be attributed to several factors such as uninstrumented canals or its irregularities, lack of adequate obturation, insufficient coronal seal, persistent infection, among others (1-4). When root canal retreatment is indicated clinicians should remove the obturation material so re-instrumentation and chemical irrigation of the root canals can

finisher R file (12) sonic and photon-induced photoacoustic streaming activation of NaOCl (17) and the Self Adjusting file (SAF) (6, 18). This last system has been used in several retreatment studies in curved mesial roots of mandibular molars (12, 19, 20) and oval shaped canals (6, 13) showing good results as a supplementary file to remove RFM.

Currently, there is a lack of studies regarding retreatment of the C-shaped root canal anatomy. This anatomy is usually more prevalent in second mandibular molars with fused roots containing several internal variations in its cross-sections, high canal volumes, large apical diameters and small amount of dentine thickness towards the radicular groove (21, 22). These complexities make the proper cleaning, shaping and obturation often complicated, especially in the apical third (22-26). For this reason, it is important to evaluate techniques for removing the filling material during retreatment of C-shaped canals, without removing excessive amount of dentine next to the groove region.

Based on the above considerations, the aim of this study was to:

1. Evaluate with micro-CT technology the remaining filling material removal after supplementary steps using the SAF system and using a manual H file in mandibular second molars with C-shaped canals.
2. Analyze the remaining wall thickness towards the radicular groove after removal of the filling material and after the supplementary steps.

The null hypothesis to be tested is that there is no difference in the removal of filling material and dentine thickness during retreatment of C-shaped root canals between the SAF and H File used as a supplementary approach.

MATERIALS AND METHODS

Sample preparation

From a previous micro-CT pre-scan of one hundred mandibular second molars with fused roots, twenty mandibular second molars with C-shaped merging type canals and C1 cross-sectional configuration: An uninterrupted C-shaped canal with no separation or division (27, 28) were selected. The Institutional Ethics Committee approved this research (#703.054).

Root canal instrumentation, obturation and initial micro-CT scan

Access cavities were performed, and the working length (WL) was established 1 mm shorter than the tooth length to the major apical foramen using a 10K file (Dentsply Maillefer, Ballaigues, Switzerland). Then, a single operator performed the root canal instrumentation using the Reciproc system, until a R25 (25/0.08) instrument (VDW, Munich, Germany). The C-shaped root canal anatomy was considered as two main canals (distal and mesial) so, the R25 reciprocating instrument was introduced in both canals using an in-and-out pecking motion with an amplitude of approximately 3 mm with gentle apical pressure until it reached the WL. After three pecking motions, the instrument was removed from the canal and cleaned with

sterile gauze. The canals were irrigated with 2 mL of 1% NaOCl after instrumentation of each third. After completion of root canal preparation, three applications (20 seconds each) of passive ultrasonic irrigation (PUI) using the Irrisonic tip (Helse Ultrasonics, Ribeirão Preto, SP, Brazil) with 1% NaOCl and with 17% EDTA were implemented. The canals were finally irrigated with 5 mL of saline solution and dried with paper points (VDW, Munich, Germany).

Afterwards, all specimens were obturated using the Tagger's Hybrid technique with a #60 gutta-percha stainless compactor (Gutta condenser; Dentsply Maillefer) using two R25 single gutta-percha cones (mesial and distal canals) (VDW, Munich, Germany) and 6 auxiliary gutta-percha points. Sealer 26 (Dentsply Maillefer, Ballaigues, Switzerland) was used as a sealer. Finally, the crowns were sealed with Coltosol (Coltène AG, Alstätten, Switzerland) temporary restorative material and stored at 37°C and 100% humidity for 1 month.

After that, all teeth were mounted on a custom-made acrylic attachment and scanned in a micro-CT system (SkyScan 1174; Bruker-microCT, Kontich, Belgium), with the following parameters: 50-kv x-ray source at 800- μ A, 0.8° rotation step, 360° of rotation and an voxel size of 14.1- μ m. Then, images were reconstructed with the NRecon software (NRecon v.1.6.3, Bruker-microCT).

Calculation of the filling material volume and sample division

The CTAn v1.5.4.0 software (Bruker-microCT) was used to calculate the filling material volume (mm^3) of the root canal from the binarized area inside the region of interest. The binary value set on the histogram for each specimen was selected and used in all further micro-CT analyses. Additionally, three segments of the root canal: apical (1-3), middle (3-6) and cervical (6-9) mm were measured separately.

Once the volumes were obtained, the specimens were divided into two groups of 10 teeth each, considering similar lengths and internal filled canal volumes. An unpaired t test using the Prism 7.0 software (GraphPad Software Inc., La Jolla, USA) was performed to confirm similar distribution regarding the initial obturation volumes. In this part of the study, the statistical analysis confirmed an even distribution of the group samples with no differences on the median canal volumes between group I (19.13 ± 4.72) and group II (21.97 ± 5.79) mm^3 ($P > 0.05$).

Initial removal of the filling material, re-instrumentation of root canals

For the filling material removal, the C-shaped root canal anatomy was considered as two main canals (distal and mesial). The material removal started with the Reciproc system R25 (25/0.08) (VDW, Munich, Germany) using a VDW Silver motor (VDW) in the reciproc mode. An in-and-out pecking motion in three stages for both canals, (cervical, middle, and apical third) until reaching the WL carefully cleaning the file after each removal with sterile gauze. Also, a gentle brushing movement without forcing the instrument was performed towards the canal walls and isthmus region of the C-shaped canals trying to remove root filling material from that

region. Irrigation with 2 mL of 1% NaOCl after instrumentation of each third was implemented. The removal procedure was considered complete when no further filling material was adhering to the instrument. Final apical enlargement was performed with the Mtwo (VDW) rotary system until a 35.04 file. Irrigation with 5 mL of 1% NaOCl and saline solution was carried out and the canals were dried with paper points (VDW, Munich, Germany).

Second Micro-CT scan.

Subsequently, all specimens were submitted to another Micro-CT scanning using the same parameters from the beginning. After images reconstruction with the NRecon software, calculation of the filling material was made with the CTAn v1.5.4.0 software (Bruker-microCT) as explained previously.

Supplementary step for the remaining filling material removal with the SAF system and H File, and final Micro-CT scan.

SAF system

In group I, a 2.0 mm in diameter SAF (ReDent Nova, Raanana, Israel) was operated in the canal using an RDT3 hand piece head (ReDent Nova) attached to the Endomate rotatory motor (NSK, Tokyo, Japan) at 5000 rpm which produced 5000 vibrations per minute with an amplitude of 0.4 mm. The SAF was connected to a Vatea system irrigator (ReDent Nova) and activated for 3 min with 1% sodium hypochlorite as an irrigant solution at a flow rate of 5 mL/min. One SAF instrument per canal was used in this process. The file was directed towards the isthmus direction trying to contour the C-shaped root canal anatomy.

Hedström (H) file

A #35 H file (Dentsply Maillefer, Ballaigues, Switzerland) per canal was used to remove the RFM of the canal using a in and out and push-pull filing motion at full WL towards the C-shaped canal walls until no filling material came out. The same amount of irrigation solution was used as in the first group.

Final irrigation in both groups with 5 mL of 1% NaOCl and saline solution was carried out and the canals were dried with paper points. Then the specimens were submitted to a last micro-CT scanning using the same parameters of the previous ones. Also, during reconstruction of these images, the same reconstruction parameters settings and the same binary

threshold values were applied. The volume of RFM was calculated as previously explained.

Volumes of the initial filling material removal with Reciproc/Mtwo in both groups and the removed RFM with the SAF and H file were recorded and converted into percentages relative to the pre-treatment volume of the filling material.

Minimum wall thickness analysis

Using the DataViewer v1.5.4 software (Bruker-microCT, Kontich, Belgium), the cross-sectional micro-CT images sections at 3, 5 and 7 mm from the root apex were recorded and co-registered, with a total 120 images per group (approximately 40 slices per third). Then, the Ctan software v1.5.4.0 (Bruker-microCT, Kontich, Belgium) was used to measure the length of the minimum wall thickness towards the C-shaped groove (danger zones) at all cross-sections. The final cross-sectional image was considered as the initial image to be measured, which allowed locating where the minimum wall thickness was situated, and then, the rest of the cross-sectional images were measured at the exact same point of the initial image. Three blind operators performed all the slice measurements and the mean values per third were calculated.

Statistical analysis

All collected data from the micro-CT analysis was submitted to a Shapiro Wilk test, which confirmed a normal distribution of the samples. For the intragroup comparison of the RFM, a paired t test was performed, while in the intergroup comparison an unpaired t test was used. The minimum wall thickness data were analyzed using repeated-measures one-way ANOVA. Additionally, comparison between groups was performed using the unpaired t test. The Prism 7.0 software (GraphPad Software Inc., La Jolla, USA) was used as the analytical tool and the significance level was set at 5%.

RESULTS

Remaining filling material

Table 1 shows the mean percentage and standard deviation of the filling material removal at the total canal length and also at the evaluated thirds. In the intragroup comparison, a statistically significant decrease of the RFM was observed at the total canal length, in both groups, after the use of supplementary steps ($P < 0.05$). The initial filling material volume for group one was 19.13 mm³ which decreased to 7.15 mm³ after Reciproc/

TABLE 1. Mean percentages and standard deviation (SD) of the remaining filling material of both groups at the total canal length and at the apical, middle and coronal thirds

	Group I		Group II	
	After reciproc/Mtwo	After SAF	After reciproc/Mtwo	After H file
Remaining filling material volume (%)				
Total canal length	36.01±15.87 ^{aA}	30.06±13.35 ^{bA}	33.26±14.74 ^{aA}	18.68±11.79 ^{bB}
1-3 mm	62.31±18.10 ^{aA}	55.26±19.99 ^{bA}	65.38±16.89 ^{aA}	34.86±23.27 ^{bB}
3-6 mm	47.61±17.79 ^{aA}	43.88±17.35 ^{bA}	43.36±19.27 ^{aA}	25.96±14.84 ^{bB}
6-9 mm	21.61±17.05 ^{aA}	15.27±12.56 ^{bA}	17.54±12.07 ^{aA}	7.46±7.06 ^{bA}

Different lowercase letters between columns represent significant differences in the intragroup comparison: After Reciproc/Mtwo vs After SAF (group I) and After Reciproc/Mtwo vs After H file (group II), while different uppercase letters were used for the intergroup comparisons; (After Reciproc/Mtwo (group I) vs After Reciproc/Mtwo (Group II) and After SAF (group I) vs After H file (group II)).

TABLE 2. Mean percentages and standard deviation (SD) of the minimum wall thickness measurements at 3, 5 and 7 mm from the root apex

	Group I			Group II		
	Initial (mm)	Reciproc/Mtwo (mm)	SAF (mm)	Initial (mm)	Reciproc/Mtwo (mm)	H file (mm)
3 mm	0.97±0.38 ^{aA}	0.89±0.35 ^{bA}	0.81±0.33 ^{cA}	0.93±0.39 ^{aA}	0.83±0.34 ^{bA}	0.74±0.30 ^{cA}
5 mm	1.05±0.45 ^{aA}	0.96±0.47 ^{bA}	0.89±0.44 ^{cA}	0.96±0.37 ^{aA}	0.85±0.37 ^{bA}	0.78±0.37 ^{cA}
7 mm	1.25±0.57 ^{aA}	1.11±0.55 ^{bA}	1.01±0.50 ^{cA}	1.23±0.45 ^{aA}	1.07±0.46 ^{bA}	0.89±0.42 ^{cA}

Different lowercase letters represent significant differences in the intragroup comparison: Initial vs Reciproc/Mtwo vs SAF (Group I) and Initial vs Reciproc/Mtwo vs H file, while different uppercase letters were used for the intergroup comparisons: Initial between group I and II, Reciproc/Mtwo between group I and II and SAF vs H file comparisons (P<0.05).

Mtwo and to 6.05 mm³ after SAF use. In group II, the total obturated canal volume was 21.97 mm³ which decreased to 7.13 mm³ after Reciproc/Mtwo use, and to 3.68 mm³ with the use of the H File.

The apical third had the highest values of RFM in both groups after both removal stages (Fig. 1). For the intergroups comparison, no differences between groups were found after initial filling material removal with Reciproc/Mtwo. However, the use of a H file significantly reduced the RFM in the total canal length and also, at 1-3 mm and 3-6 mm when compared to the use of SAF (P<0.05).

Minimum wall thickness analysis

In both groups, a progressive and significant decrease of the wall thickness was observed at all the evaluated cross-sections (P<0.05) (Table 2 and Fig. 2). The initial remaining wall thickness at 3, 5 and 7 mm was 0.97, 1.05 and 1.25 mm, while in group two was 0.93, 0.96 and 1.23 mm, respectively. In the initial obturation removal step, an approximately 0.10 mm of dentine was removed with the Reciproc/Mtwo files in both groups and all cross-sections. Subsequent SAF use removed an additional 0.80, 0.77, 0.98 mm while the H file removed 0.63, 0.49 and 1.30 mm of root dentine at 3, 5 and 7 mm from the apex respectively. However, when an unpaired t test was

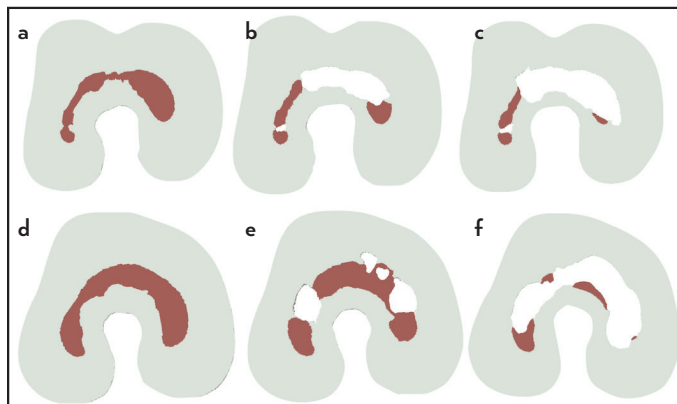


Figure 2. Representative micro-CT 2D images of the remaining wall thickness at 7 mm from the apex. Group I: (a) Initial, (b) After R25/Mtwo, (c) After SAF 2.0 mm. And Group II: (d) Initial, (e) After R25/Mtwo, (f) After #35 H file. Notice the progressive removal of dentine towards the C-shaped groove after each supplementary step

performed in the intergroup comparison, no statistical differences were found at all evaluated sections (P>0.05).

DISCUSSION

Unsuccessful root canal treatment can provide an optimal environment for micro-organisms inside the root canal causing post-treatment apical periodontitis (4). If the root canal anatomy is simpler with few anatomical complexities, around 91% removal of the obturation material is achieved (13). On the contrary, in complex root canal anatomies, some authors reported more difficulty to remove the obturation material (15, 29). Hence, leaving canal areas with considerable amounts of non-removed RMF might restrict the irrigant solutions and intracanal dressings of contacting bacteria compromising the root canal retreatment (2).

To remove the initial filling material, the Reciproc system was used. Approximately 65% of the obturation mass from the C-shaped canals in both groups was removed. The cutting efficiency of this instrumentation system has been reported to be superior to other retreatment techniques (9, 11). However, in C-shaped canals our results evidently reflected the difficulty to achieve a fully removal of the RFM especially in the apical third followed by the middle third (Fig. 3). For this reason, supplementary instrumentation steps were used. In previous studies (6, 18), a better performance of the SAF as a supplementary retreatment step in oval shaped canals was reported. However, in

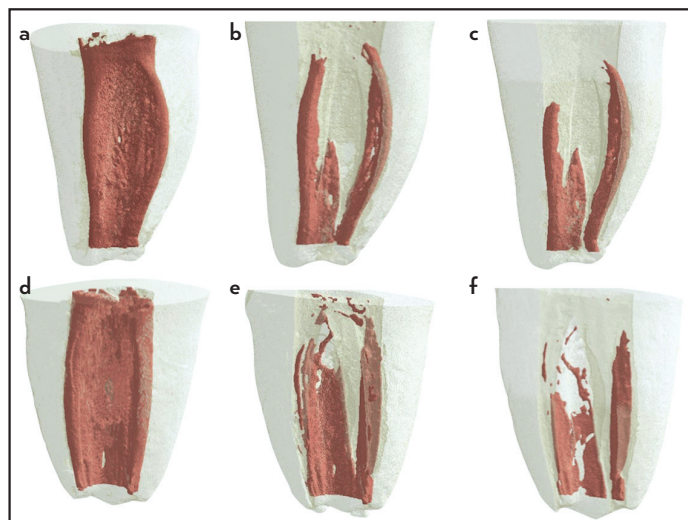


Figure 1. Representative micro-CT 3D images of all retreatment procedures at the total canal length, Group I: (a) Initial, (b) after R25/Mtwo, (c) after SAF 2.0 mm, and Group II: (d) Initial, (e) After R25/Mtwo, (f) after #35 H file in the attempts to remove the RFM

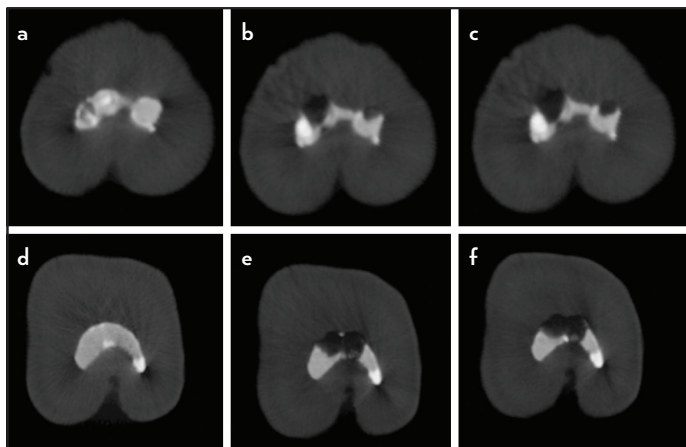


Figure 3. Representative micro-CT 2D images of at 1 mm from the apex (WL). Group I: (a) Initial, (b) After R25/Mtwo, (c) After SAF 2.0 mm and Group II: (d) Initial, (e) After R25/Mtwo, (f) After #35 H file in the attempts to remove the RFM

our study, the SAF system only removed an extra 6% of the RFM from the C-shaped canals, leaving about 29% of RFM. Thus, the first null hypothesis could be accepted. A possible reason to explain the SAF performance in our study could be found in a report of Siqueira et al. (30) which suggested that the contraction capacity of the SAF file may challenge the SAF file from entering the isthmus area and cut dentine or filling material with its abrasive surface. Furthermore, Abramovitz et al. (19), suggested that the high flexibility of the SAF file might interfere with its scrubbing effect, and it may not be sufficient to remove such quantities of RFM attached to the different dentinal walls.

The second supplementary instrument used in this study was the H file which removed 14% of the RFM from the total canal. A previous study reported that the H file had a better performance in removing RFM as a supplementary file (13). This manual file has a rigid metal core that can be directed and forced into the dentinal walls in circumferential movements removing the RFM out of the canal more easily. Even though a better performance with H file in comparison to the SAF was found in our study, high percentages of RFM still remained inside the canals in both the groups (30% SAF and 18% H file) and thus, it should not be considered as an effective removal.

As mentioned before, the apical portion of the C-shaped canal systems are connected by ribbon-like isthmi in which instruments could hardly be inserted making it complicated to shape and obturate (23-25, 31). Thus, in C-shaped retreatment procedures, these complications might also be expected when removing the RFM as revealed by our results. After supplementary instrumentation with SAF and H files, the RFM of the apical third reduced to 55% and 34% respectively. As to our knowledge, this is the first study of retreatment of C-shaped canals using Micro-CT technology and no other studies were found to compare similar results. However, other studies using different anatomical variations also reported high percentages of RFM at the apical third (15, 32).

A previous study reported that the usage of large tapers and tips may promote greater filling material removal but also larger apical transportation (32). Gao et al. (27) recommended not to

use large tapers in C-shaped canals due to the excessive dentine removal towards the C-shaped groove which could weaken the tooth structure. In our study, the initial minimum wall thickness was around 1 mm in average at 3 and 5 mm, and 1.2 mm at 7 mm from the apex in both groups similar to a previous study (22). After each retreatment step, a significantly thickness decrease was observed towards the radicular groove (Table 2). The cervical third had the lower quantity of RFM after instrumentation steps but had the highest amounts of dentinal removal. The H file was more aggressive in removing RFM than the SAF, however, it was at expenses of removing more root dentine (Fig. 2) rejecting our second null hypothesis. Although our results showed that it still remained an average of 0.74 mm of dentine thickness at the apical and middle thirds, special care must be taken to avoid canal transportation or excessive dentine removal that could induce root fracture while attempting to eliminate the RFM from C-shaped canals (33). Perhaps, the use of solvents during the supplementary steps would help the instruments to remove the RFM more easily (34). However, this factor was not part of the aim of this study.

A previous study recommended thermoplasticized gutta-percha techniques to fill the irregularities of these anatomies (24). In our study the tagger's hybrid technique was used to fill the C-shaped canals with the intention to push sealer and softened gutta-percha into the isthmuses areas and try to standardize the obturated canal volumes. In a recent in vitro study using 3D printed replicas (31), the cold lateral compaction technique showed less voids percentage in the apical region when compared to thermoplasticized gutta-percha techniques. In our study, the lateral compaction was used before using the guttacondensor to thermoplasticize the gutta-percha, thus, this probably influenced in the good quality of obturation revealed by the Micro-CT analysis. Perhaps in a clinical situation where a C-shaped canal needs retreatment, the canal obturation quality could be inferior and the removal of the filling material would be easier.

Micro-CT has the advantage to be a non-destructive research method that permitted to evaluate quantitative and qualitative 3D data of root filling material removal (11, 35). Another advantage was that the specimen could be analyzed at different stages of the treatment procedure serving as its own control (25). A limitation of the study could be the small sample size so the results should be interpreted with caution. However, a rigorous sample selection was made to minimize variables that would interfere with our results. Selecting C1 merging type canals only, almost equal root lengths, and selecting similar obturated canal volumes in both groups were performed to reduce the risk of bias.

CONCLUSION

Within the limitations of this in vitro study it can be concluded that:

1. The C-shaped root canal system presents an anatomical challenge where none of the retreatment techniques completely removed the remaining filling material.
2. The apical region presented the highest values of RFM after all the performed procedures.

3. Although C-shaped canals possess thinner dentinal wall thickness, no excessive dentine removal was observed after each instrument use.
4. The H file was more aggressive in removing root dentine while attempting to remove the RFM than the SAF, especially at 7 mm from the apex.

Disclosures

Conflict of interest: The authors deny any conflicts of interest related to this study.

Ethics Committee Approval: The Institutional Ethics Committee from the University of São Paulo approved this research (CEP #703.054).

Peer-review: Externally peer-reviewed.

Financial Disclosure: This work was supported by the Fundação de Amparo à Pesquisa do Estado de São Paulo (FAPESP) grant (2014/03009-1).

Authorship contributions: Concept – P.A.S.; Design – R.R.V.; Supervision – M.A.H.D.; Funding - P.A.S.; Materials - M.P.A.; Data collection &/or processing – M.A.H.D., P.A.S.; Analysis and/or interpretation – P.A.S., M.P.A.; Literature search – M.P.A.; Writing – P.A.S., M.P.A.; Critical Review – R.R.V., M.A.H.D.

REFERENCES

1. Siqueira JF Jr, Rôças IN. Clinical implications and microbiology of bacterial persistence after treatment procedures. *J Endod* 2008; 34(11):1291–301.
2. Siqueira JF Jr, Rôças IN, Ricucci D, Hülsmann M. Causes and management of post-treatment apical periodontitis. *Br Dent J* 2014; 216(6):305–12.
3. Ricucci D, Siqueira JF Jr, Bate AL, Pitt Ford TR. Histologic investigation of root canal-treated teeth with apical periodontitis: a retrospective study from twenty-four patients. *J Endod* 2009; 35(4):493–502.
4. Ricucci D, Siqueira JF Jr. Biofilms and apical periodontitis: study of prevalence and association with clinical and histopathologic findings. *J Endod* 2010; 36(8):1277–88.
5. Stabholz A, Friedman S. Endodontic retreatment--case selection and technique. Part 2: Treatment planning for retreatment. *J Endod* 1988; 14(12):607–14.
6. Keleş A, Alcin H, Kamalak A, Versiani MA. Oval-shaped canal retreatment with self-adjusting file: a micro-computed tomography study. *Clin Oral Investig* 2014; 18(4):1147–53.
7. Fruchi Lde C, Ordinola-Zapata R, Cavenago BC, Hungaro Duarte MA, Bueno CE, De Martin AS. Efficacy of reciprocating instruments for removing filling material in curved canals obturated with a single-cone technique: a micro-computed tomographic analysis. *J Endod* 2014; 40(7):1000–4.
8. Rodrigues CT, Duarte MA, de Almeida MM, de Andrade FB, Bernardineli N. Efficacy of CM-Wire, M-Wire, and Nickel-Titanium Instruments for Removing Filling Material from Curved Root Canals: A Micro-Computed Tomography Study. *J Endod* 2016; 42(11):1651–5.
9. de Siqueira Zuolo A, Zuolo ML, da Silveira Bueno CE, Chu R, Cunha RS. Evaluation of the Efficacy of TRUShape and Reciproc File Systems in the Removal of Root Filling Material: An Ex Vivo Micro-Computed Tomographic Study. *J Endod* 2016; 42(2):315–9.
10. Rödiger T, Reicherts P, Konietschke F, Dullin C, Hahn W, Hülsmann M. Efficacy of reciprocating and rotary NiTi instruments for retreatment of curved root canals assessed by micro-CT. *Int Endod J* 2014; 47(10):942–8.
11. Crozeta BM, Silva-Sousa YT, Leoni GB, Mazzi-Chaves JF, Fantinato T, Baratto-Filho F, et al. Micro-Computed Tomography Study of Filling Material Removal from Oval-shaped Canals by Using Rotary, Reciprocating, and Adaptive Motion Systems. *J Endod* 2016; 42(5):793–7.
12. Machado AG, Guilherme BPS, Provenzano JC, Marceliano-Alves MF, Gonçalves LS, Siqueira JF Jr, et al. Effects of preparation with the Self-Adjusting File, TRUShape and XP-endo Shaper systems, and a supplementary step with XP-endo Finisher R on filling material removal during retreatment of mandibular molar canals. *Int Endod J* 2019; 52(5):709–15.
13. Yürüker S, Görduysus M, Küçükçaya S, Uzunoğlu E, Ilgın C, Gülen O, et al. Efficacy of Combined Use of Different Nickel-Titanium Files on Removing Root Canal Filling Materials. *J Endod* 2016; 42(3):487–92.
14. Da Rosa RA, Santini MF, Cavenago BC, Pereira JR, Duarte MA, Só MV. Micro-CT Evaluation of Root Filling Removal after Three Stages of Retreat-ment Procedure. *Braz Dent J* 2015; 26(6):612–8.
15. Cavenago BC, Ordinola-Zapata R, Duarte MA, del Carpio-Perochena AE, Villas-Bôas MH, Marciano MA, et al. Efficacy of xylene and passive ultrasonic irrigation on remaining root filling material during retreatment of anatomically complex teeth. *Int Endod J* 2014; 47(11):1078–83.
16. Bernardes RA, Duarte MAH, Vivan RR, Alcalde MP, Vasconcelos BC, Bramante CM. Comparison of three retreatment techniques with ultrasonic activation in flattened canals using micro-computed tomography and scanning electron microscopy. *Int Endod J* 2016; 49(9):890–7.
17. Jiang S, Zou T, Li D, Chang JW, Huang X, Zhang C. Effectiveness of Sonic, Ultrasonic, and Photon-Induced Photoacoustic Streaming Activation of NaOCl on Filling Material Removal Following Retreatment in Oval Canal Anatomy. *Photomed Laser Surg* 2016; 34(1):3–10.
18. Solomonov M, Paqué F, Kaya S, Adigüzel O, Kfir A, Yiğit-Özer S. Self-adjusting files in retreatment: a high-resolution micro-computed tomography study. *J Endod* 2012; 38(9):1283–7.
19. Abramovitz I, Relles-Bonar S, Baransi B, Kfir A. The effectiveness of a self-adjusting file to remove residual gutta-percha after retreatment with rotary files. *Int Endod J* 2012; 45(4):386–92.
20. Voet KC, Wu MK, Wesselink PR, Shemesh H. Removal of gutta-percha from root canals using the self-adjusting file. *J Endod* 2012; 38(7):1004–6.
21. Amoroso-Silva PA, Ordinola-Zapata R, Duarte MA, Gutmann JL, del Carpio-Perochena A, Bramante CM, et al. Micro-computed Tomographic Analysis of Mandibular Second Molars with C-shaped Root Canals. *J Endod* 2015; 41(6):890–5.
22. Cheung LH, Cheung GS. Evaluation of a rotary instrumentation method for C-shaped canals with micro-computed tomography. *J Endod* 2008; 34(10):1233–8.
23. Yin X, Cheung GS, Zhang C, Masuda YM, Kimura Y, Matsumoto K. Micro-computed tomographic comparison of nickel-titanium rotary versus traditional instruments in C-shaped root canal system. *J Endod* 2010; 36(4):708–12.
24. Ordinola-Zapata R, Bramante CM, de Moraes IG, Bernardineli N, Garcia RB, Gutmann JL. Analysis of the gutta-percha filled area in C-shaped mandibular molars obturated with a modified MicroSeal technique. *Int Endod J* 2009; 42(3):186–97.
25. Amoroso-Silva P, Alcalde MP, Hungaro Duarte MA, De-Deus G, Ordinola-Zapata R, Freire LG, et al. Effect of finishing instrumentation using NiTi hand files on volume, surface area and uninstrumented surfaces in C-shaped root canal systems. *Int Endod J* 2017; 50(6):604–11.
26. Soo WK, Thong YL, Gutmann JL. A comparison of four gutta-percha filling techniques in simulated C-shaped canals. *Int Endod J* 2015; 48(8):736–46.
27. Gao Y, Fan B, Cheung GS, Gutmann JL, Fan M. C-shaped canal system in mandibular second molars part IV: 3-D morphological analysis and transverse measurement. *J Endod* 2006; 32(11):1062–5.
28. Fan B, Cheung GS, Fan M, Gutmann JL, Bian Z. C-shaped canal system in mandibular second molars: Part I--Anatomical features. *J Endod* 2004; 30(12):899–903.
29. Barreto MS, Rosa RA, Santini MF, Cavenago BC, Duarte MA, Bier CA, et al. Efficacy of ultrasonic activation of NaOCl and orange oil in removing filling material from mesial canals of mandibular molars with and without isthmus. *J Appl Oral Sci* 2016; 24(1):37–44.
30. Siqueira JF Jr, Alves FR, Versiani MA, Rôças IN, Almeida BM, Neves MA, et al. Correlative bacteriologic and micro-computed tomographic analysis of mandibular molar mesial canals prepared by self-adjusting file, reciproc, and twisted file systems. *J Endod* 2013; 39(8):1044–50.
31. Gok T, Capar ID, Akcay I, Keles A. Evaluation of Different Techniques for Filling Simulated C-shaped Canals of 3-dimensional Printed Resin Teeth. *J Endod* 2017; 43(9):1559–64.
32. Delai D, Jardine AP, Mestieri LB, Boijink D, Fontanella VRC, Grecca FS, et al. Efficacy of a thermally treated single file compared with rotary systems in endodontic retreatment of curved canals: a micro-CT study. *Clin Oral Investig* 2019; 23(4):1837–44.
33. Wilcox LR, Roskelley C, Sutton T. The relationship of root canal enlargement to finger-spreader induced vertical root fracture. *J Endod* 1997; 23(8):533–4.
34. Sağlam BC, Koçak MM, Türker SA, Koçak S. Efficacy of different solvents in removing gutta-percha from curved root canals: a micro-computed tomography study. *Aust Endod J* 2014; 40(2):76–80.
35. Alves FR, Marceliano-Alves MF, Sousa JC, Silveira SB, Provenzano JC, Siqueira JF Jr. Removal of Root Canal Fillings in Curved Canals Using Either Reciprocating Single- or Rotary Multi-instrument Systems and a Supplementary Step with the XP-Endo Finisher. *J Endod* 2016; 42(7):1114–9.