









## ORIGINAL ARTICLE

# Sporadic Creutzfeldt–Jakob disease with extremely long 14-year survival period

Izaro Kortazar-Zubizarreta<sup>1</sup>  | Rebeca Ruiz-Onandi<sup>2</sup>  | Arrate Pereda<sup>3</sup>  |  
Yerai Vado<sup>3</sup>  | Gonzalo González-Chinchon<sup>1</sup>  | Hasier Eraña<sup>4,5</sup>  |  
Guiomar Perez de Nanclares<sup>3</sup>  | Joaquín Castilla<sup>4,6</sup> 

<sup>1</sup>Department of Neurology, Bioaraba Health Research Institute, Araba University Hospital-Txagorritxu, Vitoria-Gasteiz, Spain

<sup>2</sup>Department of Pathology, Bioaraba Health Research Institute, Araba University Hospital-Txagorritxu, Vitoria-Gasteiz, Spain

<sup>3</sup>Molecular (Epi)Genetics Laboratory, Bioaraba Health Research Institute, Araba University Hospital, Vitoria-Gasteiz, Spain

<sup>4</sup>Centre for Cooperative Research in Biosciences (CIC bioGUNE), Basque Research and Technology Alliance (BRTA), Derio, Spain

<sup>5</sup>Atlas Molecular Pharma, Bizkaia Technology Park, Derio, Spain

<sup>6</sup>Ikerbasque, Basque Foundation for Science, Bilbao, Spain

## Correspondence

Izaro Kortazar-Zubizarreta, Department of Neurology, Bioaraba Health Research Institute, Araba University Hospital-Txagorritxu, Vitoria-Gasteiz, Spain.  
Email: izaro.kortazarzubizarreta@osakidetza.eus

Joaquín Castilla, Centre for Cooperative Research in Biosciences (CIC bioGUNE), Basque Research and Technology Alliance (BRTA), Derio, Spain.  
Email: castilla@joaquincastilla.com

## Funding information

This work was supported financially by the Department of Health of the Basque Government (GV202018/111002), a Spanish grant awarded to J.C. (RTI2018-098515-B-I00) by MINECO/FEDER, as well as an Interreg (POCTEFA EFA148/16) grant awarded to J.C. by FEDER. Therefore, this project was cofunded by the European Regional Development Fund.

## Abstract

**Background and purpose:** Sporadic Creutzfeldt–Jakob disease is a rapidly progressing and highly variable neurodegenerative disease with heterogeneous clinical presentation and a median survival time from diagnosis to death of 4–6 months.

**Methods:** We report a rare case of a 61-year-old woman with a history of initially rapidly progressive dementia, with subsequent development of pyramidal and extrapyramidal signs and with an unusually long survival period of 14 years. Initial magnetic resonance imaging evaluation, single-photon emission computed tomography, and electroencephalogram did not show relevant alterations.

**Results:** The postmortem examination of the brain showed diffuse spongiform change, gliosis, and neuronal loss along with abnormal immunostaining of prion protein in the grey matter, especially in the cerebellum. Indirect *PRNP* genetic analysis was negative.

**Conclusions:** This case is, to our knowledge, the sporadic Creutzfeldt–Jakob disease patient with the longest survival period ever documented. This surprisingly long duration highlights the importance of histopathological confirmation with brain autopsies for suspected cases, as the disease can easily be misdiagnosed in such slowly progressing cases.

## KEYWORDS

Creutzfeldt–Jakob disease, long survival, neuropathology, sporadic CJD

## INTRODUCTION

Creutzfeldt–Jakob disease (CJD) is a rare and devastating neurodegenerative disorder. The sporadic form of the disease (sCJD) is the

most common, although mutation-associated familial or hereditary cases are also known, as well as iatrogenic forms [1]. CJD is caused by neuronal degeneration due to the neurotoxic properties of the misfolded isoform (PrP<sup>Sc</sup>) of cellular or natively folded prion protein

This is an open access article under the terms of the Creative Commons Attribution-NonCommercial License, which permits use, distribution and reproduction in any medium, provided the original work is properly cited and is not used for commercial purposes.

© 2021 The Authors. *European Journal of Neurology* published by John Wiley & Sons Ltd on behalf of European Academy of Neurology

(PrP<sup>C</sup>), which also becomes aggregation prone and accumulates in the central nervous system [2].

The typical clinical features involve rapidly progressive dementia plus two additional symptoms such as cerebellar ataxia, myoclonus, pyramidal or extrapyramidal motor signs, and visual symptoms. Supportive criteria include magnetic resonance imaging (MRI) signal alterations, especially in diffusion-weighted images or fluid-attenuated inversion recovery (FLAIR) images in basal ganglia, with at least two cortical regions affected (temporal, parietal, or occipital), as well as typical periodic sharp and slow wave complexes in electroencephalogram pattern, and the presence of 14-3-3 protein in cerebrospinal fluid (CSF) biomarkers [3]. Among those, detection of minute amounts of PrP<sup>Sc</sup> through real-time quaking-induced conversion (RT-QuIC), a recently developed CSF biomarker that offers high sensitivity (85.7%) and specificity (100%) for the detection of sCJD [4], is worth highlighting. In spite of such recent advances, definitive confirmatory CJD diagnosis is based on pathological evaluation of the brain postmortem, by neuropathological, immunohistochemical, and biochemical analyses aimed at detecting spongiform lesions, astrogliosis, or deposits of proteinase-resistant PrP<sup>Sc</sup>.

Despite being a clinically heterogeneous disease, with marked variability also regarding the age of onset and duration, usual survival periods from diagnosis to death are from 4 to 6 months [5,6]. Other unusually long sCJD cases have been previously reported, one of the longest survival times for sCJD being described in a teenage girl, with initially rapid neurocognitive decline followed by a prolonged 10-year clinical course [7]. To our knowledge, among adults, the longest period described corresponds to a case with 16-year survival after diagnosis of rapidly progressive dementia, with neuropathological postmortem diagnosis of CJD. However, the patient had a family history of similar disease, which could suggest that the disease may not have been sCJD but some other form of prion disease with a longer disease course [8].

Herein, we report the case of an adult with a 14-year survival period after the diagnosis of rapidly progressive dementia, with neuropathological postmortem diagnosis of CJD, which is to our knowledge the longest confirmed case of sCJD ever described.

## METHODS

A 61-year-old woman presented to the hospital with a 2-month history of behavioural change including hyperactivity, aggressiveness, and exhibitionism. She had also developed progressive cognitive decline and in consequence was unable to carry out basic daily activities.

She had no history of other comorbidities, and her family history was unremarkable.

During the next month after hospitalisation, she subsequently developed delirium and visual and auditory hallucinations. The patient was inattentive and disoriented regarding time and space. On the Mini-Mental State Examination, the patient scored 10/30. Neurological examination revealed parkinsonism, including

hypomimia and symmetric increased tone with cogwheel rigidity and bradykinesia. She had no tremor. Cranial nerve, motor, sensory, and cerebellar examinations were normal. Babinski response was absent.

Extensive evaluations for autoimmune, infectious, toxic, metabolic, and neoplastic blood studies showed no alteration. Brain MRI, including diffusion-weighted imaging and single-photon emission computed tomography, was unremarkable. The routine electroencephalogram was normal. CSF analysis was not performed.

Based on the clinical symptoms of rapidly progressive cognitive decline and behavioural change, she received at that time the diagnosis of Pick's disease, more commonly referred to as one of the frontotemporal dementias with tau accumulation [9].

During the clinical course, she was admitted to a psychiatric hospital, where she started to present severe insomnia and new onset episodes of abnormal movements suggestive of myoclonus, which decreased with phenobarbital. Subsequently, as cognitive decline progressed, she developed aphasia with echolalia and perseveration. After a 1-year period from first hospitalisation, she was wheelchair-bound.

At neurological review 18 months after her first evaluation, she was mute, could not walk, even with assistance, and lost sphincter control. On examination, the patient presented with the following neurological symptoms and signs: spontaneous multidirectional nystagmus, akinetic mutism with global hyperreflexia, and extensor plantar response.

In the following years, she developed progressive dysphagia with significant weight loss, for which a dietary modification was prescribed. Nevertheless, during the follow-up, she had several aspiration pneumonia episodes, and she also developed severe constipation.

Follow-up MRI was not performed. During disease follow-up, the patient was prescribed only phenobarbital; neither doxycycline nor trazodone was given, probably because the prion disease condition was not suspected.

Despite having recurrent aspiration pneumonia episodes during the last 2 years that required antibiotic treatment, artificial feeding was not evaluated, despite the attendant risk of aspiration. However, modified-texture food diet and supplemental nutrition shakes were required since institutionalisation.

One hundred seventy-six months after clinical onset, she died of respiratory failure at age 76 years, and an autopsy was conducted.

## RESULTS

Postmortem examination of the brain revealed macroscopic changes. It weighed 790 g before fixation. Cerebral atrophy was observed, particularly in the frontal cortex, associated with widening of ventricles. Basal ganglia, thalamus, brain stem, and cerebellum were macroscopically normal. The pigmentation of the substantia nigra and locus ceruleus was also considered unaltered.

Microscopic examination revealed diffuse spongiosis in the cerebral cortex and moderate spongiosis in basal ganglia (thalamus) and

granule cell layer of the cerebellum (Figure 1). In addition, marked neuronal loss and astrocytic gliosis were observed in the pulvinar and lenticular nuclei, being moderate in cerebral cortex. No spongiform alteration was found in brain stem. Additionally, neuropil threads, tangles, and pretangles were observed in the entorhinal cortex and hippocampus (Braak Stage II).

Immunohistochemical analysis for PrP<sup>Sc</sup> with anti-PrP antibody (amino acids [a.a.] 109–112, clone 3F4 monoclonal antibody) showed synaptic, granular, and plaque-like patchy positivity in the cerebellum, frontal cortex, hippocampus, and parahippocampal circumvolution (Figure 2). The sections on the caudate and putamen nucleus were negative for prion staining. However, amyloid immunostaining with purified anti- $\beta$ -amyloid 1–42 antibody (clone 12F4 monoclonal antibody) was only positive in some leptomeningeal vessels (Figure 3). Alpha-synuclein immunohistochemistry with purified anti- $\alpha$ -synuclein (amino acids 115–121, clone LB509 monoclonal antibody) in the amygdala and midbrain was negative, as well as phosphorylated TDP-43 in hippocampus visualised with anti-phospho-TDP-43 antibody (sp409/410 monoclonal antibody).

Unfortunately, Western blot assay for PrP<sup>Sc</sup> was not possible, because only formalin-fixed and paraffin-embedded brain tissue sections were available.

As no blood sample from the patient was available, genomic DNA of the patient was extracted from formalin-fixed brain tissue using two different methods, QIAamp DNA FFPE Tissue Kit (QIAGEN, Hilden, Germany) and the procedure developed by Campos and Gilbert [10]. On the other side, the DNA of the offspring and the partner was extracted from their peripheral blood using the QIAamp DNA Mini Kit (QIAGEN).

The *PRNP* gene was analysed by direct sequencing of the whole gene, including the coding and untranslated regions and exon/intron boundaries in the patient and her progeny. Insertions and deletions in the octapeptide repeat region and microsatellites flanking the *PRNP* gene (D20S906, D20S842, D20S846, D20S882) were studied by fluorescent PCR and posterior electrophoresis using the 3500 Series Genetic Analyzer (Applied Biosystems, Foster City, CA, USA).

It was not possible to sequence the index *PRNP* gene due to the fragmentation of the DNA sample extracted from formalin-fixed paraffin-embedded brain tissue samples. Because of this, indirect

genetic studies were performed. These studies revealed that none of the descendants presented alteration in the *PRNP* gene. In addition, microsatellite genotyping of her descendants and partner allowed haplotype reconstruction and showed that both alleles of the index had been analysed, as both chromosomes were present within the offspring. As none of the descendants presented any pathogenic variant at *PRNP*, we could infer that the index patient did not carry any alteration in the *PRNP* gene and was homozygous for the Val variant at position 129 of PrP (Figure S1).

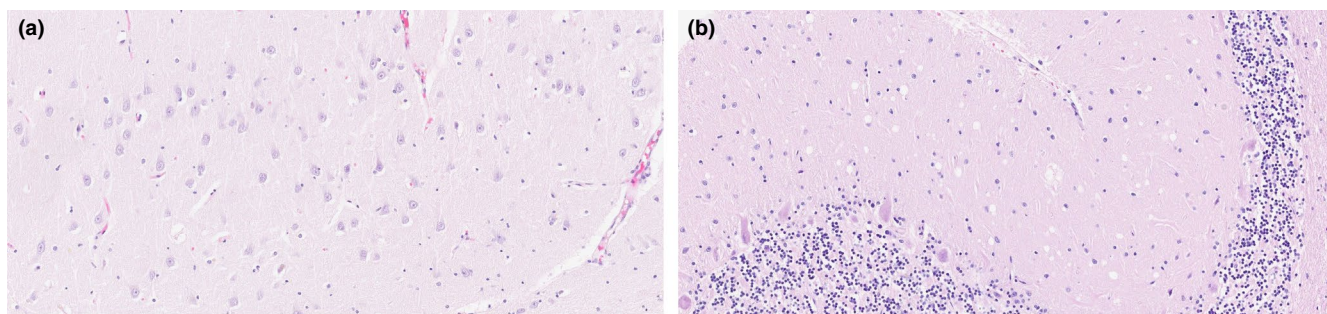
Finally, because the codon 129 was Val/Val, this case should be classified as VV, although the absence of Western blot for the formal distinction between VV1 and VV2 categories precludes further classification [11].

## DISCUSSION

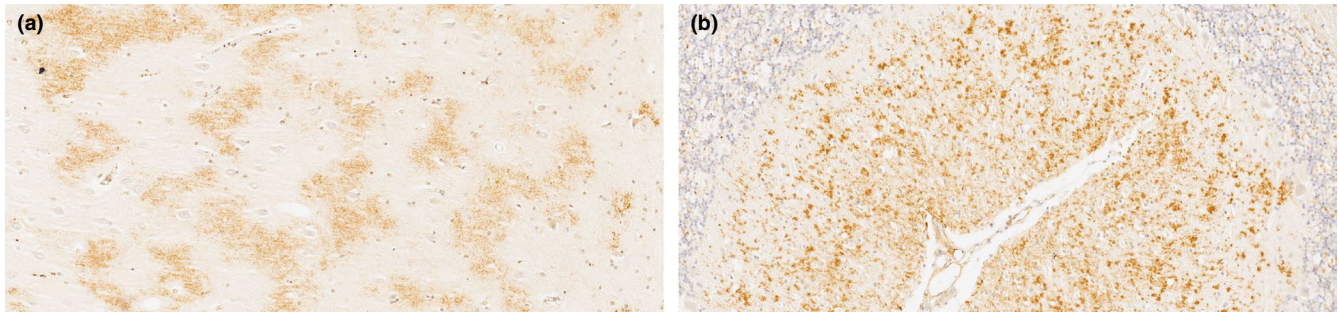
Creutzfeldt-Jakob disease is a rapidly progressive neurodegenerative disorder. To our knowledge, despite a few studies reporting unusually long duration cases of prion disease [7,8,12], mainly case reports from familial or genetic forms of the disease [5], our patient had the longest survival time ever reported for sCJD.

Cutler et al. reported a case of a 16-year duration CJD in 1984 [8], the longest period ever reported for prion disease. However, they presented a case of a 46-year-old man whose father and paternal grandmother both had progressive mental deterioration, and genetic study was absent, so it resembled a familial CJD case.

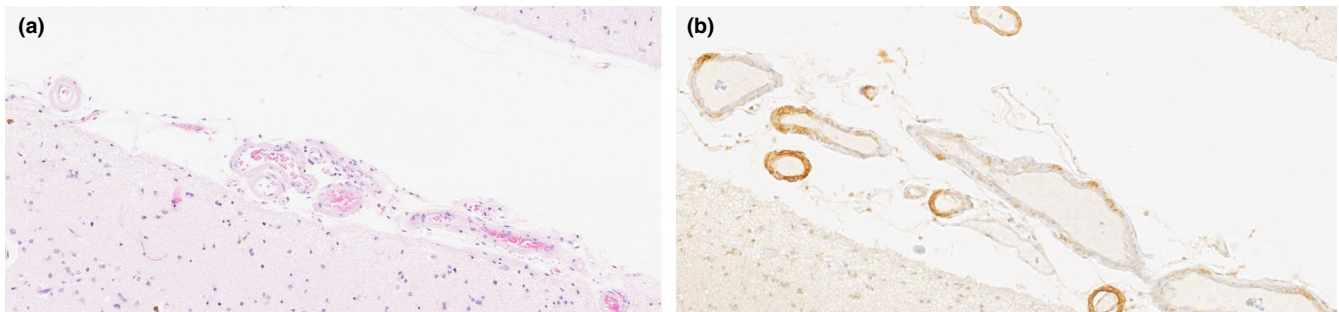
Long survival in sCJD has being reported also in the paediatric population [7], in a 15-year-old girl with a total disease duration of nearly 10 years. The case was clinically characterised by rapid neurocognitive decline followed by myoclonus and seizures. Also, as in our case, the first MRI at presentation only showed mild generalised volume loss; nevertheless, in that case follow-up MRI was performed, presenting diffusion and FLAIR hyperintensity in basal ganglia and pulvinar bilaterally. Genetic study was negative, and neuropathological findings included minimal spongiform change, PrP<sup>Sc</sup> deposits in the neocortex, striatum, and cerebellum by immunohistochemistry, and protease-resistant PrP<sup>Sc</sup> by Western immunoblot.



**FIGURE 1** Low-power photomicrographs (original magnification,  $\times 16$ ) of hippocampus (a) and cerebellum (b) stained with hematoxylin and eosin show characteristic spongiform degeneration (vacuolation) of the grey matter neuropil specific to Creutzfeldt-Jakob disease [Colour figure can be viewed at [wileyonlinelibrary.com](http://wileyonlinelibrary.com)]



**FIGURE 2** Low-power photomicrographs (original magnification,  $\times 16$ ) show prion protein (PrP) staining that identifies widespread accumulation of PrP in a plaque-like, granular, and synaptic-like pattern in parahippocampal gyrus (a) and cerebellum (b) (anti-prion protein, amino acids 109–112, clone 3F4, monoclonal antibody) [Colour figure can be viewed at [wileyonlinelibrary.com](http://wileyonlinelibrary.com)]



**FIGURE 3** Neuropathologic features showed no indication of Alzheimer's disease. Low-power photomicrographs (original magnification,  $\times 16$ ) of anti-amyloid- $\beta$  immunostaining of leptomeningeal vessels in parahippocampal gyrus reveal absence of amyloid deposition (purified anti- $\beta$ -amyloid 1–42, clone 12F4) [Colour figure can be viewed at [wileyonlinelibrary.com](http://wileyonlinelibrary.com)]

The most recently reported data of long survival [12] is a 63-year-old woman with slowly progressive dementia with pre-mortem confirmation of prion disease with positive skin biopsy testing by RT-QuIC assays, who was still alive at 34 months after disease onset.

In our patient, the clinical features of rapidly progressive dementia with pyramidal and extrapyramidal signs during the first year, in addition to the presence of early aphasia and myoclonus, made a pre-mortem diagnosis of CJD far more probable than Alzheimer disease (AD) or frontotemporal dementia. Despite the extremely long 14-year survival, the patient had a rapid clinical progression in the first year, including cognitive impairment, behavioural symptoms, motor involvement, aphasia, and myoclonus. Given that the rest of the neurodegenerative dementias have more specific clinical features than prion disorders, this initial involvement of multiple neuroanatomical regions is uncommon in most of them; evaluated retrospectively, the clinical clues of the first-year period taken altogether were indicative of sCJD. Nevertheless, CJD was not suspected in the present case, mainly due to the long survival and the absence of abnormal findings in brain MRI and electroencephalographic studies. Both tests were done in a very early phase of the disease, and because the results did not indicate a possible prion disease, they were not repeated during the course of her illness.

The co-occurrence of CJD hallmarks with AD-related findings on the neuropathological study, as in our patient, despite being

uncommon, has been previously reported [13,14]. Published data suggest that the coexistence of CJD and AD hallmarks could present in two different ways, on one hand as a regular AD case developing CJD findings in the late stages, or on the other hand as a CJD case that also develops pathological features of AD, without typical clinical findings of AD [13]. The patient reported here, according to the clinical evidence described, suggests the second option, because the main clinical hallmarks in our patient were rapid progressive dementia, with initial psychiatric and dysphasic characteristics, followed by progressive parkinsonism.

Typically, AD patients show brain atrophy, most marked in the medial temporal lobes, with relative preservation of the primary motor cortex and occipital lobes. In our case, we found atrophic brain, predominantly frontal, with ventricular dilatation.

In AD, there is also an accumulation of two proteins, extracellular beta amyloid peptide ( $A\beta$ ) within plaques [15] and abnormally phosphorylated tau in neurofibrillary tangles [16]. Amyloid peptide plaques were not present in our case. Although some leptomeningeal vessels showed some positivity on  $A\beta$  staining, these findings have been previously mentioned in sCJD patients, mainly in elderly cases [17]. The deposition of abnormal tau protein in the brain is not unique to AD but is also observed in many other neurodegenerative disorders [18–20]. In our case, tau pathology manifested in Braak Stage II findings, with neuropil threads, tangles, and pretangles in the entorhinal cortex and hippocampus.

Spongiform changes can occur in AD [21], similar to that observed in CJD [22], particularly when it is concomitant with Lewy bodies disease [23]. The spongiform change in AD usually involves the superior and inferior temporal, entorhinal, and insular cortices, as well as the amygdala [24]. In contrast, spongiform change in CJD is more widespread, with the involvement of the neocortex, striatum, thalamus, and cerebellum [22,25]. In our patient, diffuse and patchy spongiosis was observed in the cerebral cortex, the cerebellar molecular layer, and, to a lesser extent, in the basal ganglia, matching what is expected for CJD.

However, one of the most relevant findings from the immunohistochemical study was the detection of synaptic, granular, and plaque-like patchy positivity for PrP<sup>Sc</sup> in the cerebellum, frontal cortex, hippocampus, and parahippocampal circumvolution, undoubtedly pointing towards prion disease.

Finally, there were no alpha-synuclein or phosphorylated TDP-43 inclusions, ruling out synucleinopathies or frontotemporal lobar degeneration. However, the latter could not be completely discarded, given that accumulation of other misfolded proteins such as FUS can also cause the disease [26]. To rule out the presence of Transmissible spongiform encephalopathies associated mutations, which could explain a slower or atypical disease progression than that expected for sCJD, genomic DNA from fixed brain samples was extracted, but the fragmentation of the extracted material due to its long conservation in the fixing agent impeded sequencing of the *PRNP* gene. Although genotyping of descendants of the index case demonstrated the absence of such disease-associated mutations at least in the germline, in agreement with the latest reports of the potential role of somatic mutations in adult onset neurodegenerative disorders [27], the existence of such an event could not be discarded.

Unfortunately, as there was only formalin-fixed and paraffin-embedded brain tissue, the Western blot assay for PrP<sup>Sc</sup>, which would support the findings from the neuropathological analysis and permit further classification of the disease subtype, was impossible to perform, nor was it possible to analyse CSF for protein aggregation assays by RT-QuIC. Nonetheless, based on the genetic information from the descendants, we could conclude the genotype of the patient regarding polymorphisms at codon 129, which was Val/Val. Therefore, we could classify the case as sCJD of VV subtype, although the distinction between VV1 and VV2 types in accordance with the molecular classification proposed by Parchi and Saverioni [11] was not possible. Histopathological analysis also allows distinction of subtypes in certain cases, because neuropathological hallmarks are distinguishable for some subtypes. However, the variability among cases of the same subtype makes it far more complicated than the biochemical classification derived from proteinase K digestion and Western blotting detection of disease-associated PrP<sup>Sc</sup>. In the case of VV subtypes, VV2 shows usually medium-size vacuoles in striatum, hippocampus, limbic cortex, thalamus, cerebellum (molecular layer), and midbrain, and in the neocortex, the spongiform change affects deep layers predominantly. In contrast, VV1 subtype is characterised by similar spongiform changes in neocortex

and striatum mainly, with sparing of brainstem and cerebellum. In the case presented herein, diffuse spongiosis in the cerebral cortex and moderate spongiosis in basal ganglia (thalamus) and the granule cell layer of the cerebellum were observed, reminiscent of Subtype 2 more than Subtype 1. In terms of PrP immunohistochemistry, we observed synaptic, granular, and plaquelike patchy positivity in the cerebellum, frontal cortex, hippocampus, and parahippocampal circumvolution, which does not completely match with the PrP deposition expected for VV1 or VV2, although synaptic and plaquelike deposits may be more frequently associated also with the VV2 type. In any case, the lack of biochemical characterisation of the PrP<sup>Sc</sup> from the deposits impedes drawing robust conclusions on this matter, which is further complicated by the potential existence of strain mixes [28] and by atypical manifestations, which could easily happen with this case, given the unusually long duration.

## CONCLUSION

We considered this case important to present, on the one hand because as it is a rare disease, reporting every unusual case of CJD could significantly improve our understanding of this disorder and all its possible manifestations. On the other hand, it is an example of the importance of thorough histopathological studies from brains in atypical rapidly progressive dementias, as the lack of thereof could easily lead to misdiagnosis, as demonstrated by our case.

## ACKNOWLEDGEMENTS

The authors would like to thank Karol Jimenez for technical assistance and the family that participated in the study.

## CONFLICT OF INTEREST

The authors have no competing interests to declare.

## AUTHOR CONTRIBUTIONS

**Izaro Kortazar-Zubizarreta:** Conceptualisation (equal), data curation (equal), investigation (equal), methodology (equal), project administration (equal), writing—original draft (equal), writing—review & editing (equal). **Rebeca Ruiz-Onandi:** Data curation (equal), validation (equal). **Arrate Pereda:** Data curation (equal), formal analysis (equal), investigation (equal), methodology (equal), writing—review & editing (equal). **Yerai Vado:** Formal analysis (equal), methodology (equal). **Gonzalo González-Chinchon:** Supervision (equal). **Hasier Eraña:** Conceptualisation (equal), formal analysis (equal), investigation (equal), methodology (equal), project administration (equal), writing—review & editing (equal). **Guimar Perez de Nanclares:** Conceptualisation (equal), data curation (equal), formal analysis (equal), project administration (equal), supervision (equal), writing—review & editing (equal). **Joaquín Castilla:** Conceptualisation (equal), data curation (equal), formal analysis (equal), funding acquisition (equal), investigation (equal), methodology (equal), project administration (equal), resources (equal), supervision (equal), validation (equal), writing—review & editing (equal).

## ETHICAL APPROVAL

The Clinical Research Ethics Committee of the Basque Country approved the study (PI2021019). Informed consent was obtained from all individual participants included in the study.

## CONSENT TO PARTICIPATE

Family members consented to publication.

## DATA AVAILABILITY STATEMENT

Data are available upon request due to privacy/ethical restrictions.

## ORCID

Izaro Kortazar-Zubizarreta  <https://orcid.org/0000-0002-8107-660X>

Rebeca Ruiz-Onandi  <https://orcid.org/0000-0003-3667-4333>

Arrate Pereda  <https://orcid.org/0000-0002-5442-7873>

Yerai Vado  <https://orcid.org/0000-0003-4156-9159>

Gonzalo González-Chinchon  <https://orcid.org/0000-0001-5474-8717>

Hasier Eraña  <https://orcid.org/0000-0001-8776-4211>

Guiomar Perez de Nanclares  <https://orcid.org/0000-0002-2424-5294>

Joaquín Castilla  <https://orcid.org/0000-0002-2216-1361>

## REFERENCES

- Geschwind MD. Prion diseases. *Continuum*. 2015;21:1612-1638. Lippincott Williams and Wilkins.
- Requena JR, Wille H. The structure of the infectious prion protein and its propagation. *Prog Mol Biol Transl Sci*. 2017;150:341-359.
- Zerr I, Kallenberg K, Summers DM, et al. Updated clinical diagnostic criteria for sporadic Creutzfeldt-Jakob disease. *Brain*. 2009;132(10):2659-2668.
- McGuire LI, Poggioli A, Poggiolini I, et al. Cerebrospinal fluid real-time quaking-induced conversion is a robust and reliable test for sporadic creutzfeldt-jakob disease: an international study. *Ann Neurol*. 2016;80(1):160-165.
- Pocchiari M, Puopolo M, Croes EA, et al. Predictors of survival in sporadic Creutzfeldt-Jakob disease and other human transmissible spongiform encephalopathies. *Brain*. 2004;127(10):2348-2359.
- Llorens F, Rübnsamen N, Hermann P, et al. A prognostic model for overall survival in sporadic Creutzfeldt-Jakob disease. *Alzheimer's Dement*. 2020;16(10):1438-1447.
- D'Arcy CE, Bitnun A, Coulthart MB, et al. Sporadic Creutzfeldt-Jakob disease in a young girl with unusually long survival. *J Neuropathol Exp Neurol*. 2019;78(4):373-378.
- Cutler NR, Brown PW, Narayan T, Parisi JE, Janotta F, Baron H. Creutzfeldt-Jakob disease: a case of 16 years' duration. *Ann Neurol*. 1984;15(1):107-110.
- Mackenzie IRA, Neumann M, Bigio EH, et al. Nomenclature for neuropathologic subtypes of frontotemporal lobar degeneration: consensus recommendations. *Acta Neuropathol*. 2009;117(1):15-18.
- Campos PF, Gilbert TMP. DNA extraction from formalin-fixed material. *Methods Mol Biol*. 2012;840:81-85.
- Parchi P, Saverioni D. Molecular pathology, classification, and diagnosis of sporadic human prion disease variants. *Folia Neuropathol*. 2012;50:20-45.
- Liu XY, Shi Q, Wang G. Long survival sporadic Creutzfeldt-Jakob disease. *Neurology*. 2020;95(2):87-88.
- Tsuchiya K, Yagishita S, Ikeda K, et al. Coexistence of CJD and Alzheimer's disease: an autopsy case showing typical clinical features of CJD. *Neuropathology*. 2004;24(1):46-55.
- Miyake K, Hara T, Oshima E, et al. Creutzfeldt-Jakob disease with Alzheimer pathology, presenting with status epilepticus following repeated partial seizures: a case report and literature review. *BMC Neurol*. 2018;18(1):54-58.
- Murphy MP, LeVine H. Alzheimer's disease and the amyloid-beta peptide. Lovell MA, editor. *J Alzheimers Dis*. 2010;19(1):311-323.
- Gomez-Isla T, Spire T, De Calignon A, Hyman BT. Neuropathology of Alzheimer's disease. *Handb Clin Neurol*. 2008;89:233-243.
- Debatin L, Streffer J, Geissen M, Matschke J, Aguzzi A, Glatzel M. Association between deposition of beta-amyloid and pathological prion protein in sporadic Creutzfeldt-Jakob disease. *Neurodegener Dis*. 2008;5(6):347-354.
- Crary JF, Trojanowski JQ, Schneider JA, et al. Primary age-related tauopathy (PART): a common pathology associated with human aging. *Acta Neuropathol*. 2014;128(6):755-766.
- Hickman RA, Flowers XE, Wisniewski T. Primary age-related tauopathy (PART): addressing the spectrum of neuronal tauopathic changes in the aging brain. *Curr Neurol Neurosci Rep*. 2020;20(9):39.
- Kovacs GG. Tauopathies. *Handb Clin Neurol*. 2018;145:355-368.
- Sherzai A, Edland SD, Masliah E, et al. Spongiform change in dementia with Lewy bodies and Alzheimer disease. *Alzheimer Dis Assoc Disord*. 2013;27(2):157-161.
- Iwasaki Y. Creutzfeldt-Jakob disease. *Neuropathology*. 2017;37(2):174-188.
- Hansen LA, Masliah E, Terry RD, Mirra SS. A neuropathological subset of Alzheimer's disease with concomitant Lewy body disease and spongiform change. *Acta Neuropathol*. 1989;78(2):194-201.
- Fujino Y, Dickson DW. Limbic lobe microvacuolation is minimal in Alzheimer's disease in the absence of concurrent Lewy body disease. *Int J Clin Exp Pathol*. 2008;1(4):369-375.
- Parchi P, De Boni L, Saverioni D, et al. Consensus classification of human prion disease histotypes allows reliable identification of molecular subtypes: an inter-rater study among surveillance centres in Europe and USA. *Acta Neuropathol*. 2012;124(4):517-529.
- Chornenka K, Hirsch-Reinshagen V, Perez-Rosendahl M, et al. Expanding the phenotype of frontotemporal lobar degeneration with FUS-positive pathology (FTLD-FUS). *J Neuropathol Exp Neurol*. 2020;79(7):809-812.
- Nicolas G, Veltman JA. The role of de novo mutations in adult-onset neurodegenerative disorders. *Acta Neuropathol*. 2019;137(2):183-207.
- Cali I, Puoti G, Smucny J, et al. Co-existence of PrPD types 1 and 2 in sporadic Creutzfeldt-Jakob disease of the VV subgroup: phenotypic and prion protein characteristics. *Sci Rep*. 2020;10:1503.

## SUPPORTING INFORMATION

Additional supporting information may be found online in the Supporting Information section.

**How to cite this article:** Kortazar-Zubizarreta I, Ruiz-Onandi R, Pereda A, et al. Sporadic Creutzfeldt-Jakob disease with extremely long 14-year survival period. *Eur J Neurol*. 2021;28:2901-2906. <https://doi.org/10.1111/ene.14946>