

Review Article

An overview of surgery-first orthognathic approach: History, indications and limitations, protocols, and dentoskeletal stability

Atefe Ahmadvand¹, Shiva Alavi², Saeed Hasani Mehraban³

¹Department of Orthodontics, Dental Students' Research Committee, School of Dentistry, Isfahan University of Medical Sciences, ²Department of Orthodontics, Dental Research Center, School of Dentistry, Dental Research Institute, Isfahan University of Medical Sciences, Isfahan, ³Department of Oral and Maxillofacial Surgery, School of Dentistry, Tehran University of Medical Sciences, Tehran, Iran

ABSTRACT

The most common orthognathic surgery approach consists of three steps: presurgical orthodontic treatment, surgery, and postsurgical orthodontic treatment. Despite its advantages, this technique has some disadvantages, too, including a long treatment period, problems in mastication and articulation, temporary worsening of the patient's appearance, and psychological problems for the patient. The introduction of the surgery-first orthognathic approach has been an attempt to overcome these problems. In this article, we wish to provide a comprehensive overview on this approach. In this approach, which consists of surgery without orthodontic preparation and a short period of orthodontic treatment after it, the overall duration of treatment decreases and the patient's appearance improves. The skeletal anchorage, placed at the time of surgery, can be used to facilitate tooth movements after surgery. Despite the advantages of this technique, it is associated with some limitations; in particular, occlusion cannot have a guiding role during surgery. Therefore, correct diagnosis, prediction of the outcomes, and simulating correction with the model setup are of crucial importance. The surgeon's knowledge and expertise have a significant role in this respect.

Key Words: Maxillofacial orthognathic surgery, orthodontics, orthognathic surgical procedure, stability

Received: 14-Dec-2019
Revised: 29-Jul-2020
Accepted: 20-Sep-2020
Published: 22-Jun-2021

Address for correspondence:

Dr. Shiva Alavi,
Department of
Orthodontics, Dental
Research Center, Dental
Research Institute, Isfahan
University of Medical
Sciences, Isfahan, Iran.
E-mail: alavi@dnt.mui.ac.ir

INTRODUCTION

Presurgical orthodontic preparation was uncommon until 1960. The patients' and clinicians' desire for optimal esthetic and occlusal outcomes resulted to the most common current treatment approach presurgical orthodontic decompensation of the occlusal relationships and obtaining the normal dental alignment.^[1] The aims of presurgical preparation are:

1. Dental decompensation so that the teeth can be placed on the basal bone irrespective of the relationship with the opposing jaw

2. Aligning and leveling of the teeth and resolving any crowding
3. Coordinating the upper and lower jaws
4. Divergence of roots adjacent to surgical sites where interdental osteotomies are planned.

Presurgical orthodontic treatment reveals the true skeletal discrepancy before surgery and helps determine the required amount of the dental decompensation that limits the full correction of the

This is an open access journal, and articles are distributed under the terms of the Creative Commons Attribution-NonCommercial-ShareAlike 4.0 License, which allows others to remix, tweak, and build upon the work non-commercially, as long as appropriate credit is given and the new creations are licensed under the identical terms.

For reprints contact: reprints@medknow.com

How to cite this article: Ahmadvand A, Alavi S, Mehraban SH. An overview of surgery-first orthognathic approach: History, indications and limitations, protocols, and dentoskeletal stability. Dent Res J 2021;18:47.

Access this article online	
	<p>Website: www.drj.ir www.drjjournal.net www.ncbi.nlm.nih.gov/pmc/journals/1480</p>

skeletal deformity. This treatment approach usually results in satisfactory outcomes.^[2]

The disadvantages of orthodontic interventions before and after orthognathic surgery include the following: a long treatment time, resulting in an increase in the dental caries; gingival recession and root resorption; temporary worsening the patient's appearance; discomfort during mastication and articulation; and psychological problems due to the delays in achieving the patient's main demand, which is usually an esthetic facial appearance.^[3,4] In addition, if the patient refuses surgery after all these preparations, the results will be catastrophic.^[1]

In 1995, for the first time, Skaggs suggested surgery before orthodontic treatment in patients with mild dental problems;^[5] later in 1988, Behrman and Behrman proposed a concept like that^[6] which was repeated in 1991 by Brachvogel *et al.*^[7] however, these were conceptual suggestions only. In 2009, for the first time, Nagasaka *et al.* applied the surgery-first approach (SFA) clinically in the form of a systematic team approach between the orthodontist and surgeon and published the relevant articles.^[8] This technique, which is called the surgery-first orthognathic approach (SFOA) or the SFA, is defined as surgery without orthodontic preparation; orthodontic treatment is carried out after surgery. In this technique, no prior tooth movements or minimal tooth decompensation for 1 or 2 months in cases with occlusal interferences are implemented before surgery, so it is possible to rapidly achieve facial esthetic appearance, which is the patient's chief complaint before the treatment.^[2]

Behrman and Behrman claimed that the normalized surrounding soft tissues (lips, cheeks, and tongue) would settle the teeth in a better position after surgery, facilitate the remaining tooth movements, and decrease the overall duration of treatment. However, conclusive evidence is not available to substantiate these claims due to the paucity of comparative clinical trial reports.^[6]

Furthermore, since the teeth do not occlude properly after surgery, tooth movements are facilitated.^[2] Another factor that can accelerate tooth movements after orthognathic surgery is a phenomenon resembling the regional acceleratory phenomenon. It has been shown that, during the healing process after orthognathic surgery, the blood flow increases to levels higher than that before surgery, increasing bone turnover.^[9] In addition, it has been shown that the

serum levels of alkaline phosphatase and C-terminal telopeptidase Type I collagen, which are two markers of bone turn over, increase until 3–4 months after surgery in patients undergoing orthodontic surgery using the SFA.^[10]

Rigid fixation of bone segments was the key to the widespread use of SFOA. Another device was the skeletal anchorage system.^[11] Skeletal anchorage can help increase the arch length by distalization of posterior teeth to accommodate the crowded teeth and achieve a correct incisor inclination after surgery. This temporary device can help achieve predictable three-dimensional movements of the whole dentition in nongrowing patients, thereby widening the primary indications for the SFA.^[11]

In this article, we wish to provide a comprehensive overview on this approach.

MATERIALS AND METHODS

The related dental literature was searched using databases such as Medline or PubMed and Google Scholar from 1959 to 2020. The search items used were “maxillofacial orthognathic surgery,” “orthognathic surgical procedure,” “surgery first approach,” “orthognathic surgery first approach,” “orthodontics,” “stability,” and “regional acceleratory phenomenon.” Relevant articles in topic and abstract were assessed and included. Case/controls and case series from 2010 to 2020 were collected in a table and compared in the article [Table 1].

INDICATIONS AND LIMITATIONS OF THE SURGERY-FIRST APPROACH

Since each patient has an individual condition in terms of the type of malocclusion and dentofacial deformity, there are no specific criteria for the application of the SFOA technique. The patients who are candidates for this technique are those who are in a hurry to achieve esthetic results or those who want to improve both their function and esthetic appearance but cannot afford the cost of orthodontic preparation. The selection criteria largely depend on the experience and skill of the surgeon and orthodontist.^[2]

The suggested criteria for the application of this technique include the following: well-aligned to mildly crowded anterior teeth, a flat to mild curve of Spee, normal to mild proclination or retroclination of incisors (the angle of maxillary and mandibular

Table 1: Literature review of orthognathic surgery using surgery-first approach

Authors (year)	Study design	Sample size	Type of malocclusion	Presurgical orthodontic treatment	Bracket bonding before surgery	Archwire placement before surgery	Surgical method	Use of surgical splint after surgery	Initiation of postoperative orthodontic treatment	Fixation method	Total treatment time (months)
Baek <i>et al.</i> (2010)	Case series	11	Class III	1–2 months	Using bracket or without bracket	Passive surgical wires	LF+BSSO	4 weeks	4 weeks	NR	12.2±3.6
Liao <i>et al.</i> (2010)	Case/control	20 SFA, 13 CA	Class III+open bite	No	1 month	1–3 days (016x022 NiTi)	LF+BSSO	NR	Immediately	Rigid fixation	SFA 11.4±4.2 CA 17.1±3.4
Wang <i>et al.</i> (2010)	Case/control	18 SFA, 18 CA	Class III	No	1–2 weeks	NR	LF+BSSO	NR	NR	NR	NR
Ko <i>et al.</i> (2011)	Case/control	18 SFA, 35 CA	Class III	No	Before surgery	016 SS	LF+BSSO	NR	Immediately (not clear)	NR	SFA 17.8±5 CA 15.8±2.7
Hernandez-Alfaro <i>et al.</i> (2014)	Case series	45	Class II (19), Class III (22), asymmetry (4)	No	1 week	1 day (soft wire)	LF+BSSO, LF, BSSO, others	2 weeks (only for maxillary segmental surgery)	2 weeks	NR	8.8
Kim <i>et al.</i> (2014)	Case/control	23 SFA, 38 CA	Class III	No	Before surgery	Passive wires	BSSO	4–6 weeks	NR	Rigid fixation	SAF 15.4 CA 22.5
Kim <i>et al.</i> (2014)	Case series	37	Class III	No	NR	2–3 weeks (surgical wires)	LF+IVRO	4 weeks	2±1 months	IMF	14±6
Choi <i>et al.</i> (2015)	Case/control	32 SFA, 24 CA	Class III	No	Using bracket or without bracket	Passive surgical wires	LF+BSSO	NR	NR	Rigid fixation	SFA 19.4 CA 22.3
Narayan <i>et al.</i> (2016)	Case series	2 SFA	Class III	No	Before surgery	Brackets ligated with SS ligature wire	LF+BSSO+others	NR	1–4 weeks	NR	7.5
Woo Shik <i>et al.</i> (2017)	Case/control	104 SFA 51 CA	Class III	No	Before surgery	NR	LF+BSSO	Yes (duration not reported)	NR	Semi-rigid fixation	NR
Saghafi <i>et al.</i> (2020)	Case/control	18 SFA 14 CA	Class II, Class III	No	Immediately before surgery	NR	LF+BSSO+others	NR	2 weeks	NR	NR

NR: Not reported; NiTi: Nickel-titanium; SS: Stainless steel; SFA: Surgery-first approach; CA: Conventional approach; LF: Lefort; BSSO: Bilateral Sagittal Split Osteotomy

incisors relative to the basal bone in the normal range), and minimal transverse discrepancy.^[1]

Class III patients with mandibular prognathism and open bite are good candidates for this treatment approach because they usually have mild crowding and dental compensation.^[12] Baek *et al.* suggested this surgical technique for skeletal Class III patients, who do not need tooth extraction, with at least three stable occlusal stops and positive overbite of six anterior teeth and existing arch coordination.^[13] However, based on a technique introduced in Sendai, it has been pointed out that there is no need for three-point occlusal contacts during mandibular surgery because it might result in the posterior ramus elongation, which has high potential of relapse.^[14] Liao and Lo results indicated that stable occlusion can be achieved by occlusal contact on 5–6 teeth or occlusal contact on not only three segments but also on two or one (i.e., anterior) segments.^[15]

It has been reported that the risk of the complications of SFOA is a little higher than the conventional surgical techniques due to an increase in segmental osteotomies.^[16] Patients with temporomandibular joint or periodontal problems may not be candidates for the SFA.^[17] In addition, it has been suggested that this technique should not be considered for patients with deformity-related clefts, those with a high potential for CR-CO discrepancy, those with unilateral or bilateral crossbite or scissor bite postsurgery,^[18] and those who have very high esthetic and occlusal stability expectations from the treatment outcomes.^[19] The main limitations of this technique are severe curve of Spee and asymmetries in the vertical dimension.^[19] At present, technical and clinical experience advances have modified the indication and contraindications of this surgical technique, and it appears that technological advances are overcoming the barriers to this technique. For example, inferior subapical osteotomy has been applied to surgically decompensate the severely retroclined mandibular incisors.^[20] Furthermore, successful treatment outcomes have been achieved in patients with skeletal asymmetry,^[21,22] open bite,^[23,24] and cleft lip palate^[25] with the use of the SFOA. This approach combined with condylectomy has been performed in a patient with condylar hyperplasia, obtaining excellent facial and occlusal outcomes.^[26]

Some of the disadvantages of this technique include:

1. Prediction of the final occlusion is the most critical challenge in this technique due to several dental interferences
2. Patients needing tooth extraction are difficult cases with the use of this technique
3. Any minor surgical error might affect the treatment outcome
4. The treatment planning process is very time-consuming compared to the overall time required for treatment^[1]
5. The patients might not be interested in continuing the orthodontic treatment, which leads to outcomes that are not favorable in terms of the main clinical aims and orthodontic stability
6. Since the time of surgery depends on the jaw growth stage, the treatment of patients with this technique might be delayed until the completion of growth; however, the orthodontic treatment before the patient's surgery could be carried out in the final stages of growth.^[2]

Nowadays, computer-assisted methods can be used to improve the diagnostic and therapeutic SF preoperative planning by linking the virtual orthodontic planning with the virtual surgical planning.^[27]

SURGERY-FIRST ORTHOGNATHIC APPROACH PROTOCOL

SFOA can be implemented using two methods: the surgical-driven approach and the orthodontic-driven approach. In the former approach, both the jaw and dental deformities are corrected surgically. In the latter approach, the jaw deformity is corrected surgically, and the dental deformity is corrected with orthodontic treatment [Figure 1]; in this technique, after correcting the jaw relationship surgically, miniplates are used as a skeletal anchorage system for orthodontic movements.^[28]

Presurgical preparation

Regarding postsurgical orthodontics, presurgical preparation can be carried out in different ways:

1. Placement of surgical arch bar, without orthodontic archwire
2. Placement of anchor screws, without orthodontic archwire
3. Placement of light round or light rectangular wire (with or without screws or anchor plates)
4. Placement of conventional passive, rectangular wires attached with surgical hooks (with or without anchor screws).

Since the surgical hooks cannot be placed on light round or light rectangular wires, extra anchor

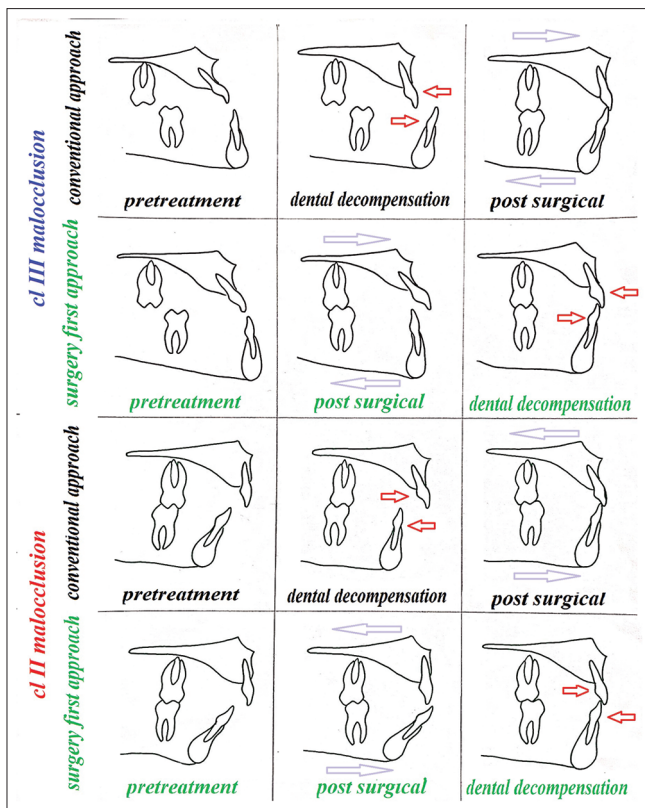


Figure 1: Surgery-first orthognathic approach compared to the conventional orthognathic approach (red arrow: orthodontic movement; purple arrow: surgical movement).

screws and plates are used for maxillomandibular fixation (MMF).

Researchers prefer the use of anchor screws to orthodontic hooks for postoperative MMF and elastic traction.^[29]

Some orthodontists use passive stainless steel wires adapted to all the teeth to prevent any tooth movements until the stability of determined positions of the jaws has been achieved,^[13,30] while some others are interested in immediate tooth movements after surgery; therefore, they prefer nickel–titanium archwires.^[31,32]

Alternatively, Baek *et al.* suggested that the archwire can be directly bonded to tooth surfaces a few days before surgery to perform as an arch bar. Although this technique is comfortable for the patient, it is difficult to remove the bonded archwire and replace it with a bracket during the healing period after surgery.^[13]

To avoid severe postoperative occlusal instability, orthodontists can remove occlusal interference by simple occlusal adjustment in mild cases and opening

the bite in more severe cases.^[15] Some authors have suggested presurgical orthodontic treatment for at least 1–2 months in patients with severe occlusal interferences;^[13] however, many others have not carried out any presurgical orthodontic treatment.^[23,33,34] The time of placement of orthodontic wires and surgical wires for intermaxillary fixation varies in different studies from 1 to 3 days before surgery^[23,35] to 2–3 weeks before surgery.^[36]

Model surgery

In the model surgery, the maxillary and mandibular casts are placed in the correct molar relationship with positive overbite. Contrary to the conventional technique, in which the decompensated incisors are used as a guide for the prediction of the final occlusion, here, the molar teeth are used as a guide. In cases of nonextraction or bimaxillary first premolar extraction, the molar relationship is adjusted at CI I relationship. In patients with the extraction of mandibular first premolars, it is adjusted at CI III relationship, and in patients with the extraction of maxillary first premolars, it is adjusted at CI II relationship.^[37] Liao *et al.* suggested 2 mm overcorrection when there is a need for compensation of horizontal skeletal relapse so they often set the Class II molar relationship in their occlusion setup.

The vertical dimension in their guidelines suggests deep overbite or posterior open bite for preventing bite opening from dental alignment and arch leveling after surgery because the posterior open bite is easier to correct than anterior open bite after surgery. The posterior open bite is also helpful for correction of posterior crossbite from buccoversion of maxillary second molars.

In the transverse dimension to prevent positional asymmetry, the maxillary and mandibular jaw (alveolar base) midlines must be coincident or close to it. Since the surgical occlusion is sometimes set with dental midline off due to dental arch asymmetry, they suggested surgical occlusion to be set as coordination of jaw midlines instead of dental midlines.^[15]

Baek *et al.* used a different technique for the model surgery in skeletal CI III cases with two jaws surgery. In this technique, it is necessary to use a semi-adjustable articulator. The dental and base sections of the study models are separated for skeletal changes and alignment of the teeth, and after making the changes and modifications, intermediate and final surgical wafers are prepared.

In this technique, the orthodontist must have experience and confidence to be able to move the teeth similar to the results of the model surgery.^[13]

Postsurgical orthodontic treatment

There is no consensus on the time of orthodontic treatment initiation. Since dental compensation in the dental arches has not been eliminated before surgery, it is expected that the occlusion will be very unstable due to the presence of premature contacts. Some authors begin leveling the dentition to eliminate occlusal interferences and coordinate the arches immediately. Replacing heavy stabilizing wires with light and flexible wires immediately after surgery has been suggested to shorten the duration of postsurgical orthodontic treatment.

Some others also have emphasized that the postsurgical orthodontic treatment should begin as soon as possible to maximally benefit from the advantages of the regional acceleratory phenomenon after surgery.^[12] This time might vary from 1 week to 1 month.^[38,39]

Orthopedic appliances, such as the facemask or chin cup, might be used in CI III patients for the maintenance of the jawbone position during orthodontic tooth movements.^[37] Concerning the time to use a surgical splint, some have recommended its use only at the time of surgery; however, some others have recommended its use 1–4 weeks after surgery.^[1]

SPECIFIC GUIDELINES

Dental decompensation in the anteroposterior and vertical dimensions in class III patients

1. Two techniques are available to decompensate the proclined upper incisors in CI III patients: by extraction of the maxillary first premolar teeth and anterior segmental osteotomy, or by clockwise (CW) rotation of the maxilla during LeFort I osteotomy (preferred approach)
2. To decompensate the moderately retroclined and crowded lower incisors, the molars can be set up in CI I relationship and excessive overjet can be resolved after surgery by aligning the anterior teeth
3. To decompensate the severely retroclined and crowded mandibular incisors, after mandibular first premolar extraction, the molars can be placed in CI III relationship, and the excessive overjet can be resolved after surgery by aligning the anterior teeth
4. It is advisable to flatten moderate to deep curve of Spee in the mandible before surgery or surgically

with anterior segmental osteotomy to prevent upward and forward rotation of the mandible after surgery. Upward and forward rotation of the mandible improves the chin projection in CI II mandibular retrognathism patients; however, it worsens the chin projection in CI III patients with mandibular prognathism patients. Alternatively, it is possible to intrude the lower incisors and extrude upper incisors simultaneously to prevent the upward and forward rotation of the mandible after surgery

5. A chin cup can be used during the 3-month period after surgery to prevent skeletal mandibular relapse.

Dental decompensation in the anteroposterior and vertical dimensions in class II patients

1. In moderate to deep curve of Spee and proclined lower incisors in CI II mandibular retrognathism patients, it is possible to level and intrude the anterior teeth during anterior segmental osteotomy; therefore, the mandible can be adequately advanced
2. Alternatively, it is possible to advance the mandible to an edge-to-edge incisors relationship without posterior teeth occlusal contact. Then, the mandibular anterior teeth can be intruded after surgery, which is followed by the upward and forward rotation of the mandible, providing the contact of the posterior teeth, and improving the chin projection^[37]
3. The upper incisor inclination is important in deciding for extracting or not extracting teeth in the maxilla. If the angle of maxillary incisors relative to the occlusal plane is $<53^{\circ}$ – 55° , tooth extraction should be considered.^[1]

SKELETAL STABILITY

It has been reported that the dentoskeletal relapse is related to factors such as the fixation method of the bone plates, muscle contraction, maxillary constriction, the curve of Spee, and increased overjet and overbite. Better stability has been observed in patients with a flat curve of Spee and smaller overbite. Some authors have reported a relationship between the amount of relapse and the surgical technique and the sequence of orthodontic treatment with surgery. In the SFA, more favorable arch coordination can be achieved after elimination of the functional muscular forces in an unfavorable skeletal position. However,

this method is technique-sensitive, and the stability of treatment outcome can be affected by factors such as unfavorable fixation of jaw segments, lack of integrity of the osteotomized bone segments during healing, a loose IMF, an improper position of the condyle relative to the cranial base, improper placement of the proximal and distal segments which leads to torquing of the proximal parts, and an unfavorable splinting. In addition, the CR-CO discrepancy has a pivotal role in the equilibrium of the functional matrix.^[40]

Studies have not shown any significant differences in the transverse dimension stability between the SFOA and the conventional approach. Liao *et al.* reported greater anti-CW rotation in the vertical plane, while Kim *et al.* reported greater CW rotation in the mandible of patients undergoing SFOA, compared to those who underwent conventional approach. In the sagittal plane, Kim *et al.* reported greater relapse in the SFOA approach compared to conventional approach.^[15,36]

CONCLUSION

Although the SFA has some advantages, such as shortening the duration of treatment and rapid response to the patient's chief complaint, it has also some limitations. In particular, occlusion cannot have a guiding role during surgery. Therefore, patient/case selection, appropriate diagnosis, accurate prediction of the postoperative outcomes, and simulation with the model surgery are of utmost importance. The knowledge and experience of the orthodontist and surgeon have a pivotal role in this technique.

Financial support and sponsorship

Nil.

Conflicts of interest

The authors of this manuscript declare that they have no conflicts of interest, real or perceived, financial or non-financial in this article.

REFERENCES

- Sharma VK, Yadav K, Tandon P. An overview of surgery-first approach: Recent advances in orthognathic surgery. *J Orthod Sci* 2015;4:9-12.
- Leelasinjaroen P, Godfrey K, Manosudprasit M, Wangsrimongkol T, Surakunprapha P, Pisek P. Surgery first orthognathic approach for skeletal Class III malocclusion corrections – A literature review. *J Med Assoc Thai* 2012;95 Suppl 11:S172-80.
- Jacobs JD, Sinclair PM. Principles of orthodontic mechanics in orthognathic surgery cases. *Am J Orthod* 1983;84:399-407.
- Jeong WS, Choi JW, Lee JY, Kwon SM. Can a surgery-first orthognathic approach reduce the total treatment time? *Int J Oral Maxillofacial Surg* 2017;46:473-82.
- Skaggs JE. Surgical correction of prognathism. *Am J Orthod* 1959;45:265-71.
- Behrman SJ, Behrman DA. Oral surgeons' considerations in surgical orthodontic treatment. *Dent Clin North Am* 1988;32:481-507.
- Brachvogel P, Berten JL, Hausamen JE. Surgery before orthodontic treatment: A concept for timing the combined therapy of skeletal dysgnathias. *Dtsch Zahn Mund Kieferheilkd Zentralbl* 1991;79:557-63.
- Nagasaka H, Sugawara J, Kawamura H, Nanda R. "Surgery first" skeletal Class III correction using the Skeletal Anchorage System. *J Clin Orthod* 2009;43:97-105.
- Mahmood HT, Ahmed M, Fida M, Kamal AT, Fatima F. Concepts, protocol, variations and current trends in surgery first orthognathic approach: A literature review. *Dental Press J Orthod* 2018;23:36.e1.
- Liou EJ, Chen PH, Wang YC, Yu CC, Huang CS, Chen YR. Surgery-first accelerated orthognathic surgery: Postoperative rapid orthodontic tooth movement. *J Oral Maxillofac Surg* 2011;69:781-5.
- Tavares CA, Sheffer MA, Allgayer S. Surgery first using skeletal anchorage with tandem mechanics for mandibular molar distalization. *Am J Orthod Dentofacial Orthop* 2018;153:118-30.
- Choi DS, Garagiola U, Kim SG. Current status of the surgery-first approach (Part I): Concepts and orthodontic protocols. *Maxillofac Plast Reconstr Surg* 2019;41:10.
- Baek SH, Ahn HW, Kwon YH, Choi JY. Surgery-first approach in skeletal Class III malocclusion treated with 2-jaw surgery: Evaluation of surgical movement and postoperative orthodontic treatment. *J Craniofac Surg* 2010;21:332-8.
- Sugawara J, Aymach Z, Yamada S, Nagasaka H, Kawamura H, Nanda R. Surgery first: The protocol of innovative surgical orthodontics. In: *Esthetics and Biomechanics in Orthodontics*. WB Saunders; 2015. p. 442-73.
- Liao YF, Lo SH. Surgical occlusion setup in correction of skeletal class iii deformity using surgery-first approach: Guidelines, characteristics and accuracy. *Sci Rep* 2018;8:11673.
- Pelo S, Saponaro G, Patini R, Staderini E, Giordano A, Gasparini G, *et al.* Risks in surgery-first orthognathic approach: Complications of segmental osteotomies of the jaws. A systematic review. *Eur Rev Med Pharmacol Sci* 2017;21:4-12.
- Hernández-Alfaro F, Guijarro-Martínez R, Molina-Coral A, Badía-Escriche C. "Surgery first" in bimaxillary orthognathic surgery. *J Oral Maxillofac Surg* 2011;69:201-7.
- Choi JW, Bradley JP. Surgery first orthognathic approach without presurgical orthodontic treatment: Questions and answers. *J Craniofac Surg* 2017;28:1330-3.
- Hyon WS. Surgery-First-Orthognathic-Approach (SFOA) to prognathism: Indications and limitations. *J Oral and Maxillofac Surg* 2008;66:39-40.
- Hernández-Alfaro F, Nieto MJ, Ruiz-Magaz V, Valls-Ontañón A, Méndez-Manjón I, Guijarro-Martínez R. Inferior subapical osteotomy for dentoalveolar decompensation of class III

- malocclusion in ‘surgery-first’ and ‘surgery-early’ orthognathic treatment. *Int J Oral Maxillofac Surg* 2017;46:80-5.
21. Watanabe Y, Sasaki R, Matsuno I, Akizuki T. Surgery-first orthognathic surgery for severe facial asymmetry combined with mandibular distraction osteogenesis using a three-dimensional internal distractor. *J Craniofac Surg* 2019;30:39-46.
 22. Liao YF, Chen YF, Yao CF, Chen YA, Chen YR. Long-term outcomes of bimaxillary surgery for treatment of asymmetric skeletal class III deformity using surgery-first approach. *Clin Oral Investig* 2019;23:1685-93.
 23. Liao YF, Chiu YT, Huang CS, Ko EW, Chen YR. Presurgical orthodontics versus no presurgical orthodontics: Treatment outcome of surgical-orthodontic correction for skeletal class III open bite. *Plast Reconstr Surg* 2010;126:2074-83.
 24. Oh JY, Park JW, Baek SH. Surgery-first approach in class III open-bite. *J Craniofac Surg* 2012;23:e283-7.
 25. Hasibe BK, Nisa GA, Alper A. Surgery-first orthognathic treatment of an adult patient with unilateral cleft lip-palate and multiple missing teeth: A case report. *S Eur J Orthod Dentofacial Res* 2019;6:19-24.
 26. López DF, Aristizábal JF, Martínez-Smit R. Condylectomy and “surgery first” approach: An expedited treatment for condylar hyperplasia in a patient with facial asymmetry. *Dental Press J Orthod* 2017;22:86-96.
 27. Badiali G, Costabile E, Lovero E, Pironi M, Rucci P, Marchetti C, *et al.* Virtual Orthodontic surgical planning to improve the accuracy of the surgery-first approach: A prospective evaluation. *J Oral Maxillofac Surg* 2019;77:2104-15.
 28. Sugawara J, Nagasaka H, Yamada S, Yokota S, Takahashi T, Nanda R, editors. The application of orthodontic miniplates to Sendai surgery first. *Semin Orthod* 2018;24:17-36.
 29. Kwon TG, Han MD. Current status of surgery first approach (part II): Precautions and complications. *Maxillofac Plast Reconstr Surg* 2019;41:23.
 30. Choi JW, Lee JY, Yang SJ, Koh KS. The reliability of a surgery-first orthognathic approach without presurgical orthodontic treatment for skeletal class III dentofacial deformity. *Ann Plast Surg* 2015;74:333-41.
 31. Yu CC, Chen PH, Liou EJ, Huang CS, Chen YR. A Surgery-first approach in surgical-orthodontic treatment of mandibular prognathism – A case report. *Chang Gung Med J* 2010;33:699-705.
 32. Villegas C, Uribe F, Sugawara J, Nanda R. Expedited correction of significant dentofacial asymmetry using a “surgery first” approach. *J Clin Orthod* 2010;44:97-103.
 33. Parker CD, Nanda RS, Currier GF. Skeletal and dental changes associated with the treatment of deep bite malocclusion. *Am J Orthod Dentofacial Orthop* 1995;107:382-93.
 34. Jeong WS, Lee JY, Choi JW. Large-scale study of long-term anteroposterior stability in a surgery-first orthognathic approach without presurgical orthodontic treatment. *J Craniofac Surg* 2017;28:2016-20.
 35. Hernández-Alfaro F, Guijarro-Martínez R, Peiró-Guijarro MA. Surgery first in orthognathic surgery: What have we learned? A comprehensive workflow based on 45 consecutive cases. *J Oral Maxillofac Surg* 2014;72:376-90.
 36. Kim JY, Jung HD, Kim SY, Park HS, Jung YS. Postoperative stability for surgery-first approach using intraoral vertical ramus osteotomy: 12 month follow-up. *Br J Oral Maxillofac Surg* 2014;52:539-44.
 37. Liou EJ, Chen PH, Wang YC, Yu CC, Huang CS, Chen YR. Surgery-first accelerated orthognathic surgery: Orthodontic guidelines and setup for model surgery. *J Oral Maxillofac Surg* 2011;69:771-80.
 38. Gandedkar NH, Chng CK, Tan W. Surgery-first orthognathic approach case series: Salient features and guidelines. *J Orthod Sci* 2016;5:35-42.
 39. Saghafi H, Benington P, Ayoub A. Impact of orthognathic surgery on quality of life: A comparison between orthodontics-first and surgery-first approaches. *Br J Oral Maxillofac Surg* 2020;58:341-7.
 40. Seifi M, Matini NS, Motabar AR, Motabar M. Dentoskeletal stability in conventional orthognathic surgery, presurgical orthodontic treatment and surgery-first approach in class-iii patients. *World J Plast Surg* 2018;7:283-93.