

A new laparoscopic triangle fixation technique for gastrostomy: a safe and effective procedure for reduction of the wound infection rate

Michimasa Fujiogi¹, Yujiro Tanaka², Hizuru Amano¹, Kyoichi Deie¹, Keisuke Suzuki¹, Hiroshi Kawashima¹, Naruhiko Murase², and Hiroo Uchida²

¹Department of Pediatric surgery, Saitama Children's Medical Center, Saitama, Japan

²Department of Pediatric surgery, Nagoya University Graduate School of Medicine, Nagoya, Japan

ABSTRACT

Gastrostomy is often performed with fundoplication in handicapped children. We devised a new laparoscopic triangle fixation technique for gastrostomy.

In this study, 100 patients underwent gastrostomy with fundoplication between January 2008 and January 2016. We retrospectively reviewed the early postoperative results between the new laparoscopic procedure (NLP) group (n = 63) and conventional procedure (CP) group (n = 37). In the CP, the gastrostomy tube was inserted with a purse-string ligature at the gastric wall, and the gastric wall was sutured to the peritoneum under a small laparotomy. In NLP, three sutures were placed on the gastric wall, forming the three sides of a triangle, and the tube was inserted into the center of the triangle. The ends of each suture were pulled directly through the abdominal wall using a laparoscopic percutaneous extraperitoneal closure needle to join the gastric wall and peritoneum. Both groups showed no significant differences in age, body weight, and external leakage rate. The wound infection rate was significantly lower in the NLP group. In conclusions, the NLP is straightforward and can achieve firm fixation between the stomach and abdominal wall by suturing in the form of a triangle. The NLP was associated with a lower complication rate, especially concerning infection.

Keywords: gastrostomy, laparoscopic fundoplication, surgical site infection, children, handicapped children

This is an Open Access article distributed under the Creative Commons Attribution-NonCommercial-NoDerivatives 4.0 International License. To view the details of this license, please visit (<http://creativecommons.org/licenses/by-nc-nd/4.0/>).

INTRODUCTION

In neurologically impaired children with gastroesophageal reflux disease, gastrostomy is often performed simultaneously with fundoplication.^{1,2)}

In our institution, the conventional procedure (CP) entailed suturing the stomach wall to the peritoneum around the gastrostomy tube under direct vision, which was achieved by extending the incision ventral to the gastric corpus to approximately 3 cm in length. Both ends of the

Received: November 2, 2017; accepted: May 2, 2018

Corresponding Author: Hiroo Uchida, MD, PhD

Department of Pediatric Surgery, Nagoya University Graduate School of Medicine, 65 Tsurumai, Showa, Nagoya 466-8550, Japan

Tel: +81-52-744-2959, E-mail: hiro2013@med.nagoya-u.ac.jp

extended wound were closed after tube insertion. However, infection and external leakage occasionally occurred, which sometimes led to wound dehiscence at the open site. Since 2011, we have devised a new laparoscopic procedure (NLP) for gastrostomy that does not require extending the incision to avoid these complications. Here, we describe the straightforward NLP and compare the complication rates between the two procedures.

PATIENTS AND METHODS

Methods

We retrospectively reviewed the medical records of all patients who underwent gastrostomy tube placement after laparoscopic fundoplication at our hospital. The study protocol was approved by the ethics committee of our hospital and conforms to the provisions of the Declaration of Helsinki.

Between January 2008 and January 2016, 100 gastrostomy tube placements with laparoscopic fundoplication were performed at our institution. A total of 37 pediatric patients were treated with the CP, and 63 pediatric patients were treated with the NLP. The ordinary port placement of laparoscopic fundoplication is shown in Fig. 1a. The operation is performed using 3 ports (circle) (ENDOPATH XCEL® Bladeless Trocar, 5 mm, Ethicon, USA) and 2 port-less forceps (triangle). A gastrostomy tube (Neofeed gastrostomy tube®, balloon type, 14 Fr, TOP Corporation, Tokyo, Japan) was inserted through the incision just ventral to the gastric corpus, which was also used as the route for grasping the stomach to facilitate visualization during fundoplication.

Surgical Techniques

Conventional Procedure (CP)

Between January 2008 and December 2010, all pediatric patients were treated with the CP. In these cases, the incision for gastrostomy was extended to approximately 3 cm (Fig. 1a, arrow), and the gastrostomy tube was inserted into the stomach under direct vision. After creating a purse-string ligature at the gastric wall to avoid leakage around the tube, the anterior wall surrounding the tube was sutured at the seromuscular layer to the peritoneum of the abdominal wall with three or four stitches under direct vision. The incision was then sealed with sutures, leaving the tube secured in the middle of the incision.

New Laparoscopic Procedure (NLP)

After January 2011, all pediatric patients in this study were treated with the NLP. Three 3-0 absorbable monofilament sutures were laparoscopically placed at the seromuscular layer of the gastric wall, forming the three sides of an equilateral triangle (Fig. 1b), and the gastrostomy tube was inserted in the center of the triangle. The ends of each suture were pulled directly through the abdominal wall using a laparoscopic percutaneous extraperitoneal closure (LPEC) needle (LAPA-HER-CLOSURE™, Hakko Medical, Nagano, Japan), attaching the gastric wall to the peritoneum as described in another study.³⁾ For each suture, the LPEC needle was percutaneously inserted at the same point, and different subcutaneous routes were used to secure each knot (Fig. 1c). The points where the sutures were pulled out from formed an equilateral triangle with the incision in the center (Fig. 1d).

An electrocautery needle was inserted in the incision under laparoscopic supervision, in order to penetrate the gastric wall. The cranial suture was then pulled up toward the abdominal wall, and the caudal gastric wall was secured with two forceps (left and right), forcing the anterior gastric wall into a tense plane, in order to avoid puncturing the posterior wall (Fig.

1e). After inserting the gastrostomy tube and inflating the balloon, 50–100 mL of air was injected into the stomach, to ensure the tube was correctly placed. At this point, the three

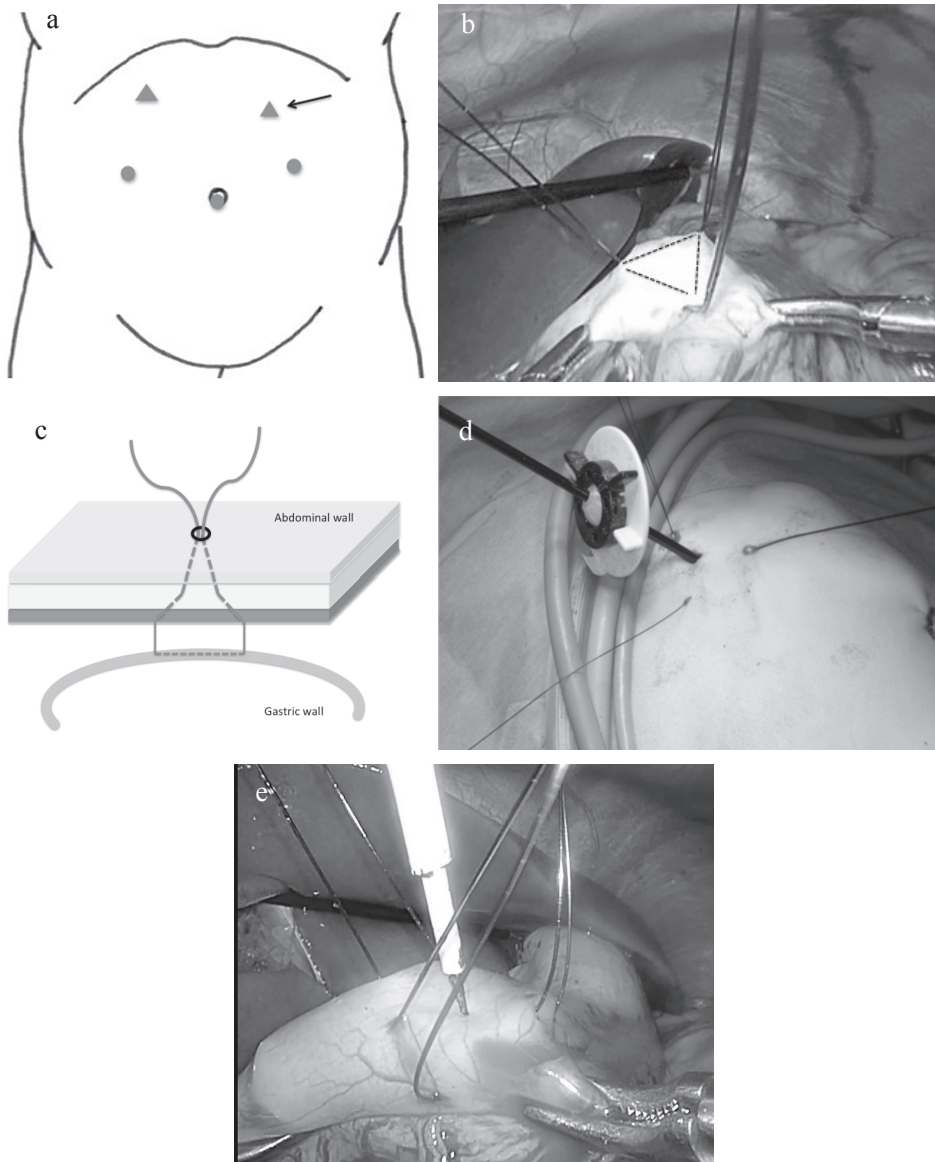


Fig. 1 A new laparoscopic triangle fixation technique for gastrostomy

Fig. 1a: Typical port positions used in laparoscopic fundoplication. The working or camera port (5-mm port, circle), port-less forceps hole (1–2 mm, triangle), and insertion site of the gastrostomy tube (arrow) have been indicated.

Fig. 1b, e: A new laparoscopic procedure in gastrostomy tube insertion when performed with laparoscopic fundoplication. Three sutures form the sides of an equilateral triangle.

Fig. 1c, d: The laparoscopic percutaneous extraperitoneal closure (LPEC) needle is percutaneously inserted from the same point, taking different routes subcutaneously to catch the ends of the suture so that the tied knot is under the skin after ligation.

Table 1 Comparison of patient characteristics and surgical complications in gastrostomy between our new laparoscopic procedure and the conventional procedure

	NLP (n = 63)	CP (n = 37)	P-value
Male/female	36/27	26/11	0.20
Median age at operation, (month) (range)	56 (3–394)	66 (5–250)	0.81
Median weight at operation, (kg) (range)	12.2 (3.8–42)	11.7 (5.1–38)	0.85
	n	n	
Infection	0	4	0.01
External leakage	3	5	0.14
External leakage that required closing the gastrostomy	2	0	0.52
Wound dehiscence	0	3	0.14
Total	5	12	0.002

New laparoscopic procedure (NLP) group, January 2011 to January 2016; conventional procedure (CP) group, January 2008 to December 2010.

Fisher's exact test, chi-square (χ^2) test, and Mann-Whitney's U test were used to compare clinical data between the two groups.

stitches were tied extracorporeally, with the secured knot remaining subcutaneously. No purse-string ligature was made around the tube.

Statistics

Fisher's exact test, chi-square test, and Mann-Whitney's U test were used to compare the clinical data between the CP and NLP groups. P-values < 0.05 were considered statistically significant.

RESULTS

Patients' demographic data and surgical complications on gastrostomy are shown in Table 1. The age and body weight of the NLP group were not significantly different from those of the CP group (P = 0.81 and 0.85, respectively). Incidental intraperitoneal malposition of the gastrostomy tube was not found in both the groups. The incidence of leakage around the gastrostomy tube was not significantly different between the CP and NLP groups. Wound dehiscence was more frequent in the CP (n = 3) than in the NLP group (n = 0), although without significance. In contrast, the infection rate was significantly lower in the NLP group compared to that in the CP group (n = 0 vs. n = 4; P = 0.01). The total complication rate was also significantly lower in the NLP group compared to that in the CP group (n = 5 vs. n = 12; P = 0.002), supporting that the NLP would be a better procedure in gastrostomy with fundoplication.

DISCUSSION

In our country, a transnasal feeding tube is the primary device used to treat pediatric patients with neurological impairment or failure to thrive. Although the transnasal tube is a simple and

effective method of tube feeding, constant irritation to the throat, the possibility of accidental dislodgement, and occasional difficulty in insertion count as distinct disadvantages associated with its use. In such cases, a gastrostomy may be preferred. Therefore, a gastrostomy is usually performed in neurologically impaired children in whom fundoplication is necessary.

Multiple techniques have been reported in performing a gastrostomy.⁴⁻¹³⁾ Historically, the predominant approach was an open gastrostomy, commonly performed using the Stamm technique, which involves suturing the anterior stomach to the abdominal wall to secure the gastrostomy tract.⁴⁾ We had been using this technique during the CP. Although relatively simple and easy to perform, the open Stamm gastrostomy has been associated with a notable incidence of complications including wound infections, bleeding, and skin erosions with leakage around the tube. A previous study reported that approximately 13% of patients developed wound infection and 5–20% developed leakage around the gastrostomy site.^{5,14)} Our study also showed a significantly higher rate of wound infection in this group compared to that in the NLP group.

A Stamm gastrostomy was modified to a laparoscopic Stamm gastrostomy.¹⁵⁾ This technique showed good outcomes associated with purse-string suturing and fixation of the stomach to the abdominal wall using the needle loop, without extending the port incision. Although this technique was feasible, we consider it a slightly complicated procedure. However, the study describing the modified Stamm gastrostomy was limited by a small sample size (N = 16) and reported findings of a single surgeon. It is necessary to perform further research using a larger sample size.

Presently, percutaneous endoscopic gastrostomy is a standard gastrostomy technique utilized in both adult and pediatric patients.^{16,17)} However, percutaneous endoscopic gastrostomy is associated with serious complications including the risk of injury to other organs, bleeding, and dislodgement, among other adverse events.¹⁸⁻²¹⁾ An author has suggested laparoscopic-assisted percutaneous endoscopic gastrostomy as a technique that can reduce the risk of organ damage.¹⁰⁾ However, this technique is not commonly performed concomitant with fundoplication because an endoscope and clinician who operates the endoscope are necessary during the operation using this technique. Furthermore, this technique requires inflation of the stomach, which might increase the risk of contamination within the abdominal cavity. It is therefore not ideal to perform a gastrostomy concomitant with fundoplication because non-absorbable sutures are used for wrap formation, and artificial materials (e.g., Gore-Tex) are often used for reinforcement in patients with a fragile esophageal hiatus.²²⁾ Moreover, insertion of the endoscope is associated with an inherent risk of complications including mucosal bleeding, esophageal perforation, and dental injury particularly in neurologically impaired children who are often undernourished.

Fixation of the stomach to the abdominal wall (gastropexy) has been described as a method to achieve a safe gastrostomy.^{23,24)} Gastropexy prevents dislodgement of the tube and peritonitis in the event of accidental removal of the gastrostomy tube before maturation of the gastrostomy tract.²⁵⁾ The representative laparoscopic gastrostomy technique performed with gastropexy is the Georgeson's U-stitch technique.¹³⁾ The laparoscopic U-stitch technique has gained popularity because it is a relatively simple technique and has shown favorable outcomes.¹¹⁾ However, after the U-stitches are removed to prevent site erosion on the second or third postoperative day, there exists a 1.5% (confidence interval, 0.4–2.6%) risk of intraperitoneal displacement of the tube secondary to dislodgement.¹¹⁾ In Japan, the Funada-style gastropexy is popular. Percutaneous endoscopic gastrostomy with a Funada technique was modified to a laparoscopic-assisted method.²⁶⁾ It is similar to the U-stitch technique, except in the layers of the gastric wall sewn (seromuscular layer using the U-stitch technique vs. all layers using the Funada technique). Thus, the Funada technique is associated with a higher risk of tube dislodgement following suture removal. Another known method is laparoscopic gastrostomy using the T-fastener technique.²⁷⁾ However, metallic anchors remain within the gastrointestinal tract, and there exists a potential

risk of pneumoperitoneum from an eroded T-fastener;²⁸⁾ therefore, this technique might not be suitable in pediatric patients with thin gastric walls.

The use of two sutures might be associated with the risk of a loose and weak fixation in the gastric and abdominal walls. Additionally, dislodgement following removal of sutures is a known concern. Thus, in agreement with a previous study,²⁹⁾ we used three sutures in the form of a triangle to achieve a more secure fixation around the gastrostomy tube and decided to maintain the knot subcutaneously to avoid suture removal. Although placing these sutures through a small incision is complicated, placing them laparoscopically is relatively easy such as with the use of the U-stitch or Funada technique. Following a firm fixation of the gastric and abdominal walls, placing a purse-string ligature around the gastrostomy tube becomes unnecessary. A previous study that reported a similar technique²⁹⁾ has described that this technique showed a higher success rate in reducing the incidence of re-operation after dislodgement of the tube than that with percutaneous endoscopic gastrostomy.

Neurologically impaired children are usually undernourished and show a high intra-abdominal pressure secondary to hypermyotonia, which increases their risk of infection and leakage around their gastrostomy tubes. Nonetheless, the infection rate was significantly lower in the NLP than in the CP group in this study. Additionally, although not significant, external leakage and wound dehiscence occurred less commonly in the NLP group. These findings suggest the superiority of the NLP in severely neurologically impaired children.

Although long-term results are not yet available, our NLP may be an attractive alternative laparoscopic gastrostomy technique, particularly useful when performing concomitant laparoscopic fundoplication. Lately, our laparoscopic method is being used in gastrostomy without fundoplication. Using a single incision and curved forceps, a multi-port laparoscopic procedure can be performed as reduced-port laparoscopic surgery.

In conclusion, we report a NLP in gastrostomy concomitant with fundoplication. Our NLP can achieve stable and firm fixation between the gastric and abdominal walls using sutures placed in the form of a triangle without an additional incision. Our laparoscopic method in gastrostomy is a simple technique and demonstrated a lower complication rate.

CONFLICTS OF INTERST

The authors declare no conflicts of interest.

REFERENCES

- 1) Iwanaka T, Kanamori Y, Sugiyama M, Komura M, Tanaka Y, Kodaka T, *et al.* Laparoscopic fundoplication for gastroesophageal reflux disease in infants and children. *Surg Today*, 2010; 40: 393–397.
- 2) Mizuno M, Kobayashi M, Sasaki A, Nakajima J, Wakabayashi G. Early experience with single-incision laparoscopic Nissen fundoplication for gastroesophageal reflux disease in patients with mental retardation via a gastrostomy site incision: Report of five cases. *Surg Today*, 2012; 42: 601–604.
- 3) Deie K, Uchida H, Kawashima H, Tanaka Y, Amano H, Murase N *et al.* Operative procedures of single-incision laparoscopic repair of pediatric epigastric hernia have become simple and feasible with the use of a novel suture-assisting needle. *J Ped Surg Case Reports*, 2016; 4: 22–26.
- 4) Kazmierski M, Jordan A, Saeed A, Aslam A. The benefits and management of gastrostomy in children. *Paediatr Child Heal (United Kingdom)*, 2013; 23: 351–355.
- 5) Sulkowski JP, De Roo AC, Nielsen J, Ambeba E, Cooper JN, Hogan MJ, *et al.* A comparison of pediatric gastrostomy tube placement techniques. *Pediatr Surg Int*, 2016; 32: 269–275.
- 6) Nah SA, Narayanaswamy B, Eaton S, Coppi P De, Kiely EM, Curry JI, *et al.* Gastrostomy insertion in children: percutaneous endoscopic or percutaneous image-guided? *J Pediatr Surg*, 2010; 45: 1153–1158.

New laparoscopic technique for gastrostomy

- 7) Tomicic JT, Luks FI, Shalon L, Tracy TF. Laparoscopic gastrostomy in infants and children. *Eur J Pediatr Surg*, 2002; 12: 107–110.
- 8) Karpelowsky J, Numanoglu A, Rode H. Single-port laparoscopic gastrostomy. *Eur J Pediatr Surg*, 2008; 18: 285–286.
- 9) Gauderer MW, Ponsky JL, Izant RJJ. Gastrostomy without laparotomy: a percutaneous endoscopic technique. *J Pediatr Surg*, 1980; 15: 872–875.
- 10) Perger L, Watch L, Weinsheimer R, Fahl J, Azzie G. Laparoscopically supervised PEG at time of Nissen fundoplication: a safe option. *J Laparoendosc Adv Surg Tech A*, 2008; 18: 136–9.
- 11) Aprahamian CJ, Morgan TL, Harmon CM, Georgeson KE, Barnhart DC. U-Stitch laparoscopic gastrostomy technique has a low rate of complications and allows primary button placement: experience with 461 pediatric procedures. *J Laparoendosc Adv Surg Tech*, 2006; 16: 643–649.
- 12) Sampson LK, Georgeson KE, Winters DC. Laparoscopic gastrostomy as an adjunctive procedure to laparoscopic fundoplication in children. *Surg Endosc*, 1996; 10: 1106–1110.
- 13) Georgeson KE. Laparoscopic fundoplication and gastrostomy. *Semin Laparosc Surg*, 1998; 5: 25–30.
- 14) Grant JP. Comparison of percutaneous endoscopic gastrostomy with Stamm gastrostomy. *Ann Surg*, 1988; 207: 598–603.
- 15) Kaya M, Sancar S, Ozcakir E. A new method for laparoscopic Stamm gastrostomy. *J Laparoendosc Adv Surg Tech*, 2018; 28: 111–115.
- 16) Gauderer MWL. Percutaneous endoscopic gastrostomy - 20 Years later: A historical perspective. *J Pediatr Surg*, 2001; 36: 217–219.
- 17) Rahnemai-Azar AA, Rahnemai-Azar AA, Naghshizadian R, Kurtz A, Farkas DT. Percutaneous endoscopic gastrostomy: Indications, technique, complications and management. *World J Gastroenterol*, 2014; 20: 7739–7751.
- 18) Lantz M, Hultin Larsson H, Arnbjörnsson E. Literature review comparing laparoscopic and percutaneous endoscopic gastrostomies in a pediatric population. *Int J Pediatr*, 2010; 2010: 507616.
- 19) Larson DE, Burton DD, Schroeder KW, DiMugno EP. Percutaneous endoscopic gastrostomy: Indications, success, complications, and mortality in 314 consecutive patients. *Gastroenterology*, 1987; 93: 48–52.
- 20) Merli L, De Marco EA, Fedele C, Mason EJ, Taddei A, Paradiso F V, *et al.* Gastrostomy placement in children: percutaneous endoscopic gastrostomy or laparoscopic gastrostomy? *Surg Laparosc Endosc Percutan Tech*, 2016; 26: 381–384.
- 21) Suksamanapun N, Mauritz FA, Franken J, van der Zee DC, van Herwaarden-Lindeboom MY. Laparoscopic versus percutaneous endoscopic gastrostomy placement in children: results of a systematic review and meta-analysis. *J Minim Access Surg*, 2017; 13: 81–88.
- 22) Amano H, Tanaka Y, Kawashima H, Deie K, Suzuki K, Fujiogi M, *et al.* Mesh hiatal reinforcement in laparoscopic Nissen fundoplication for neurologically impaired children is safe and feasible. *Nagoya J Med Sci*, 2017; 79: 427 – 433.
- 23) Dormann a J, Glosemeyer R, Leistner U, Deppe H, Roggel R, Wigglinghaus B, *et al.* Modified percutaneous endoscopic gastrostomy (PEG) with gastropexy--early experience with a new introducer technique. *Z Gastroenterol*, 2000; 38: 933–938.
- 24) Hashiba K. Endoscopic gastrostomy. *Endoscopy*, 1987; 19 Suppl 1: 23–24.
- 25) Okumura N, Tsuji N, Ozaki N, Matsumoto N, Takaba T, Kawasaki M, *et al.* Percutaneous endoscopic gastrostomy with Funada-style gastropexy greatly reduces the risk of peristomal infection. *Gastroenterol Rep*, 2015; 3: 69–74.
- 26) Takahashi T, Miyano G, Shiyonagi S, Lane GJ, Yamataka A. Laparoscopy-assisted percutaneous endoscopic gastrostomy using a “Funada-kit II” device. *Pediatr Surg Int*, 2012; 28: 925–929.
- 27) Duh QY, Way LW. Laparoscopic jejunostomy using t-fasteners as retractors and anchors. *Arch Surg*, 1993; 128: 105–108.
- 28) Ho T, Margulies D. Pneumoperitoneum from an eroded T-fastener. *Surg Endosc*, 1999, 13: 285–286.
- 29) Villalona GA, Mckee MA, Diefenbach KA. Modified laparoscopic gastrostomy technique reduces gastrostomy tract dehiscence. *J Laparoendosc Adv Surg Tech*, 2011; 21: 355–359.