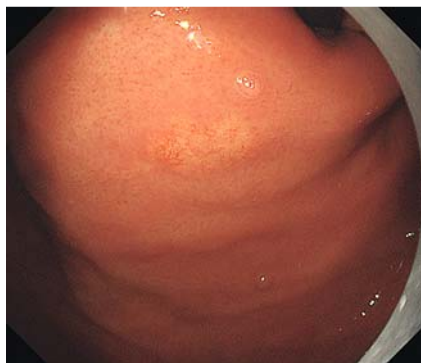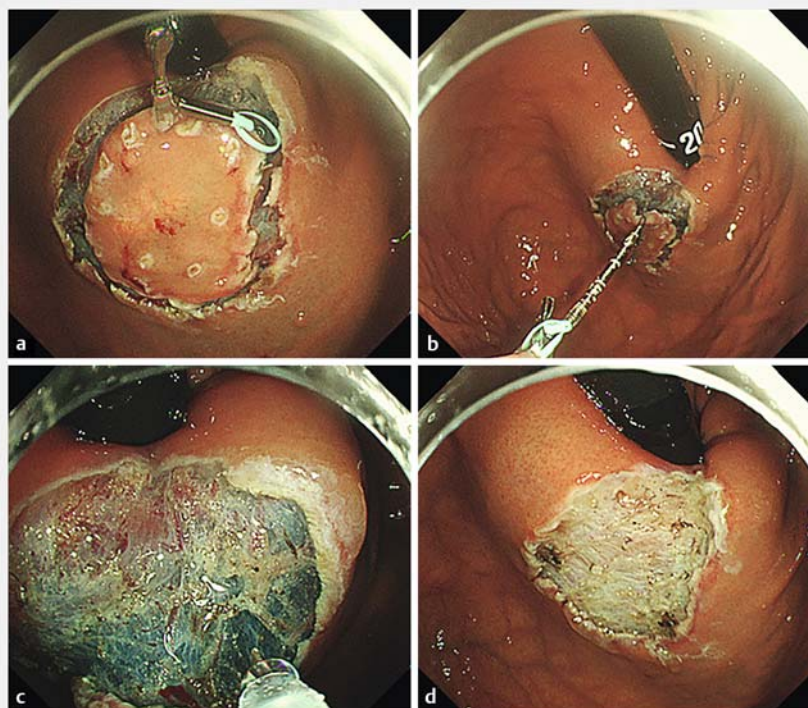


Modified attachment method using S-O clip and multibending scope for gastric ESD at the greater curvature of the fundus



► **Fig. 1** White light images of early gastric cancer (gastric adenocarcinoma of fundic-gland type). A 0-IIa lesion was located at the greater curvature of the fundus near the cardia. Pathological diagnosis: U, 0-IIa, 9x6 mm, gastric adenocarcinoma of fundic-gland type, pT1b/SM2 (600 µm), ULO, Ly0, V0, HM0, VM0.



► **Fig. 2** Traction ESD with an S-O clip. a After circumferential mucosal incision, an S-O clip was applied to the edge of the oral side of the lesion. b The S-O clip was anchored on the opposite side at the greater curvature in the upper third of the stomach. c Good visualization of the submucosa and adequate traction were obtained. d Complete en bloc resection was achieved without any complications.

Introduction


Endoscopic submucosal dissection (ESD) is an established treatment for gastric neoplasms. However, gastric ESD at the greater curvature of the fundus near the cardia is a challenging procedure because of its technical difficulties [1]. Here, we report the usefulness of a modified attachment method using an S-O clip (ZEON Medical, Japan) [2–4] and multibending scope (M-scope, GIF-2T240M; Olympus, Japan) for ESD at this location.

Video

A 58-year-old man underwent ESD for a 10-mm type 0-IIa tumor (gastric adenocarcinoma of fundic-gland type) at the greater curvature of the fundus near the cardia (► **Fig. 1**). A conventional endoscope could not reach this lesion with good operability for ESD. We selected the M-scope to reach this lesion and improve the operability for ESD.

After the lesion was separated from the peripheral mucosa circumferentially using a dual knife (KD-650L, Olympus) and IT knife2 (KD-611L, Olympus), the anchor site was marked with the dual knife. An S-O clip was attached to the edge of the oral side of this lesion (► **Fig. 2a**) and the S-O clip was anchored on the opposite side at the greater curvature in the upper third of the stomach to place the spring extension in the appropriate direction (► **Fig. 2b**). Good visualization of the submucosa and adequate traction were obtained with extension of the spring (► **Fig. 2c**). Even with respirator movement and technical difficulties, resection was performed safely

with the dual knife in 25 minutes with no complications (► **Video 1**, ► **Fig. 2d**). Although natural traction can be obtained in this location to flap up the specimen, it is difficult to manipulate the entry to create the flap because the traction force gets weaker during the first half of the ESD procedure and the endoscope faces the lesion vertically. This problem was overcome with combined use of an S-O clip and M-scope to obtain good visualization of the submucosa and good operability for ESD and it was as easy as using dental floss for clip traction [5]. Therefore, this method may contribute to making the ESD procedure technically less complicated without compro-

 VIDEO


► **Video 1** showing the usefulness of the modified attachment method using an S-O clip and M-scope for gastric ESD at the greater curvature of the fundus near the cardia.

mising safety, especially during flap creation. We believe that this newly developed procedure is useful for not only beginners but also specialists.

Competing interests

The authors declare that they have no conflict of interest.

The authors

Hiroya Ueyama¹, Takashi Murakami¹, Kenshi Matsumoto¹, Naoto Sakamoto¹, Taro Osada¹, Takashi Yao², Akihito Nagahara¹

- 1 Department of Gastroenterology, Juntendo University, School of Medicine, Tokyo, Japan
- 2 Department of Human Pathology, Juntendo University Graduate School of Medicine, Tokyo, Japan

Corresponding author

Hiroya Ueyama, MD, PhD

Department of Gastroenterology, Juntendo University School of Medicine, 2-1-1 Hongo, Bunkyo-Ku, Tokyo 113-8421, Japan
 Fax: +81-3-3813-8862
 psyro@juntendo.ac.jp

References

- [1] Yano T, Hasuie N, Ono H et al. Factors associated with technical difficulty of endoscopic submucosal dissection for early gastric cancer that met the expanded indication criteria: post hoc analysis of a multi-institutional prospective confirmatory trial (JCOG0607). *Gastric Cancer* 2020; 23: 168–174
- [2] Sakamoto N, Osada T, Shibuya T et al. The facilitation of a new traction device (S-O clip) assisting endoscopic submucosal dissection for superficial colorectal neoplasms. *Endoscopy* 2008; 40: E94–E95
- [3] Nagata M. Modified attachment method using S-O clip for gastric endoscopic submucosal dissection. *VideoGIE* 2019; 4: 151–153
- [4] Hashimoto R, Hirasawa D, Iwaki T et al. Usefulness of the S–O clip for gastric endoscopic submucosal dissection (with video). *Surg Endosc* 2018; 32: 908–914
- [5] Yoshida M, Takizawa K, Suzuki S et al. Conventional versus traction-assisted endoscopic submucosal dissection for gastric neoplasms: a multicenter, randomized controlled trial (with video). *Gastrointest Endosc* 2018; 87: 1231–1240

Bibliography

Endoscopy International Open 2021; 09: E195–E196

DOI 10.1055/a-1315-0293

ISSN 2364-3722

© 2021. The Author(s).

This is an open access article published by Thieme under the terms of the Creative Commons Attribution-NonCommercial License, permitting copying and reproduction so long as the original work is given appropriate credit. Contents may not be used for commercial purposes, or adapted, remixed, transformed or built upon. (<https://creativecommons.org/licenses/by-nc-nd/4.0/>)

Georg Thieme Verlag KG, Rüdigerstraße 14, 70469 Stuttgart, Germany

