

# Treatment of acute myeloid leukemia with active pulmonary tuberculosis with venetoclax-based anti-acute myeloid leukemia regimen combined with an intensive and then individualized anti-tuberculosis regimen: A report of two cases

LIN JI, WEI YANG, LIU JIE GAO, BEI YUAN ZHANG, YA QING XU\* and XIAO FENG XU\*

Department of Oncology and Hematology, Hangzhou Red Cross Hospital, Hangzhou, Zhejiang 310003, P.R. China

Received October 12, 2023; Accepted June 11, 2024

DOI: 10.3892/ol.2024.14734

**Abstract.** Patients with concurrent acute myeloid leukemia (AML) and active pulmonary tuberculosis (TB) exhibit certain characteristics; cough, phlegm, fever, hemoptysis, weight loss and dyspnea are common symptoms of both diseases. These patients often cannot tolerate traditional intensive chemotherapy regimens, and finding the optimal timing in the treatment of both AML and active pulmonary TB is complex. Neglecting timely treatment can lead to serious complications and even fatal outcomes. The present paper reports two cases of patients with AML who were diagnosed with active pulmonary TB. The patients received intensive anti-TB treatment with isoniazid, rifampicin, pyrazinamide and ethambutol for 10-15 days. After three consecutive negative sputum smears, the patients in cases 1 and 2 were treated with a venetoclax, homoharringtonine and cytarabine regimen; and a venetoclax and azacitidine regimen for anti-AML therapy, respectively, as well as individualized anti-TB regimens of isoniazid, pyrazinamide, ethambutol and quinolone. Subsequently, both patients achieved complete remission of AML and their active TB was well controlled.

## Introduction

In 2022, there were 10.6 million new cases of tuberculosis (TB) worldwide, with 1.3 million deaths globally due to TB, and the number of newly-diagnosed patients with TB in China

was 748,000 in 2022 (1). Acute myeloid leukemia (AML) is a frequently fatal bone marrow stem cell cancer characterized by unbridled proliferation of malignant marrow stem cells with associated infection, anemia and bleeding (2). The basic treatment strategy for newly diagnosed AML remains intensive therapy based on combination chemotherapy, inducing a complete remission (CR) with initial therapy, followed by consolidation therapy after remission (3). For older adults with AML considered appropriate for antileukemic therapy but not for intensive antileukemic therapy, the ASH guideline panel suggests using either of the options when choosing between hypomethylating-agent monotherapy and low-dose-cytarabine monotherapy (4). Chemotherapy typically results in bone marrow suppression, prolonged neutropenia and a decrease in immune function in patients (5). Additionally, due to the weakened immune system in patients with AML, these patients are more susceptible to acquiring new infections and the reactivation of latent infections, including TB (6,7). Treating AML complicated by active pulmonary TB poses significant challenges for clinicians. Although TB is highly prevalent in developing countries, its common symptoms such as fever and lymphadenopathy may also occur in patients with AML, leading to delayed diagnosis in these patients with atypical clinical presentations (7). In terms of treatment, patients with AML and active TB may face multiple issues such as cumulative toxicity from various medications, drug interactions and an inability to tolerate traditional intensive chemotherapy regimens (8). Finding the optimal timing for treatment of both AML and TB is complex. Our previous study reports the case of a patient with AML and active pulmonary TB who, in early 2022, was treated with a venetoclax, homoharringtonine (HHT) and azacitidine regimen, and achieved CR whilst achieving excellent control of the active pulmonary TB (9). The present study reports the diagnosis and treatment process of two patients with AML, which demonstrated that following a combination of a venetoclax-based anti-AML regimen combined with an intensive and then individualized anti-TB regimen, CR was achieved as well as good control of active TB. A balance was observed in the treatment of these patients, effectively treating acute myeloid leukemia, while safely controlling active pulmonary tuberculosis, thus making it a safer treatment option.

---

*Correspondence to:* Mrs. Ya Qing Xu or Dr Xiao Feng Xu, Department of Oncology and Hematology, Hangzhou Red Cross Hospital, 208 Huancheng East Road, Hangzhou, Zhejiang 310003, P.R. China  
E-mail: 875971251@qq.com  
E-mail: hhxuxiaofeng@126.com

\*Contributed equally

**Key words:** acute myeloid leukemia, active pulmonary tuberculosis, venetoclax

## Case report

**Case 1.** A 33-year-old female patient was diagnosed with AML-M5b (8) in March 2022 at The First Affiliated Hospital of Medical School of Zhejiang University (Hangzhou, China). Next-generation sequencing (NGS) (10) indicated AML1-ETO-positive and mutated *fms*-like tyrosine kinase 3 (FLT3)-internal tandem duplication (ITD; 2.56%). The DNA was extracted using the QIAGEN QIAseq FX DNA Library Kit (cat. no. 180479; Qiagen GmbH). The samples were analyzed using the Agilent 2100 Bioanalyzer (Agilent Technologies, Inc.) to assess the integrity of the DNA and to determine the concentration of the sample. DNA quality scores were used to ensure the sample quality. The sequencing kits used included the NovaSeq 6000 S4 Reagent Kit v1.5 (300 cycles; cat. no. 20028312; Illumina, Inc.), NovaSeq 6000 S2 Reagent Kit v1.5 (300 cycles; cat. no. 20028314; Illumina, Inc.), NovaSeq 6000 S1 Reagent Kit v1.5 (300 cycles; cat. no. 20028317; Illumina, Inc.) and NovaSeq 6000 SP Reagent Kit v1.5 (300 cycles; cat. no. 20028400; Illumina, Inc.). Paired-end sequencing with a nucleotide length of 150x2 bp was performed. Both strands were sequenced (forward and reverse). The concentration was determined using the NadPrep<sup>®</sup> Hybrid Capture Reagents kit [1005101; Nanoda (Nanjing) Biotechnology Co., Ltd.]. The target regions in the library were captured with a custom blood cancer panel. High-fidelity DNA polymerase (KK2621; Kapa Biosystems; Roche Diagnostics) was used to perform PCR amplification of the target regions. The amplification conditions were as follows: 98°C for 45 sec, 98°C for 15 sec, 65°C for 30 sec and 72°C for 30 sec with 8 cycles. After the last reaction cycle, the PCR reaction was further extended at 72°C for 1 min and then cooled to 10°C. The Applied Biosystems 7500 Fast Real-Time PCR System (Thermo Fisher Scientific, Inc.) was used for detection. The loading concentration of the final library was  $\geq 10$  ng/ $\mu$ l. The software used for data analysis included Burrows-Wheeler Aligner (0.7.10; <https://sourceforge.net/projects/bio-bwa/files/>), Sequence Alignment/Map (1.9; Wellcome Sanger Institute) and Genome Analysis Toolkit (3.5; Broad Institute). Lung computed tomography (CT) revealed inflammation in the upper lobe of the left lung and multiple nodules in both lungs, some of which were ground-glass nodules (data not shown). The patient commenced chemotherapy with oral venetoclax (100 mg on day 1, 200 mg on day 2 and 300 mg on days 3-10), intravenous HHT (3 mg on days 1-5), intravenous aclarubicin (17 mg on days 1-5) and subcutaneous cytarabine (70 mg on days 1-5; VHAA) for 10 days, followed by an 18-day rest (1 cycle), along with oral isoniazid (300 mg) and rifampicin (450 mg) for TB prophylaxis. After two cycles of the VHAA regimen, bone marrow cytomorphology examination (Wright-Giemsa composite stain at 25°C for 15 min; light microscope) results indicated that the proportions of mature and immature monocytes were 4 and 1%, respectively (data not shown). Lung CT revealed scattered ground-glass nodules in both lungs, with an increasing number of new-onset nodules (data not shown). Furthermore, the T cells spot test of TB infection (11) was positive for TB infection and *Mycobacterium tuberculosis* was detected in the sputum culture. The complete blood cell count showed a white blood cell count of  $32.3 \times 10^9/l$  (normal reference values,  $3.5-9.5 \times 10^9/l$ ), hemoglobin levels of

65 g/l (normal reference values, 120-170 g/l) and a platelet count of  $102 \times 10^9/l$  (normal reference values,  $100-300 \times 10^9/l$ ). After being transferred to Hangzhou Red Cross Hospital (Hangzhou, China) in April 2022, the patient underwent a chest CT scan, which revealed scattered ground-glass nodules in both lungs, with increasing new-onset nodules (Fig. 1A), and was treated with intensive anti-TB therapy with oral isoniazid (300 mg), rifampicin (450 mg), pyrazinamide (1.25 g) and ethambutol (750 mg) (HRZE). After 10 days, acid-fast bacillus (AFB) was not detected in the sputum. The patient was then treated with oral venetoclax (100 mg on day 1, 200 mg on day 2 and 300 mg on days 3-10), intravenous HHT (3 mg on days 1-5) and subcutaneous cytarabine (70 mg q12 h, on days 1-5; V + HA) for 10 days, followed by an 18-day rest (1 cycle). The anti-TB regimen was changed to oral isoniazid (300 mg), pyrazinamide (1.25 g), ethambutol (750 mg) (HZE) with levofloxacin (500 mg). In May 2022, a lung CT suggested absorption of the lung lesions (Fig. 1B). The patient continued to receive the V + HA for antileukemia regimen and eventually achieved CR. The patient underwent hematopoietic stem cell transplant (HSCT) after achieving CR and received oral levofloxacin (500 mg) for anti-TB therapy for 1 year. The patient is followed up in the outpatient clinic every 2 weeks for a routine blood test. Additionally, a routine bone marrow cytomorphology examination is repeated once every quarter. As of July 2024, the patient was in good condition with no recurrence.

**Case 2.** In April 2023, a 57-year-old male patient was diagnosed with active TB at a local hospital (Yiwu Central Hospital, Yiwu, Jinhua, China), and *Mycobacterium tuberculosis* was detected in the sputum culture. After undergoing anti-TB therapy with oral ethambutol hydrochloride, pyrazinamide, rifampicin and isoniazid tablet II (8 tablets per day), the complete blood cell count revealed a white blood cell count of  $4.45 \times 10^9/l$  (normal reference values,  $3.5-9.5 \times 10^9/l$ ), hemoglobin levels of 108 g/l (normal reference values, 120-170 g/l) and a platelet count of  $76 \times 10^9/l$  (normal reference values,  $100-300 \times 10^9/l$ ). Manual classification (12) revealed that 13% of cells were primitive. The patient was transferred to the Department of Oncology and Hematology (Hangzhou Red Cross Hospital, Hangzhou, China) in April 2023 for TB, and lung CT indicated TB in the upper lobes of both lungs (Fig. 1C). The patient was treated with regular intensive anti-TB therapy using the oral isoniazid (300 mg), rifampicin (600 mg), pyrazinamide (1.0 g) and ethambutol (750 mg) (HRZE) regimen. Furthermore, the patient was diagnosed with AML-M2a (8). NGS (10) indicated double mutation of CCAAT enhancer binding protein  $\alpha$  and isocitrate dehydrogenase (IDH)2. Regular anti-TB therapy with the HRZE regimen was administered for 15 days, and no AFB was detected in any of the three sputum smears. Subsequently, the anti-TB regimen was changed to oral isoniazid (300 mg), pyrazinamide (1.0 g), ethambutol (750 mg) (HZE) and moxifloxacin (400 mg), along with antileukemia therapy that included oral venetoclax (100 mg on day 1, 200 mg on day 2 and 300 mg on days 3-21) and subcutaneous azacitidine (100 mg on days 1-7; VA) for 21 days, followed by a 7-day rest (1 cycle). The bone marrow test after one cycle of treatment suggested primitive granulocytes of 1.0 and promyelocytes of 1.0. Flow cytometry of bone marrow (13) aspirates

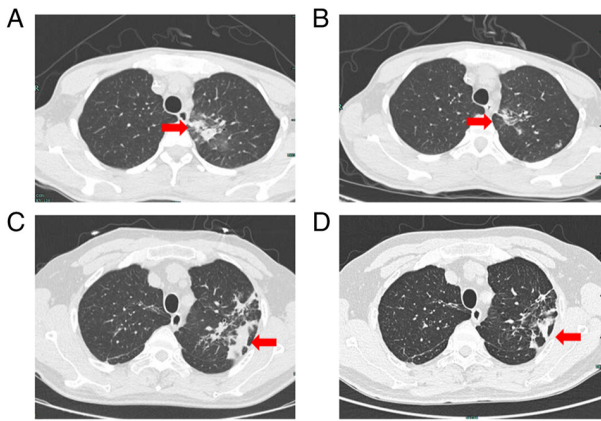


Figure 1. Chest CT in case 1 and case 2. (A) As indicated by the red arrow, in April 2022, lung CT revealed scattered ground-glass nodules in both lungs, with increasing new-onset nodules, in case 1. (B) As indicated by the red arrow, in May 2022, lung CT demonstrated absorption of lung lesions in case 1. (C) As indicated by the red arrow, in April 2023, lung CT indicated TB in the upper lobes of both lungs in case 2. (D) As indicated by the red arrow, in August 2023, lung CT indicated TB in the upper lobes of both lungs with a certain degree of absorption compared with the condition at the time of admission in case 2. CT, computed tomography; TB, tuberculosis.

revealed no abnormal cells (Fig. S1). The marrow sample was mixed with EDTA anticoagulant and the following antibodies were added for incubation in a dark environment at room temperature for 15 min: CD10-mFlour450 (cat. no. S010MF14; Caprico Biotechnologies), CD117-allophycocyanin (APC)-A750 (cat. no. A80249; Beckman Coulter, Inc.), CD11b-APC (cat. no. 652819; BD Biosciences), CD11c-PC7 (cat. no. B36300; Beckman Coulter, Inc.), CD123-phycoerythrin (PE) (cat. no. 649453; BD Biosciences), CD13-PC7 (cat. no. 338425; BD Biosciences), CD13-PE (cat. no. 347406; BD Biosciences), CD14-PC5 (cat. no. A70204; Beckman Coulter, Inc.), CD15-FITC (cat. no. 340703; BD Biosciences), CD16-mFlour450 (cat. no. IM0814U; Beckman Coulter, Inc.), CD19-PC7 (cat. no. 348804; BD Biosciences), CD20-APC-A750 (cat. no. 641396; BD Biosciences), CD22-APC (cat. no. 340932; BD Biosciences), CD33-PC5.5 (cat. no. A70198; Beckman Coulter, Inc.), CD34-APC (cat. no. IM2472U; Beckman Coulter, Inc.), CD36-FITC (cat. no. B49201; Beckman Coulter, Inc.), CD38-PC5 (cat. no. A70205; Beckman Coulter, Inc.), CD3-APC (cat. no. Z6410048; Beijing Quantobio Biotechnology Co., Ltd.), CD45-mFluor540 (cat. no. 340942; BD Biosciences), CD4-APC-A750 (cat. no. 340672; BD Biosciences), CD56-PC5.5 (cat. no. B49189; Beckman Coulter, Inc.), CD5-PC7 (cat. no. 348790; BD Biosciences), CD64-APC-A750 (cat. no. B96769; Beckman Coulter, Inc.), CD7-PE (cat. no. 340656; BD Biosciences), CD8-FITC (cat. no. S008FI04; Caprico Biotechnologies), HLA-DR-mFlour450 (cat. no. Z6410082; Beijing Quantobio Biotechnology Co., Ltd.), kappa-FITC (cat. no. 643774; BD Biosciences) and lambda-PE (cat. no. 642924; BD Biosciences). Lysis buffer (2,000  $\mu$ l) was added to each tube, followed by incubation at room temperature for 10-15 min and centrifugation at 160 x g for 5 min at room temperature. The supernatant was discarded and PBS (1,000  $\mu$ l) was added, followed by centrifugation at 160 x g for 5 min at room temperature. The washing procedure was repeated once more. After discarding the supernatant

again, the cells were resuspended with an appropriate volume of PBS (500-2,000  $\mu$ l) based on the cell concentration. Specimens were examined using flow cytometry (BD FACS Canto II; BD Biosciences) after mixing. The detected data were analyzed using Kaluza software (version no. A82959; Beckman Coulter, Inc.). A CR without significant infection due to agranulosis was achieved after clinical evaluation. The patient was on the fourth cycle of the VA regimen whilst continuing the anti-TB therapy, and the blood concentration of venetoclax fluctuated between 1,270 and 4,580 ng/ml. The results of the bone marrow test and flow cytometry (13) were normal (Fig. S2), and no significant agranulosis was observed. Lung CT indicated TB in the upper lobes of both lungs, with a certain degree of absorption compared with the condition at the time of admission (Fig. 1D). The patient continued the anti-TB therapy with HZE and moxifloxacin for 1 year and the patient is being treated with the VA regimen. The patient continues to be hospitalized every 28 days for examination and treatment until such time as the disease recurs or the current treatment regimen becomes intolerable. As of July 2024, the patient was in good condition.

## Discussion

Due to the uniqueness of *Mycobacterium tuberculosis*, balancing the timing of treatment for AML and active TB is a great challenge for clinicians. A previous study reported 15 patients with active TB at the time of initial AML diagnosis in whom the first induction chemotherapy lasted for 2 months (14). TB was controlled and leukemia went into remission in 13 patients, but the other 2 patients did not achieve remission and subsequently died. However, the aforementioned study included few cases and, to the best of our knowledge, there are no large-scale studies or guidelines for clinical work guidance. When diagnosing pulmonary TB, clinicians should carefully collect medical history, understand whether there is a history of contact with pulmonary TB, and perform detailed physical examinations, chest imaging, tuberculin skin tests and laboratory tests (15). It is not appropriate to consider only TB recurrence when the patient has been diagnosed with pulmonary TB in the past and when the number of lung lesions increases, as patients with AML can have one or many concomitant pulmonary concomitant diseases (16-19). However, when diagnosing pulmonary TB, it is necessary to differentiate it from other lung diseases, such as lung cancer, chronic pulmonary aspergillosis (CPA) and pulmonary leukemic infiltration (PLI). Clinical symptoms serve a crucial role in the differential diagnosis between TB and lung cancer. For instance, cough, phlegm, fever, hemoptysis, weight loss and dyspnea are common symptoms of both diseases; however, sudden weight loss, hemoptysis and a history of smoking are more common in lung cancer. Nevertheless, the diagnosis of TB and lung cancer still requires comprehensive analysis through pathological and microbiological tests (16). Additionally, pulmonary CT has good application value in distinguishing between TB and lung cancer alone (17). The clinical manifestations of CPA, such as weight loss, fatigue, fever, chronic coughing, chest discomfort and occasional hemoptysis, are similar to those of most patients with TB. The diagnosis of TB and CPA infection still requires a comprehensive analysis combining etiological

examination and radiographic examination (18). PLI is most commonly manifested as nodules or masses, but interstitial abnormalities, such as thickening of bronchovascular bundles, are also seen. Clinical confirmation requires radiographic examination and lesion biopsy (19,20). However, a previous study (19) suggests that PLI often occurs in the terminal stage. In the 2 cases in the present study, the platelet counts of the patients were low, making percutaneous biopsy impractical. However, after anti-TB treatment, the pulmonary lesions in the 2 patients were notably reduced in size. Moreover, sputum cultures for AFB were positive with conversion to negative. Therefore, we hypothesize that the pulmonary infection in the patients was active TB.

A total of four drugs are usually used simultaneously during the intensive phase of anti-TB therapy. This is due to the stronger synergistic bactericidal effect that is capable of killing a larger number of reproducing *Mycobacterium tuberculosis* in <2 weeks, thereby triggering a significant decline in its virulence (21). In the 2 cases in the present study, venetoclax-based antileukemia regimens combined with individualized anti-TB regimens were commenced after 10-15 days of intensive anti-TB therapy with the HRZE regimen and three negative sputum cultures. Eventually, the AML went into remission, and the active TB was well-controlled without any significant adverse effects. Therefore, the venetoclax-based antileukemia regimens combined with individualized anti-TB therapy that were administered to the 2 patients after a short period of intensive anti-TB therapy, were practically feasible.

Patients with concurrent AML and active pulmonary TB cannot tolerate traditional intensive therapy (8). Therefore, physicians must consider choosing the best combination therapy. AML cells are dependent on Bcl-2 for survival, and the inhibitory effect of venetoclax can induce the endogenous apoptotic pathway, leading to rapid apoptosis of AML cells and eradication of leukemic stem cells in the stationary phase (22,23). Azacitidine increases the sensitivity of AML cells to T cells, making them more susceptible to T cell-mediated cytotoxicity (24). The VA regimen achieves improved therapeutic effects and is the standard treatment for newly diagnosed patients with AML who are unsuited for intensified chemotherapy (8). Additionally, the VA regimen can overcome certain high-risk genes such as FLT3-ITD and IDH1/2, but has poor efficacy for certain genes such as FLT3-tyrosine kinase domain (TKD) (25,26). The patient in case 2, who did not have a FLT3 mutation, received the VA regimen and achieved CR with just one course. Our previous report described a case in which the patient was diagnosed with AML-M5b, accompanied by mutations in DNA methyltransferase 3 $\alpha$ , FLT3-TKD and IDH2, as well as active pulmonary tuberculosis (9). The response to the VA regimen of the patient was evaluated as no response. A study has shown that HHT can inhibit the anti-apoptotic proteins myeloid cell leukemia 1 and Bcl-xL and synergistically exerts anti-AML effects with venetoclax (27). Li *et al* (28) elucidated the high sensitivity of FLT3-mutated AML to HHT treatment. The patient in our previous report was then administered HHT in addition to the VA regimen, forming the VA+H regimen, which resulted in a CR, followed by a HSCT (9). Zhou *et al* (29) reported that the overall response rate (CR + partial response) of the venetoclax combined with HHT, cytarabine and aclacinomycin (VHAA)

regimen was 97.5% and the CR rate was 95.0% (29); however, the VHAA regimen is associated with severe bone marrow suppression, and the common adverse reactions are infections and fever (29). A recent study by Liu *et al* (30) reported that the CR rate of venetoclax combined with HHT and cytarabine (V + HA) was as high as 97.9% in elderly or intensive chemotherapy ineligible patients with newly diagnosed AML. The patient in case 1 received the VHAA regimen followed by the V + HA regimen, achieved CR, and underwent HSCT. Therefore, after achieving CR with a venetoclax-based anti-AML regimen, high-risk patients are recommended to undergo HSCT as soon as possible. Low-risk patients can be treated with venetoclax-based regimen. After stable TB control is achieved at 6 months, patients can be treated with a standard anti-AML regimen; however, further studies are required to confirm this finding.

The individual differences in blood venetoclax concentration are large, and blood venetoclax concentration is associated with the objective response rate and safety events (31). Therefore, venetoclax-based antileukemia regimens were selected in the present cases to detect the changes in blood concentrations over time. Previous studies have also demonstrated that small-dose, short-course venetoclax-based combination regimens achieve better remission with few adverse effects and are well tolerated by patients (32-34). In the present study, both patients were treated with a small dose of short-course venetoclax, and achieved CR. Intensive anti-TB therapy, HRZE, was chosen to be used to promptly kill a large number of reproducing and active susceptible bacteria in a short period. Rifampicin was then replaced with a quinolone, which is also capable of killing both intracellular and extracellular bacteria (35), to compose an individualized anti-TB regimen of HZE and quinolone to prevent rifampicin, a strong inducer of cytochrome P450 3A4 enzymes, from affecting the concentration of venetoclax. Both patients with AML achieved good control of active TB and CR for AML.

In addition, another study demonstrated that *Mycobacterium tuberculosis* increases the expression of Bcl-2 at the transcriptional level (36). Based on the aforementioned study, we hypothesized that venetoclax, as a Bcl-2 inhibitor, may reduce the expression of *Mycobacterium tuberculosis*-induced Bcl-2, which may affect TB stability in patients with active pulmonary TB. This provides a direction for future research and clinical trials and is expected to bring new breakthroughs in the treatment of concurrent active pulmonary TB and AML.

How to treat AML combined with active TB is currently a clinical issue that doctors and patients face together and urgently need to solve, and the treatment plan for patients with TB and AML is constantly being explored. A total of 4 other patients with the same diagnoses after November 2023 were treated and achieved good treatment results (Ji *et al*, unpublished data). Future studies should build on these efforts and carry out scientific research based on clinical problems, so as to provide more patients with effective treatment and explore the possibility of a breakthrough in the combined fields of TB and AML.

In summary, AML combined with active TB has unique characteristics, and its clinical diagnosis and treatment are challenging. For patients with AML combined with active



TB, a venetoclax-based anti-AML regimen combined with an intensive and then individualized anti-TB regimen is efficacious with few side effects. More cases should be collected to further clarify its efficacy and safety and promote its application, thereby improving the overall survival of patients with concurrent AML and active pulmonary TB.

### Acknowledgements

Not applicable.

### Funding

The present study was supported by the Research Fund of Hangzhou Municipal Health and Health Commission (grant no. A20210210).

### Availability of data and materials

The next-generation sequencing data generated in the present study may be found in the Sequencing Read Archive under accession number PRJNA1118206 or at the following URL: <https://www.ncbi.nlm.nih.gov/bioproject/PRJNA1118206>. All other data generated in the present study may be requested from the corresponding author.

### Authors' contributions

XFX designed the chemotherapy plans. YQX was responsible for tuberculosis management and nursing. WY, LJG and BYZ were responsible for the clinical diagnosis and treatment of the patients. LJ mainly collected the data for the manuscript, drafted the manuscript, and revised key intellectual content. XFX and LJ are responsible for the manuscript, ensuring that issues related to the integrity of any part of the work were appropriately investigated and resolved, and confirm the authenticity of all the raw data. All authors have read and approved the final manuscript.

### Ethics approval and consent to participate

The publication of the present case reports was approved by the Ethics Committee of Hangzhou Red Cross Hospital [Hangzhou, China; approval no. 118(2023)].

### Patient consent for publication

Written informed consent for publication of the article, including clinical data and images, was obtained from the patients.

### Competing interests

The authors declare that they have no competing interests.

### References

- World Health Organization (WHO): Global Tuberculosis report. WHO, Geneva, 2023. [http://www.who.int/tb/publications/global\\_report/en/](http://www.who.int/tb/publications/global_report/en/). Accessed November 7, 2023.
- Shimony S, Stahl M and Stone RM: Acute myeloid leukemia: 2023 update on diagnosis, risk-stratification, and management. *Am J Hematol* 98: 502-526, 2023.
- Döhner H, Wei AH, Appelbaum FR, Craddock C, DiNardo CD, Dombret H, Ebert BL, Fenaux P, Godley LA, Hasserjian RP, *et al*: Diagnosis and management of AML in adults: 2022 recommendations from an international expert panel on behalf of the ELN. *Blood* 140: 1345-1377, 2022.
- Sekeres MA, Guyatt G, Abel G, Alibhai S, Altman JK, Buckstein R, Choe H, Desai P, Erba H, Hourigan CS, *et al*: American Society of Hematology 2020 guidelines for treating newly diagnosed acute myeloid leukemia in older adults. *Blood Adv* 4: 3528-3549, 2020.
- Kantarjian H: Acute myeloid leukemia-major progress over four decades and glimpses into the future. *Am J Hematol* 91: 131-145, 2016.
- Malone JL, Ijaz K, Lambert L, Rosencrans L, Phillips L, Tomlinson V, Arbise M, Moolenaar RL, Dworkin MS and Simoes EJ: Investigation of healthcare-associated transmission of Mycobacterium tuberculosis among patients with malignancies at three hospitals and at a residential facility. *Cancer* 101: 2713-2721, 2004.
- Jain A, Prakash G, Singh C, Lad D, Khadwal A, Suri V, Malhotra P, Kumari S, Varma N and Varma S: Analysis of clinical profile and outcome of tuberculosis in patients with acute leukemia. *Indian J Hematol Blood Transfus* 34: 430-442, 2018.
- Leukemia & Lymphoma Group, Chinese Society of Hematology and Chinese Medical Association: Chinese guidelines for diagnosis and treatment of adult acute myeloid leukemia (not APL) (2023). *Zhonghua Xue Ye Xue Za Zhi* 44: 705-712, 2023 (In Chinese).
- Ji L, Yang W, Xu XF and Xu YQ: A case report of complete remission of acute myeloid leukemia combined with DNMT3A, FLT3-TKD, and IDH2 gene mutations and active pulmonary tuberculosis treated with homeharringtonine + venetoclax + azacytidine. *Front Med (Lausanne)* 10: 1180757, 2023.
- Hematology Oncology Committee of China Anti-Cancer Association; Chinese Society of Hematology Chinese Medical Association; Chinese Society of Pathology Chinese Medical Association: Expert consensus on the application of next-generation sequencing in hematological neoplasms (2018). *Zhonghua Xue Ye Xue Za Zhi* 39: 881-886, 2018 (In Chinese).
- Sun Y, Yao X, Ni Y, Peng Y and Shi G: Diagnostic Efficacy of T-SPOT.TB for active tuberculosis in adult: A retrospective study. *Infect Drug Resist* 15: 7077-7093, 2022.
- Experimental Diagnosis Group, Hematology Society Chinese Medical Association: Consensus of Chinese experts on morphologic analysis of blood cells. *Zhonghua Xue Ye Xue Za Zhi* 34: 558-560, 2013 (In Chinese).
- Chinese Society of Immunology, Clinical Flow Cytometry Group: Expert consensus on minimal residual disease detection of acute leukemia and plasma cell neoplasms by multi-parameter flow cytometry. *Zhonghua Xue Ye Xue Za Zhi* 38: 1001-1011, 2017 (In Chinese).
- Li J and Niu T: Clinical research progress of hematological malignancies complicated with active tuberculosis. *Zhonghua Xue Ye Xue Za Zhi* 34: 1076-1079, 2013 (In Chinese).
- World Health Organization (WHO): WHO operational handbook on tuberculosis. Module 2: Screening-Systematic screening for tuberculosis disease. WHO, Geneva, 2021.
- Sheikhpour M, Mirbahari SN, Sadr M, Maleki M, Arabi M, and Abolfathi H: A comprehensive study on the correlation of treatment, diagnosis and epidemiology of tuberculosis and lung cancer. *Tanaffos* 22: 7-18, 2023.
- Sun W, Zhang L, Liang J, Li X, Yang Y, Sun W, and Hou J: Comparison of clinical and imaging features between pulmonary tuberculosis complicated with lung cancer and simple pulmonary tuberculosis: A systematic review and meta-analysis. *Epidemiol Infect* 150: e43, 2022.
- Mei ZX, Han JF, Yu HW, Zhang Y, Ji P, Xie Y, and Hsueh PR: Detection of serum Aspergillus-specific IgM and IgG antibody levels for the diagnosis of chronic pulmonary aspergillosis developed in patients with tuberculosis. *Eur J Clin Microbiol Infect Dis* 42: 1081-1089, 2023
- Gosangi B, Hatabu H, and Hammer MM: Imaging features of pulmonary leukemic infiltration with comparison of lymphoid and myeloid leukemias. *Curr Probl Diagn Radiol* 50: 164-167, 2021.

20. Yoshifuji K, Toya T, Yanagawa N, Sakai F, Nagata A, Sekiya N, Ohashi K and Doki N: CT classification of acute myeloid leukemia with pulmonary infiltration. *Jpn J Radiol* 39: 1049-1058, 2021.
21. Dickinson JM, Aber VR and Mitchison DA: Bactericidal activity of streptomycin, isoniazid, rifampin, ethambutol, and pyrazinamide alone and in combination against *Mycobacterium tuberculosis*. *Am Rev Respir Dis* 116: 627-635, 1977.
22. Zhang Y and Jin J: Application of Bcl-2 inhibitor venetoclax in acute myeloid leukemia. *Zhonghua Xue Ye Xue Za Zhi* 42: 438-440, 2021 (In Chinese).
23. DiNardo CD, Jonas BA, Pullarkat V, Thirman MJ, Garcia JS, Wei AH, Konopleva M, Döhner H, Letai A, Fenaux P, *et al*: Azacitidine and Venetoclax in Previously Untreated Acute Myeloid Leukemia. *N Engl J Med* 383: 617-629, 2020.
24. Lee JB, Khan DH, Hurren R, Xu M, Na Y, Kang H, Mirali S, Wang X, Gronda M, Jitkova Y, *et al*: Venetoclax enhances T cell-mediated antileukemic activity by increasing ROS production. *Blood* 138: 234-245, 2021.
25. Bouligny IM, Murray G, Doyel M, Patel T, Boron J, Tran V, Gor J, Hang Y, Alnimer Y, Zacholski K, *et al*: Venetoclax with decitabine or azacitidine in the first-line treatment of acute myeloid leukemia. *EJHaem* 4: 381-392, 2023.
26. De Leeuw DC, Ossenkoppele GJ and Janssen JJWM: Older patients with acute myeloid leukemia deserve individualized treatment. *Curr Oncol Rep* 24: 1387-1400, 2022.
27. Yuan F, Li D, Li G, Cheng C and Wei X: Synergistic efficacy of homoharringtonine and venetoclax on acute myeloid leukemia cells and the underlying mechanisms. *Ann Transl Med* 10: 490, 2022.
28. Li C, Dong L, Su R, Bi Y, Qing Y, Deng X, Zhou Y, Hu C, Yu M, Huang H, *et al*: Homoharringtonine exhibits potent anti-tumor effect and modulates DNA epigenome in acute myeloid leukemia by targeting SP1/TET1/5hmC. *Haematologica* 105: 148-160, 2020.
29. Zhou Z, Zhao X, Suo X, Bai G, Shi Z, Luo Y, Tan Y, Lu X, Yuan L, Zhang C, *et al*: Venetoclax combined with homoharringtonine, cytarabine, and aclacinomycin (HAAV) as induction therapy in newly diagnosed young adult acute myeloid leukemia. *Blood* 142 (Supplement 1): S1517, 2023.
30. Liu K, Suo X, Bai G, Yan Z, Li Y, Zhang B, He J, Li J, Wei S, Li Q, *et al*: Venetoclax combined with homoharringtonine and cytarabine (HAV) as induction treatment in elder or intensive chemotherapy (IC) ineligible patients with newly diagnosed acute myeloid leukemia. *Blood* 142 (Supplement 1): S4272, 2023.
31. Li K, Zhao W, Liu Y, Gao X, Zhou F, Chen Q, Chang Y and Wang W: The value of venetoclax blood concentration monitoring in the treatment of acute myeloid leukemia and the efficacy and safety of combined azacitidine in the treatment of acute myeloid leukemia. *J Clin Hematol* 35: 812-816, 2022 (In Chinese).
32. Jin H, Zhang Y, Yu S, Du X, Xu N, Shao R, Lin D, Chen Y, Xiao J, Sun Z, *et al*: Venetoclax combined with azacitidine and homoharringtonine in relapsed/refractory AML: A multicenter, Phase 2 trial. *J Hematol Oncol* 16: 42, 2023.
33. Mirgh S, Sharma A, Shaikh MRMA, Kadian K, Agrawal N, Khushoo V, Mehta P, Ahmed R and Bhurani D: Hypomethylating agents+venetoclax induction therapy in acute myeloid leukemia unfit for intensive chemotherapy-novel avenues for lesser venetoclax duration and patients with baseline infections from a developing country. *Am J Blood Res* 11: 290-302, 2021.
34. Vachhani P, Flahavan EM, Xu T, Ma E, Montez M, Gershon A, Onishi M, Jin H, Ku G, Flores B, *et al*: Venetoclax and hypomethylating agents as first-line treatment in newly diagnosed patients with AML in a predominately community setting in the US. *Oncologist* 27: 907-918, 2022.
35. Millanao AR, Mora AY, Villagra NA, Bucarey SA and Hidalgo AA: Biological Effects of Quinolones: A family of broad-spectrum antimicrobial agents. *Molecules* 26: 7153, 2021.
36. Ramon-Luing LA, Olvera Y, Flores-Gonzalez J, Palacios Y, Carranza C, Aguilar-Duran Y, Vargas MA, Gutierrez N, Medina-Quero K and Chavez-Galan L: Diverse cell death mechanisms are simultaneously activated in macrophages infected by virulent *Mycobacterium tuberculosis*. *Pathogens* 11: 492, 2022.



Copyright © 2024 Ji *et al.* This work is licensed under a Creative Commons Attribution-NonCommercial-NoDerivatives 4.0 International (CC BY-NC-ND 4.0) License.