

# Safety and Efficacy of Polymeric Clips for Appendiceal Stump Closure

Caroline E. Reinke, MD, Lawrence E. Tabone, MD, Philip Fong, MD, Jin S. Yoo, MD, Chan W. Park, MD

## ABSTRACT

**Background and Objectives:** Laparoscopic appendectomy remains one of the most common emergency general surgical procedures in the United States. In an era of increasing focus on costs in medical care, we sought to evaluate the use of polymeric clips to secure the appendiceal base during laparoscopic appendectomy.

**Methods:** We performed a prospective cohort study of patients undergoing laparoscopic appendectomy from April 2013 through September 2014 at a single academic teaching institution. Polymeric clips were used to secure the appendiceal stump. Tissue dissection techniques and control of the mesoappendix were the operating surgeon's choice. Clinical outcomes are reported.

**Results:** A total of 25 patients (56% women; mean age, 41 y; body mass index of 29 kg/m<sup>2</sup>) were enrolled in our study and underwent laparoscopic appendectomy with polymeric clips. One patient was unable to have polymeric clips placed due to inflammation of the appendiceal base. There were no major perioperative complications. One patient developed a suture abscess in the umbilical incision, and another had prolonged ileus with computed tomography demonstrating persistent pelvic fluid that did not require intervention. Median length of stay was 1 d and mean length of follow-up was 81 d. The use of polymeric clips contributed ~ \$32 to the overall operative cost.

**Conclusions:** Polymeric clips are a safe alternative for securing the appendiceal base in laparoscopic appendec-

tomy. They offer significant cost savings without any evidence of increased complications.

**Key Words:** Cost, Laparoscopic appendectomy, Polymeric clips, Safety, Value.

## INTRODUCTION

Appendectomy for acute appendicitis is one of the most common emergency general surgery procedures performed in the United States.<sup>1</sup> While novel nonoperative treatments for acute appendicitis are emerging,<sup>2,3</sup> the mainstay of treatment for nonperforated appendicitis remains laparoscopic removal of the appendix.

In the current healthcare environment, the cost of medical care is under constant scrutiny. Methods to maximize the value of care delivered are being explored. Identifying methods to achieve the same outcomes at lower cost are one important way to increase value. The choice of instruments used for any given surgical procedure has traditionally been left to the discretion of each individual surgeon, within the confines of what instruments are available at that particular hospital. The ability to reduce costs in laparoscopic appendectomy has been demonstrated by standardizing instrument trays.<sup>4</sup> Introducing less expensive instruments for achieving the same outcomes is another method of reducing costs. The current literature most commonly describes using either a suture ligation device or an endoscopic stapler to transect the appendix.

Our institution was interested in the use of polymeric clips for securing the appendiceal base, which has been reported in the literature outside of the United States.<sup>5-9</sup> Polymeric clips are currently in use for numerous procedures, but have not been reported in the United States for use during appendectomy.

The purpose of this study was to examine the outcomes of appendectomy performed with polymeric clips. We hypothesized that the use of polymeric clips for ligation of the appendiceal stump would be feasible and would not lead to significant perioperative complications.

Duke University Health System, Durham, North Carolina (Drs Reinke, Fong, Yoo, and Park).

West Virginia University, Morgantown, West Virginia (Dr Tabone).

Disclosures: Dr. Reinke is a consultant for Medtronic/Covidien, Minneapolis, Minnesota, and Teleflex, Wayne, Pennsylvania. Dr. Tabone is a consultant for Teleflex. Dr. Fong has nothing to disclose. Dr. Yoo is a consultant for Medtronic/Covidien; Teleflex; Gore, Flagstaff, Arizona; and Novadaq, Bonita Springs, Florida. Dr. Park is a consultant for Medtronic/Covidien, Teleflex, Gore, and TransEnterix.

Address correspondence to: Caroline E. Reinke, MD, Duke University Health System, 407 Crutchfield St., Durham, NC 27704. E-mail: caroline.coor@gmail.com

DOI: 10.4293/JSLS.2016.00045

© 2016 by JSLS, *Journal of the Society of Laparoendoscopic Surgeons*. Published by the Society of Laparoendoscopic Surgeons, Inc.

## MATERIALS AND METHODS

In this prospective study, we examined a cohort of patients who underwent laparoscopic appendectomy with polymeric clips (Hem-o-lok, Weck Polymer Locking Ligation System, Teleflex, Research Triangle Park, North Carolina, USA). This study was registered with the National Institutes of Health (<https://clinicaltrials.gov/ct2/show/NCT01830387>). The trial included patients 18 years old or older who were scheduled for laparoscopic appendectomy for a diagnosis of appendicitis. The diagnosis of appendicitis was made by the consulting surgeon after review of the patient's history and imaging. All patients in this study had undergone computer-assisted tomography (CT) before surgical consultation.

Patients with a diagnosis of appendicitis and who were scheduled for a laparoscopic appendectomy were approached by a member of the research team and were prospectively asked to consent to participate in the study. Patients were excluded if they were less than 18 years of age, had signs of appendiceal rupture or abscess on preoperative CT, or were unable to provide informed consent.

Three surgeons experienced in minimally invasive techniques who routinely perform a variety of laparoscopic general surgery procedures performed all of the appendectomy procedures and were occasionally assisted by surgical trainees with various experience levels (residents and fellows). Standard 3-port laparoscopic appendectomy techniques were used, and all appendiceal bases were ligated with polymeric clips. A clip applicator placed through a 10-mm port was used to apply the X-Large clips. Two clips were left on the appendiceal stump, and a third clip was applied toward the specimen side of the appendix before sharp scissor division of the appendix. Tissue dissection and mesoappendix ligation techniques were left up to the discretion of the surgeon; bipolar vessel-sealing technology and monopolar electrocautery dissection were the methods most commonly used. The exposed appendiceal stump mucosa was fulgurated with electrocautery (**Figure 1**).

Our primary outcome of interest was the incidence of major surgical complications: appendiceal stump dehiscence, abscess, and hemorrhage. Our secondary outcomes of interest were other complications (pneumonia, urinary tract infection, myocardial infarction, pulmonary embolism, deep vein thrombosis, and death) and length of stay (LOS). Data on patient, operative, and hospitalization characteristics and on postoperative follow-up were gathered from review of medical records. LOS was determined by chart review and was calculated from the date of surgical consult or date of admission until the date of discharge.

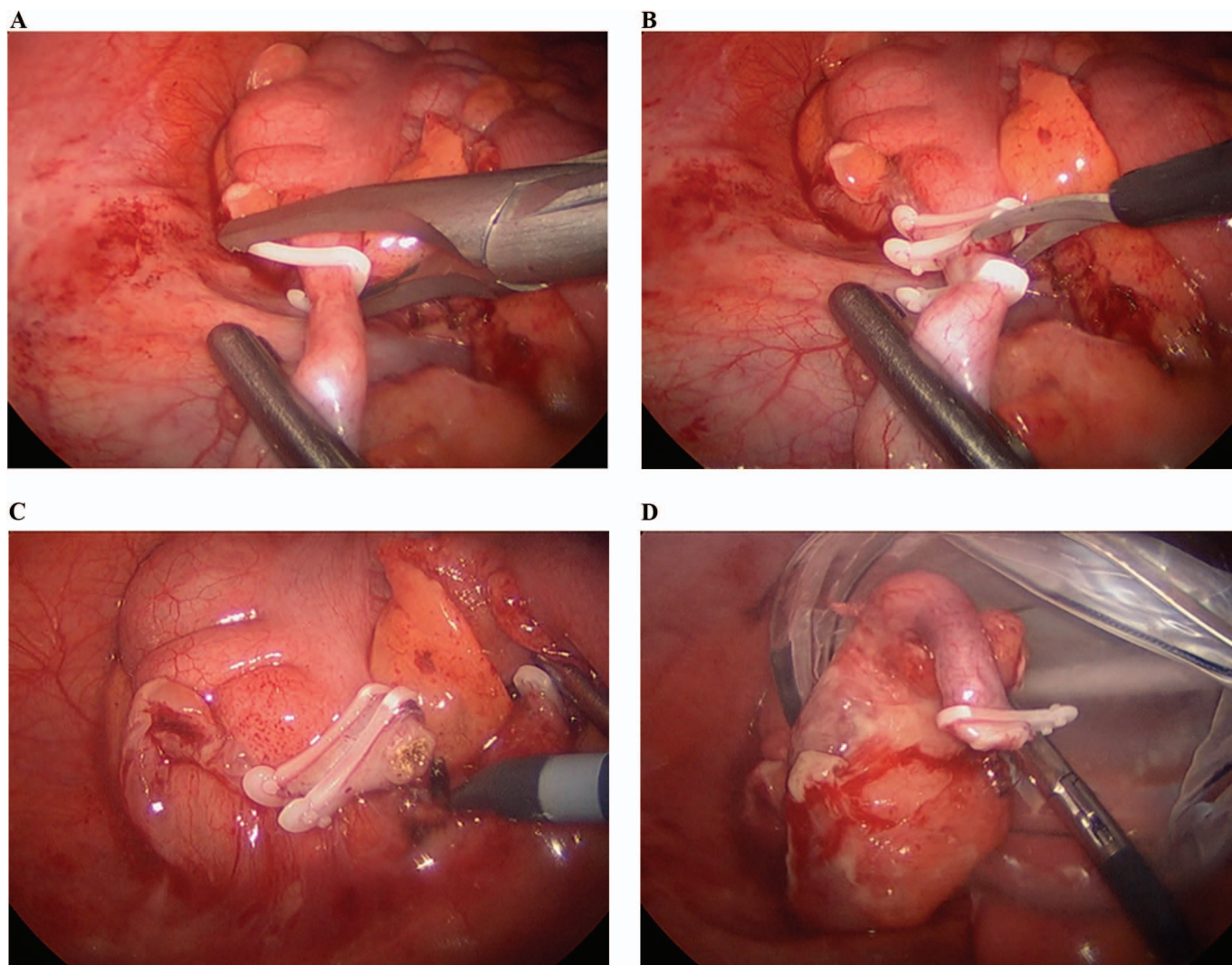
Patient characteristics included sex, age, white blood cell (WBC) count before the operation, preoperative imaging, smoking history, body mass index (BMI, kg/m<sup>2</sup>), American Society of Anesthesiologists (ASA) Physical Status classification, and final pathology. Operative characteristics included stump closure technique, intraoperative complications, estimated blood loss (EBL), and other concurrent procedures. Hospital characteristics included total LOS, postoperative LOS, and outpatient antibiotic regimen. Follow-up characteristics included time to follow-up in surgical clinic, total length of follow-up time in our healthcare system (in any clinic), and all postoperative complications (presenting either during hospitalization or after discharge).

This study was approved by the Institutional Review Board of Duke University. All analyses were performed using STATA (StataCorp, College Station, Texas, USA).

## RESULTS

A total of 26 patients were enrolled in our study, and 25 underwent laparoscopic appendectomy with polymeric clips. One patient was unable to have the clips placed because of inflammation of the appendiceal base. The maximum diameter of tissue that can be ligated by the XL (largest size) clip is 16 mm, and acute tissue inflammation resulting in appendiceal base diameter beyond 16 mm precluded use of the clip in that patient.

The patients were 56% female with a mean age of 41 years and average BMI of 29 kg/m<sup>2</sup>. Mean operative time was 45 min, and there were no perioperative complications. One patient underwent CT on postoperative day 2 for abdominal pain and ileus, which revealed a small amount of persistent fluid in the pelvis. However, the patient did not require drainage or other invasive interventions, and symptoms resolved spontaneously. One patient presented to the emergency department for evaluation of continued abdominal pain several days after surgery, but no physiological abnormalities were identified. One patient had placement of an intraoperative drain due to radiologic concerns over possible concurrent diverticulitis in the descending colon. This patient's clinical condition improved after appendectomy, and the drain was removed without incident. One patient had a localized suture abscess of the umbilical incision. Mean length of stay was 1 d and mean length of follow-up within our health system was 81 d. Twelve percent of the patients did not come for a follow-up appointment in our health system. Additional patient-related and perioperative characteristics can be found in **Tables 1, 2, and 3**. The polymeric clips contributed very little (~\$32) to the overall operative cost.



**Figure 1.** **A**, Placement of polymeric clip on appendiceal base. **B**, Scissor ligation of appendix after placement of 3 polymeric clips. **C**, Electrosurgical fulguration of appendiceal stump mucosa with 2 polymeric clips secured. **D**, Inflamed appendix placed into specimen bag for removal.

## DISCUSSION

Laparoscopic appendectomy for acute appendicitis has been shown to be a safe alternative to the standard open procedure. Initial reports suggested that the laparoscopic approach offers shorter LOS and decreased incidence of wound infection in exchange for higher operative cost and a potential for increased incidence of intra-abdominal infection.<sup>10</sup> However, more recent studies suggest that the complication rates are now similar, and efforts are ongoing to reduce costs.<sup>4,10,11</sup> Furthermore, if operative cost differences remain, this may be compensated for by shorter LOS and quicker return to work for laparoscopic procedures.

In our institution, laparoscopic appendectomy is the most common treatment for acute appendicitis, but a variety of techniques have been used for transecting the appendix. The use of endoscopic linear staplers to control the appendix base is the most common technique and has been shown to be safe and effective.<sup>12,13</sup> However, there is a significant cost associated with this application; stapler handles and loads usually cost several hundred dollars. Institution-specific pricing schedules prevent detailed comparison of stapler/load costs, but there is no question that polymeric clips are much less expensive than endoscopic staplers. Use of an Endoloop (Ethicon, LLC,

**Table 1.**

Postoperative Characteristics of Patients Undergoing Laparoscopic Appendectomy With a Polymeric Clip Used to Secure the Appendiceal Stump

Patient Preoperative Characteristics	Distribution (mean, SD) or %
Sex	
Female	56
Mean age, years (SD)	41 (18)
Mean BMI, kg/m <sup>2</sup> (SD)	29.2 (6.6)
Preoperative smoking status, %	
Nonsmoker	75
Smoker	21
Unknown	4
ASA status, n	
1 (E)	7 (1)
2 (E)	15 (4)
3 (E)	3 (1)
WBC, preoperative mean (SD)	14.0 (4.1)
Additional CT scan findings, n	
Adjacent terminal ileum appears inflamed	2
Suspicion of early diverticulitis of descending colon	1
None	12

N = 25 patients. Other incidental CT findings included nephrolithiasis/large staghorn calculus, ovarian cyst/dominant follicle, cholelithiasis, focal diverticulitis of the descending colon, constipation, atherosclerosis, medical duodenal diverticulum, suspected hepatic cyst, small hiatal hernia, colonic diverticulosis, hepatic steatosis, bilateral renal cysts, intrauterine device, borderline retroperitoneal and mesenteric adenopathy, small right inguinal hernia containing fat only, mild elevation right hemidiaphragm, mild biliary dilatation. E, emergent.

Cincinnati, Ohio, USA) or similar suture ligation technique has been advocated as a less expensive option that can be placed through a 5-mm port, which is another proposed benefit.<sup>14,15</sup> However, they can be more difficult to apply, and this may be why their use has been limited at our institution. Furthermore, Endoloops are associated with increased operative time, in comparison to polymeric clips and Endostaplers.<sup>8,16</sup> Proficient use of Endoloop is part of the Fundamentals of Laparoscopic Surgery (FLS) curriculum, and surgeons who have completed this training should therefore feel comfortable using this technique but may still take more time to do so. We believe that the application of polymeric clips represents a more basic skill and is a

**Table 2.**

Postoperative Characteristics of Patients Undergoing Laparoscopic Appendectomy Using Polymeric Clip to Secure the Appendiceal Stump

Intraoperative Characteristics	Distribution (mean, SD) or %
Intraoperative complications	0
Mean estimated blood loss, mL (SD)	12.5 (5)
Other concurrent procedures, %	
None	84
Umbilical hernia repair	12
Drain for diverticulitis	4
N = 25 patients.	

readily applicable and cost-effective option for surgeons who may not have completed FLS training but continue to perform basic laparoscopic procedures.

The polymeric clip offers significant cost savings when compared to endoscopic staplers, and provides a simpler application when compared to suture ligation techniques. Recently, several international studies have demonstrated the effective use of a polymeric clip for transecting the appendix.<sup>5-9</sup> Polymeric clips are made of nonconductive, inert, nonabsorbable material and are capable of securing vessels and tissue bundles up to 16 mm in thickness. The clips have a hinged locking mechanism, as well as integrated teeth, which prevent slippage. Because it is non-metallic, it is safe to use electrocautery near the clip without risk of transmitting current. The only known contraindications to use of polymeric clips are severe inflammation with associated poor tissue quality, and tissue diameter larger than can be encompassed by the clip. Sound surgical judgment should determine applicability of polymeric clip ligation of acutely inflamed tissue, and in one of our cases, an intraoperative decision was made to avoid clip ligation of an acutely inflamed appendiceal base with a diameter approaching the maximum size of 16 mm. Of note, all other published studies to date examining the use of polymeric clips to secure the appendiceal stump have demonstrated it to be safe and cost-effective (**Table 4**).

Polymeric clips are routinely used during laparoscopic cholecystectomy for clipping the cystic duct and artery, during laparoscopic urologic procedures for control of vessels and ureters, and in numerous other gynecologic and general surgery procedures. Based on our clinical experience and the positive international reports in the

**Table 3.**

Postoperative Characteristics of Patients Undergoing Laparoscopic Appendectomy With Polymeric Clip to Secure the Appendiceal Stump

Postoperative Characteristics	Distribution (mean, SD) or %
Outpatient antibiotic regimen, %	
None	64
Outpatient antibiotics prescribed	28
Unknown	8
Complications, %	
None	88
Pelvic fluid collection	4
Suture abscess at umbilicus	4
Presentation to ED for pain (no pathology)	4
Mean total hospital LOS, days (SD)	2.4 (1)
Postoperative LOS, days	
Median	1
Minimum	0
Maximum	6
IQR	2
Mean time to follow-up in surgical clinic, days (SD)	19.6 (12)
No follow-up in surgical clinic, %	36
Mean length of follow-up, days (SD)	80.7 (88)
No f/u in our system, %	12

N = 25 patients.

literature, we conducted the first prospective clinical series using polymeric clips in the United States. We were particularly interested in expanding their use to appendectomies while maintaining our established, safe surgical outcomes profile and capturing potential cost savings.

**Complications**

There were no major perioperative complications in this study. The single minor complication we encountered was associated with a superficial suture abscess, which developed at the umbilical incision site. This stitch abscess was easily managed with suture removal and outpatient wound care. One patient (4%) experienced postoperative pain and prolonged ileus caused by persistent pelvic fluid observed on CT scan. However, given the prompt and spontaneous resolution of this complication without any invasive intervention, we did not classify this event as

significant. Of note, the reported rate of postoperative intra-abdominal abscess in the literature ranges from 1 to 24%.<sup>11,20,21</sup>

Clip migration is the most commonly reported complication of polymeric clips in the literature, although it has not been reported after laparoscopic appendectomy.<sup>17-19</sup> It has been reported to happen as soon as 5 weeks after radical prostatectomy and as long as 8 months after a laparoscopic cholecystectomy. Other theoretical complications related specifically to this technique include chronic pain, granulomas, or foreign body reaction due to the nonabsorbable nature of the clips.<sup>6</sup> We did not encounter any such complications or problems with the clips. Given that the mean length of follow-up in our health system was almost 3 months, we feel that we would have been aware of any occurrences of early migration. Although it is possible that later migrations may yet occur, this complication remains extremely rare overall.

**Cost**

We believe that the polymeric clips provided a significant cost savings without compromising patient safety outcomes. At our institution and in other studies,<sup>5,6,8</sup> polymeric clips are less expensive than either an Endoloop or endoscopic linear stapler. Polymeric clips contributed approximately \$32 to the operative cost. In contrast, a stapler plus just one staple load would contribute several hundred dollars to the operative cost. Of note, we used the polymeric clips, not only for control of the appendix, but also for ligation and control of the mesoappendix in most cases. This application resulted in greater cost savings since a vessel sealing bipolar device or ultrasonic dissection device would contribute even greater additional costs to the operation.

Our average operative time was 45 min with only 1 case where the clip could not be applied because of significant appendiceal tissue inflammation. Our study demonstrates surgical feasibility and safety.

**Study Limitations**

A major limitation of our study was the relatively small sample size. In fact, we had initially estimated a sample size of 40 patients to be recruited prospectively over a 1-year period. However, we did not anticipate the difficulty in obtaining investigational research consent in acutely ill patients presenting with abdominal pain and appendicitis. Given their acute pain as well as their stress and anxiety in anticipation of unexpected impending surgery, we found them often unwilling to engage in a discussion regarding participation in a research study. We

**Table 4.**  
Prior Studies Examining Use of Polymeric Clips in Laparoscopic Appendectomy

Author	Year	Country	Journal	N	Outcomes	Cost Analysis
Colak et al	2013	Turkey	<i>Surg Laparosc Endosc Percutan Tech</i>	53	No difference in the complications	30 USD for 3 PCs
				26 PC		120 USD for 3 Endoloop
				27 Endoloop		300 USD for Endostapler
Akkoyun and Akbiyik	2012	Turkey	<i>Eur J Pediatr Surg</i>	121 Pedi	No complications	Cost of PC 10 USD
				71 Double PC	LOS <24 hours postop	(vs 55 USD for Endoloop, 330 for Endostapler)
				50 Single PC		
Partecke et al	2010	Germany	<i>Langenbecks Arch Surg</i>	82	Longer OT for PC	20 € for one set of PCs
				56 Endostapler	Morbidity did not differ	356 € for staplers
				26 PC		
Delibegovic and Matovic	2009	Bosnia and Herzegovina	<i>Surg Endosc</i>	52	No difference in LOS	77 € for 3 PCs
				28 PC	Shorter OT for PC	89 € for 3 Endoloop
				24 Endoloop	No postoperative complications	
Hanssen et al	2007	Venezuela	<i>JSLs</i>	Cohort 2: 28	NS difference in OT	Hospital expenses
				14 PC	No complications in either group	PC 3084 USD
				14 Endostapler		Endostapler 4237 USD
				Cohort 2: 250 PC		Cohort 2: 4418 USD

PC, polymeric clip; OT, operative time; LOS, length of stay; USD, U.S. Dollars.

extended the initial study period beyond 12 months, and approached a larger number of patients than expected. However, we were able to obtain consent from only 26 patients and closed our recruitment at 18 months. Another limitation is that 3 patients did not have follow-up in our system after discharge. In addition, the mean follow-up was 81 d, meaning that we could have missed some longer term complications. However long-term complications are rare after an appendectomy, and prolonged follow-up would have placed an undue burden on the patients.

## CONCLUSION

In this prospective study of the use of polymeric clips in laparoscopic appendectomy, our findings support previous international conclusions that polymeric clips are safe, efficient, and effective for securing the appendiceal stump. Although the absolute value of cost savings varies by specific health system and individual pricing contracts, we confirmed

that polymeric clips offer the ability to secure the appendiceal stump at a reduced cost, without increasing operative time or overall length of stay. Thus, we believe polymeric clips can provide increased value of healthcare to patients undergoing laparoscopic appendectomy.

## References:

1. Addiss DG, Shaffer N, Fowler BS, Tauxe RV. The epidemiology of appendicitis and appendectomy in the United States. *Am J Epidemiol.* 1990;132:910–925.
2. Liu BR, Ma X, Feng J, et al. Endoscopic retrograde appendicitis therapy (ERAT): a multicenter retrospective study in China. *Surg Endosc.* 2015;29:905–909.
3. Di Saverio S, Sibilio A, Giorgini E, et al. The NOTA Study (Non-Operative Treatment for Acute Appendicitis): prospective study on the efficacy and safety of antibiotics (amoxicillin and clavulanic acid) for treating patients with right lower quadrant

abdominal pain and long-term follow-up of conservatively treated suspected appendicitis. *Ann Surg.* 2014;260:109–117.

4. Avansino JR, Goldin AB, Risley R, Waldhausen JH, Sawin RS. Standardization of operative equipment reduces cost. *J Pediatr Surg.* 2013;48:1843–1849.
5. Colak E, Kement M, Ozlem N, et al. A comparison of non-absorbable polymeric clips and Endoloop ligatures for the closure of the appendicular stump in laparoscopic appendectomy: a prospective, randomized study. *Surg Laparosc Endosc Percutan Tech.* 2013;23:255–258.
6. Akkoyun I, Akbiyik F. Closing the appendicular stump with a polymeric clip in laparoscopic appendectomy: analysis of 121 pediatric patients. *Eur J Pediatr Surg.* 2012;22:133–135.
7. Partecke LI, Kessler W, von Bernstorff W, Diedrich S, Heidecke CD, Patrzyk M. Laparoscopic appendectomy using a single polymeric clip to close the appendicular stump. *Langenbecks Arch Surg.* 2010;395:1077–1082.
8. Delibegovic S, Matovic E. Hem-o-lok plastic clips in securing of the base of the appendix during laparoscopic appendectomy. *Surg Endosc.* 2009;23:2851–2854.
9. Hanssen A, Plotnikov S, Dubois R. Laparoscopic appendectomy using a polymeric clip to close the appendicular stump. *JLSLS.* 2007;11:59–62.
10. Fanelli R, Richardson W, Korndorffer JR, et al. SAGES Guidelines for Laparoscopic Appendectomy. 2009.
11. Katkhouda N, Mason RJ, Towfigh S, Gevorgyan A, Essani R. Laparoscopic versus open appendectomy: a prospective randomized double-blind study. *Ann Surg.* 242:439–448, 2005; discussion 448–450.
12. Kazemier G, in't Hof KH, Saad S, Bonjer HJ, Sauerland S. Securing the appendiceal stump in laparoscopic appendectomy: evidence for routine stapling? *Surg Endosc.* 2006;20:1473–1476.
13. Wagner M, Aronsky D, Tschudi J, Metzger A, Klaiber C. Laparoscopic stapler appendectomy: a prospective study of 267 consecutive cases. *Surg Endosc.* 1996;10:895–899.
14. Arcovedo R, Barrera H, Reyes HS. Securing the appendiceal stump with the Gea extracorporeal sliding knot during laparoscopic appendectomy is safe and economical. *Surg Endosc.* 2007;21:1764–1767.
15. Beldi G, Muggli K, Helbling C, Schlumpf R. Laparoscopic appendectomy using endoloops: a prospective, randomized clinical trial. *Surg Endosc.* 2004;18:749–750.
16. Lukish J, Powell D, Morrow S, Cruess D, Guzzetta P. Laparoscopic appendectomy in children: use of the endoloop vs the endostapler. *Arch Surg.* 142:58–61, 2007; discussion 62.
17. Krisher SL, Browne A, Dibbins A, Tkacz N, Curci M. Intra-abdominal abscess after laparoscopic appendectomy for perforated appendicitis. *Arch Surg.* 2001;136(4):438–441.
18. Gupta R, Sample C, Bamehriz F, Birch DW. Infectious complications following laparoscopic appendectomy. *Can J Surg.* 2006;49(6):397–400.
19. Mora ER, Gali OB, Garin JA, Arango O. Intravesical migration and spontaneous expulsion of a Hem-o-lok polymer ligating clip after laparoscopic radical prostatectomy. *Urology.* 2010; 75(6):1317.
20. Seyyedmajidi M, Hosseini SA, Hajiebrahimi S, Vafaeimanesh J. Hem-o-Lok Clip in the First Part of Duodenum after Laparoscopic Cholecystectomy. *Case Rep Gastrointest Med.* 2013;2013: 251634.
21. Hagopian TM, Harmon PJ, Clifton MS. Polymer Surgical Clip Migration Into the Trachea of an Infant. *CRSLS, MIS Case Reports from SLS.* 2014.