

## Evaluation of Micronucleus in Exfoliated Buccal Epithelial Cells Using Liquid-based Cytology Preparation in Petrol Station Workers

### Abstract

**Background:** Liquid-based cytology (LBC) can be used for the evaluation of micronucleus (MN) in exfoliated buccal epithelial cells of populations occupationally exposed to potentially carcinogenic agents. **Aim:** This study was undertaken to evaluate the frequency of MN of exfoliated buccal epithelial cells using LBC preparation in petrol station workers. **Materials and Methods:** Fifty petrol station workers (cases) and fifty hospital administrative staffs (controls) were recruited and evaluated for MN by May-Grunwald Giemsa, Hematoxylin and Eosin, and Papanicolaou stains using LBC preparation. Statistical analysis was performed with Student's *t*-test, and  $P < 0.05$  was considered statistically significant. **Results:** Regardless of staining method used, the mean frequency of MN for cases was significantly higher than that of controls ( $P < 0.001$ ). **Conclusion:** The present study concluded that petrol station workers are under risk of significant cytogenetic damage. The MN in exfoliated buccal epithelial cells found to be a useful biomarker of occupational exposure to genotoxic chemicals. LBC can be used for sample preparation to evaluate the frequency of MN in those who are occupationally exposed to potentially carcinogenic agents in view of overall improvement on sample preservation and visualization of cell morphology.

**Keywords:** Exfoliated buccal epithelial cells, liquid-based cytology, micronucleus, petrol station workers

### Introduction

Micronucleus (MN), a microscopically visible round or oval cytoplasmic chromatin mass in the extranuclear vicinity, originates from aberrant mitosis and consists of eccentric chromosomes, chromatid fragments, or whole chromosomes, which have failed to reach spindle poles during mitosis.<sup>[1]</sup> MN assay in exfoliated buccal cells is a useful and minimally invasive method for monitoring genetic damage in humans in comparison to obtaining blood samples for lymphocyte and erythrocyte assays or tissue biopsies.<sup>[2]</sup> There are definite chances of inhalation of the volatile fraction of petrol during vehicle refueling by petrol station workers, and these petroleum products contain a large amount of benzene. Chronic occupational exposure to such derivatives possesses genotoxic risk and said to be carcinogenic in nature.<sup>[3,4]</sup> Acute myeloid leukemia and non-Hodgkin's lymphomas have been found to be increasingly associated with those who are occupationally exposed to benzene.<sup>[3]</sup>

This is an open access article distributed under the terms of the Creative Commons Attribution-NonCommercial-ShareAlike 3.0 License, which allows others to remix, tweak, and build upon the work non-commercially, as long as the author is credited and the new creations are licensed under the identical terms.

For reprints contact: reprints@medknow.com

Buccal epithelial cells form the first barrier for the inhalation or ingestion route and are capable of metabolizing carcinogens to reactive products. About 90% of human cancers originate from epithelial cells. Hence, they represent a preferred target site for early genotoxic events induced by carcinogenic agents entering the body through inhalation and ingestion.<sup>[5]</sup>

Application of liquid-based cytology (LBC) in the field of gynecologic cytology goes back almost three decades.<sup>[6]</sup> Since its introduction, majority of laboratories have started to apply LBC to exfoliative and nongynecological aspiration.<sup>[5]</sup> The advantages of LBC include rapid fixation, even distribution of cells over a smaller slide area, and decreased obscuring background elements, such as blood, inflammation, and mucus.<sup>[7]</sup> The present study was undertaken to evaluate frequency of MN of exfoliated buccal epithelial cells using LBC preparations in petrol station workers.

### Materials and Methods

This prospective study was undertaken at the Department of Pathology in our

**How to cite this article:** Arul P, Shetty S, Masilamani S, Akshatha C, Naveen Kumar BJ. Evaluation of micronucleus in exfoliated buccal epithelial cells using liquid-based cytology preparation in petrol station workers. *Indian J Med Paediatr Oncol* 2017;38:273-6.

P Arul,  
Smitha Shetty,  
Suresh Masilamani,  
C Akshatha,  
BJ Naveen Kumar

Department of Pathology,  
Dhanalakshmi Srinivasan  
Medical College and Hospital,  
Perambalur, Tamil Nadu, India

### Address for correspondence:

Dr. P Arul,  
No 83, Ayyanar Kovil Street,  
Vinayagampet, Sorapet Post,  
Puducherry - 605 501, India.  
E-mail: drarul3@gmail.com

### Access this article online

Website: [www.ijmpo.org](http://www.ijmpo.org)

DOI: 10.4103/ijmpo.ijmpo\_26\_16

### Quick Response Code:



institution, conducted during the period from August 2015 to October 2015, after obtaining approval from the Institutional Ethical Committee. Informed written consent was obtained from each patient.

A total of 100 healthy participants with devoid of any oral lesions formed the study population. Of these, fifty males were petrol station workers (cases) and remaining fifty were hospital administrative staffs (controls). All the participants were asked to complete the questionnaire to obtain demographic data such as age, history of smoking/alcohol, duration of work, and family history of cancer. All participants in both groups were nonsmokers and nontobacco chewers.

All the 100 healthy participants were advised to rinse their mouth thoroughly with water to remove unwanted debris prior collection of exfoliated buccal epithelial cells. Sterile wooden spatula was used to obtain cell samples from buccal mucosa, and material was preserved in alcohol-based liquid preservative. The material was centrifuged at 1500 rpm for 5 min. The supernatant was discarded and pellet was agitated to get homogeneous sample. One drop of normal saline was added to pellet and it was mixed well. About 50  $\mu$ l of diluted pellet was placed on clean slides with a drop of fixative solution and was subsequently stained with May-Grunwald Giemsa (MGG), Hematoxylin and Eosin (H and E), and Papanicolaou stain (Pap). The slides were examined under light microscope by pathologist.

The frequency of MN in 1000 exfoliated cells was scored using criteria established by Tolbert *et al.* and El-Setouhy *et al.*<sup>[8,9]</sup> Tolbert *et al.* criteria used for both choosing of cells and for identification of cells; the following parameters for cell inclusion in the cells to be scored: (a) intact cytoplasm and a relatively flat cell position on the slide, (b) little or no overlap with adjacent cells, (c) little or no debris, and (d) normal, intact smooth, and distinct nuclear perimeter; the criteria used to identify the MN: smooth and round perimeter, size less than one-third of the main nucleus diameter but large enough to discern shape and color, texture and intensity of the staining similar to that of the nucleus, same focal plane as the nucleus, and no overlap or connection to the nucleus. El-Setouhy *et al.* criteria for identification of MN: opaque extranuclear intracytoplasmic bodies viewed under an oil immersion lens and by phase contrast. However, binucleate cells or cells with fragmented nuclei, karyolysis, and nuclei appearing as broken eggs were not counted as MN.

All the statistical analyses were performed using the International Business Machines (IBM) Corporation Statistical Package for the Social Sciences Statistics for Windows (version 20.0. Armonk, New York, USA: IBM Corporation). The mean frequencies of MN cases and controls were compared for all stains using Student's *t*-test.  $P < 0.05$  was considered statistically significant.

## Results

The characteristics of the both groups are presented in Table 1. The mean age and alcohol habits were similar in both cases and controls. The mean frequency of MN stained with MGG [Figure 1a], H and E [Figure 1b], and Pap stain [Figure 1c] using LBC preparation was significantly higher in cases than that of controls ( $P < 0.001$ ) regardless of staining method used [Table 2].

## Discussion

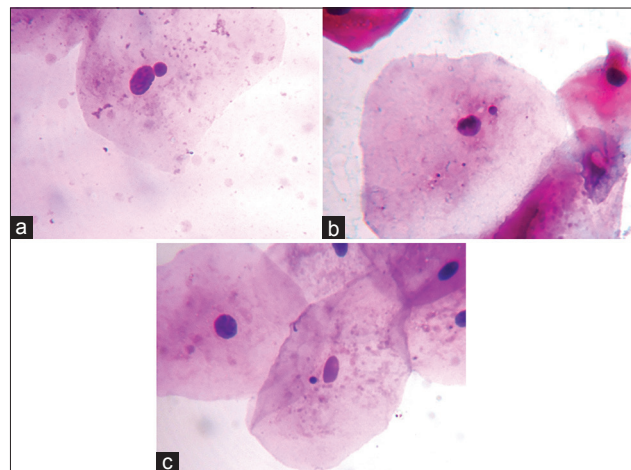
Benzene is a widely distributed environmental contaminant, which is an important component of petrol. Approximately 98% of the benzene is derived from the petrochemical and petroleum refining industries. Hence, occupational exposure to benzene in humans generally takes place in factories, refineries, and other industrial settings. Furthermore, the general population is exposed to benzene contained in petrol, vehicle exhaust, diesel fuel, and cigarette smoke.<sup>[10]</sup>

The most important fundamental cause of developmental and degenerative disease is probably due to genomic damage.<sup>[11]</sup> Those who are occupationally exposed to toxic environmental agents such as solvents, polycyclic aromatic hydrocarbons (benzene), emissions of sugarcane straw burning, gasoline, arsenic, and antineoplastic drugs have been demonstrated high frequencies of MN in exfoliated

**Table 1: Demographic characteristics of participants**

	Cases	Controls
Individuals	50	50
Mean age $\pm$ SD (years)	37 $\pm$ 9	35 $\pm$ 6
Alcoholics (%)	14 (28)	12 (24)
Family history of cancer (%)	5 (10)	4 (8)
Length of time working in petrol filling station	19.36 $\pm$ 8.41	

SD – Standard deviation



**Figure 1: Cytosmears prepared using liquid-based cytology showing exfoliated buccal epithelial cells with micronucleus. (a) May-Grunwald Giemsa,  $\times 400$ , (b) H and E,  $\times 400$ , (c) Papanicolaou stain,  $\times 400$**

**Table 2: Comparison of mean frequency of micronucleus using Student's *t*-test among all stains**

Stain	Total number of participants	Cases		Controls		<i>P</i> *
		Mean±SD	Median	Mean±SD	Median	
MGG	100	15.48±4.6	15	6.64±4.54	6	<0.001
H and E	100	17.72±5	17	7.8±4.83	7	<0.001
Pap	100	21.16±5.54	23	11.68±4.81	11	<0.001

\**P*<0.05 was considered statistically significant. MGG – May-Grunwald Giemsa; H and E – Hematoxylin and Eosin; Pap – Papanicolaou stain; SD – Standard deviation

buccal cells compared to the controls.<sup>[5]</sup> Due to its ease of use and handling, low capital investment requirements, and the accuracy achieved, MN assay in exfoliated buccal epithelial cells has received special attention to assess the impact of environmental and genetic factors and lifestyle habits on genomic instability in humans.<sup>[12,13]</sup> Hence, buccal epithelial cells provide an alternative source of tissue in human subjects monitoring for occupational and environment toxic exposures.<sup>[14]</sup> However, oral mucosa permeability in different regions of the mouth is an important aspect to consider when analyzing the local effects of carcinogenic effects. Nonkeratinized tissues, such as the buccal mucosa, are shown to be much more permeable than keratinized tissues, such as the palate and gingiva.<sup>[15,16]</sup>

However, the data on cytogenetic damage in petrol station attendants are rather controversial. Pitarque *et al.*<sup>[17]</sup> found no statistically significant increased frequencies of MN in cultured blood lymphocytes from a group of filling station attendants. Surrallés *et al.*<sup>[18]</sup> studied molecular cytogenetic analysis of buccal cells and lymphocytes from benzene-exposed workers in a petrochemical complex in Estonia and found that there was no increase in the frequency of cytogenetic damage compared to the controls.

The present study evaluated the genotoxicity in the petrol station workers, and we found that they had higher frequencies of MN compared to that of controls, regardless of staining method used. These findings were considered statistically significant (*P* < 0.001). Hence, this study reveals that it is possible to analyze the frequency of MN using LBC preparation in both cases and controls. Celik *et al.*,<sup>[3]</sup> done a study on cytogenetic biomonitoring in petrol station attendants by evaluating MN in buccal epithelial cells and they found that a significant increase in the frequency of MN. These findings were comparable to the current study and works done by Singaraju *et al.*,<sup>[11]</sup> Rajkokila *et al.*,<sup>[14]</sup> Sellappa *et al.*,<sup>[19]</sup> and Gadhia *et al.*,<sup>[20]</sup> and they found a significant increase in the frequency of nuclear abnormalities in the exfoliated buccal epithelial cells of petrol station workers than the controls.

LBC offers many advantages such as complete preservation of collected material, reduced reading time, due to the decrease in the area of cell concentration and optimal cell preservation, and staining which improves the clarity and visibility of cytomorphological features, thus facilitating

the detection of cellular changes.<sup>[21]</sup> Kujan *et al.*<sup>[22]</sup> first applied LBC in buccal epithelial cells and authors found a uniform distribution of cells. Authors also demonstrated improved cytomorphology and visibility of nuclear detail and thereby offering a superior and unbiased sample while controlling cell density, reducing scanty preparations, and eliminating air-drying artifacts. A study done by Hayama *et al.*<sup>[23]</sup> demonstrated that the technique of slide preparation can be enhanced by the use of LBC which showed a statistically significant improvement in smear thickness, cell distribution, and a reduction in cell overlapping and the presence of blood; authors also concluded that LBC demonstrated an overall improvement on sample preservation, specimen adequacy, visualization of cell morphology, and reproducibility. Similar to these studies, the current study also showed improved cytomorphology, uniform cell distribution with visibility of nuclear details. Hence, slides prepared by LBC technique provide good quality smears with elimination of confounding factors. Thus, application of LBC in MN assay is one way to refine and improve the assessment of this biomarker with very less false-positive results.

## Conclusion

The present study concluded that petrol station workers are under risk of significant cytogenetic damage. The MN in exfoliated buccal epithelial cells found to be a useful biomarker of occupational exposure to genotoxic chemicals. LBC can be used for sample preparation to evaluate the frequency of MN in those who are occupationally exposed to potentially carcinogenic agents in view of overall improvement on sample preservation and visualization of cell morphology.

## Financial support and sponsorship

Nil.

## Conflicts of interest

There are no conflicts of interest.

## References

- Sivasankari NP, Kaur S, Reddy KS, Vivekanandam S, Rao KR. Micronucleus index: An early diagnosis in oral carcinoma. *J Anat Soc India* 2008;57:8-13.
- Motgi AA, Chavan MS, Diwan NN, Chowdhery A, Channe PP, Shete MV. Assessment of cytogenetic damage in the form of micronuclei in oral epithelial cells in patients

- using smokeless and smoked form of tobacco and non-tobacco users and its relevance for oral cancer. *J Cancer Res Ther* 2014;10:165-70.
3. Celik A, Cavas T, Ergene-Gözükara S. Cytogenetic biomonitoring in petrol station attendants: Micronucleus test in exfoliated buccal cells. *Mutagenesis* 2003;18:417-21.
  4. Carere A, Antoccia A, Crebelli R, Degrassi F, Fiore M, Iavarone I, *et al.* Genetic effects of petroleum fuels: Cytogenetic monitoring of gasoline station attendants. *Mutat Res* 1995;332:17-26.
  5. Ramos MA, Cury Fde P, Scapulatempo Neto C, Marques MM, Silveira HC. Micronucleus evaluation of exfoliated buccal epithelial cells using liquid-based cytology preparation. *Acta Cytol* 2014;58:582-8.
  6. Zeppa P. Liquid-based cytology: A 25-year bridge between the Pap smear and molecular cytopathology. *Acta Cytol* 2014;58:519-21.
  7. Mygdakos N, Nikolaidou S, Tzilivaki A, Tamiolakis D. Liquid based preparation (LBP) cytology versus conventional cytology (CS) in FNA samples from breast, thyroid, salivary glands and soft tissues. Our experience in Crete (Greece). *Rom J Morphol Embryol* 2009;50:245-50.
  8. Tolbert PE, Shy CM, Allen JW. Micronuclei and other nuclear anomalies in buccal smears: A field test in snuff users. *Am J Epidemiol* 1991;134:840-50.
  9. El-Setouhy M, Loffredo CA, Radwan G, Abdel Rahman R, Mahfouz E, Israel E, *et al.* Genotoxic effects of waterpipe smoking on the buccal mucosa cells. *Mutat Res* 2008;655:36-40.
  10. Zhang L, Eastmond DA, Smith MT. The nature of chromosomal aberrations detected in humans exposed to benzene. *Crit Rev Toxicol* 2002;32:1-42.
  11. Singaraju M, Singaraju S, Parwani R, Wanjari S. Cytogenetic biomonitoring in petrol station attendants: A micronucleus study. *J Cytol* 2012;29:1-5.
  12. Sisenando HA, Batistuzzo de Medeiros SR, Artaxo P, Saldiva PH, Hacon Sde S. Micronucleus frequency in children exposed to biomass burning in the Brazilian Legal Amazon region: A control case study. *BMC Oral Health* 2012;12:6.
  13. Thomas P, Holland N, Bolognesi C, Kirsch-Volders M, Bonassi S, Zeiger E, *et al.* Buccal micronucleus cytome assay. *Nat Protoc* 2009;4:825-37.
  14. Rajkokila K, Shajithanoop S, Usharani MV. Nuclear anomalies in exfoliated buccal epithelial cells of petrol station attendants in Tamil Nadu, South India. *J Med Genet Genomics* 2010;2:18-22.
  15. Revazova J, Yurchenko V, Katosova L, Platonova V, Sycheva L, Khripach L, *et al.* Cytogenetic investigation of women exposed to different levels of dioxins in Chapaevsk town. *Chemosphere* 2001;43:999-1004.
  16. Roth MG, Viégas J, Amaral M, Oliveira L, Ferreira FL, Erdtmann B. Evaluation of genotoxicity through micronuclei test in workers of car and battery repair garages. *Gene Mol Biol* 2002;25:495-500.
  17. Pitarque M, Carbonell E, Lapeña N, Marsá M, Torres M, Creus A, *et al.* No increase in micronuclei frequency in cultured blood lymphocytes from a group of filling station attendants. *Mutat Res* 1996;367:161-7.
  18. Surrallés J, Autio K, Nylund L, Järventaus H, Norppa H, Veidebaum T, *et al.* Molecular cytogenetic analysis of buccal cells and lymphocytes from benzene-exposed workers. *Carcinogenesis* 1997;18:817-23.
  19. Sellappa S, Sadhanandhan B, Francis A, Vasudevan SG. Evaluation of genotoxicity in petrol station workers in South India using micronucleus assay. *Ind Health* 2010;48:852-6.
  20. Gadhia PK, Thumbbar RP, Kevadiya B. Cytome assay of buccal epithelium for bio-monitoring genotoxic assessment of benzene exposure among petrol pump attendants. *Int J Hum Genet* 2010;10:239-45.
  21. Beerman H, van Dorst EB, Kuenen-Boumeester V, Hogendoorn PC. Superior performance of liquid-based versus conventional cytology in a population-based cervical cancer screening program. *Gynecol Oncol* 2009;112:572-6.
  22. Kujan O, Desai M, Sargent A, Bailey A, Turner A, Sloan P. Potential applications of oral brush cytology with liquid-based technology: Results from a cohort of normal oral mucosa. *Oral Oncol* 2006;42:810-8.
  23. Hayama FH, Motta AC, Silva Ade P, Migliari DA. Liquid-based preparations versus conventional cytology: Specimen adequacy and diagnostic agreement in oral lesions. *Med Oral Patol Oral Cir Bucal* 2005;10:115-22.