

Open repair of descending thoracic aneurysms

R. Chiesa, Y. Tshomba, E. Civilini, E.M. Marone, L. Bertoglio, D. Baccellieri, G. Coppi, D. Logaldo, G. Melissano

Department of Vascular Surgery, Università Vita-Salute San Raffaele, Milan, Italy

HSR Proceedings in Intensive Care and Cardiovascular Anesthesia 2010; 2: 177-190

ABSTRACT

Introduction: Current strategies for operative treatment of a thoracic aortic aneurysm consist of open repair with surgical graft replacement or endovascular exclusion. To reduce mortality and morbidity of open repair, a multimodal approach has gradually evolved by maximizing organ protection.

Methods: On a total of 1108 patients treated in our Center from 1993 for pathology involving the thoracic aorta, we reviewed the prospectively collected data of 194 consecutive patients who underwent open thoracic aortic aneurysm repair, 104 (54%) for degenerative aneurysms, 65 (34%) for dissections, 25 (12%) for other pattern of disease. Left Heart Bypass was used in 82% of cases, clamp and sew technique in 16%, hypothermic circulatory arrest in 2%.

Results: Overall perioperative mortality was 4.1%. The rate of pulmonary complications was 8.8%. The rate of cardiac complications, i.e. new onset myocardial necrosis demonstrated by positive blood tests, was 6.2%. The rate of renal complications was 7.2%. Cerebrovascular accident, defined as a new neurologic deficit lasting more than 24 hours confirmed by imaging, occurred in 2.0% of patients. The rate of spinal cord ischemia, manifesting either as paraplegia or paraparesis, was 4.6%.

Conclusions: Mortality and morbidity rates of open thoracic aortic aneurysm repair are currently satisfactory especially in fit patients. In order to define surgical indications and the role of endovascular repair, consideration of age of the patient, comorbidity, symptoms, life expectancy, likely quality of life (if asymptomatic), aortic diameter, aneurysm morphology, aneurysm extent, suitability of landing zones, and operator experience are all distinctly relevant.

Keywords: *thoracic aortic aneurysm, open aortic repair, aortic surgical graft, thoracic aortic dissection, type B aortic dissection, Marfan syndrome.*

INTRODUCTION

Etiology and indications to treatment

Aortic disease is a potentially serious condition and can be particularly severe when it involves the thoracic segment. Thoracic aortic disease can be diagnosed and treated before it becomes dangerous and the most

appropriate management is related to the severity, extension and site of disease and to the specific patient's clinical characteristics and risk factors. Descending thoracic aorta (DTA) may be involved by very different pattern of disease:

Degenerative aneurysms

The incidence of degenerative aneurysms involving the DTA is considered approximately 10 in 10.000 adults, with 30-40% of these aneurysms limited to the intrathoracic segment of the descending aorta (1).

Corresponding author:
 Prof. Roberto Chiesa, MD
 IRCCS H. San Raffaele
 Department of Vascular Surgery
 Via Olgettina, 60
 e.mail: r.chiesa@hsr.it

The pathogenesis of DTA is in most ways similar to the more frequent infrarenal aneurysms and it is due to progressive destruction of the lamina media.

Considering the inherent risk of complications, an aortic diameter of 5.5 cm is widely recognized as the threshold for interventions, while no benefit from treatment exists in case of aneurysms smaller than 5.5 cm². These criteria apply only to asymptomatic patients; symptomatic aneurysms should be treated regardless of size if there are no other contraindications, because symptoms often portend rupture. No level A or B scientific evidence from prospective, randomized studies exists related to the timing of operative intervention according to aneurysm size, as in the case for abdominal aortic aneurysms.

The surgical open repair is currently considered the first therapeutic choice, and the thoracic endovascular aortic repair (TEVAR) should be currently indicated in selected patients with a suitable anatomy allowing a safe and effective endograft deployment, on a predicted operative risk that is clearly lower than the risk of either conventional open repair or optimal medical management.

Dissecting aneurysm

In the acute setting, uncomplicated type B dissection is best managed with medical therapy, however as many as half of all patients develop or present with complications requiring intervention and have a marked increase in mortality. There are at present four indications for acute intervention: unremitting pain, progressive aortic dilatation, malperfusion syndromes, or imminent rupture (3).

The role of primary open procedures for visceral, renal, and limb ischemia is nowadays unclear given the rapid advancement of percutaneous endovascular techniques. The goal of TEVAR in a complicated acute

dissection is to occlude the primary tear(s) and relieve malperfusion syndromes.

Once a patient survives 14 days after initial onset of an acute aortic dissection, it is defined as chronic. Data suggest that TEVAR in patients with chronic aortic dissection can be performed with satisfying technical success. Indications are a maximal thoracic aorta diameter greater than 5.5 cm, documented increase of aortic diameter of more than 1.0 cm within 1 year, resistant hypertension despite antihypertensive combination therapy associated with a small true lumen or renal malperfusion, or recurrent episodes of chest/back pain that cannot be attributed to other causes (2).

Connective tissue disorders

One contraindication to endovascular approaches seems to be defined by connective tissue disorders. Although endografts have been used in Marfan cases in the setting of aneurismal disease, there is too high a risk for creating retrograde dissection or acute or delayed perforation (4). This concept is particularly relevant when considering that centers with extensive experience have excellent results with open repair. Endovascular approach may play a role in the treatment of recurrences when a previously implanted surgical graft can be used as a landing zone.

Imaging modalities

In order to plan the best possible treatment modality for each individual patient, accurate imaging must be obtained preoperatively. There are many different modalities that allow to image the thoracic aorta, each one has its own advantages and drawbacks:

- Chest XR (a valuable basic screening exam).
- Ultrasonography (in particular trans thoracic and trans-oesophageal echography)
- Digital Subtraction Angiography (implies arterial catheterization, contrast

media injection and exposure to ionizing radiation).

- MR-Angiography (no radiations are involved but an intravenous contrast agent may still need to be injected).
- CT-Angiography (exposure to ionizing radiation, intravenous contrast agent injection).

Thoracic aorta CT-angiography and OsiriX

There are several reasons why most surgeons that treat thoracic aortic disease choose CT-Angio as their preferred imaging modality, provided that there are not specific contra-indications. State-of-the-art multi-detector CT scanners produce excellent imaging. Typically a complete exam to study the thoraco-abdominal aorta consists of at least 1000-2000 scans.

To obtain the most from the CT dataset one must be able to navigate through the images and manipulate them (reformatting techniques) in order to extract the most appropriate images that are needed. Until recently, reformatting the CT dataset in order to obtain the images we really need in order to plan our procedure was possible only on dedicated imaging workstations that were expensive, usually located in the radiology department and had to be shared by many specialists, making practical access to them rather difficult.

Since 2004 and especially in the last couple of years the situation have changed considerably. We owe to the ingenuity of Dr. Ratib and his co-workers from the University of Genève (CH) for the creation of the OsiriX software. OsiriX is dedicated to “DICOM” images (Digital Imaging and Communications in Medicine) produced by current medical equipment, and runs on regular Mac OS X computers. It has been specifically designed for navigation and visualization of multi-modality and multidimensional images, including CT. It is world widely

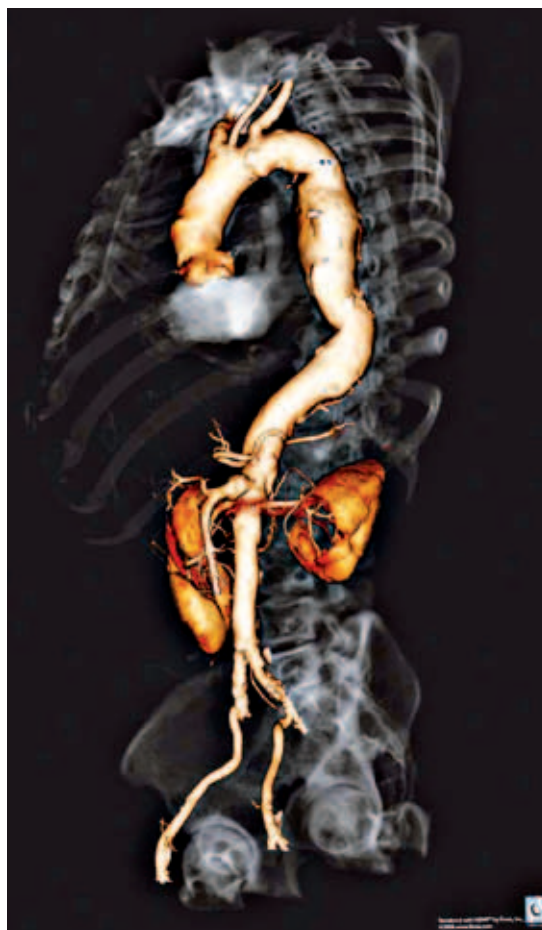

Figure 1 - This image depicts a three-dimensional rendering of the entire aorta in a patient with a descending thoracic aortic aneurysm obtained with the OsiriX and the Fovia high definition volume rendering software.

available to be freely downloaded on the Internet, and is released under GNU free software license, which grants recipients rights to use, modify and redistribute copyrighted work. It is possible to create personalized plug-ins that performs desired actions. With the help of the OsiriX software we started working on our CT dataset to obtain the images of the aorta that we need (Figure 1).

The classic way to show a CT dataset are axial (transverse) scans. However the data-

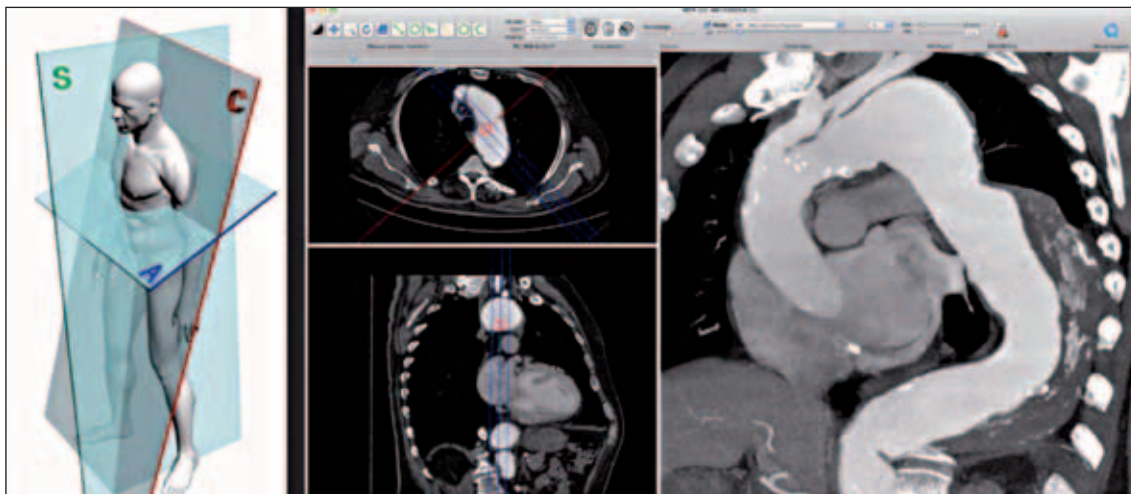


Figure 2 - Customized angulated (non orthogonal) cutting planes are extremely useful when studying a particularly angulated descending thoracic aneurysm. (Osirix screen capture - right).

set contains the whole volume of the body, and we are allowed to view the structure we are studying in a very realistic three-dimensional way using 3D rendering tools. Furthermore, the slices of our dataset can be cut not only in a transverse (Axial) plane but also in a frontal (Coronal) or in a lateral (Sagittal) plane. Scrolling these 3

sets of scans, adjusting the window level and width, zooming and modifying the slice thickness will allow us to gain a lot of information, however unfortunately the important structures in our body don't follow orthogonal planes, the aorta in particular have a tortuous path that curves in all directions of space.

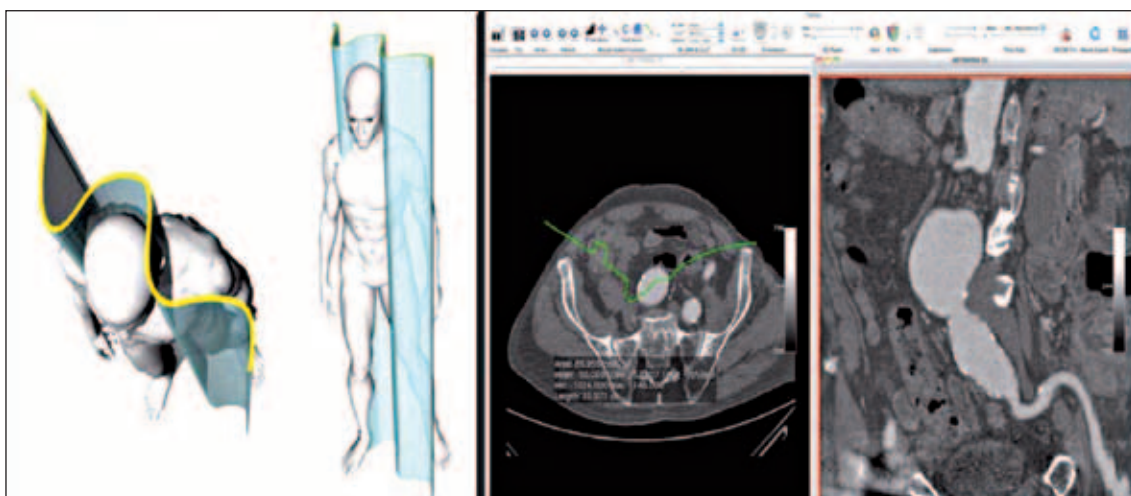


Figure 3 - A very tortuous structure may not be represented by a straight cut. A curved cut, opportunely hand-drawn on the axial scan (green line) can depict the course of this iliac access in a single reformatting plane. (Osirix screen-capture - right).

An oblique multi-planar reconstruction (MPR) may therefore help us producing a scan whose angulation matches that of the aorta, or the vessel we need to study (*Figure 2*).

If the vessel (for example an iliac axis for a peripheral access of a device) we are studying is too tortuous to be followed even in an appropriate oblique MPR we can use an even more sophisticated tool: a curved MPR where the plane we are going to extract from the dataset is hand-drawn on the scan and have precisely the course of the anatomical structure we need to follow (*Figure 3*).

Curved MPR for critical intercostal artery study

The mechanism underlying the occurrence of spinal cord ischemia after open and endovascular thoracic aortic repair has yet to be completely understood.

Several Authors believe the presence of one

or more critical intercostal arteries providing spinal cord blood flow, to play a crucial role in the development of postoperative spinal cord ischemia.

Kieffer et al. recently published a remarkable large single-centre study of open and endovascular repair of descending thoracic aortic aneurysms in which endovascular repair was carried out exclusively in high-surgical risk patients in whom preoperative spinal cord arteriography demonstrated the origin of the critical intercostal arteries outside the zone to be covered by the endograft¹.

A curved MPR may provide preoperative imaging not only of intercostal arteries, but of all the vascular collateral network providing flow to spinal cord (*Figure 4*) including vertebral, hypogastric and mammary arteries.

Although this methods to study spinal cord blood supply is extremely interesting from an academic perspective, it's probably still

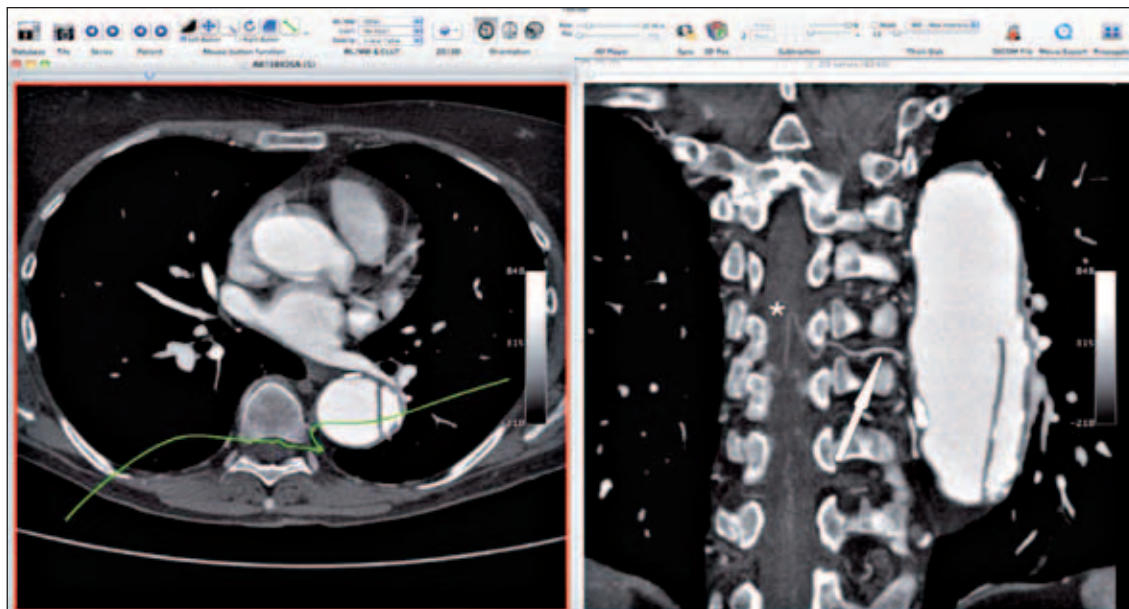


Figure 4 - A curved plane (green line) allowed depicting the path of the Adamkiewicz artery(*) in this patient, clearly showing its continuity with the false lumen of its dissected aorta (arrow). (OsiriX screen capture).

Table 1 - Results of open descending aortic repair. Updated personal series (*).

Author (year)	Patients	Operative mortality (%)	Paraplegia/paraparesis (%)	Stroke (%)	Renal failure (%)
Estrera (6) (2005)	300	24 (8.0)	7 (2.3)	6 (2.1)	12 (4.2)
Coselli (7) (2004)	387	11 (2.8)	10 (2.6)	/	29 (7.5)
Borst (8) (1994)	132	4 (3)	12 (9.1)	/	2 (1.3)
Svensson (9) (1993)	832	63 (8)	90 (10.8)	29 (3.5)	58 (6.9)
Verdant (10) (1992)	267	39 (15)	0 (0)	/	1 (0.4)
Fehrenbacher (11) (2007) ²	63	2 (3)	0 (0)	/	0 (0)
Chiesa (2009)*	194	8 (4.1)	9 (4.6)	4 (2.0)	14 (7.2)

not accurate enough to act as bases for operative strategies. Furthermore it only depicts the vascular anatomy without provide any functional information.

Once validation and improved understanding of the information acquired with CT-based angiography (or alternatively MR-angiography) of the spinal cord vasculature are realized, several important clinical benefits are possible:

1. Preoperative stratification of the risk of spinal cord ischemia;
2. Selective intercostal/lumbar artery re-implantation (open surgery);
3. Avoidance of unnecessary coverage of intercostal feeders of the artery of Adamkiewicz (TEVAR);
4. Selective revascularization of left subclavian artery or hypogastric artery;
5. Selective use of adjuncts that have an intrinsic risk of complications, such as cerebrospinal fluid drainage (CSFD).

Open repair

Open surgery for DTA is a major vascular procedure with mortality and morbidity rates not negligible.

However, thanks to the multimodality approaches of organ protection, the outcomes have considerably improved in the last decades, especially in “high-volume” centers as shown in *table 1*.

Preoperative evaluation

Imaging

A preoperative angioCT with 3D volume rendering tools may play a role beyond in studying diseased aorta and the spinal cord vascular anatomy, in understanding the conformation of the patient and locating the most appropriate intercostal space to

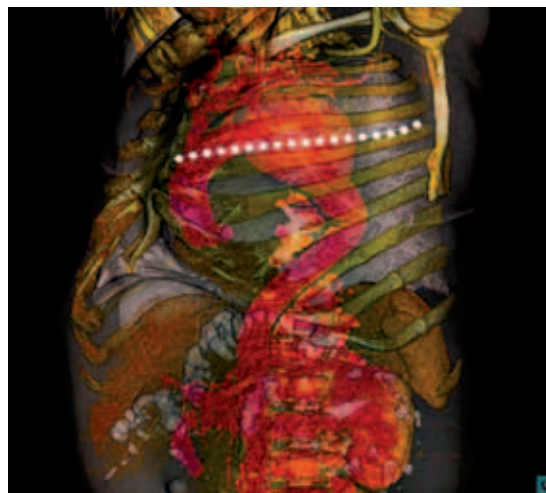


Figure 5 - This image obtained with the OsiriX software and the Fovia high definition volume rendering software allows a pseudo-realistic three-dimensional depiction of the human body highlighting different structures. This kind of images can be useful to plan the surgical access to the thoracic aorta and the ideal intercostal space for thoracotomy.

perform thoracotomy (*Figure 5*). Also the most safe site of proximal and/or distal aortic cannulation (when required) in order to avoid intraluminal thrombus and to reduce the risk of potential embolization may be carefully planned.

Physiologic reserve

An adequate preoperative assessment of physiologic reserve of cardiac, pulmonary, and renal function and an accurate knowledge of cerebral and spinal cord vascular anatomy are useful in evaluating operative risk, planning the best operative strategy and take early additional perioperative precautions.

Preoperative transthoracic echocardiography is a satisfactory noninvasive screening method that evaluates both valvular and biventricular function, exercise testing or dipyridamole-thallium myocardial scanning identifies regions of myocardium that are reversibly ischemic and, in patients with a significant history of angina or reduced ejection fraction, cardiac catheterization with coronary arteriography should be performed. Computed tomographic coronary angiography has recently emerged as a less-invasive alternative method to visualize the coronary arteries anatomy. Interestingly, new multi-row (256) scanners, allow to obtain images of the coronary arteries and thoracic aorta in a single scan, thus improving spatial resolution with reduced radiation dose (12).

Renal function is an established predictor of postoperative outcome. The National Kidney Foundation currently recommends the use of estimated glomerular filtration rate to assess renal function in order to avoid the misclassification of patients on the basis of serum creatinine levels alone (13). Based to this indicator, chronic kidney disease has been shown to be a strong predictor of death after thoracic aneurysm open and endovascular repair even in pa-

tients without clinical evidence of preoperative renal disease (14).

Pulmonary function evaluation with arterial blood gases and spirometry is mandatory in all the patients undergoing open surgery of descending aorta. In patients with a FEV₁ lower than 1.0 and a PCO₂ more than 45, pulmonary function should be improved by stopping smoking, progressively treating bronchitis, losing weight, and following a general exercise program for a period of 1 to 6 months before operation. However, in patients with symptomatic aortic aneurysms, despite a poor pulmonary function, the operation should not be delayed.

Intraoperative monitoring

A right radial arterial pressure line together with a right femoral arterial one are always inserted in order to guarantee an intraoperative continuous arterial blood pressure monitoring.

Temperature monitoring is essential to guide hypothermia especially in time-consuming operations and if a period of circulatory arrest is required. Nasopharyngeal and bladder temperature sensors are inserted to monitor brain and core temperature respectively.

Single lung ventilation by means of a double-lumen endobronchial tube is required in order to obtain adequate surgical exposure and to limit compression of the heart by retractors. Fiberoptic bronchoscopy is recommended to check correct positioning of endotracheal tube especially in large aneurysms of the descending aorta that may lead to distortion of the trachea or the left main bronchus.

Intraoperative (TEE) is a very helpful tool during thoracic aortic surgery.

Transoesophageal echocardiography enables dynamic monitoring of haemodynamic patients' status and modification of therapeutic management. Furthermore the central venous pressure, right atrial pressure,

and pulmonary capillary wedge pressure may be severely influenced by the patient's right lateral decubitus during surgery and may be not completely reliable in order to monitor cardiac volumes and function.

Both systolic and diastolic changes that may occur at the different stages of the surgical procedure may be real time assessed and patients at risk for perioperative haemodynamic deterioration may be selected. To assess the systolic function, ejection fraction is commonly used, transmitral flow and pulmonary vein flow patterns are commonly used to assess the diastolic function. Myocardial performance index can be used to assess both systolic and diastolic functions and is also useful to assess right ventricular function.

Recently developed real time 3-dimensional systems may provide adjunctive accurate cardiac information, such as left ventricle volumetry, wall motion, dyssynchrony and valvular pathology.

These techniques require considerable technical skill both in obtaining adequate images and in interpretation and may also provide specific information regarding the aorta, especially useful to exclude threatening retrograde dissection or intramural hematoma related to aortic cannulation or

clamping. These information have limitations in assessing the region of the transverse aortic arch and upper abdominal aorta.

In order to reduce the incidence of spinal cord ischemic complications, we routinely utilize CSFD except in cases of planned hypothermic arrest (15). Cerebrospinal fluid is freely drained during aortic clamping, while in the first 72 hours we drain fluid to maintain a target pressure of less than 10 cm/H₂O.

Surgical procedure

Access

The patient is positioned in a right lateral decubitus over a beanbag with the shoulders at 60° and the hips flexed back to 30° to access the entire left thorax, the abdomen and the left groin. A circulating water mattress with heat exchanger is placed between the beanbag and the patient, in order to assist body temperature management.

An adequate exposure is preferable for a safe surgical control of distal and proximal neck and careful anastomotic sutures. The thoracotomy incision varies in length and level, depending on the aneurysm extent. It's our standard practice to deliberately

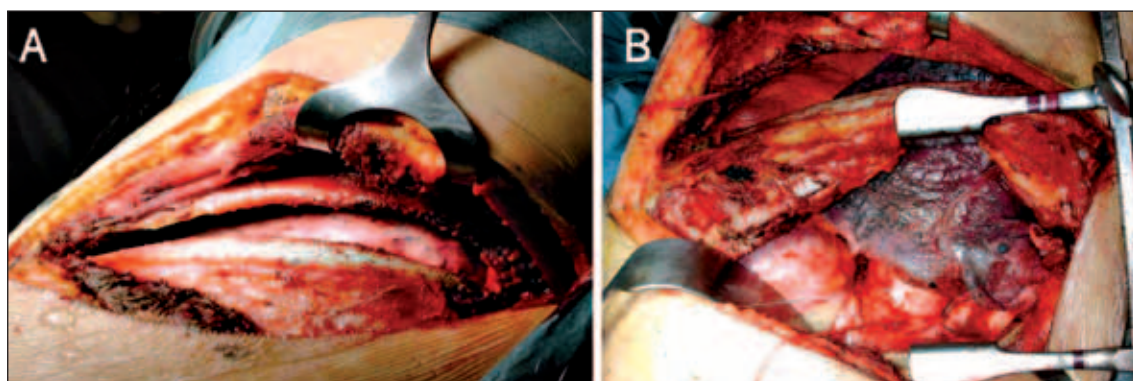


Figure 6 - The picture shows a left thoracotomy in the fifth intercostal space. The left lung has not been excluded yet (A). In rare cases we perform a double left thoracotomy (B) in order to have a better access to the distal and proximal aorta.

cut the rib of the incised intercostal space posteriorly for a better mobilization. When required, rib resection can be performed in order to improve proximal exposure or a double thoracotomy may be performed (*Figure 6*).

Surgical dissection of the deflated lung is kept to a minimum. Large aneurysms that extend proximally require an aortic clamping between the left common carotid and left subclavian artery and repair of the entire descending thoracic aorta.

In these cases, the distal aortic arch is mobilized gently and dissected by dividing the arterial ligament and the left subclavian artery is circumferentially mobilized. Mean aortic pressure should not be above 60 mm Hg during arch manipulation. Preservation of the vagus and left recurrent laryngeal nerves is desirable, if postoperative vocal cord medialization occurs with disabling symptoms, a thyroplasty or polytetrafluoroethylene injection may be required. If a prior left internal mammary arterial bypass graft is present, either a left common carotid to subclavian bypass or a left subclavian to carotid transposition is required to avoid cardiac ischemia when the cross-clamp is applied proximal to the left subclavian artery.

Distal aortic perfusion

Distal aortic perfusion is an effective adjunct in reducing incidence of paraplegia in patients undergoing surgical repair of extensive thoracoabdominal aortic aneurysms (16). The utility of distal aortic perfusion during less invasive repairs such as for DTA is still controversial. Although the “clamp-and-sew” technique has been shown to be a suitable approach to descending thoracic aneurysms repair if performed by experienced Authors, we try to limit its use to emergency cases with hemodynamic instability. We used hypothermic circulatory arrest selectively in cases of challenging proximal aortic clamping

like huge aneurysms or proximal dissections, or as a bailout procedure in case of intraoperative distal arch rupture. Methods of distal aortic perfusion may include passive aortic shunts, partial femoral–femoral cardiopulmonary bypass with or without hypothermia, complete cardiopulmonary bypass, and, as in our series, left heart bypass (LHBP).

Our preferred choice for distal aortic perfusion is the use of a LHBP composed by two cannulas (in and out) connected to a Bio-pump (Biomedicus, Medtronic, Inc., Eden-Prairie, MN) by two hoses. The Bio-Pump is an extracorporeal, cell-preserving centrifugal device that can provide support for circulation during DTA open repair.

The transparent pump housing is shaped like a cone. The pump consists of an acrylic pump head with inlet and outlet ports placed at right angles to each other. The impeller, which is a stack of parallel cones, is driven by an external motor and power console. Rotation of this impeller at high speeds creates a vortex, which drives blood flow in relation to rotational speed. Blood enters through an inlet at the top of the cone and exits via an outlet at the base. The pump can rotate up to 5000 rpm and can provide flow rates of up to 10 litres per minute. The flow generated by the pump has to be regulated on the territory of distribution of the blood, on the rate between the pressure generated by the heart and by the pump itself. The heparin-coated inner surface of the circuit allows to lower systemic heparin administration and to minimize the inflammatory response. Besides, the Bio-Pump allows better platelet preservation and reduced haemolysis.

The aim of the LHBP is:

- support the heart function, particularly in case of underlying heart disease;
- prevent proximal hypertension;
- minimize visceral and spinal cord hypoperfusion;

- reduce the need for pharmacologic intervention to maintain hemodynamic stability during the different steps of surgical procedure;
- keep the cerebrospinal fluid pressure low by enhancing the collateral network.

Left heart bypass is usually achieved from the left superior pulmonary vein to either the left femoral artery or distal descending thoracic aorta. Alternatively to the left superior pulmonary vein, left atrium or distal arch or descending aorta proximally to the aneurysm can be cannulated (*Figure 7*).

Before patient cannulation for left heart bypass, 50 IU/Kg of heparin are administered, distal aortic perfusion is instituted and thoracic aorta is clamped. The bypass flows are targeted toward a value between 1500 and 2500 mL/min in order to maintain a distal arterial pressures of 70 mm Hg. Since the flow of LHBP is not as high as in cardiopulmonary bypass, pediatric cannulas can be used (14 F). This is especially advantageous when distal aortic perfusion must be instituted through small common femoral arteries and/or stenotic iliac vessels. In this cases, smaller cannulas do not occlude the vessels allowing ipsilateral lower limb perfusion during LHBP reducing the risk of femoral and iliac arteries injury and thrombosis.

For the proximal cannulation usually we prefer a 20 F mouldable cannula when we cannulate the left superior pulmonary vein, and a 16-18 F standard cannula for the proximal aortic cannulation. Normally the priming of the circuit is 400 ml. In particular clinical condition (anaemia, dialysis) the priming can be replaced with the patient's autologous blood. Technically, this manoeuvre can condition hemodynamic instability that can be resolved pharmacologically or by homologous blood transfusion.

Among the potential benefits of reducing hepatic, bowel and spinal cord hypoperfusion during aortic clamping, there are decreased risks for postoperative coagulopathy, bacterial translocation, and spinal cord ischemia-reperfusion injury respectively.

Aortic Clamping

During aortic clamping, the importance of cardiovascular stability cannot be overstated and the mean aortic pressure should not be lower than 70 mm Hg in order to reduce the risk of spinal cord ischemia (17). The use of TEE to monitor cardiac changes and to guide hemodynamic management in this critical surgical phase is now widely accepted as a routine monitoring and diagnostic tool in our protocol. This is especially true,

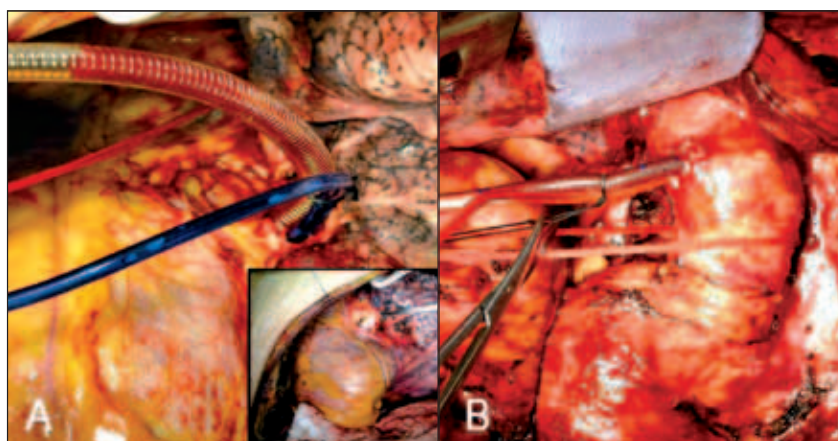


Figure 7 - Intraoperative pictures showing two alternative inflow sites for left heart bypass. A: cannulation of the left superior pulmonary vein is shown. B: cannulation of the proximal descending thoracic aorta. A single purse string suture reinforced with pledgets is generally used to close the breach on vein and a double one on the aorta.

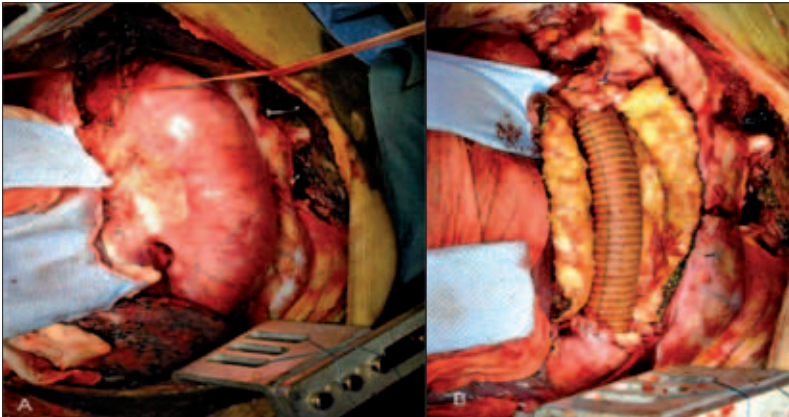


Figure 8 - A) depicts complete isolation of a large aneurysm involving the entire descending aorta right before cross-clamping of the proximal neck between left common carotid and subclavian arteries. B) shows final aortic reconstruction with bypass grafting with a conventional Dacron graft.

during LHBP, in which while below the pump the readout of the flow is available, the only data above the pump, in absence of a TEE evaluation, would be the poor arterial blood pressure monitored through the radial artery and often not completely reliable central venous pressures (see above, section intraoperative patient monitoring and preparation). The patient's temperature is allowed to drift down to a rectal temperature of 32°C to 33°C.

Sequential clamping technique is our preferred choice although is often not feasible due to aneurysm size, quality of aortic wall, and reduced intrathoracic space. In these cases proximal and distal necks are clamped, and the entire aneurysm is longitudinally opened.

In case of dissections, rubber-shod Fogarty aortic clamps are preferred, especially in acute pattern, in order to reduce the clamping-related aortic damage. Possible critical intercostals arteries are always temporarily occluded with 3 or 4 French occlusion-perfusion balloon catheters (Pruitt, Lemaitre Vascular, Inc. Burlington-MA-USA), suturing the other ones with 2-0 pledgeted polypropylene. Proximal aortic neck is transected and circumferentially isolated to reduce the risk of injuring the oesophagus through the aortic wall during proximal aortic anastomosis.

Aortic repair

Historically a collagen- or a gelatin-impregnated woven Dacron graft was used for aortic repair (Figure 8). The proximal anastomosis is usually made with a running suture with 2-0 polypropylene suture, in dissecting lesions, 3-0 or 4-0 sutures are preferred. In the aneurysms involving the distal arch, if left subclavian artery can not be included in a bevelled proximal anastomosis a selective bypass is required.

In case of chronic dissecting aneurysms (Figure 9) the distal clamp is temporarily opened and a distal fenestration is per-

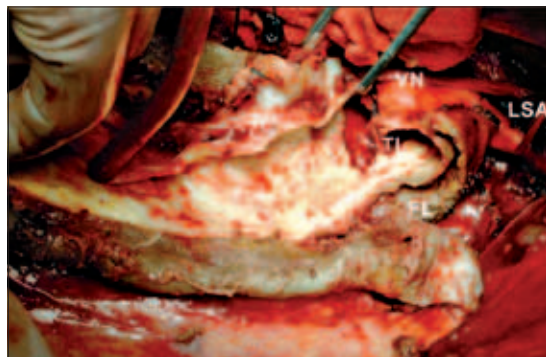

Figure 9 - Surgical treatment of a chronic dissection using deep hypothermic circulatory arrest (note the absence of aortic cross-clamping). The true (TL) and the false lumen (FL) are clearly recognizable. The origin of the left subclavian artery (LSA) and the vagus nerve (VN) are also visible.

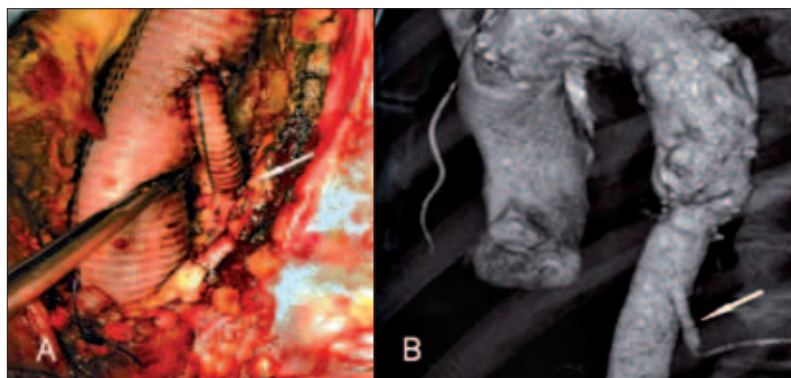


Figure 10 - Surgical picture (A) and postoperative CT (B) showing critical intercostal artery reimplantation (arrow) to the aortic graft by means of single Dacron bypass.

formed before performing distal anastomosis both with the true and false distal aortic lumens. In acute dissection a distal anastomosis only with the true lumen is performed obliterating the false lumen with a suture usually reinforced with 2 strips of Teflon and glue (sandwich technique). After performing distal anastomosis, the thoracic aorta is unclamped and the possible critical intercostals arteries temporarily occluded with balloon catheters are then reattached with a direct reimplantation, either a bypass (*Figure 10*). Usually in dissecting aneurysm intercostals arteries reimplantation is avoided due to the friability of the aortic wall and risk of rupture and bleeding from the reimplanted tissues.

Completion of procedure

Left heart bypass is then discontinued and proximal and distal cannulae are removed. Especially in patients with dissecting aneurysms, detection of visceral organ ischemia immediately after aortic unclamping is a real important task. Femoral pulses and arterial lines are carefully assessed, and renal perfusion is checked by monitoring diuresis after distal clamp removal. In case of significant alterations of metabolic parameters such as blood gases, liver-dependent enzymes, and lactate, liver and bowel perfusion can be controlled directly by an intraoperative laparoscopy.

When a good peripheral perfusion is confirmed, protamine sulphate is administered based to the activated clotting time values. After left heart bypass and especially after long periods of deep hypothermia, achieving hemostasis usually requires prompt administration of agents improving coagulation such as protamine, fresh-frozen plasma, thrombocytes, and, when deficient, concentrates of several coagulation factors. The aneurismal wall is then wapped around the aortic graft with a running suture. Two posterior thoracic drainage tubes are placed prior to closure at the apex and at the base of left pleural cavity prior to closure.

Early postoperative management

The main focus of the immediate postoperative management of these patients in the intensive care unit, is addressed to the early detection of any possible neurological and cardiovascular complication, in order to perform the most prompt as possible prophylactic or therapeutic intervention.

As soon as normal pressure and body temperature are reached, the patient is allowed to wake up. In case of clinical evidence of neurological damage, immediate computed tomography scanning or nuclear magnetic resonance imaging are performed to exclude intracerebral bleeding or spinal cord compression by an intradural hematoma. When a spinal cord ischemia is detected,

mean arterial pressure is maintained above 80 mmHg, spinal fluid is freely drained, and methylprednisolone (1g in bolus, than 4 gr in 24 hours in continuous perfusion) and 18% mannitol (5 mg/kg 4 times/die) are administrated.

If signs of lower limbs, renal or visceral malperfusion develop in the post-operative period, immediate diagnostic measures must be taken to assess organ blood supply and to appropriately plan surgical revascularization procedures. For a precise visualization of visceral organ perfusion, emergency arteriography or angioCT scanning are recommended. In uncomplicated cases, drainage tubes are removed at 36 to 48 hours postoperatively, while the intrathecal catheter of cerebrospinal fluid drainage is usually removed only after 72 hours postoperatively if coagulation parameter and platelets count are normal.

Personal results

Our experience with descending aortic open repair started back in 1993. Since then we have performed a total of 194 surgical procedures in several patterns of disease. A total rate of 54% of procedures was conducted for degenerative aneurysms, 34% for dissections, 12% for other pattern of disease acute and chronic. We used LHBP in the 82% of the cases, clamp-and-sew technique in 16%, hypothermic arrest in 2%

Overall perioperative mortality in open surgery of descending thoracic aorta was 4.1%. The rate of pulmonary complications, i.e. the need for more than 24 hours of mechanical ventilation, was 8.8%. The rate of cardiac complications, i.e. new onset myocardial necrosis demonstrated by positive blood tests, has been 6.2%. The rate of renal complications, (i.e. the need for temporary or permanent haemodialysis) was 7.2%. Cerebrovascular accident, defined as a new neurologic deficit lasting more than

24 hours confirmed by CT/MRI, occurred in 2.0% of patients. The rate of spinal cord ischemia, manifesting either as paraplegia or paraparesis, was 4.6%.

CONCLUSIONS

Mortality and morbidity rates of open TAA repair with a multimodal approach by maximizing organ protection are satisfactory especially in fit patients. In order to define surgical indications and the role of endovascular repair, consideration of the age of the patient, comorbidity, symptoms, life expectancy, likely quality of life (if asymptomatic), aortic diameter, aneurysm morphology, aneurysm extent, suitability of landing zones, and operator experience are all distinctly relevant.

No conflict of interest acknowledged by the authors.

REFERENCES

1. Clouse WD, Hallett JW Jr, Schaff HV, et al. Improved prognosis of thoracic aortic aneurysms: a population-based study. *JAMA* 1998; 280: 1926-1929.
2. Svensson LG, Kouchoukos NT, Miller DC, et al. Expert consensus document on the treatment of descending thoracic aortic disease using endovascular stent-grafts. *Ann Thorac Surg* 2008; 85: S1-S41
3. Erbel R, Alfonso F, Boileau C, et al. Diagnosis and management of aortic dissection. *Eur Heart J* 2001; 22: 1642-1681.
4. Coselli JS. Panel discussion: session III-natural history and dissection. *Ann Thorac Surg* 2007; 83: S84-850.
5. Kieffer E, Chiche L, Cluzel P, et al. Open surgical repair of descending thoracic aortic aneurysms in the endovascular era: a 9-year single-center study. *Ann Vasc Surg* 2009; 23: 60-66.
6. Estrera AL, Miller CC 3rd, Chen EP, et al. Descending thoracic aortic aneurysm repair: 12-year experience using distal aortic perfusion and cerebrospinal fluid drainage. *Ann Thorac Surg* 2005; 80: 1290-1296.
7. Coselli JS, LeMaire SA, Conklin LD, Adams GJ. Left heart bypass during descending thoracic aortic

- aneurysm repair does not reduce the incidence of paraplegia. *Ann Thorac Surg* 2004; 77: 1298-1303.
8. Borst HG, Jurmann M, Bühner B, Laas J. Risk of replacement of descending aorta with a standardized left heart bypass technique. *J Thorac Cardiovasc Surg* 1994; 107: 126-132.
 9. Svensson LG, Crawford ES, Hess KR, et al. Variables predictive of outcome in 832 patients undergoing repairs of the descending thoracic aorta. *Chest* 1993; 104: 1248-1253.
 10. Verdant A. Descending thoracic aortic aneurysms: surgical treatment with the Gott shunt. *Can J. Surg.* 1992; 35: 493-496.
 11. Fehrenbacher JW, Hart DW, Huddleston E, et al. Optimal end-organ protection for thoracic and thoracoabdominal aortic aneurysm repair using deep hypothermic circulatory arrest. *Ann Thorac Surg.* 2007; 83: 1041-1046.
 12. Isma'eel H, Hamirani YS, Mehrinfar R, et al. Optimal phase for coronary interpretations and correlation of ejection fraction using late-diastole and end-diastole imaging in cardiac computed tomography angiography: implications for prospective triggering. *Int J Cardiovasc Imaging* 2009; 25: 739-749.
 13. National Kidney Foundation. K/DOQI clinical practice guidelines for chronic kidney disease: evaluation, classification and stratification. *Am J Kidney Dis* 2002;39:S1-S266.
 14. Marrocco-Trischitta MM, Melissano G, Kahlberg A, et al. Chronic kidney disease classification stratifies mortality risk after elective stent graft repair of the thoracic aorta. *J Vasc Surg* 2009; 49: 296-301.
 15. Coselli JS, Lemaire SA, Köksoy C, et al. Cerebrospinal fluid drainage reduces paraplegia after thoracoabdominal aortic aneurysm repair: results of a randomized clinical trial. *J Vasc Surg* 2002; 35: 631-639.
 16. Coselli JS, LeMaire SA. Left heart bypass reduces paraplegia rates following thoracoabdominal aortic aneurysm repair. *Ann Thorac Surg* 1999; 67: 1931-1934.
 17. Chiesa R, Melissano G, Marrocco-Trischitta MM, et al. Spinal cord ischemia after elective stent-graft repair of the thoracic aorta. *J Vasc Surg* 2005; 42: 11-17.