



Case report

Can acute radiculopathy be caused by upper lumbar hemorrhagic synovial cyst spinal compression in the elderly?

Wongthawat Liawrungrueang^a, Choksuphan Deevijit^b, Torphong Bunmaprasert^{a,*}

^a Department of Orthopaedics, Faculty of Medicine, Chiang Mai University, Chiang Mai 50200, Thailand

^b Bangkok Hospital Chiang Mai, Muang Chiang Mai, Chiang Mai 50000, Thailand

ARTICLE INFO

Keywords:

Intracyst hemorrhage
Synovial cyst
Spinal nerve compression
Acute radicular pain

ABSTRACT

Introduction and importance: Acute radiculopathy caused by upper lumbar synovial cysts is rare. They generally present with a slow development of symptoms resulting from spinal canal involvement. Intracyst hemorrhagic synovial cysts are extremely uncommon and can manifest as radicular pain, radiculopathy or even cauda equina compression syndrome.

Case presentation: A 71-year-old woman with acute back and radicular leg pain presented with worsening symptoms after receiving 1 week of therapy to the left lower limb without trauma. Magnetic resonance imaging (MRI) showed a hemorrhagic synovial intracyst at L2-L3 on the front of the left inter-facet joint which was identified as the cause of the acute back pain and radiculopathy which required surgical removal. Post-surgery, the patient followed the rehabilitation program instructions and attended all scheduled follow-up visits. The patient was asymptomatic at the one-year follow-up.

Clinical discussion: Synovial cysts are commonly associated with degenerative changes that occur with aging, although the specific cause is unknown. Surgical removal of an upper lumbar synovial cyst gives better results than non-surgical treatments if the symptoms persist or recurrent.

Conclusion: For recurrent symptomatic upper lumbar spine synovial cysts (L2–L3), surgery is usually the best option. Surgical removal of an upper lumbar synovial cyst can result in full relief of acute symptoms and reduction of neurologic deficits.

1. Introduction and importance

Although the pathophysiology of lumbar cysts is still debated, they are often link to degenerative alterations in the facet joint and can result in back pain and radiculopathy. Although there have been a few documented instances in the cervical and thoracic spines, the majority of cysts are located in the lumbar area, primarily around L4-L5, as the lumbar spine moves more and is more prone to instability [1]. However, the cysts located at the upper lumbar synovial facet are uncommon. Only a few cases, associated with acute intracyst bleeding, have been reported [2]. Intracyst bleeding is likely to cause significant nerve root compression, which would explain the patients' acute symptoms [2].

The standard treatment for lumbar synovial cysts and associated intracystic hemorrhage is surgical excision with decompression [2,3]. In certain circumstances, acute symptoms necessitate immediate surgery. Even if the procedure is done without delay, some individuals still have a neurological disability [3]. We present a case of acute radiculopathy

caused by a synovial cyst associated with an intracyst hemorrhage at the upper lumbar spine (L2-L3), adjacent to the left inter-facet joint, in an elderly patient which required surgical resection. The patient's written informed consent was obtained for the publication of this case report and accompanying images. A copy of the written consent is available for review from the Editor-in Chief of this journal upon request. This work has been reported in accordance with the SCARE 2020 guidelines [4].

2. Case presentation

A 71-year-old woman with acute back and radicular leg pain presented with worsening pain after 1 week of therapy to the left lower limb without trauma. She had no history of underlying disease. The patient did not smoke, drink alcohol, or use recreational drugs. A physical examination revealed that initial vital signs and mental status were normal. She had no upper extremity or lower extremity weakness (gr. V). Upper and lower extremity deep tendon reflexes were found to be

* Corresponding author.

E-mail addresses: choksuphan.de@bangkokhospital-chiangmai.com (C. Deevijit), torpong197@gmail.com (T. Bunmaprasert).

<https://doi.org/10.1016/j.ijscr.2022.107002>

Received 2 March 2022; Received in revised form 27 March 2022; Accepted 27 March 2022

Available online 29 March 2022

2210-2612/© 2022 The Authors. Published by Elsevier Ltd on behalf of IJS Publishing Group Ltd. This is an open access article under the CC BY-NC-ND license (<http://creativecommons.org/licenses/by-nc-nd/4.0/>).

normal. She reported painful side and limited rotational movement of the lumbar spine. In addition to generalized degenerative spondyloarthropathy, magnetic resonance imaging (MRI) of the lumbar spine revealed a significant synovial cyst at L2-L3, causing narrowing of the vertebral canal and compression of the dural sac and the lateral recess of the left root at L3 (Fig. 1). Based on that, L2-L3 laminectomy and cyst excision under general anesthesia was selected. The patient was placed in the prone position for posterior surgical approach. Intra-operative findings included dark-brown tissue admixed with bone measuring $2.8 \times 2.5 \times 0.5$ cm in aggregates which was discovered at L2-L3 (Fig. 2). The L2-L3 laminectomy and cyst excision were done by an experienced spine surgeon (TB). The diagnosis of a synovial cyst with bleeding was confirmed by pathological examination (Fig. 3). Pathology reported sections showed segments of fibrous tissue and some bony trabeculae. Papillae-like structures were seen, suggestive of synovium (Fig. 3A). Aggregates of hemosiderin were observed (Fig. 3B), indicating remote hemorrhage. There was no evidence of inflammation. There were no visible granulomas and no tumor was found. The patient had no post-operative complications and was discharged after completing a gait and balance training program. The patient followed the rehabilitation program instructions and attended all planned follow-up visits. The patient was asymptomatic at the one-year follow-up. The patient was highly satisfied with this treatment and can now activity daily living normally again.

3. Clinical discussion

Synovial cysts, also known as ganglion cysts, are most commonly seen in the joints of the extremities [5]. A soft tissue mass situated extradurally along the medial border of a deteriorated facet joint, particularly at the L4–5 level, is known as a spinal synovial cyst [6,7]. Kao and coworkers in 1974 [8] used the term “Juxtafacet cyst” to characterize synovial and ganglion cysts in the extradural region of the spine. These cysts have a synovial-like epithelial lining, a detectable link to the joint capsule and are filled with clear or xanthochromic fluid. A cyst is classified as ganglionic if there is no synovial cell lining or contact with the joint capsule [1,6]. Synovial cysts in the capsule of the lumbar zygapophysial joint can cause symptoms that are similar to those of an extradural space-occupying lesion [5,6]. Intraspinous synovial cysts are uncommon, although they are becoming more commonly reported as neuroradiological imaging technology improves. MRI is considered to be an excellent diagnostic tool. On MRI, the cysts appear as well-circumscribed epidural mass lesions with hypo- and hyper-intense T1 and T2 weighted images, respectively [3]. Synovial cysts, on the other

hand, are associated with intracyst hemorrhage, and the MRI reveals a cystic mass with T1 hyperintensity and T2 hypointensity at L2-L3.

For patients presenting with progressive back pain and radicular symptoms, symptomatic lumbar facet cysts should be considered in the differential diagnosis. Disc herniation and spinal stenosis symptoms are often identical. Facet cysts are more likely to occur in individuals who have severe facet degeneration and instability. A previous study by Eck et al. [9] described a case of a hemorrhagic synovial cyst at L3 that had developed as a result of anticoagulant medication. Other than a significant synovial facet cyst, that patient presented with low back and radicular symptoms. A significant facet cyst compressing the thecal sac and L3 exiting nerve root was detected on MRI as well. Our patient, on the other hand, had no history of anticoagulant medication and no underlying hematologic disorder, suggesting a diagnosis of synovial cysts at L2-L3 related to spontaneous intracyst bleeding or hemorrhaging.

Synovial cysts are treated using a combination of conservative and/or surgical methods. Synovial cysts of the spine have no known natural history [3,7]. Cysts can be reduced and/or can resolve spontaneously with rest and immobility [7]. Percutaneous aspiration is sometimes used to treat non-hemorrhagic synovial cysts, which can result in symptomatic relief. Corticosteroid injections into the facet joint are another treatment option. The main non-surgical therapies reported in the literature are percutaneous techniques such as cyst aspiration, injection, and/or rupture. The success rates range from 20% to 75%, and around half of the patients get considerable relief from these non-surgical interventions [10].

Surgical excision with decompression is the current standard treatment for lumbar synovial cysts or hemorrhagic synovial cysts [1,10]. Acute symptoms may necessitate immediate surgery in some circumstances. Even when the procedure is done without delay, some individuals nevertheless continue to have a neurological disability [1,3,6]. In general, however, early diagnosis and a suitable surgical strategy can lead to good outcomes. We reported on an effective outcome following surgical treatment of a patient with a left L2-L3 facet synovial cyst which had caused acute back pain and radiculopathy. The cyst was resected and evacuated, resulting in total neurological recovery.

4. Conclusion

Acute radicular pain can be caused by a synovial cyst in the upper lumbar spine with or without an associated hemorrhagic intracyst, although such cases are rare. Spontaneous or degenerative conditions as well as other unknown causes can potentially combine to result in hemorrhagic metamorphosis of these cysts. For symptomatic upper

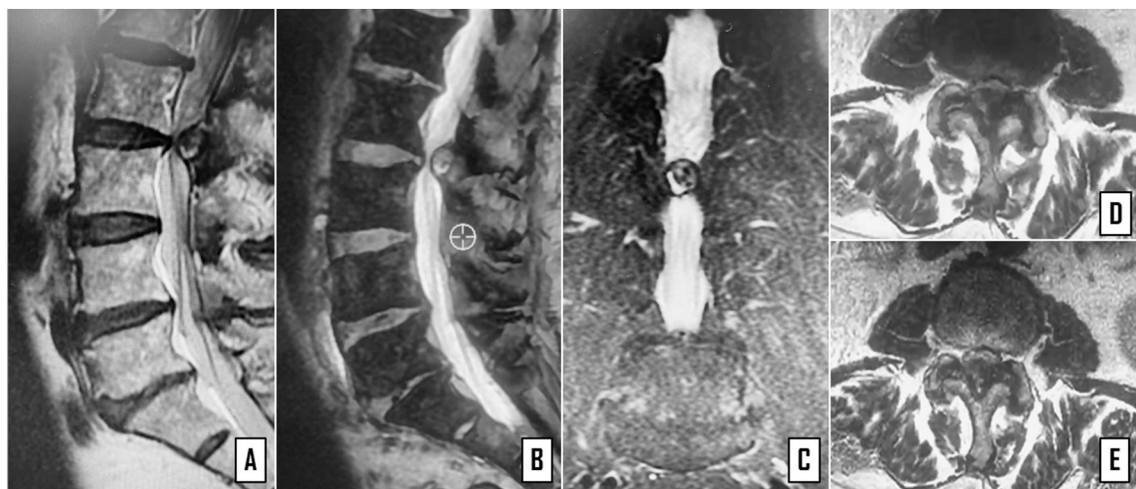


Fig. 1. Magnetic resonance imaging (MRI) showed a heterogeneous intraspinal and extradural mass adjacent to the inter-apophyseal joint in sagittal view (A, B) and in axial view (C) with radicular and dural compression (D, E) at L2-L3 of the lumbar spine.

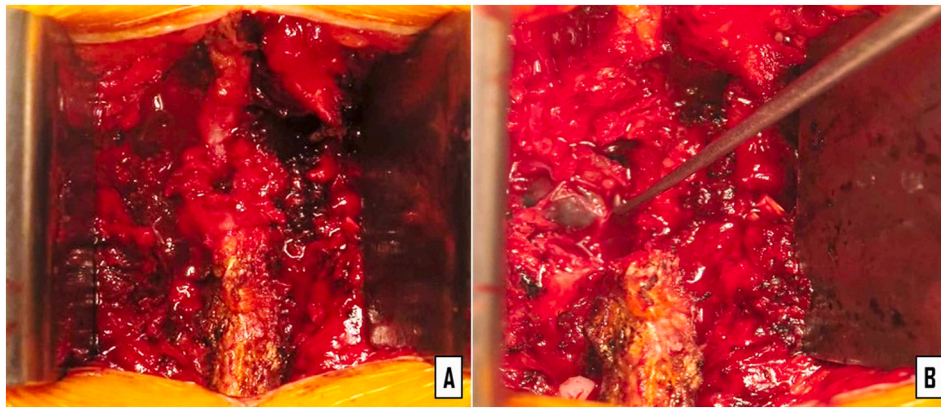


Fig. 2. An extradural hemorrhagic cyst compressing the dura mater (A) at L2-L3 was removed via laminectomy and cyst excision (B).

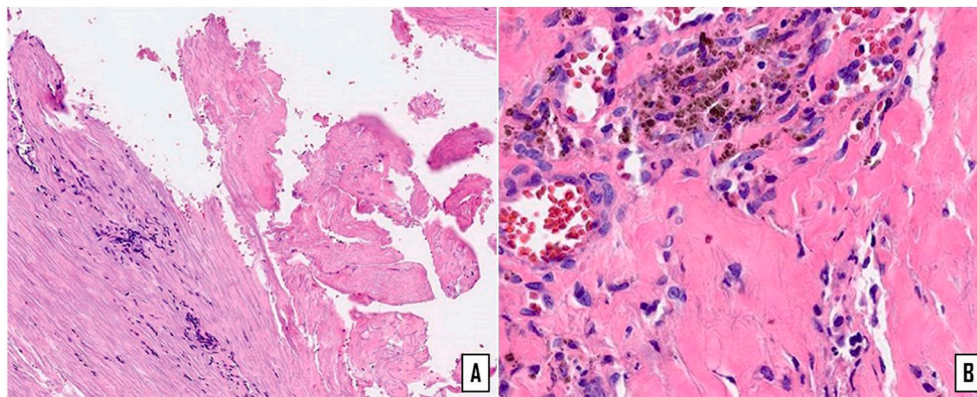


Fig. 3. Microscopic view (H&E stain) of the cyst structure of fibrous walls lined by flat synovial epithelium, suggestive of a hemorrhagic synovial cyst (A) and aggregates of hemosiderin (hemorrhagic area) (B).

lumbar spine synovial cysts (L2-L3), surgery is usually the best option for recurrent or persistent symptoms. Removal of an upper lumbar synovial cyst during surgery can result in full relief of acute symptoms and of neurologic deficits.

Provenance and peer review

Not commissioned, externally peer-reviewed.

Ethical approval

This case report was approved by the Institutional Review Board, Faculty of Medicine, Chiang Mai University.

Source of funding

Funding for this research was provided by the Faculty of Medicine, Chiang Mai University, Chiang Mai, Thailand. The funders had no role in the study design, data collection and analysis, decision to publish or preparation of the manuscript.

Consent

Written informed consent was obtained from the patient for publication of this case report and accompanying images. A copy of the written consent is available for review from the Editor-in Chief of this journal upon request.

Registration of research studies

None.

Guarantor

Torphong Bunmaprasert, MD., Associate Professor.

CRediT authorship contribution statement

Wongthawat Liawrungueang (WL): Writing original draft, review of literature, conceptualization, methodology, artwork design and writing-original draft.

Choksuphan Deevijit (CD): Writing original draft, review of literature and data analysis.

Torphong Bunmaprasert (TB): Supervision, data curation, writing - review & editing and revision the final version for publication.

Declaration of competing interest

The authors declare that they have no competing interests.

Acknowledgments

The authors would like to express their sincere thanks to Dr. G. Lamar Robert, Ph.D., and Assoc. Prof. Dr. Chongchit Sripun Robert, Ph. D., for editing the English manuscript. We would also like to express our thanks to Department of Orthopaedics, Faculty of Medicine, Chiang Mai University for their support.

References

- [1] M.K. Lyons, J.L. Atkinson, R.E. Wharen, H.G. Deen, R.S. Zimmerman, S.M. Lemens, Surgical evaluation and management of lumbar synovial cysts: the Mayo Clinic experience, *J. Neurosurg.* 93 (2000) 53–57, <https://doi.org/10.3171/spi.2000.93.1.0053>.
- [2] K. Kaneko, Y. Inoue, Haemorrhagic lumbar synovial cyst. A cause of acute radiculopathy, *J. Bone Joint Surg. Br.* 82 (2000) 583–584, <https://doi.org/10.1302/0301-620x.82b4.10444>.
- [3] H.S. Park, H.B. Sim, S.C. Kwon, J.B. Park, Hemorrhagic lumbar synovial cyst, *J. Korean Neurosurg. Soc.* 52 (2012) 567–569, <https://doi.org/10.3340/jkns.2012.52.6.567>.
- [4] R.A. Agha, T. Franchi, C. Sohrabi, G. Mathew, A. Kerwan, SCARE Group, The SCARE 2020 guideline: updating consensus Surgical CAse REport (SCARE) guidelines, *Int. J. Surg.* 84 (2020) 226–230, <https://doi.org/10.1016/j.ijsu.2020.10.034>.
- [5] R.J. Spinner, H. Wang, The first described joint-associated intraneural ganglion cyst, *Neurosurgery* 69 (2011) 1291–1298, <https://doi.org/10.1227/NEU.0b013e3182237299>.
- [6] T.D. Kjerulf, D.W. Terry, R.J. Boubelik, Lumbar synovial or ganglion cysts, *Neurosurgery* 19 (1986) 415–420, <https://doi.org/10.1227/00006123-198609000-00013>.
- [7] B.M. Onofrio, A.D. Mih, Synovial cysts of the spine, *Neurosurgery* 22 (1988) 642–647, <https://doi.org/10.1227/00006123-198804000-00004>.
- [8] C.C. Kao, S.S. Winkler, J.H. Turner, Synovial cyst of spinal facet. Case report, *J. Neurosurg.* 41 (1974) 372–376, <https://doi.org/10.3171/jns.1974.41.3.0372>.
- [9] J.C. Eck, S.J. Triantafyllou, Hemorrhagic lumbar synovial facet cyst secondary to anticoagulation therapy, *Spine J.* 5 (2005) 451–453, <https://doi.org/10.1016/j.spinee.2005.01.005>.
- [10] M. Machino, Y. Yukawa, K. Ito, S. Kanbara, F. Kato, Spontaneous hemorrhage in an upper lumbar synovial cyst causing subacute cauda equina syndrome, *Orthopedics* 35 (2012) e1457–e1460, <https://doi.org/10.3928/01477447-20120822-41>.