



CASE SERIES

# Lichen Planopilaris Responsive to a Novel Phytoactive Botanical Treatment: A Case Series

Sanusi Umar · Petrina Kan · Marissa J. Carter ·

Paul Shitabata · Myroslava Novosilska

Received: April 6, 2022 / Accepted: May 17, 2022 / Published online: June 8, 2022  
© The Author(s) 2022

## ABSTRACT

**Introduction:** Lichen planopilaris (LPP) is characterized by chronic scarring alopecia that is progressive and typically refractory to therapy. Current drug treatments are suboptimal and not applicable for long-term use because of the high potential for adverse effects,

warranting safer and more effective treatment alternatives.

**Methods:** Based on our previous success in treating a patient with central centrifugal cicatricial alopecia using a topical botanical formulation (Gashee), we reviewed records of four patients with biopsy-proven LPP treated with the topical formulation alone or in combination with its oral preparation. Three patients had failed previous treatment with intralesional steroid injections, topical minoxidil, tacrolimus, and clobetasol. Physical examination and photographic documentation were also used as outcome measures. Treatment duration with the botanical formulations ranged from 6 weeks to 9.5 months.

**Results:** All patients showed overall improvement in surrogate indicators of LPP activity as evidenced by the disappearance of symptoms (pruritus, tenderness, scalp irritation, and hair shedding), improvement in hair growth, and reduction in redness. All reported a high satisfaction level and no adverse effects.

**Conclusions:** Patients with treatment-refractory LPP responded to a novel botanical treatment. To the best of our knowledge, this is the first published report of LPP responding to a plant-based natural treatment. Further evaluation of this treatment in a controlled trial with a larger number of patients is warranted.

---

S. Umar (✉) · P. Shitabata  
Department of Medicine, University of California at  
Los Angeles, Los Angeles, CA, USA  
e-mail: drumar@dru.com

S. Umar · P. Shitabata  
Division of Dermatology, Department of Medicine,  
Harbor-UCLA Medical Center, Torrance, CA, USA

S. Umar  
Dr. U Hair and Skin Clinic, 2121 N. Sepulveda  
Avenue, Suite 200, Manhattan Beach, CA 90266,  
USA

P. Kan  
Department of Molecular Biology, University of  
California at Los Angeles, Los Angeles, CA, USA

M. J. Carter  
Strategic Solutions, Inc., Bozeman, MT, USA

P. Shitabata  
Dermatopathology Institute, Torrance, CA, USA

M. Novosilska  
Department of Dermatology and Oncology,  
Aesthetic Medical Clinic Myroslava Novosilska,  
Lviv, Ukraine

## PLAIN LANGUAGE SUMMARY

Lichen planopilaris is a chronic and progressive condition, most commonly affecting middle-aged women. It results in scalp inflammation, scarring, and ultimately permanent hair loss. Treatments are typically ineffective in the long term and are associated with side effects that limit their use. We report success in treating four patients using a new botanical formulation called Dr. UGro Gashee as the sole therapy for a duration ranging from 6 weeks to 9.5 months. The treatment was administered topically or in combination with its oral formulation. All the patients showed cessation of disease progression with significant hair regrowth. They also reported complete resolution of scalp itch, tenderness, and irritation, with no adverse effects. Our report is the first published study of lichen planopilaris responding to a plant-based natural treatment and warrants further evaluation in larger controlled trials.

**Keywords:** Botanical; Central centrifugal cicatricial alopecia; Cosmeceutical; Fibrosing alopecia in patterned distribution; Frontal fibrosing alopecia; Hair loss; Natural treatment; Nutraceutical; Phytoactive; Scarring alopecia

### Key Summary Points

Lichen planopilaris (LPP) is a rare chronic unremitting condition with permanent hair loss.

The current treatments are suboptimal and unsuitable for long-term use because of adverse effects.

Four cases of classical LPP, of which two were refractory to previous therapies, are described.

The patients were successfully treated with a novel botanical formulation, named Dr. UGro Gashee, as a sole therapy.

The roles of three main phytoactive ingredients in the formulation in targeting pathophysiological mechanisms responsible for LPP are discussed.

## INTRODUCTION

Lichen planopilaris (LPP), believed to be a variant of lichen planus, is a chronic, smoldering, and progressive scarring alopecia characterized by hair loss, fibrosis, and inflammation. Pruritus, tenderness, and burning of the scalp are often associated symptoms. Although LPP affects both men and women, it is more prevalent in women aged 30–60 years [1]. Inflammation in LPP is mainly lymphocytic and confined to the isthmus and infundibular levels of the perifollicular and interfollicular dermis; this pathobiology represents a cell-mediated autoimmune attack of the hair bulge likely caused by the loss of hair follicle immune privilege (HFIP) [2].

Although a standard treatment for LPP has not been defined, the most common treatment regimen involves topical/intralesional high-potency steroids and oral hydroxychloroquine. Treatments with tetracyclines, pioglitazone, isotretinoin, cyclosporine, mycophenolate mofetil, methotrexate, calcineurin inhibitors, systemic steroids [1], and naltrexone [3] have also been reported. Combinations of some of the treatments mentioned above with procedures, such as low-level light therapy [4] or platelet-rich plasma (PRP) [5], have been reported as therapeutic approaches. These approaches are suboptimal, as is evident from the variable and often contradictory results [1]. Furthermore, a high potential for adverse effects makes these treatments unsuitable for long-term use. Without effective treatment, LPP typically results in an unrelenting course, affecting wider areas of the scalp with erythema and white perifollicular keratotic casts. The end results include smooth, shiny atrophic scarred plaques devoid of follicular ostia and indicative of scarring permanent hair loss. There is an

unmet need for effective and safe treatments for this chronic condition.

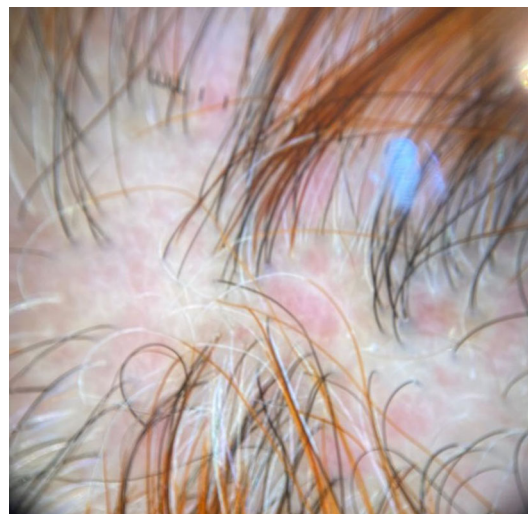
Gashee contains a proprietary formulation of at least 12 phytoactive ingredients designed to modulate multiple biological pathways that cause hair loss favorably. We retrospectively reviewed records of patients with histologically proven LPP treated with topical Gashee lotion (cosmeceutical) alone or in combination with oral Gashee supplements (nutraceutical). Here, we report four patients with classical LPP treated exclusively with Gashee botanical formulations using the topical form alone or in combination with the oral form.

## CASE PRESENTATIONS

All patients provided written consent to publish the data and images in this report. Approval from an Institutional Review Board was not required, given the retrospective description of clinical findings in routine care of the patients.

### Patient 1

A 56-year-old white Hispanic woman had a 10-year duration of progressive hair loss and a paternal family history of hair loss. She reported intermittent scalp irritation, pruritus, and hair shedding. Examination revealed atrophic scarring and hair loss, extending across the vertex, mid-scalp, and frontal regions of the head. Follicular erythema and areas of perifollicular casting were visible on trichoscopy. The patient had a history of frequent use of hair dyes, blow dryers, and curling irons on her hair. Trichoscopy revealed perifollicular scaling and erythema (Fig. 1). A biopsy obtained from the mid-frontal scalp showed histological features consistent with LPP. Several years of treatment with intralesional triamcinolone 5–10 mg/cc, 5% minoxidil foam, and clobetasol 0.05% ointment were suboptimal. After the patient discontinued all previous treatments, twice daily use of topical Gashee lotion combined with four daily capsules of Gashee oral supplements was started. She continued her usual routine of dyeing, blow-drying, and curling hair. Reduced erythema, new hair growth, and



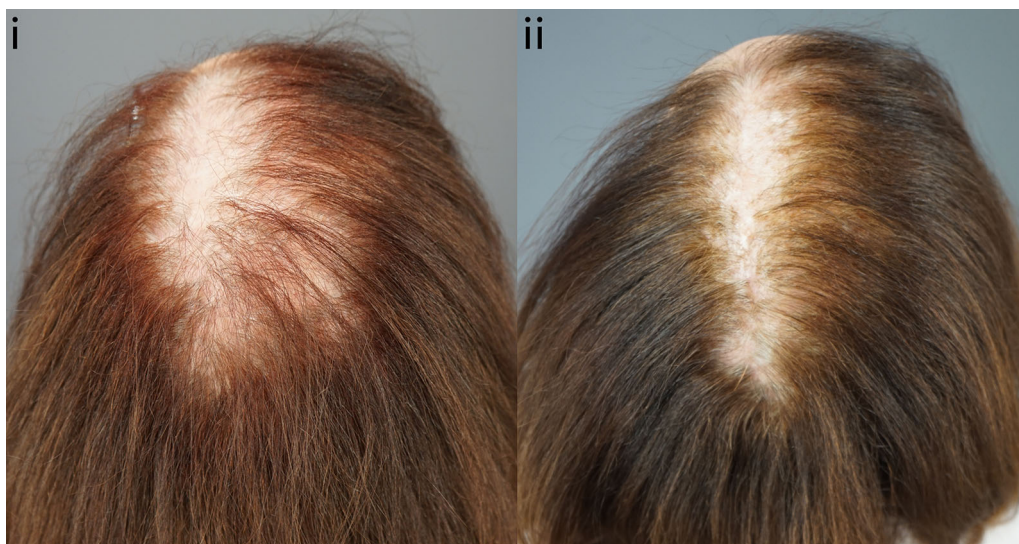
**Fig. 1** Trichoscopy image of patient 1. Trichoscopic image of a patient diagnosed with lichen planopilaris, showing perifollicular casts and erythema

increased coverage of the affected regions of the head were observed after 5 months of treatment (Figs. 2 and 3). The patient reported complete cessation of hair shedding and all the symptoms and had no adverse effects. Owing to supply issues, she discontinued the oral Gashee. However, she continued to experience continuing growth and absence of symptoms at 7 months of follow-up using only topical Gashee (Fig. 4).

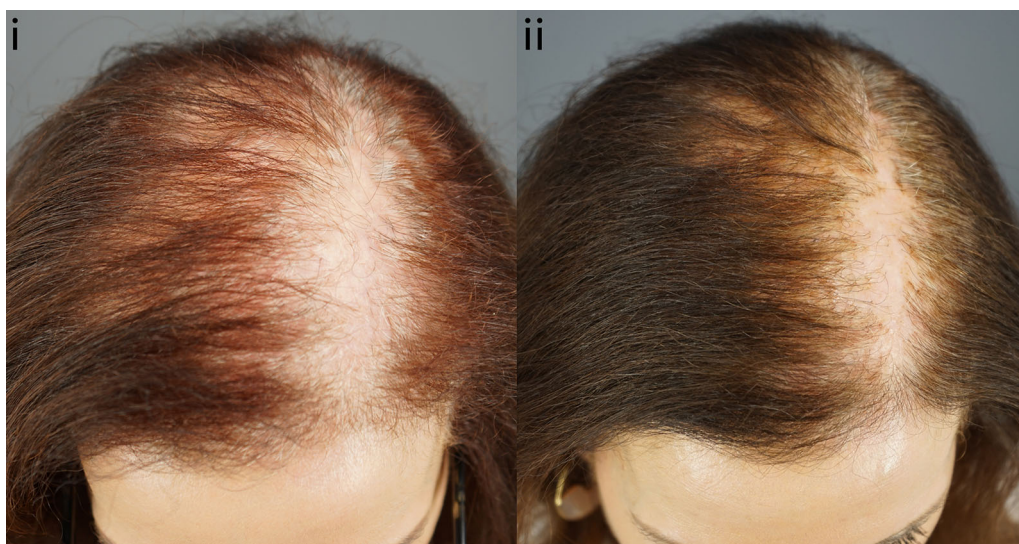### Patient 2

A 54-year-old African American woman had a 2-year duration of hair loss, visible hair shedding, and scalp irritation and pruritus. Examination revealed areas of thinning hairline in the frontal and temporal regions. Trichoscopy showed perifollicular casts and erythema (Fig. 5). The patient had not tried any previous hair loss treatment. A biopsy showed histological findings consistent with LPP. Twice daily use of the topical Gashee formulation in combination with four daily capsules of Gashee oral supplements was implemented. A reduction in erythema and significantly increased hair coverage were observed in the temple areas of the head after 6 weeks of treatment (Figs. 6 and 7). The patient reported a cessation of all the symptoms and had no adverse effects.





**Fig. 2** Frontal and mid-scalp regions of patient 1. Images of the frontal and mid-scalp regions of a patient diagnosed with lichen planopilaris, obtained before (i) and after (ii) 5 months of treatment with Gashee lotion and oral supplements



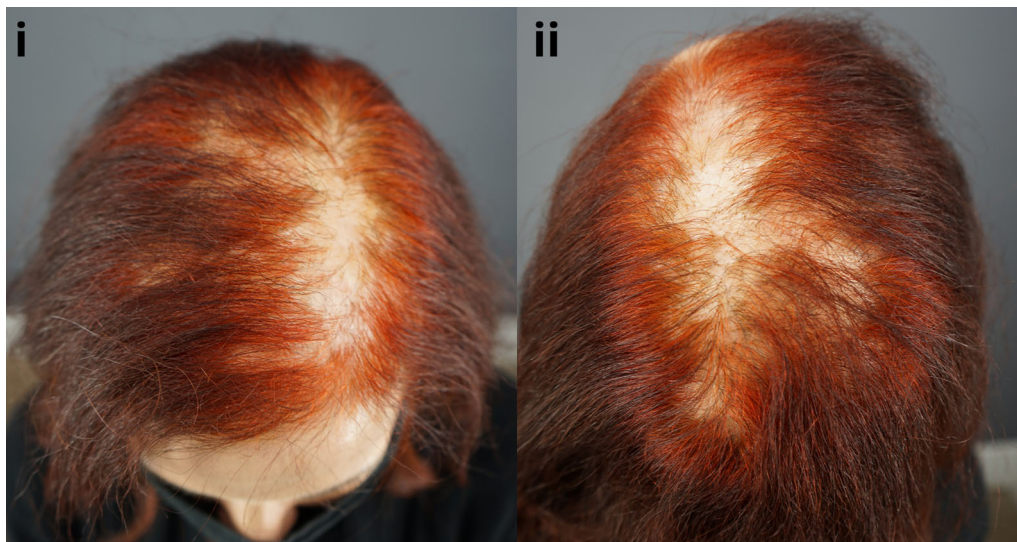
**Fig. 3** Frontal to crown regions of patient 1. Images of the frontal region extending to the crown of the head of a patient diagnosed with lichen planopilaris, obtained before

(i) and after (ii) 5 months of treatment with Gashee lotion and oral supplements

### Patient 3

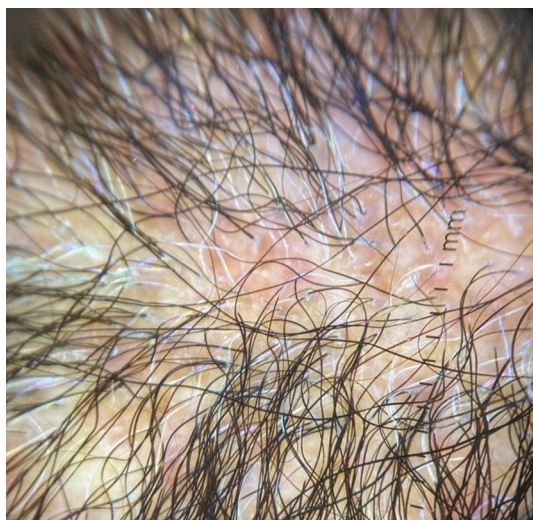
Patient 3 was a 38-year-old white female with a 10-month history of hair loss, severe itch, irritation, redness, and hair shedding. Examination revealed erythema, atrophic plaques, and visible thinning in the frontal, mid-scalp, and vertex areas. She had been treated with triamcinolone

acetonide 40 mg/cc scalp for 4 months and had used tacrolimus 0.1% ointment twice daily. She discontinued all treatments 6 months prior to presentation due to a lack of improvement. A biopsy revealed features of LPP, and she was started on topical Gashee, which she initially used once a day for a month. She experienced some irritation at the application site,



**Fig. 4** Frontal. Mid-scalp and crown regions of patient 1. Images of the frontal and mid-scalp (i) and the frontal region extending to the crown of the head (ii) of patient 1,

at 7 months after stopping Oral gashee and using topical Gashee as a sole treatment



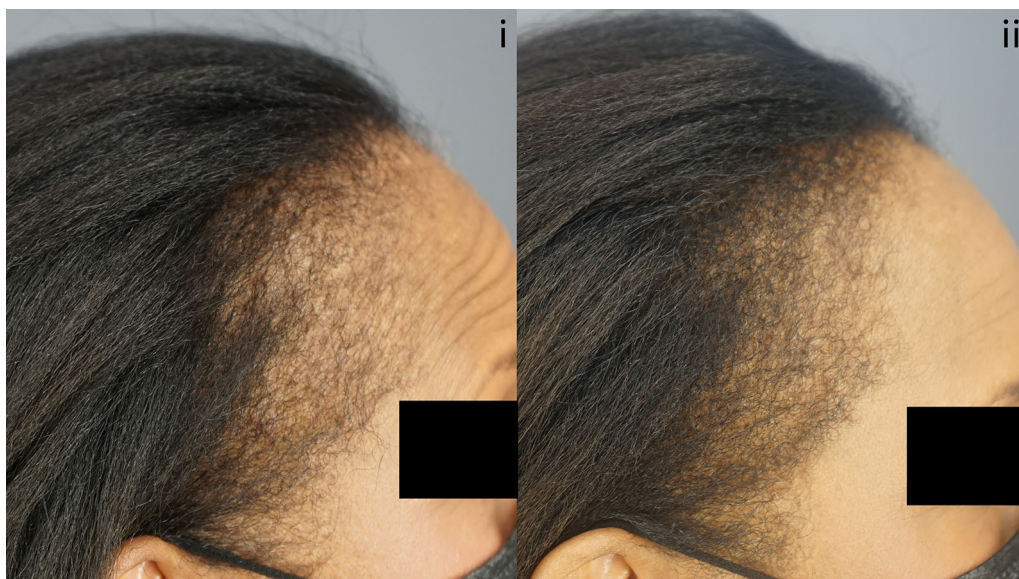**Fig. 5** Trichoscopy image of patient 2. Trichoscopic image of a patient diagnosed with lichen planopilaris, showing perifollicular casts and erythema

prompting her to revert to a once every other day regimen that led to the resolution of the irritation. Within 6 weeks of usage, all LPP symptoms had resolved. At 4 months, she showed complete resolution of erythema, and evidence of significant hair regrowth (Figs. 8 and 9), without adverse effects.

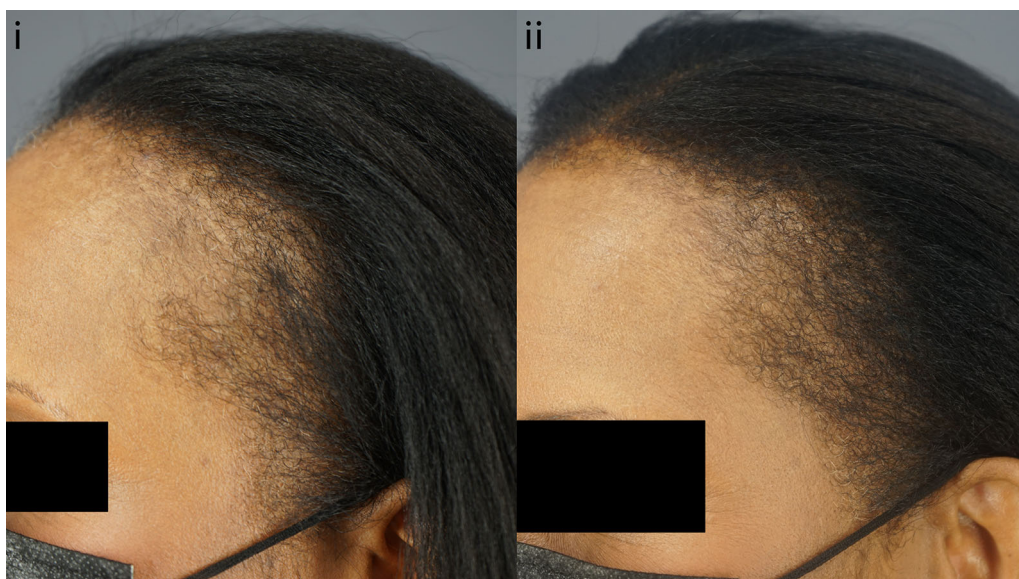**Patient 4**

A 29-year-old African American male had acne keloidalis nuchae (AKN) in the nuchal area and scalp-wide hyperpigmented atrophic plaques affecting most of the remaining scalp with progressive miniaturization and loss of hair follicles. The scalp was swollen and chaffed. He had symptoms of hair shedding, pruritus, and scalp irritation. Trichoscopy revealed perifollicular casts and erythema, combined with hyperpigmentation of interfollicular spaces (Fig. 10). A biopsy of these lesions confirmed LPP. The disease progressed despite treatment with intralesional steroid triamcinolone 5 mg/cc injections and topical betamethasone 0.05% solution. A regimen of twice-daily use of the topical Gashee formulation was started. The patient noted the resolution of all the symptoms. On examination, his scalp was supple and uninflamed. There was thickening and lengthening of hair, resulting in areas of new hair growth and cessation of disease progression within 3 months. The improvement was sustained at the last observation, at 7 months follow-up (Figs. 11 and 12). A repeat biopsy taken from a region adjacent to the previous one revealed less number of inflammatory cells and





**Fig. 6** Left temporal region of patient 2. Images of the left temporal region of a patient diagnosed with lichen planopilaris, obtained before (i) and after (ii) 6 weeks of treatment with Gashee lotion and oral supplements



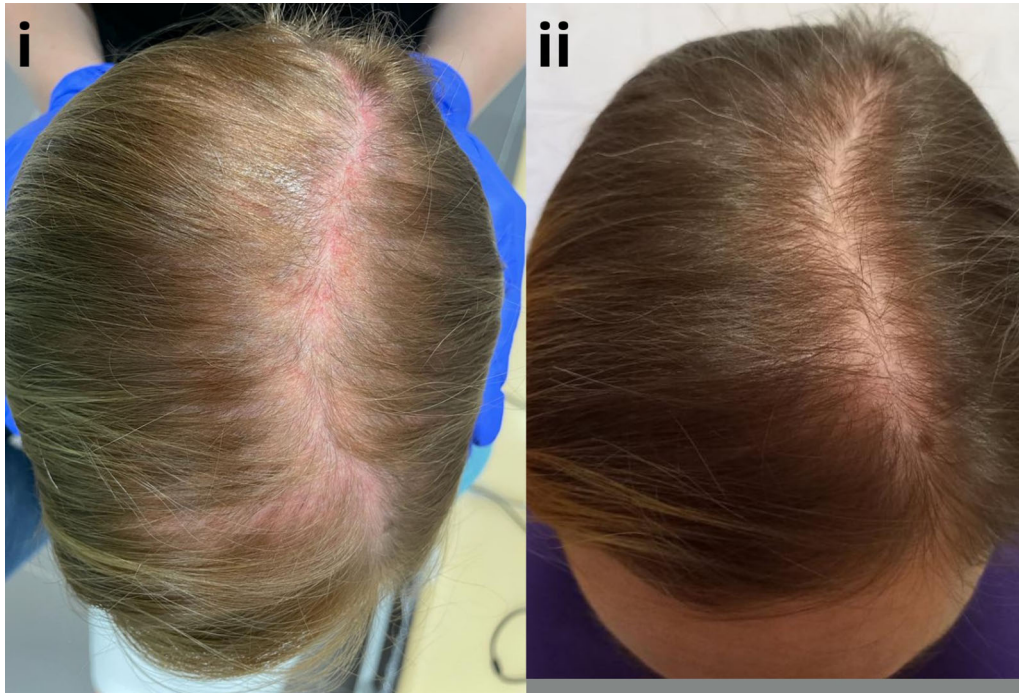
**Fig. 7** Right temporal region of patient 2. Images of the right temporal region of a patient diagnosed with lichen planopilaris, obtained before (i) and after (ii) 6 weeks of treatment with Gashee lotion and oral supplements

more follicular activity associated with an increased number of adipocytes (Figs. 13 and 14). The patient reported no adverse effects.

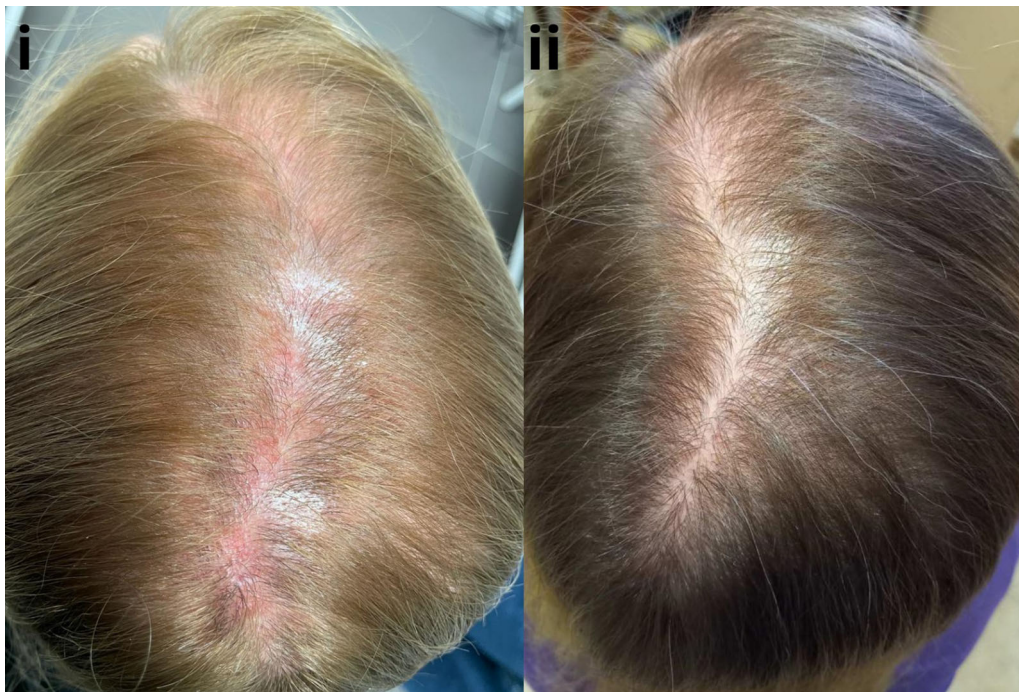## DISCUSSION

In this report, we focused on patients diagnosed with classical LPP and excluded patients diagnosed with frontal fibrosing alopecia (FFA) or fibrosing alopecia in patterned distribution

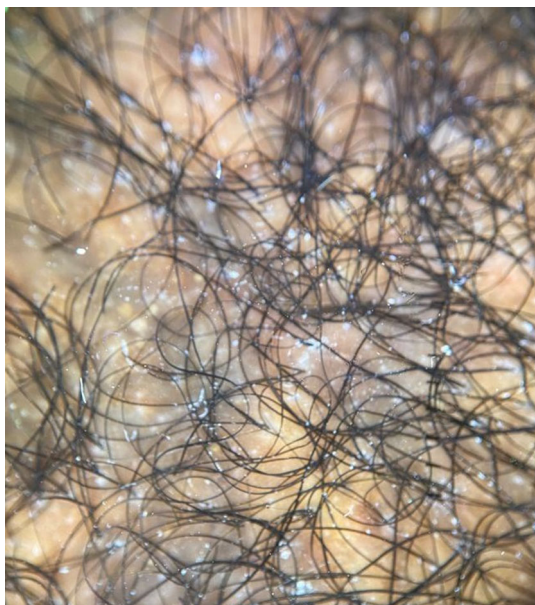



**Fig. 8** Top of head and vertex viewed from the back of patient 3. Images of the top of the head and vertex of a patient diagnosed with lichen planopilaris, obtained before (i) and after (ii) 4 months of treatment with Gashee lotion



**Fig. 9** Top of head and vertex viewed from the front of patient 3. Images of the top of the head and vertex of a patient diagnosed with lichen planopilaris, obtained before (i) and after (ii) 4 months of treatment with Gashee lotion

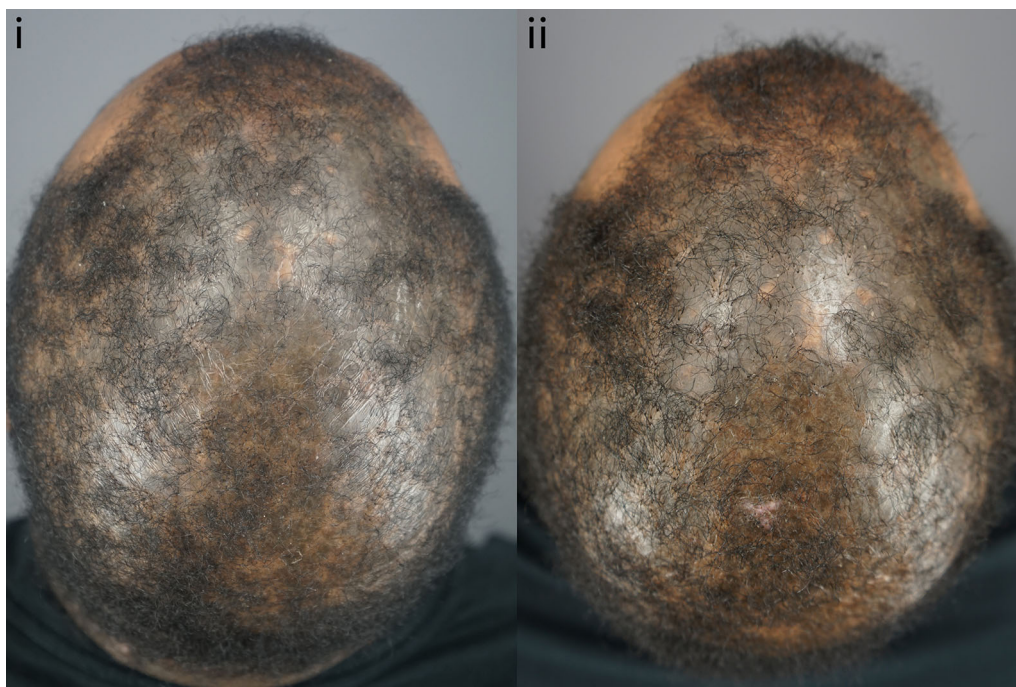


**Fig. 10** Trichoscopy image of patient 4. Trichoscopic image of a patient diagnosed with lichen planopilaris, showing hyperpigmentation, perifollicular casts, and erythema

(FAPD). These latter variants have a different mechanistic part that influences different symptomatology and therapeutic approaches [9].

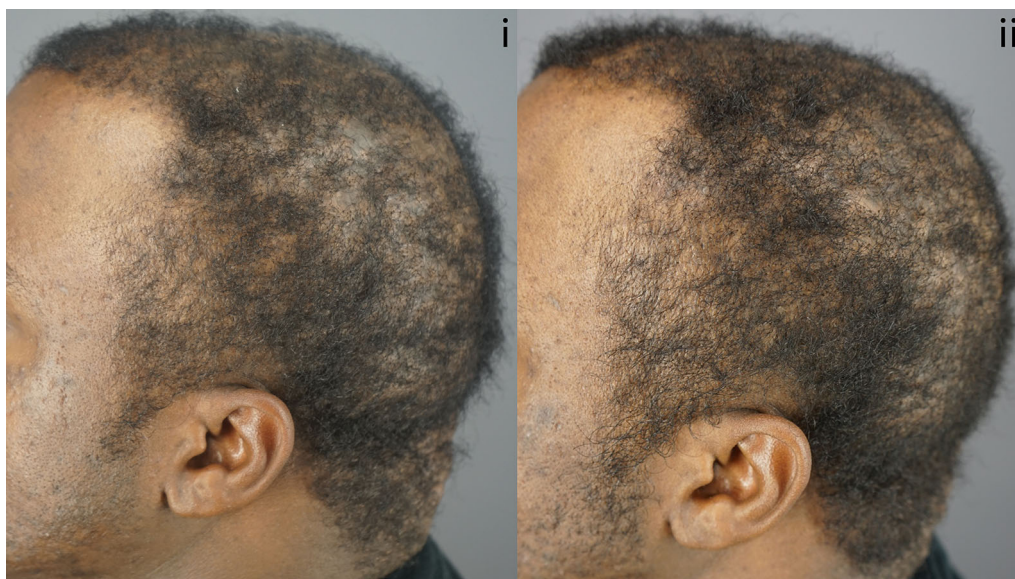We report four patients diagnosed with classical LPP who received marked benefit from a natural treatment, using a topical botanical alone or in combination with its oral formulation. All patients consistently showed a significant improvement in surrogate indicators of LPP activity, including a reduction in inflammation, complete resolution of symptoms, and signs of hair regrowth. In addition, they reported a high satisfaction level and the absence of adverse effects. We are not aware of prior reports on botanical formulas or natural treatments for LPP.

All patients were treated exclusively with the formulation, avoiding the need for high-potency steroids or other pharmaceuticals that have conventionally been used to treat LPP and have potential adverse effects. To elucidate the mechanism for the observed improvements, we examined the ingredient list. We found that, of

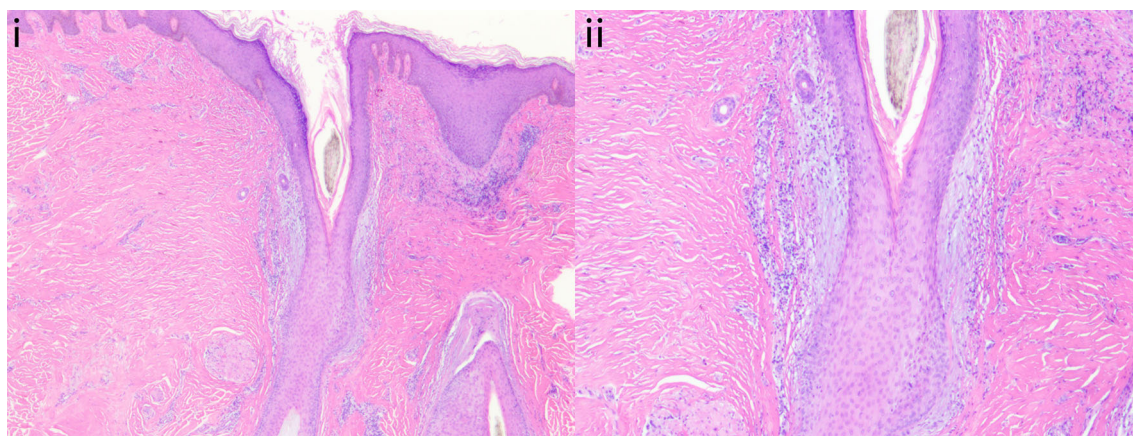


**Fig. 11** Top of head and vertex of patient 4. Images of the top of the head and vertex of a patient diagnosed with lichen planopilaris, obtained before (i) and after (ii) 7 months of treatment with Gashee lotion





**Fig. 12** Left side view of patient 4. Images of the left side view of a patient diagnosed with lichen planopilaris, obtained before (i) and after (ii) 7 months of treatment with Gashee lotion



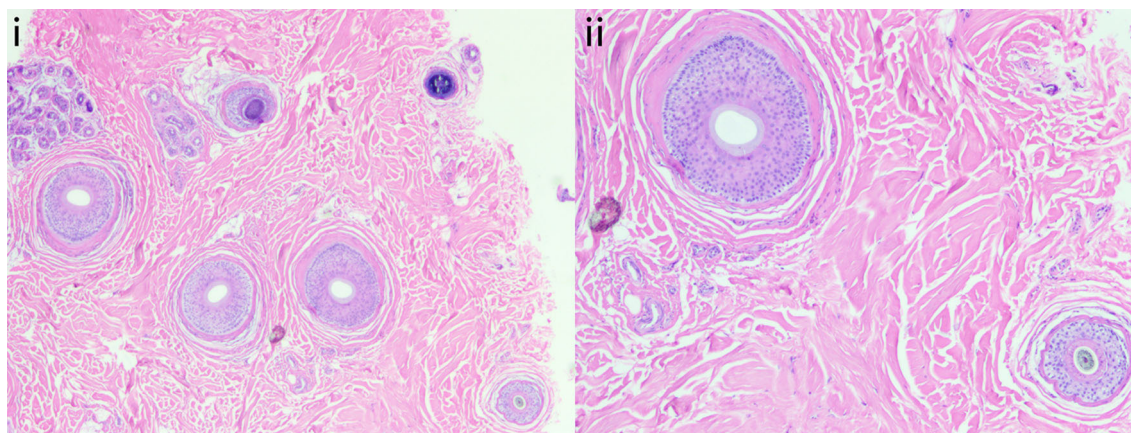
**Fig. 13** Hematoxylin and eosin staining of the vertex of patient 3 before starting the use of the Gashee lotion. The vertical section at  $\times 2$  (i) and  $\times 4$  (ii) magnification shows scarring and moderate perifollicular lymphocytic infiltration

12 reported ingredients of Gashee [6], at least 3 can modulate multiple LPP mechanistic pathways, such as the JAK/STAT pathway, which induces increased interferon-gamma ( $\text{IFN-}\gamma$ ) activity and loss of immune privilege in LPP [10]; the antifibrotic peroxisome proliferator-activated receptor gamma ( $\text{PPAR-}\gamma$ ) pathway, which is downregulated in LPP [10]; the profibrotic and catagen-inducing transforming growth factor-beta1 ( $\text{TGF-}\beta 1/\text{SMAD}$ ), which is increased in LPP [12]; and proinflammatory

cytokines such as interferons (IFNs) and tumor necrosis factor-alpha ( $\text{TNF-}\alpha$ ), the levels of which are increased in LPP [13].

Direct causes of hair loss in LPP include  $\text{TGF-}\beta$ , which induces catagen in hair [14],  $\text{IFN-}\gamma$ , which leads to an immune attack on hair bulge, and  $\text{TNF-}\alpha$ , which induces apoptosis of dermal papillae cells (Table 1).

The possible mechanisms underlying the improvement of LPP by a botanical are further discussed below.



**Fig. 14** Hematoxylin and eosin staining of the vertex of patient 3 at 7 months after using the Gashee lotion. The transverse section at  $\times 2$  (i) and  $\times 4$  (ii) magnification, showing scarring, moderate perifollicular lymphocytic

infiltration, increased number of follicles with mixed anagen and catagen phase as well as several vellus hair follicles, with an increased number of adipocytes and absence of inflammation

### Inhibition of JAK/STAT

JAK1 and JAK3 are significantly upregulated in dermal inflammatory cells of patients with LPP. Upregulation of JAK1 is believed to result in increased IFN- $\gamma$  activity, which may cause the loss of HFIP, especially in the bulge region [37]. This may explain the reported success in treating LPP with the JAK inhibitor, tofacitinib [10]. Two major ingredients, curcumin [15–17] and fenugreek [24, 25], in both the topical and oral Gashee, as well as green tea extract [32, 33] in topical Gashee, are JAK/STAT inhibitors (Table 1).

### Upregulation of PPAR- $\gamma$

PPAR- $\gamma$  normally inhibits fibrosis at the involved tissue points. The following findings evidence the implication of reduced PPAR- $\gamma$  activity in the causation of LPP: reduced PPAR- $\gamma$  activity in LPP tissue compared with that in non-LPP involved tissue [12], a significant reduction in the expression of PPAR- $\gamma$  [38], a transcription factor in LPP, and success in the treatment of LPP with a PPAR agonist, pioglitazone [11]. Curcumin [19, 20] and fenugreek [27], found in both topical and oral Gashee, as well as green tea [34], found only in topical

Gashee, have been shown to upregulate PPAR- $\gamma$  (Table 1).

### Inhibition of TGF- $\beta 1$ /SMAD

TGF- $\beta 1$ , SMAD2, and SMAD3 transcripts was upregulated in LPP-involved tissue compared with noninvolved tissue of the same patient [12]. TGF- $\beta$ /SMAD causes hair loss by pushing hair into catagen [14, 39] while causing fibrosis by inducing epithelial–mesenchymal transition through downregulation of PPAR- $\gamma$  [12]. Curcumin [18] and fenugreek [26] have been shown to inhibit TGF- $\beta 1$ /SMAD activity (Table 1).

### Modulation of Proinflammatory Cytokines

The levels of the proinflammatory cytokine IFN- $\gamma$  are increased in LPP-involved tissue compared with uninvolved tissue. IFN- $\gamma$  plays a central role in LPP by canceling the HFIP in the bulge and stem cell exhaustion [37].

Furthermore, thiazolidinediones were reported to cause improvements in LPP, reduce proinflammatory nuclear transcription factors (nuclear factor- $\kappa\beta$  and nuclear factor of activated T-lymphocytes), proteolytic enzymes (matrix metalloproteinase-9), and



**Table 1** Lichen planopilaris (LPP)-relevant properties of various Gashee components

Generic name	INCI name	Properties
Turmeric	<i>Curcuma longa</i> (curcumin)	<ol style="list-style-type: none"> <li>1. Inhibits JAK/STAT signaling pathway [15] through inhibition of STAT phosphorylation, thus enhancing antiinflammatory cytokine levels [16]; suppresses activation of DCs to restore immunologic balance [17]</li> <li>2. Possesses potent antifibrotic properties by blocking the profibrotic actions of TGF-<math>\beta</math> through downregulation of the Smad signaling pathway [18]; its derivative, THC, is potent in upregulating PPAR-<math>\gamma</math> [19, 20]</li> <li>3. Antiinflammatory effects by suppression of NF-<math>\kappa</math>B activation [21]; downregulates COX-2, lipoxygenase, and iNOS activities [22]; inhibits production of TNF-<math>\alpha</math>, IL-1, IL-2, IL-6, IL-8, IL-12, MCP migration inhibitory protein, Janus kinases [23]</li> </ol>
Fenugreek	<i>Trigonella foenum-graecum</i>	<ol style="list-style-type: none"> <li>1. Inhibits JAK/STAT signaling pathway [24] through major steroidal sapogenin in fenugreek seed, diosgenin; suppresses JAK1 and JAK2 and increases SH-PTP2 expression, which thus inhibits STAT3 activation [25]</li> <li>2. Diosgenin possesses antifibrotic properties by inhibiting the TGF-<math>\beta</math>1/Smad signaling pathway [26]; it upregulates PPAR-<math>\gamma</math> expression [27]</li> <li>3. Diosgenin demonstrates several antiinflammatory functions, such as reduction in the production of inflammatory mediators in macrophages and counteracting the effects of proinflammatory cytokines, such as IL-6 and TNF-<math>\alpha</math> [28, 29]; promotes angiogenesis and vasodilation, with improved blood flow to the scalp and increased supply of nutrients to the hair follicles [30, 31]</li> </ol>
Green tea	<i>Camellia sinensis</i>	<ol style="list-style-type: none"> <li>1. Inhibits JAK/STAT signaling pathway [32] through inactivation of positive regulators JAK1 and JAK2, which are upstream activators of STAT1; activation of negative regulator SHP-2 [33]</li> <li>2. Upregulation of PPAR-<math>\gamma</math> expression through activation of luciferase reporter driven by PPAR-responsive elements [34]</li> <li>3. Antiinflammatory properties [35] by reduction of inflammatory cytokine production, such as IFN-<math>\gamma</math>, IL-6, and TNF-<math>\alpha</math>; production of IL-10 [36]</li> </ol>

*INCI* International Nomenclature of Cosmetic Ingredients; *JAK* Janus kinase; *STAT* signal transducer and activator of transcription; *DCs* dendritic cells; *TGF- $\beta$*  transforming growth factor-beta; *THC* tetrahydro curcumin; *NF- $\kappa$ B* nuclear factor kappa B; *COX-2* cyclooxygenase-2; *iNOS* nitric oxide synthase; *PPAR- $\gamma$*  peroxisome proliferator-activated receptor-gamma; *TNF- $\alpha$*  tumor necrosis factor-alpha; IL, interleukin; *MCP* monocyte chemoattractant protein; *SH-PTP2* src homology 2 protein tyrosine phosphatase; *IFN- $\gamma$*  interferon gamma

inflammatory interleukins (interleukin [IL]-1 $\beta$ , IL-2, and IL-6), and other inflammatory molecules (TNF) [40].

Curcumin [21–23] and fenugreek [28–31], present in the topical and oral Gashee formulations, and green tea [35, 36], found only in the

topical formulation, are potent antiinflammatory agents (Table 1).

## Limitations

The limitations of the present study include a small sample size, retrospective nature, and lack of controls. While the improvements seen in patients are not consistent with the natural history of treatment-refractory LPP, a prospective and well-controlled study will help evaluate the use and optimal dosing, efficacy, and safety profile of topical and oral Gashee formulations or their combination.

## CONCLUSIONS

Current treatments for classic LPP, a typically refractory and progressive disease, are suboptimal and associated with potential adverse effects that complicate long-term use. Treatment-refractory LPP responded to the plant-based natural treatment Gashee. Our findings suggest that the role of botanicals in the treatment of LPP, including optimal dosing, warrants further investigation in larger controlled trials.

## ACKNOWLEDGEMENTS

We are grateful to our patients.

**Funding.** The Rapid Service Fee was funded by the authors.

**Authorship.** All named authors meet the International Committee of Medical Journal Editors (ICMJE) criteria for authorship for this article, take responsibility for the integrity of the work as a whole, and have given their approval for this version to be published.

**Author Contributions.** Sanusi Umar: Conception, Design, Data collection, Draft, and Review, Petrina Kan Data Collection, Design, Draft, and Review, Marissa J. Carter Design, Draft, and Review. Paul Shitabata Conception, Design, Data collection, Draft and Review. Myroslava Novosilska Conception, Data Collection, Draft and Review.

**Disclosures.** Dr. Sanusi Umar has a patent application for Gashee and has equity in its parent company, FineTouch Laboratories Inc. Petrina Kan, Dr. Marissa J. Carter, Dr. Paul Shitabata, and Dr. Myroslava Novosilska have nothing to disclose.

**Compliance with Ethics Guidelines.** All patients provided written consent to publish the data and images in this report. Approval from an Institutional Review Board was not required, given the retrospective description of clinical findings in routine care of the patients.

**Data Availability.** Data sharing does not apply to this article as no datasets were generated or analyzed during the current study.

**Open Access.** This article is licensed under a Creative Commons Attribution-NonCommercial 4.0 International License, which permits any non-commercial use, sharing, adaptation, distribution and reproduction in any medium or format, as long as you give appropriate credit to the original author(s) and the source, provide a link to the Creative Commons licence, and indicate if changes were made. The images or other third party material in this article are included in the article's Creative Commons licence, unless indicated otherwise in a credit line to the material. If material is not included in the article's Creative Commons licence and your intended use is not permitted by statutory regulation or exceeds the permitted use, you will need to obtain permission directly from the copyright holder. To view a copy of this licence, visit <http://creativecommons.org/licenses/by-nc/4.0/>.

## REFERENCES

1. Errichetti E, Figini M, Croatto M, Stinco G. Therapeutic management of classic lichen planopilaris: a systematic review. *Clin Cosmet Investig Dermatol*. 2018;11:91–102.
2. Rongioletti F, Christana K. Cicatricial (scarring) alopecias: an overview of pathogenesis, classification, diagnosis, and treatment. *Am J Clin Dermatol*. 2012;13(4):247–60.



3. Strazzulla LC, Avila L, Lo Sicco K, Shapiro J. Novel treatment using low-dose naltrexone for lichen planopilaris. *J Drugs Dermatol*. 2017;16(11):1140–2.
4. Randolph MJ, Salhi WA, Tosti A. Lichen planopilaris and low-level light therapy: four case reports and review of the literature about low-level light therapy and lichenoid dermatosis. *Dermatol Ther (Heidelb)*. 2020;10(2):311–9.
5. Bolanča Ž, Goren A, Getaldić-Švarc B, Vučić M, Šitum M. Platelet-rich plasma as a novel treatment for lichen planopilaris. *Dermatol Ther*. 2016;29(4):233–5.
6. Umar S, Carter MJ. A multimodal hair-loss treatment strategy using a new topical phytoactive formulation: a report of five cases. *Case Rep Dermatol Med*. 2021;2021:6659943.
7. Sundberg JP, Hordinsky MK, Bergfeld W, et al. Cicatricial Alopecia Research Foundation meeting, May 2016: progress towards the diagnosis, treatment and cure of primary cicatricial alopecias. *Exp Dermatol*. 2018;27(3):302–10.
8. Jordan CS, Chapman C, Kolivras A, Roberts JL, Thompson NB, Thompson CT. Clinicopathologic and immunophenotypic characterization of lichen planopilaris and central centrifugal cicatricial alopecia: a comparative study of 51 cases. *J Cutan Pathol*. 2020;47(2):128–34.
9. Tavakolpour S, Mahmoudi H, Abedini R, Kamyab Hesari K, Kiani A, Daneshpazhooh M. Frontal fibrosing alopecia: an update on the hypothesis of pathogenesis and treatment. *Int J Womens Dermatol*. 2019;5(2):116–23.
10. Yang CC, Khanna T, Sallee B, Christiano AM, Bordonone LA. Tofacitinib for the treatment of lichen planopilaris: a case series. *Dermatol Ther*. 2018;31(6):e12656.
11. Mirmirani P, Karnik P. Lichen planopilaris treated with a peroxisome proliferator-activated receptor gamma agonist. *Arch Dermatol*. 2009;145(12):1363–6.
12. Imanishi H, Ansell DM, Chéret J, et al. Epithelial-to-mesenchymal stem cell transition in a human organ: lessons from lichen planopilaris. *J Invest Dermatol*. 2018;138(3):511–9.
13. McPhie ML, Wang A, Molin S, Herzinger T. Lichen planopilaris induced by infliximab: a case report. *SAGE Open Med Case Rep*. 2020;8:2050313X20901967.
14. Soma T, Tsuji Y, Hibino T. Involvement of transforming growth factor-beta2 in catagen induction during the human hair cycle. *J Invest Dermatol*. 2002;118(6):993–7.
15. Kim HY, Park EJ, Joe EH, Jou I. Curcumin suppresses Janus kinase-STAT inflammatory signaling through activation of Src homology 2 domain-containing tyrosine phosphatase 2 in brain microglia. *J Immunol*. 2003;171(11):6072–9.
16. Ashrafizadeh M, Rafiei H, Mohammadinejad R, Afshar EG, Farkhondeh T, Samarghandian S. Potential therapeutic effects of curcumin mediated by JAK/STAT signaling pathway: a review. *Phytother Res*. 2020;34(8):1745–60. <https://doi.org/10.1002/ptr.6642>.
17. Zhao HM, Xu R, Huang XY et al. Curcumin suppressed activation of dendritic cells via JAK/STAT/SOCS signal in mice with experimental colitis. *Front Pharmacol*. 2016;7:455. Published 2016 Nov 25. <https://doi.org/10.3389/fphar.2016.00455>
18. Hu Y, Liang H, Du Y, Zhu Y, Wang X. Curcumin inhibits transforming growth factor-beta activity via inhibition of Smad signaling in HK-2 cells. *Am J Nephrol*. 2010;31(4):332–41.
19. Pan Y, Zhao D, Yu N, et al. Curcumin improves glycolipid metabolism through regulating peroxisome proliferator activated receptor  $\gamma$  signalling pathway in high-fat diet-induced obese mice and 3T3-L1 adipocytes. *R Soc Open Sci*. 2017;4(11):170917.
20. Jacob A, Wu R, Zhou M, Wang P. Mechanism of the anti-inflammatory effect of curcumin: PPAR-gamma activation. *PPAR Res*. 2007;2007:89369.
21. Kim JH, Gupta SC, Park B, Yadav VR, Aggarwal BB. Turmeric (*Curcuma longa*) inhibits inflammatory nuclear factor (NF)- $\kappa$ B and NF- $\kappa$ B-regulated gene products and induces death receptors leading to suppressed proliferation, induced chemosensitization, and suppressed osteoclastogenesis. *Mol Nutr Food Res*. 2012;56(3):454–65.
22. Jurenka JS. Anti-inflammatory properties of curcumin, a major constituent of *Curcuma longa*: a review of preclinical and clinical research [published correction appears in *Altern Med Rev*. 2009 Sep; 14:277]. *Altern Med Rev*. 2009;14:141–53.
23. Abe Y, Hashimoto S, Horie T. Curcumin inhibition of inflammatory cytokine production by human peripheral blood monocytes and alveolar macrophages. *Pharmacol Res*. 1999;39:41–7.
24. Li F, Fernandez PP, Rajendran P, Hui KM, Sethi G. Diosgenin, a steroidal saponin, inhibits STAT3 signaling pathway leading to suppression of proliferation and chemosensitization of human

- hepatocellular carcinoma cells. *Cancer Lett.* 2010;292(2):197–207.
25. Bose S, Banerjee S, Mondal A et al. Targeting the JAK/STAT signaling pathway using phytochemicals for cancer prevention and therapy. *Cells.* 2020;9(6):1451. Published 2020 Jun 11. <https://doi.org/10.3390/cells9061451>
  26. Dinesh Babu V, Suresh Kumar A, Sudhandiran G. Diosgenin inhibits TGF- $\beta$ 1/Smad signaling and regulates epithelial mesenchymal transition in experimental pulmonary fibrosis. *Drug Chem Toxicol.* 2020;1–12.
  27. Mohammad-Sadeghipour M, Mahmoodi M, Noroozi Karimabad M, Mirzaei MR, Hajizadeh MR. Diosgenin and 4-hydroxyisoleucine from fenugreek are regulators of genes involved in lipid metabolism in the human colorectal cancer cell line SW480. *Cell J.* 2021;22(4):514–22.
  28. Jung D-H, Park H-J, Byun H-E, et al. Diosgenin inhibits macrophage-derived inflammatory mediators through downregulation of CK2, JNK, NF- $\kappa$ B and AP-1 activation. *Int Immunopharmacol.* 2010;10:1047–54.
  29. Chowdhury AA, Gawali NB, Munshi R, Juvekar AR. Trigoneelline insulates against oxidative stress, proinflammatory cytokines and restores BDNF levels in lipopolysaccharide induced cognitive impairment in adult mice. *Metab Brain Dis.* 2018;33:681–91.
  30. Moers-Carpi M. Influence of nutritive factors on hair growth. *Aktuelle Dermatol.* 2011;37:171–5.
  31. Cai B, Zhang Y, Wang Z, et al. Therapeutic potential of diosgenin and its major derivatives against neurological diseases: recent advances. *Oxid Med Cell Longev.* 2020;2020:3153082.
  32. Tang SN, Fu J, Shankar S, Srivastava RK. EGCG enhances the therapeutic potential of gemcitabine and CP690550 by inhibiting STAT3 signaling pathway in human pancreatic cancer. *PLoS ONE.* 2012;7(2): e31067.
  33. Farooqi AA, Pinheiro M, Granja A et al. EGCG mediated targeting of deregulated signaling pathways and non-coding RNAs in different cancers: focus on JAK/STAT, Wnt/ $\beta$ -Catenin, TGF/SMAD, NOTCH, SHH/GLI, and TRAIL mediated signaling pathways. *Cancers (Basel).* 2020;12(4):951. Published 2020 Apr 12. <https://doi.org/10.3390/cancers12040951>
  34. Liu Y, Zhao B, Mao G, et al. Epigallocatechin-3-O-gallate, a green tea polyphenol, induces expression of pim-1 kinase via PPAR $\gamma$  in human vascular endothelial cells. *Cardiovasc Toxicol.* 2013;13(4): 391–5. <https://doi.org/10.1007/s12012-013-9220-4>.
  35. Ohishi T, Goto S, Monira P, Isemura M, Nakamura Y. Anti-inflammatory action of green tea. *Antiinflamm Antiallergy Agents Med Chem.* 2016;15(2): 74–90.
  36. Min SY, Yan M, Kim SB, et al. Green tea epigallocatechin-3-gallate suppresses autoimmune arthritis through indoleamine-2,3-dioxygenase expressing dendritic cells and the nuclear factor, erythroid 2-like 2 antioxidant pathway. *J Inflamm (Lond).* 2015;12:53. <https://doi.org/10.1186/s12950-015-0097-9>.
  37. Harries MJ, Meyer K, Chaudhry I, et al. Lichen planopilaris is characterized by immune privilege collapse of the hair follicle's epithelial stem cell niche. *J Pathol.* 2013;231(2):236–47.
  38. Karnik P, Tekeste Z, McCormick TS, et al. Hair follicle stem cell-specific PPAR $\gamma$  deletion causes scarring alopecia. *J Invest Dermatol.* 2009;129(5): 1243–57.
  39. Tsuji Y, Denda S, Soma T, Raftery L, Momoi T, Hibino T. A potential suppressor of TGF- $\beta$  delays catagen progression in hair follicles. *J Investig Dermatol Symp Proc.* 2003;8(1):65–8.
  40. Jiang C, Ting AT, Seed B. PPAR- $\gamma$  agonists inhibit production of monocyte inflammatory cytokines. *Nature.* 1998;391(6662):82–6.