

ORIGINAL PAPER

Role of 18F-FDG PET/CT in the Follow-up of Colorectal Cancer

Renata Milardovic¹, Nermina Beslic¹, Amera Sadija¹, Sejla Ceric¹, Melika Bukvic², Lejla Džananovic³

¹Clinic of Nuclear Medicine and Endocrinology, Clinical Center of Sarajevo University, Sarajevo, Bosnia and Herzegovina

²Clinic of Radiology, Clinical Center of Sarajevo University, Sarajevo, Bosnia and Herzegovina

³Institute of Epidemiology and Medical Statistics, Medical Faculty of Sarajevo University, Sarajevo, Bosnia and Herzegovina

Corresponding author: Renata Milardovic, MD, Clinic of Nuclear Medicine and Endocrinology, Clinical Center of Sarajevo University, Sarajevo, Bosnia and Herzegovina. E-mail: milardovic2001@yahoo.com. ORCID ID: <http://www.orcid.org/0000-0002-3240-5630>.

doi: 10.5455/aim.2020.28.119-123

ACTA INFORM MED. 2020 JUN 28(2): 119-123

Received: Mar 13, 2020

Accepted: Jun 18, 2020

© 2020 Renata Milardovic, Nermina Beslic, Amera Sadija, Sejla Ceric, Melika Bukvic, Lejla Džananovic

This is an Open Access article distributed under the terms of the Creative Commons Attribution Non-Commercial License (<http://creativecommons.org/licenses/by-nc/4.0/>) which permits unrestricted non-commercial use, distribution, and reproduction in any medium, provided the original work is properly cited.

ABSTRACT

Introduction: Colorectal cancer (CRC) is the third most common cancer worldwide with the incidence of about 1,8 million newly diagnosed cases in 2018. According to the World Cancer Report 2014, in Bosnia and Herzegovina 6700 people died of cancer in 2014, and CRC was the cause of mortality in 724 patients (10%). Prevention programs including screening, state-of-the-art diagnostic modalities and therapeutic approaches to CRC are being constantly improved. **Aim:** Our study was designed to address the diagnostic accuracy of 18F-FDG PET/CT in the follow-up of CRC in patients with normal or elevated CEA. **Methods:** We retrospectively analyzed 50 patients previously diagnosed with CRC who were initially surgically treated. All patients were suspicious of recurrence and were referred to as 18F-FDG PET/CT for restaging between February 2014 and February 2019. Possible recurrence was indicated by rising CEA, equivocal radiological findings or clinical findings. **Results:** Out of a total of 50 patients for whom the follow-up of at least six months was available, 27 had CRC confirmed with the gold standard, and all 27 patients had 18F-FDG PET/CT positive for recurrence, giving a sensitivity of 18F-FDG PET/CT in detecting the recurrence of CRC of 100.0% (0.0% of false-negative – FN results). Out of 23 patients with no signs of CRC recurrence on the gold standard, 19 were also 18F-FDG PET/CT negative, giving a specificity of 18F-FDG PET/CT in detecting the recurrence of CRC of 82.6%, and 17.4% of false-positive – FP results. Out of 31 patients who were 18F-FDG PET/CT positive, 27 had it confirmed pathophysiologically or clinically, giving positive predictive value (PPV) of 18F-FDG PET/CT in detecting CRC recurrence of 87.1%; negative predictive value (NPV) was 100.0%, meaning all 19 patients showing no signs of CRC recurrence when imaged with 18F-FDG PET/CT were gold standard negative as well. **Conclusion:** 18F-FDG PET/CT proves to be a valid diagnostic tool in detecting recurrence in patients with CRC.

Keywords: Colorectal cancer, 18-FDG PET/CT.

1. INTRODUCTION

Colorectal cancer (CRC) is the third most common cancer worldwide with the incidence of about 1,8 million newly diagnosed cases in 2018 (1). According to the World Cancer Report 2014, in Bosnia and Herzegovina 6700 people died of cancer in 2014, and CRC was the cause of mortality in 724 patients (10%) (2). Prevention programs including screening, state-of-the-art diagnostic modalities, and therapeutic approaches to CRC are being constantly improved. The modern approach to CRC has been extensively contributed by the development of molecular biology and ge-

netics, which were given impetus by the first Human Genome Project (1990-2003) and its mapping of all human genes. Later discovery of genetic changes in tumors laid the foundation for the development of molecular-based diagnostic imaging and targeted therapies.

Positron-emission tomography/computed tomography (PET/CT) as a molecular-based imaging modality has been introduced into clinical practice in 2001 (3). As a technically integrated system, PET/CT enables imaging of metabolism based on the molecular features of the tissues with its PET component and morphology with its CT component. In the majority of cases, imaging of metabolism is based on

glucose as the malignant cells with their defected glucose metabolism produce energy in aerobic glycolysis, and use much more glucose than the normal cells. Such a discrepancy in glucose consumption enables visualization of malignant tissues on PET/CT using fludeoxyglucose (18F-FDG), which accumulates more in the malignant tissues in comparison with the surrounding ones. Metabolic and anatomic information provided by an integrated PET/CT scanner is used for answering the specific clinical questions. About 90% of PET/CT studies are oncologic, and detailed guidelines on the clinical settings for imaging exist. PET/CT imaging in CRC is indicated in: (a) staging of patients with metastases suitable for resection, (b) restaging of patients with suspicious recurrence based on rising CEA, radiological findings or clinical symptoms, and (c) assessment of treatment response (4, 5).

Carcinoembryonic antigen (CEA) is a glycoprotein that has long been used as a tumor biomarker in detecting recurrent CRC, and the assessment of treatment response. It is also proved to be an independent prognostic marker for CRC in multiple studies (6-8). Serum CEA levels higher than 5 ng/ml in patients with CRC portend a suspicion of recurrence, and require further evaluation (9).

2. AIM

Our study was designed to address the diagnostic accuracy of 18F-FDG PET/CT in the follow-up of CRC in patients with normal or elevated CEA.

Materials and methods

We retrospectively analyzed 50 patients previously diagnosed with CRC who were initially surgically treated. All patients were suspicious of recurrence and were referred to as 18F-FDG PET/CT for restaging between February 2014 and February 2019. Possible recurrence was indicated by rising CEA, equivocal radiological findings, or clinical findings. Inclusion criteria were surgical resection of the primary tumor six or more months before the imaging, pathohistological diagnosis of adenocarcinoma of the colon or rectum, and CEA measured within three months from the imaging. CEA level above 5 ng/ml was considered abnormal. The patients were possibly treated with chemotherapy or radiation six or more months before the study. Exclusion criteria were the lack of follow-up, death of a patient, other colorectal tumors except for adenocarcinoma, and second primary tumor diagnosed.

After the intravenous injection of 337,0 MBq of 18F-FDG and application of an oral contrast agent, all patients were imaged according to the institutional whole-body low-dose imaging protocol with an integrated PET/CT scanner (GE, 610 Discovery, GE Healthcare). 18F-FDG PET/CT images were analyzed visually and semi-quantitatively after reconstruction in axial, coronal, and sagittal projections. For analysis, vendor software (Advantage Workstation, Release 4.6. Software, GE) was used. In PET analysis, a tumor lesion was defined as a focus of increased 18F-FDG accumulation reflecting glucose hypermetabolism in comparison with the surrounding tissues. Benign conditions and physiological activity of 18F-FDG had to be excluded. As the gold standard, patho-

histological results or clinical data from the follow-up of at least six months were used. For each lesion, a location and maximum standardized uptake value (SUVmax) were noted. Multiple lesions in one organ were counted as one, and the highest SUVmax per organ was noted.

True positive PET/CT studies demonstrated focal FDG hypermetabolism consistent with recurrence proven by the gold standard. True negative studies demonstrated no FDG hypermetabolism and no structural changes on CT suggestive of recurrence confirmed by the gold standard. In the case of normal PET/CT and serially increasing CEA, colonoscopy, radiological examinations and close follow-up ensued. False-positive studies referred to FDG hypermetabolism in normal anatomic structures, benign lesions, or lesions of inflammatory origin. False-negative studies were considered FDG negative with normal CT but proved positive in the follow-up.

For statistical analysis, MS Excel 2019 and SPSS 21. were used, and the following were calculated for 18F-FDG PET/CT in detecting the recurrence of CRC: sensitivity, specificity, positive predictive value, and negative predictive value. 18F-FDG PET/CT results (positive vs. negative) were associated with the CEA level (normal vs. elevated). Finally, CEA levels were correlated with SUVmax for each lesion. Organ-based and patient-based analysis for recurrence of CRC were also performed.

3. RESULTS

Total number of 50 patients (25 men and 25 women, mean age 60.7±10.5 years, range 36-80 years) with suspicious recurrent colorectal cancer were included in the study.

18F-FDG PET/CT. Out of a total of 50 patients for whom the follow-up of at least six months was available, 27 had CRC confirmed with the gold standard, and all 27 patients had 18F-FDG PET/CT positive for recurrence, giving a sensitivity of 18F-FDG PET/CT in detecting the recurrence of CRC of 100.0% (0.0% of false-negative – FN results). Out of 23 patients with no signs of CRC recurrence on the gold standard, 19 were also 18F-FDG PET/CT negative, giving a specificity of 18F-FDG PET/CT in detecting the recurrence of CRC of 82.6%, and 17.4% of false-positive – FP results. Out of 31 patients who were 18F-FDG PET/CT positive, 27 had it confirmed pathophysiologically or clinically, giving positive predictive value (PPV) of 18F-FDG PET/CT in detecting CRC recurrence of 87.1%; negative predictive value (NPV) was 100.0%, meaning all 19 patients showing no signs of CRC recurrence when imaged with 18F-FDG PET/CT were gold standard negative as well.

CEA. Out of 27 patients whose PET/CT studies were positive on CRC recurrence, 13 had elevated CEA (>5 ng/ml) giving a sensitivity of elevated CEA in detecting the recurrence of CRC of 48.1% (51.9% of false-negative – FN results). Out of 23 patients with no signs of CRC recurrence on the gold standard, 19 had normal CEA levels, giving a specificity of elevated CEA in detecting the recurrence of CRC of 82.6%, and 17.4% of false-positive – FP results. Out of 17 patients with elevated CEA (>5.0 ng/ml), 13 had it confirmed pathophysiologically or clinically, giving positive predictive value (PPV) of elevated CEA in detecting CRC recurrence of 76.5%; negative predictive value (NPV) was 57.6%,

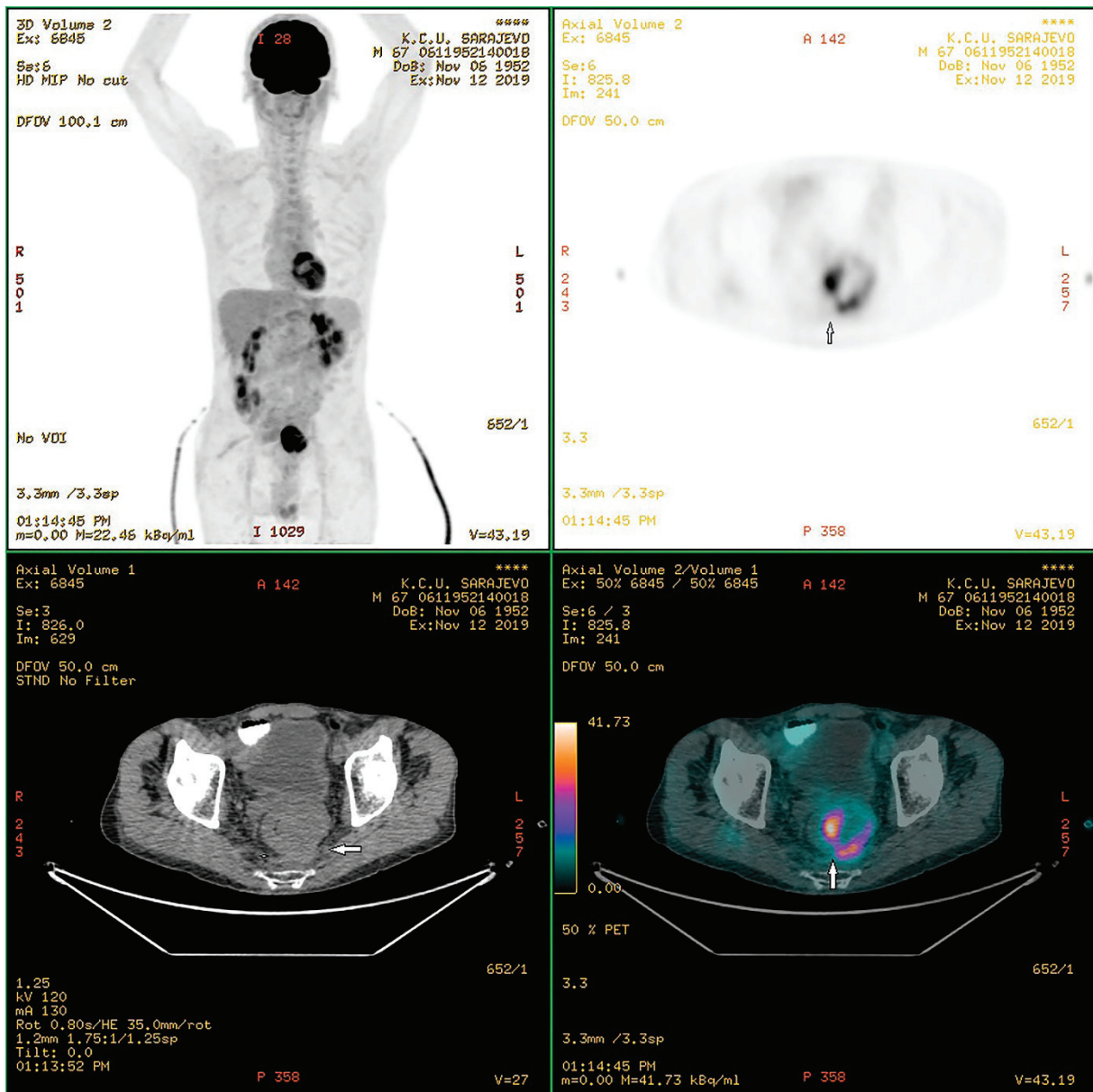


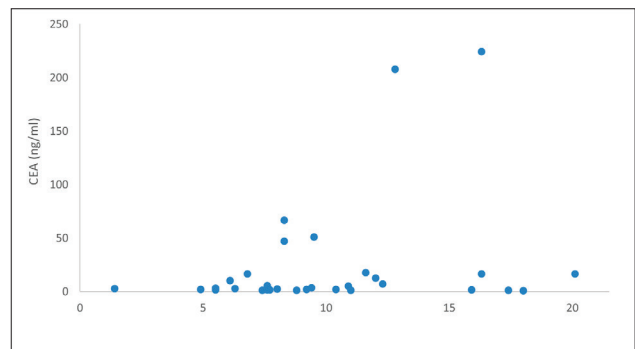
Figure 1. Recurrent rectal cancer. Axial PET image in a patient with previously resected rectal cancer demonstrates recurrence manifested as a ring-shaped accumulation of FDG with central hypometabolism (arrow). Axial CT image demonstrates left-sided solid mass in the pelvis growing from the rectal wall (arrow). Fused PET/CT image precisely localize the lesion characterized by central necrosis. Note air-filled rectum and distended urinary bladder. Patient has bilateral nephrostoma to relieve obstruction.

meaning out of 33 patients with CEA levels within the reference range (≤ 5.0 ng/ml) 19 were gold standard negative as well.

Organ-based analysis (n=46) demonstrated recurrence on the following sites: regional and distant lymph nodes 14 (30.4%), liver 10 (21.7%), lung 9 (19.5%), resection site 8 (17.4%), bones 2 (4.3%) and other sites (e.g. peritoneum and subcutaneous tissue) 3 (6.5%). Patient-based analysis (n=27) demonstrated: local recurrence at the resection site 6 (22.2%), liver 5 (18.5%), lymph nodes 3 (11.1%), lung 2 (7.4%) and multiple sites 11 (40.7%). The primary site for disseminated CRC with multiple sites was rectum in 63.6%.

18F-FDG PET/CT and CEA. When 18F-FDG PET/CT results (positive vs. negative) were associated with CEA level (normal vs. elevated), a statistically significant association was found to exist ($\chi^2(1)=4.53, p=0.033$).

CEA and SUVmax. Finally, SUVmax was correlated with CEA



Graph 1. Scatter plot of CEA and SUVmax (n=31)

on a patient-basis. As the distribution of CEA level was skewed (as showed using Shapiro-Wilk test, $p < 0.001$), the correlation of these two variables was tested using non-parametric correlation test; it showed statistically non-significant low positive rank cor-

relation ($\rho=0.164$, $p=0.38$; $n=31$) (Graph 1).

4. DISCUSSION

After the surgical resection of CRC as the primary treatment, the recurrence rate remains high. According to different authors, the recurrence rate reaches 40-50% and is most common in the first two years thereafter (9, 10). Rectal carcinoma, stage of the tumor, perforation, and local invasion are all considered positive predictors of recurrence (11). For this reason, a close follow-up is mandatory to detect the recurrence as soon as possible. Before PET/CT was introduced into clinical practice, follow-up of CRC was based on serial CEA measurements, colonoscopy, and radiological imaging. CEA measurements have been widely used in the follow-up of CRC, however, their sensitivity and specificity of about 80% and 70% are considered relatively low (12). With the state-of-the-art hybrid imaging modalities, new guidelines were brought into practice indicating their use in specific clinical settings.

Earlier studies such as that of Metser et al. (13) compared 18F-FDG PET/CT and contrast-enhanced 64-MDCT in the detection of recurrent CRC and concluded that 18F-FDG PET/CT had higher sensitivity, while specificity remained similar. The higher sensitivity of 18F-FDG PET/CT is attributed to its PET component to detect molecular changes in the malignant cells, which precede morphological changes in the tissues. In this way, the occult disease may be detected.

Our study was designed to address the diagnostic accuracy of 18F-FDG PET/CT in the follow-up of CRC in patients with normal or elevated CEA. In a similar study by Ozkan et al. (10), which included 76 patients with elevated CEA, the sensitivity and specificity of 18F-FDG PET/CT in the detection of recurrence were 97% and 61%, respectively. A meta-analysis including 510 patients of Lu et al. (14) also analyzed patients with elevated CEA imaged on 18F-FDG PET/CT, and the calculated sensitivity and specificity were 94.1% and 77.2%. Sanli et al. (15) compared in their study the utility of FDG-PET/CT for detection of recurrent CRC in patients with normal and elevated CEA and concluded that the sensitivity and specificity deferred for these two subgroups, 100.0% and 84.0% for normal CEA group, and 97.1% and 84.6% for abnormal CEA group.

Our results indicate that 18F-FDG PET/CT has sensitivity and specificity of 100.0% and 82.6%, respectively for the detection of CRC recurrence regardless of the CEA level. Such results add up to the body of evidence that supports the clinical usefulness of 18F-FDG PET/CT. Sensitivity depends upon the molecular features of the cells but also on the lesion size. Lower, but still clinically accepted specificity is attributed to increased accumulation of FDG in the normal tissues (e.g. intestinal wall), benign lesions (e.g. polyp, abscess, diverticulitis, fistula), but also other malignant lesions. In our study, false-positive results were caused by a herniated colonic wall, normal rectal wall, and reactive lymph nodes.

To the same end of making a diagnosis of recurrence as early as possible and improve prognosis, Gade et al (16)

studied a diagnostic value of 18F-FDG PET/CT as the first choice in the detection of CRC recurrence. Their study concluded that 18F-FDG PET/CT could be used as the first choice. In recent years, this has become a practice at our institution, too, with CEA measurements done concurrently. CEA is thought to be the first abnormal test in 38% to 66% of patients who develop recurrence, about 4-6 months before the appearance of clinical symptoms or positive imaging modalities (17).

Standard incorporation of SUVmax as the metabolic parameter in the PET/CT reports increases the specificity. Adding another metabolic parameter was proven to further increase specificity (18). Attempts have been made in oncological imaging to further increase the specificity by introducing many quantitative PET/CT parameters that characterize the tissues in what is called „a multiparametric approach“ (19). Such parameters reflect, for example, tumor vascularity or tissue heterogeneity, and present one of the future directions of PET/CT development.

In our study, CEA sensitivity in detecting the recurrence of CRC of 48.1% is considered low. It may partly be attributed to normal CEA levels in the presence of recurrence that may be found after chemotherapy when apoptosis and cell death of malignant cells happen. It may also be the case in poorly differentiated CRCs. However, when 18F-FDG PET/CT results (positive vs. negative) were associated with CEA (normal vs. elevated), a statistically significant association was found to exist ($p=0.033$). It, once again, highlights the role of CEA in detecting recurrence. In correlation with CEA and SUVmax, a non-significant low positive rank correlation ($\rho=0.164$, $p=0.38$; $n=31$) was found. This result could be attributed to complex and differing factors causing each. Serum CEA level is thought to be influenced by a tumor location, invasiveness of a tumor and tumor burden making more differentiated and left-sided CRCs to cause higher CEA levels. Research of Ozkan et al (10) showed no correlation between patients' serum CEA and lesions' SUVmax to exist.

The main limitation of our study is its design as a retrospective study so that not completely the same criteria are followed for each patient, even though every patient met the previously set inclusion criteria for the study.

5. CONCLUSION

18F-FDG PET/CT proves to be a valid diagnostic tool in detecting recurrence in patients with CRC.

- **Authors contribution:** All authors were included in all steps of preparation this article. Final proof reading was made by the first author.
- **Conflict of interest:** None declared.
- **Financial support and sponsorship:** Nil.

REFERENCES

1. World Health Organization, www.who.int/factsheets, January, 2020
2. The World Health Organization, Cancer Country Profile 2014, www.who.int
3. Townsend D, Combined PET/CT: the historical perspective. *Semin Ultrasound CT MR.* 2008 August ; 29(4): 232-235.

4. Evidence-based indications for the use of PET-CT in the United Kingdom 2016
5. FDG PET and PET/CT: EANM procedure guidelines for tumour PET imaging: version 1.0. Accessed January 2020
6. Fakhri MG, Padmanabhan A. CEA monitoring in colorectal cancer. What you should know. *Oncology (Williston Park)*. 2006 May;20(6):579-87
7. Saito G, Sadahiro S, Kamata H, Miyakita H, Okada K, Tanaka A et Suzuki T. Monitoring of Serum Carcinoembryonic Antigen Levels after Curative Resection of Colon Cancer: Cutoff Values Determined according to Preoperative Levels Enhance the Diagnostic Accuracy for Recurrence. *Oncology*. 2017 Apr;92(5): 276-282.
8. Campos-da-Paz M, Dorea JG, Galdino AS, Lacava ZGM, de Fatima Menezes Almeida Santos M. Carcinoembryonic Antigen (CEA) and Hepatic Metastasis in Colorectal Cancer: Update on Biomarker for Clinical and Biotechnological Approaches. *Recent Pat Biotechnol*. 2018;12(4):269-279
9. Pelosi E., Deandreis D. The role of 18F-fluoro-deoxy-glucose positron emission tomography (FDG-PET) in the management of patients with colorectal cancer. *EJSO* 33 (2007) 1-6
10. Ozkan E, Soydal C, Araz M, Kir KM, Ibis E. The role of 18F-FDG PET/CT in detecting colorectal cancer recurrence in patients with elevated CEA levels. *Nucl Med Commun*. 2012 Apr;33(4): 395-402
11. O'Connor OJ, McDermott S, Slattery J, Sahani D and Blake MA. The Use of PET/CT in the Assessment of Patients with Colorectal Carcinoma. *Int J Surg Oncol*. 2011;2011:846512
12. Duffy MJ. Carcinoembryonic antigen as a marker for colorectal cancer: is it clinically useful? *Clin Chem* 2001; 47:624-630
13. Metser U, You J, McSweeney S, Freeman M, Hendler A. Assessment of Tumor Recurrence in Patients with Colorectal Cancer and Elevated Carcinoembryonic Antigen Level: FDG PET/CT Versus Contrast-Enhanced 64-MDCT of the Chest and Abdomen. *AJR* 2010;194:766-771
14. Lu YY, Chen JH, Chien CR, Chen WT, Tsai SC, Lin WY, Kao CH. Use of FDG-PET or PET/CT to detect recurrent colorectal cancer in patients with elevated CEA: a systematic review and meta-analysis. *Int J Colorectal Dis*. 2013 Aug;28(8): 1039-47
15. Sanli Y, Kuyumcu S, Ozkan ZG, Kilic L, Balik E, Turkmen C, Has D, Isik G, Asoglu O, Kapran Y, Adalet I. The utility of FDG-PET/CT as an effective tool for detecting recurrent colorectal cancer regardless of serum CEA levels. *Ann Nucl Med*. 2012 Aug;26(7):551-8
16. Gade M, Kubik M, Fisker RV, Thorlacius-Ussing O, Petersen LJ. Diagnostic value of (18)F-FDG PET/CT as first choice in the detection of recurrent colorectal cancer due to rising CEA. *Cancer Imaging*. 2015 Aug 13;15(1):11
17. Buie WD, Attard JA. Follow-up Recommendations for Colon Cancer. Buie WD, Attard JA. Follow-up recommendations for colon cancer. *Clin Colon Rectal Surg*. 2005;18(3):232-243. doi:10.1055/s-2005-916284
18. Ince S, Okuyucu K, Hancerliogullari O, Alagoz E, San H, Arslan N. Clinical significance of fluorine-18-fluorodeoxyglucose positron emission tomography/computed tomography in the follow-up of colorectal cancer: searching off approaches increasing specificity for detection of recurrence. *Radiol Oncol*. 2017 Nov 1;51(4):378-385. doi: 10.1515/raon-2017-0045.
19. Singh D, Miles K. Multiparametric PET/CT in oncology. *Cancer Imaging*. 2012;12(2):336-344. Published 2012 Sep 28. doi:10.1102/1470-7330.2012.9007.