

## Efficacy of hybrid implants in oral and maxillofacial surgery: A clinical prospective study

### ABSTRACT

**Aim:** The present study was aimed to evaluate the efficacy of hybrid implants in replacement of missing teeth in either jaw.

**Materials and Methods:** Twenty hybrid implants were placed in maxilla and mandible and the implants were assessed for pain, implant exposure, mobility, infection and wound dehiscence at first, third and sixth month postoperatively.

**Results:** According to our study the statistical data showed that all the parameters which were seen clinically were nonsignificant.

**Conclusion:** Hybrid implants being a new option in this field, our study provides a platform for further research with larger sample size with longer follow ups to be judgemental on their efficacy.

**Keywords:** Hybrid implants, residual ridges, sinus lift

### INTRODUCTION

Replacement of missing tooth has evolved from removable partial dentures to fixed prosthesis and recently to dental implants.<sup>[1]</sup> In an edentulous patient, the ultimate aim is the replacement of missing teeth to restore function and to certain extent esthetics as well. Dental implants eliminate the need of deriving support for a stable denture base from an otherwise dynamic mucosa also, in partially edentulous cases where one or more teeth may require replacement; it tends to avoid the adjacent teeth and focuses on deriving the support from the underlying bone mimicking as a close replica of natural tooth. As they gather momentum in rehabilitation, various authors have come across obstacles' significant enough to discourage the use of an otherwise efficient modality and resort to conventional means. In the maxilla and mandible, there is resorption of alveolar bone region due to postextraction pneumatization, and in mandible, there is sometimes close approximation to inferior alveolar nerve which might present as a challenge for dental implant placement.<sup>[1]</sup> The proposed hybrid implant overcomes the risk of damage to the anatomic structures in mandible as it is a subperiosteal implant and also overcomes sinus

lifting procedure in maxilla which is a very technique sensitive procedure. Lack of primary stability is a surgical complication that should be dealt with at the time of implant surgery. However, in hybrid implant, it is not an issue as the implant is stabilized using screws buccally or palatally/lingually in maxilla and mandible. Taking all these points into consideration, hybrid implants were used for the replacement of teeth in the edentulous areas of maxilla and mandible in our study.

**GAURAV MITTAL, GAGAN KHARE<sup>1</sup>, RITESH GARG, ABHISHEK RATHI, SIDDHARTH SHARMA, DIPIKA RAGHAW**

Department of Oral and Maxillofacial Surgery, Institute of Dental Studies and Technologies, Modinagar, <sup>1</sup>Department of Oral and Maxillofacial Surgery, TMU, Moradabad, Uttar Pradesh, India

**Address for correspondence:** Dr. Gaurav Mittal, Department of Oral and Maxillofacial Surgery, Institute of Dental Studies and Technologies, Modinagar, Uttar Pradesh, India. E-mail: drgauravmittal@rediffmail.com

**Received:** 27-09-2017, **Revised:** 06-11-2017, **Accepted:** 11-12-2017, **Published:** 12-11-2019

Access this article online	
<b>Website:</b> www.njms.in	<b>Quick Response Code</b> 
<b>DOI:</b> 10.4103/njms.NJMS_61_17	

This is an open access journal, and articles are distributed under the terms of the Creative Commons Attribution-NonCommercial-ShareAlike 4.0 License, which allows others to remix, tweak, and build upon the work non-commercially, as long as appropriate credit is given and the new creations are licensed under the identical terms.

**For reprints contact:** reprints@medknow.com

**How to cite this article:** Mittal G, Khare G, Garg R, Rathi A, Sharma S, Raghaw D. Efficacy of hybrid implants in oral and maxillofacial surgery: A clinical prospective study. Natl J Maxillofac Surg 2019;10:175-81.

## MATERIALS AND METHODS

### Research design

A prospective research was designed which included placement of twenty hybrid implants over a period of 1 year with a follow up of 6 months postoperatively (1st, 3rd, and 6 months). Its efficacy was assessed by various parameters clinically that includes pain, implant exposure, mobility, infection, and wound dehiscence. Prosthetic rehabilitation was done after 3 months after the implant placement. All the data were analyzed by SPSS 19 version (IBM Corporation, Thrissur, kerala, India) statistical package and Shapiro–Wilk test was used for assessing the distribution of all parameters. A duly consent form was signed from all the patients included in this study.

### Procedure of implant placement

The design of hybrid implant is shown in Figure 1. Under local anesthesia, crestal incision was given followed by a vertical releasing incision [Figures 2 and 3]. A triangular mucoperiosteal flap was elevated, and the alveolar bone was exposed. The implant blade [Figure 1] was molded according to the arch shape and fixed using titanium screws on both buccal and palatal/lingual cortices in maxilla and mandible in such a way that the abutment was only part projecting occlusally in the oral cavity [Figures 4 and 5]. Primary closure was done such that abutment only remained exposed [Figures 6 and 7]. The closure was done with 3–0 silk suture. Prosthetic rehabilitation was done after 3 months of implant placement [Figures 8 and 9].

## RESULTS

Twenty hybrid implants were placed, and its efficacy was assessed by various clinical parameters that include pain, implant exposure, mobility, and infection and wound dehiscence.

1. Pain – visual analog scale (0–10) [Figure 10]
2. Mobility – Grade (0–5)<sup>[1]</sup> during the 1<sup>st</sup>, 3<sup>rd</sup>, and 6<sup>th</sup> month postoperatively [Figure 11]
3. Infection – infection criteria<sup>[2]</sup> [Figure 12]
4. Implant exposure [Figure 13]
5. Wound dehiscence [Figure 14].

## DISCUSSION

The evidences of implant placements are present even in the prehistoric times. The first dental implant system was proposed by Gustav Dahl<sup>[3]</sup> in 1937 and later on placed by Aaron<sup>[4]</sup> in 1948. It consisted of a metal framework placed underneath the soft tissue above the alveolus with an abutment emerging from the surface to carry denture. Many clinicians modified the technique and design of




Figure 1: Design of hybrid implant

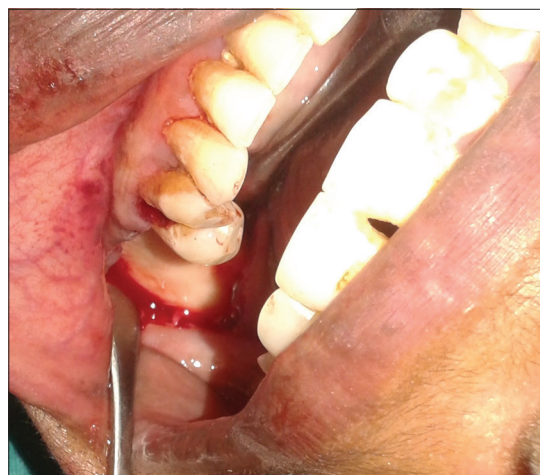

Figure 2: Incision for site exposure in mandible

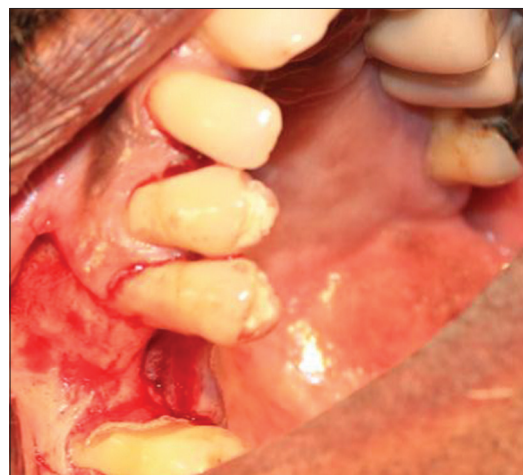

Figure 3: Incision for site exposure in maxilla

subperiosteal implants. Later on in 1981, Branemark<sup>[5]</sup> proposed the endosseous implants and did a 15-year study on osseointegrated dental implants in the treatment of edentulous jaw and concluded various aspects about osseointegration and stability of osseointegrated dental implants. When an endosseous implant is placed, there are many limiting factors. For successful implant, the need of sufficient bone around the endosseous implant is critical



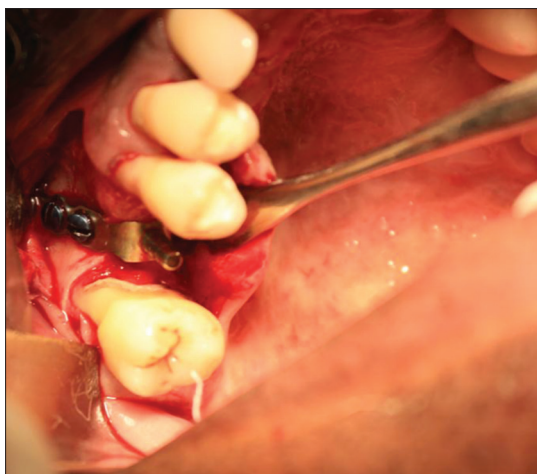


Figure 4: Placement of hybrid implant in maxilla

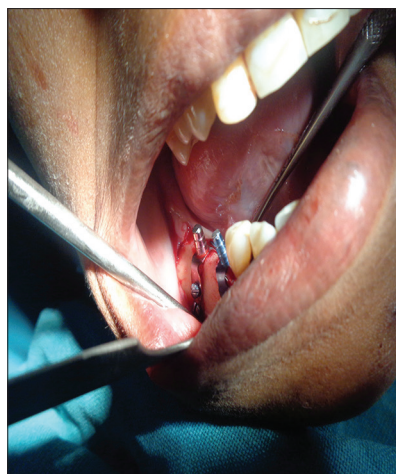


Figure 5: Placement of hybrid implant in mandible

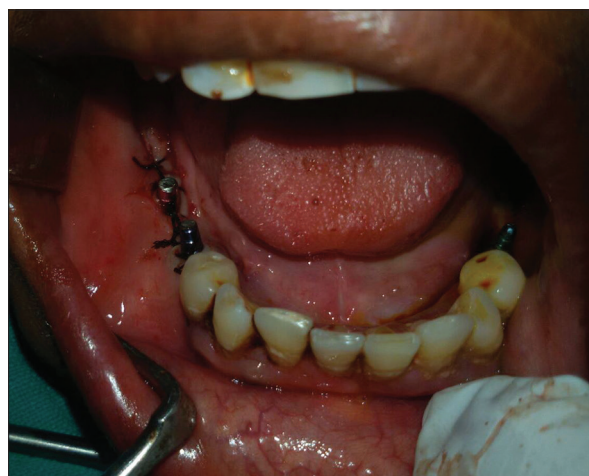

Figure 6: Final closure in mandible

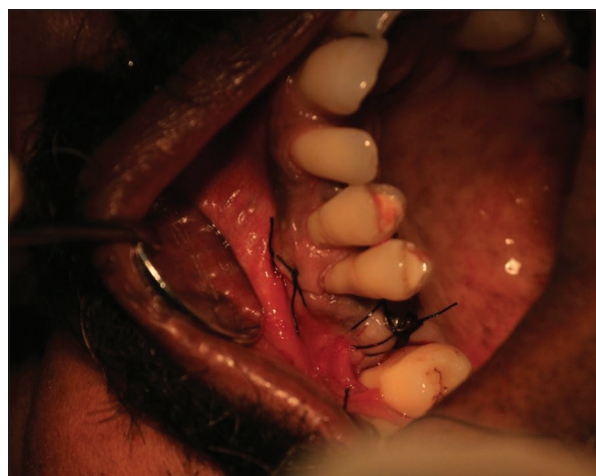

Figure 7: Final closure in maxilla

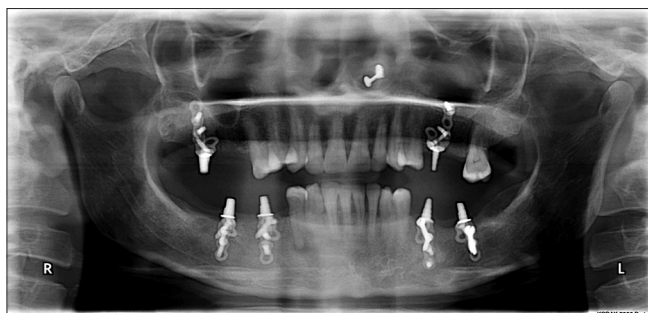


Figure 8: Postoperative OPG showing all implants after 1 month

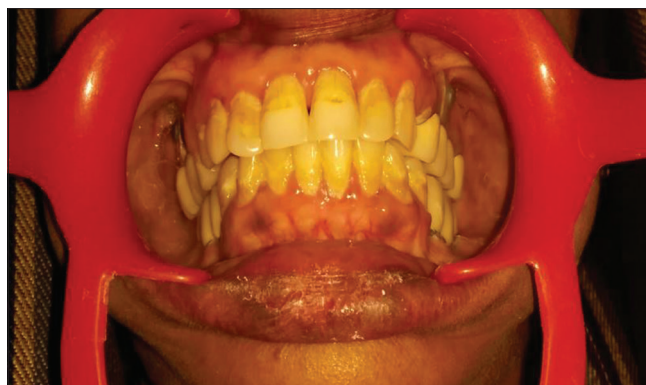

Figure 9: Prosthetic rehabilitation

for the placement and success of the implant. In the maxilla, there is a reduction of alveolar bone height in sinus region due to postextraction pneumatization, and in mandible resorption, alveolar ridge poses a close approximation to inferior alveolar nerve which sometimes might present as a challenge for dental implant placement.

Keeping in mind the above-said difficulties, Mani *et al.*<sup>[1]</sup> developed a new implant system in 2014 called the “HYBRID

IMPLANT SYSTEM” which will be cost-effective and easy to use with adequate strength to support prosthesis. According to Mani *et al.*,<sup>[1]</sup> the hybrid implant system is a versatile implant which has got both subperiosteal and endosseous components.<sup>[1]</sup> In our study, we have placed twenty hybrid implants in the maxilla and mandible, and its efficacy and success was assessed by various clinical

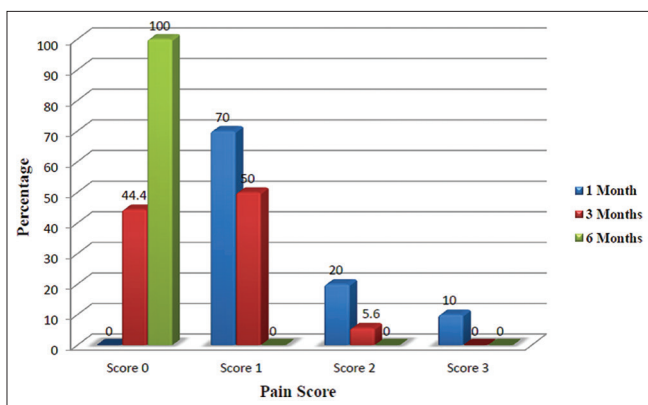


Figure 10: Graph depicting pain scores

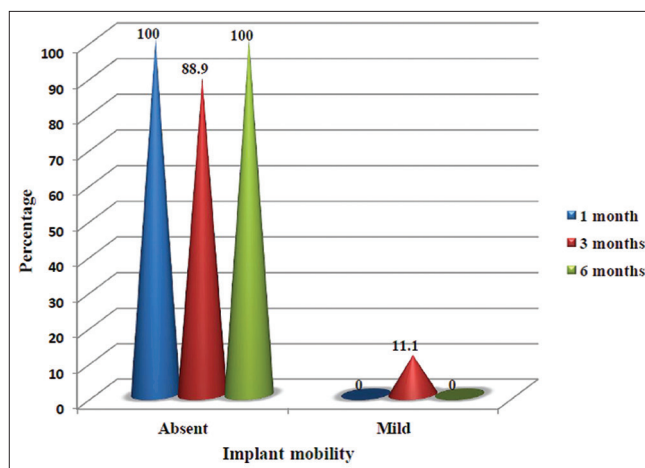


Figure 11: Graph depicting mobility

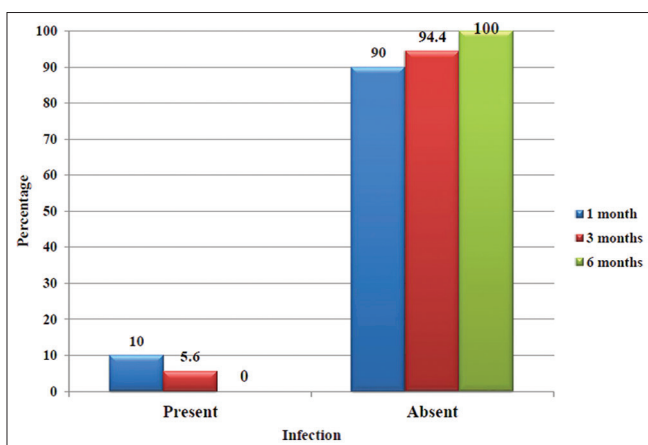


Figure 12: Graph depicting infection

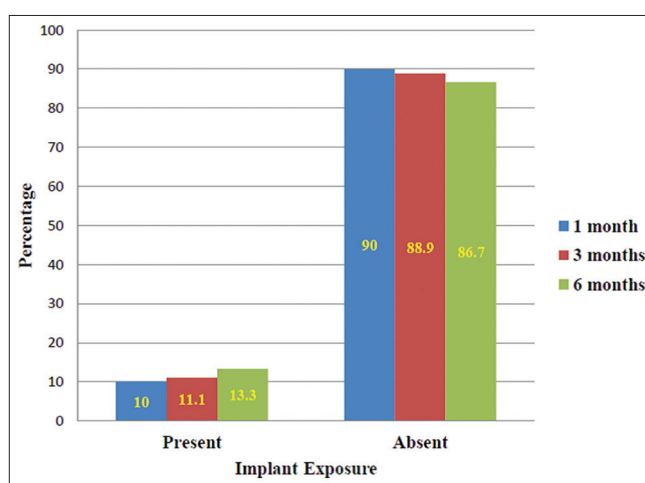


Figure 13: Graph depicting implant exposure

parameters that include pain, implant exposure, mobility, infection, and wound dehiscence at 1<sup>st</sup>, 3<sup>rd</sup>, and 6<sup>th</sup> month postoperatively.

The prerequisites of a successful dental implant are the achievement and maintenance of implant stability. Implant stability may be well defined as the lack of clinical mobility that is also described as osseointegration. Implant instability might lead to fibrous encapsulation, resulting in failure. Being mechanical phenomenon, primary implant stability is connected to local bone quantity and quality, the kind of implant, and its placement method used. In our study, we have observed mobility in five hybrid implants. Obwegeser<sup>[6]</sup> (1956) also reported mobility of five subperiosteal dental implants. According to them, reasons of mobility might be due to an inflammation, pressure, or lateral stress or the bone resorption may be merely a physiologic process. In 1983, Young *et al.*<sup>[7]</sup> also evaluated 25 patients and reported a 5-year survival rate of about 90% and 6-year survival rate of about 75%. They also evaluated the subperiosteal implants for mobility and found lateral mobility present in one of the implants, and the reason they mentioned for this mobility was bone loss. In our study, mobility was present mesiodistally

and buccolingually after the prosthetic rehabilitation of the hybrid implants, and the possible reason was that the hybrid implant could not bear the masticatory load and forces in these particular patients.

Implant exposure should certainly be considered as major criteria in terms of longevity/success of implant. As hybrid implant is a subperiosteal implant, the framework of implant may be exposed primarily because of rupture of the suture or a hematoma, or it may become exposed gradually. In some cases of hybrid implants, implant exposure was also seen followed by screw exposure buccally in the maxilla and mandible. It was recorded 10% in 1<sup>st</sup> month, 11.1% in 2<sup>nd</sup> month, and 13.3% in the 3<sup>rd</sup> month postoperatively. Obwegeser<sup>[6]</sup> in 1956 also reported in his study implant exposure in six patients and they mentioned that implants may be exposed primarily. Peev and Stefan<sup>[8]</sup> in 2013 placed 93 subperiosteal implants and observed implant exposure in 29.5% patients, and they mentioned that implant exposure was because of bone resorption. Bailey *et al.*<sup>[9]</sup> in 1988 reported in their study

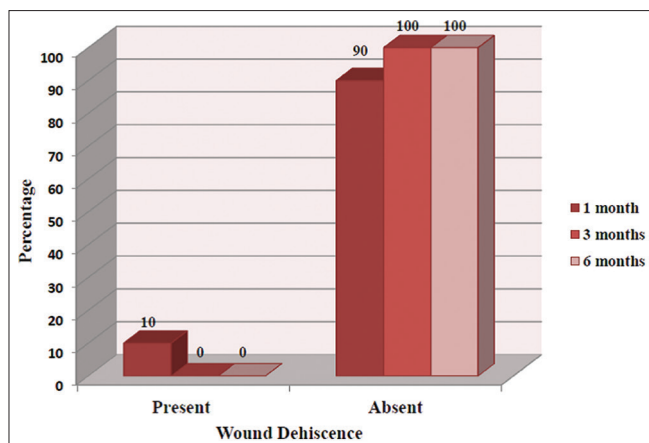


Figure 14: Graph depicting wound dehiscence

implant exposure in 33.3% patients, and the possible reasons they mentioned were bone resorption, occlusal wear, or flexure of the mandible. In our study, we observed that implant exposure could be because of improper suturing, insufficient flap for closure, and closure done in tension.

Ahead of implant exposure, the next major complication, which might hamper the implant success would be wound dehiscence, which sometimes occurs during the first 10 days. Contributing factors of wound dehiscence include flap tension, continuous mechanical trauma or irritation associated with the loosening of the screws, incorrect incisions, and formation of sequestration of bone debris. We have found 10% of patients having wound dehiscence. Linkow<sup>[10]</sup> in 1956 also mentioned in his study poor suturing of the mucoperiosteal tissue immediately after the implant is inserted can cause wound dehiscence, and the suturing should not be too tight or too loose, and there should be sufficient exposure of the alveolar bone beyond the borders of the metal framework. Obwegeser<sup>[6]</sup> in their study in 1956 also reported wound dehiscence in their patients, and they mentioned it was because of insufficient vascularization, inadequate suturing, or infection of the wound margins. In our cases, dehiscence that was seen could be because of improper suturing, insufficient flap for closure, and closure done in tension.

Infection represents one of other factors contributing to the failure of any dental implant. At present, no single microorganism has been closely associated with colonization or infection of any implant system. Failing dental implants are associated with a microbial flora traditionally associated with periodontitis. *Staphylococcus aureus* has been demonstrated to have the ability to adhere to titanium surfaces. This may be significant in the colonization of dental implants and subsequent infections. The main cause of late-stage infection is contamination of recently inserted implants by the pathogenic

microflora of natural teeth. Contamination of the implants may be favored by the presence of necrotic and traumatized bony tissue or impaired host defense mechanisms. Characteristic clinical features are edema, swelling, purulent exudate, pain on palpation, or fistulae. In our study, all the implants were assessed clinically for infection according to surgical site infection criteria, of which two implants had the signs of infection; there was the presence of abscess in one of the implants followed by purulent discharge in other implants during the 1<sup>st</sup> and 3<sup>rd</sup> month postoperatively. Young *et al.* in 1983<sup>[7]</sup> in his study also reported infection in one patient, and he mentioned it was because of swelling, suppuration, pain, and heat. In hybrid implants, we found out that it was because of poor patient oral hygiene.

Pain is always associated with any type of surgical intervention postoperatively. In our study, all the patients were evaluated for pain using visual analog scale (0–10). All the patients complained of mild-to-moderate pain immediately postoperatively which lasted for 1 week. No patient had pain on subsequent follow-ups. Bailey *et al.*<sup>[9]</sup> in 1988 also reported pain and inflammation in 57% patients and it also gradually decreased with time in intensity.

Garefis<sup>[11]</sup> in 1978 suggests that placement of subperiosteal implant is a very long procedure and it cannot be done under local anesthesia and it has to be carried out in two different phases. However, in our study, we have performed it under local anesthesia with a mean time of 45 min.

Bodine *et al.*<sup>[12]</sup> in 1974 reported that the permanent fixation of the subperiosteal implant occurs by dense, collagenous, fibrous tissue encapsulation around the framework. In our study, the implant gains its stability by the cortical screws and by bone formation around the plate and screws.

In hybrid implants, we found difficulty in adjusting the implant on the mandible because of the narrow and knife edge ridges as compared to maxilla. However, the survival rate was more in mandible as compared to maxilla. In 1978 Golec<sup>[13]</sup> also evaluated 100 cases of subperiosteal implant and got a 4-year survival rate of 100%, 5-year survival rate of 96%, 6-year survival rate of 92%. He also concluded that the success rate is less in maxillary arch compared to mandibular arch.

Linkow<sup>[10]</sup> in 1956 put forward a new design endosseous implant to meet the functional demands that are placed on implants, especially in completely or near completely edentulous maxilla and to reduce the problems encountered in knife edge ridges. He called the design as blade-vent implant. According to him, the new design serves well in withstanding



lateral forces that are placed upon them. In our study, the hybrid implant that was used has got both subperiosteal and endosseous components which is similar to blade-vent implants, and it is aimed to very well handle atrophic maxilla without sinus lift and grafting procedures, and there is no risk of involvement of anatomical structures in mandible.

In the maxillary posterior, the proximity of the sinuses can create a problem for dental implants if there is minimal residual crestal bone (5 mm) for stability.<sup>[14,15]</sup> Ardekian *et al.*<sup>[16]</sup> found that maxillary sinus membrane perforations were more common in areas with a minimal amount (5 mm) of residual alveolar bone, so there is a need of sinus lifting procedure. Jung *et al.*<sup>[17]</sup> also reported the risk of maxillary sinus complications in implants which penetrated the bone and mucous membrane of the sinus floor at 2, 4, and 8 mm extensions if sinus lifting is not done. However, in our study, hybrid implant being a subperiosteal implant adapts over the cortical bone and hence alleviating the need of technique-sensitive sinus lift procedure.

When placing implants in the mandible, proper radiographs and pretreatment planning are done to ensure complete aversion of the inferior alveolar, mental, incisive, or lingual nerves so that a minimum distance of 2 mm is maintained.<sup>[18]</sup> Bartling *et al.*<sup>[19]</sup> observed 405 mandibular endosseous implants placed in 94 patients to determine the incidence of altered sensation using standard neurologic tests over a 6-month period. He found that nerve injury was present in 9% of patients. van Steenberghe *et al.*<sup>[20]</sup> also reported a similar incidence rate of 6.5% for altered sensation at 1 year after mandibular implant placement. Ellies and Hawker<sup>[21]</sup> also found an altered nerve sensation incidence of 36% in their patients. However, in our study, there was no incidence of nerve alteration or nerve injury to any patient.

According to Parel and Thayer,<sup>[22]</sup> potential problems that can complicate the placement of screws for fixation of the subperiosteal implants are:

1. Unless the screw is in total intimate contact with dense cortical bone, some types of resorptive process will occur
2. The chrome cobalt screws, which were used for fixation, may break
3. The screw can penetrate the sinus or the canal.

In case of hybrid implants, the worry for the proper adaptation of the framework is avoided as the plate component of the implant is malleable and can be adapted in close contact with the surface of the alveolar bone. None of the patients in our study experienced any sinus infection or nerve deficit after placement of the implant.

## CONCLUSION

Hybrid implant system is a newer system for the rehabilitation of edentulous spaces with inadequate bone which is cost-effective and less technique sensitive and its design and placement technique allows its use in thin resorbed ridges without doing sinus lift and alveolar canal modification, and it requires minimum armamentarium for implant placement. Till date, no literature or evidence is available on the success of hybrid implants. Our study provides a basis for further research work on this system with larger samples and long follow-ups to prove their efficacy to widen the horizon for the use of hybrid implants in oral rehabilitation with confidence.

## Declaration of patient consent

The authors certify that they have obtained all appropriate patient consent forms. In the form the patient(s) has/have given his/her/their consent for his/her/their images and other clinical information to be reported in the journal. The patients understand that their names and initials will not be published and due efforts will be made to conceal their identity, but anonymity cannot be guaranteed.

## Financial support and sponsorship

Nil.

## Conflicts of interest

There are no conflicts of interest.

## REFERENCES

1. Mani V, Sivaprasad KK, George A, Sankar Vinod V, Mathew M, Paul S, *et al.* Hybrid implant: A Novel implant system. *J Maxillofac Oral Surg* 2015;14:720-7.
2. Horan TC, Gaynes RP, Martone WJ, Jarvis WR, Emori TG. CDC definitions of nosocomial surgical site infections, 1992: A modification of CDC definitions of surgical wound infections. *Infect Control Hosp Epidemiol* 1992;13:606-8.
3. Gustav Dahl. *Contemporary Implant Dentistry*. 2<sup>nd</sup> ed. St. Louis: Mo: Mosby; 1999.
4. Aaron: American Academy of Implant Dentistry. 1948. Available from: <http://www.aaid.com/about/History.html>. [Last accessed on 2017 Sep 02].
5. Brånemark PI. A 15 year study of osseointegrated implants in the treatment of the edentulous jaw. *Int J Oral Surg* 1981;10:387-416.
6. Obwegeser HL. Experiences with subperiosteal implants. *Oral Surg Oral Med Oral Pathol* 1956;12:777-86.
7. Young L Jr., Michel JD, Moore DJ. A twenty-year evaluation of subperiosteal implants. *J Prosthet Dent* 1983;49:690-4.
8. Peev S, Sabeva E. Subperiosteal implants in treatment of total and partial edentulism – A long term follow up. *Int J Sci Res* 2013;2:12319-7064.
9. Bailey JH, Yanase RT, Bodine RL. The mandibular subperiosteal implant denture: A fourteen-year study. *J Prosthet Dent* 1988;60:358-61.
10. Linkow LI. The unilateral implant. *D Dig* 1970;60:302-6.
11. Garefis PN. Complete mandibular subperiosteal implants for edentulous mandibles. *J Prosthet Dent* 1978;39:670-7.
12. Bodine RL. Evaluation of 27 mandibular subperiosteal implant dentures

- after 15 to 22 years. *J Prosthet Dent* 1974;32:188-97.
13. Golec TS. Maxillary full subperiosteal implants. Clinical review of 18 cases. *J Oral Implantol* 1978;8:98-107.
  14. Shin HI, Sohn DS. A method of sealing perforated sinus membrane and histologic finding of bone substitutes: A case report. *Implant Dent* 2005;14:328-33.
  15. Kim SG, Mitsugi M, Kim BO. Simultaneous sinus lifting and alveolar distraction of the atrophic maxillary alveolus for implant placement: A preliminary report. *Implant Dent* 2005;14:344-6.
  16. Ardekian L, Oved-Peleg E, Mactei EE, Peled M. The clinical significance of sinus membrane perforation during augmentation of the maxillary sinus. *J Oral Maxillofac Surg* 2006;64:277-82.
  17. Jung JH, Choi BH, Zhu SJ, Lee SH, Huh JY, You TM, *et al.* The effects of exposing dental implants to the maxillary sinus cavity on sinus complications. *Oral Surg Oral Med Oral Pathol Oral Radiol Endod* 2006;102:602-5.
  18. Misch K, Wang HL. Implant surgery complications: Etiology and treatment. *Implant Dent* 2008;17:159-68.
  19. Bartling R, Freeman K, Kraut RA. The incidence of altered sensation of the mental nerve after mandibular implant placement. *J Oral Maxillofac Surg* 1999;57:1408-12.
  20. van Steenberghe D, Lekholm U, Bolender C, Folmer T, Henry P, Herrmann I, *et al.* Applicability of osseointegrated oral implants in the rehabilitation of partial edentulism: A prospective multicenter study on 558 fixtures. *Int J Oral Maxillofac Implants* 1990;5:272-81.
  21. Ellies LG, Hawker PB. The prevalence of altered sensation associated with implant surgery. *Int J Oral Maxillofac Implants* 1993;8:674-9.
  22. Parel SM, Thayer HH. An alternative method of unilateral subperiosteal implant fixation: A preliminary report. *J Prosthet Dent* 1972;28:434-8.