

Endovascular therapy for floating thrombus in the inferior vena cava

Journal of International Medical Research
48(9) 1–9

© The Author(s) 2020

Article reuse guidelines:

sagepub.com/journals-permissions

DOI: 10.1177/0300060520959990

journals.sagepub.com/home/imr



Zhi-Wen Zhang¹ , Xue-Ming Chen¹,
Ren-Ming Zhu¹, Chen-Yu Li¹, Hong-Zhi Yu¹
and Zhong-Tao Zhang² 

Abstract

Objective: We aimed to summarize the clinical characteristics of floating thrombus in the inferior vena cava (IVC).

Methods: From January 2014 to June 2019, four patients with floating thrombus in the IVC were admitted to our hospital and underwent intracavitary therapy. Diagnosis, therapy, and clinical characteristics of floating thrombus were summarized.

Results: Three patients presented with pulmonary embolism. Three of the patients had a floating thrombus discovered by inferior venacavography and one was found by contrast-enhanced computed tomography. Two patients had deep venous thrombosis in the lower extremities. One patient had a double IVC, one had left iliac vein compression syndrome, and one had right renal phlebothrombosis. The four patients underwent implantation of a temporary IVC filter and were treated with anti-coagulation, debulking, and thrombolysis. All four patients achieved satisfactory results.

Conclusions: Floating thrombus in the IVC is often caused by spread of branch vein thrombosis, and is more likely to lead to pulmonary embolism. Anti-coagulant therapy and debulking under the protection of filters can achieve satisfactory clinical results.

Keywords

Inferior vena cava, floating thrombus, pulmonary embolism, catheter-directed thrombolysis, anti-coagulant therapy, inferior venacavography

Date received: 8 April 2020; accepted: 24 August 2020

¹Department of Vascular Surgery, Beijing Friendship Hospital, Capital Medical University, Beijing, China

²Department of General Surgery, Beijing Friendship Hospital, Capital Medical University, Beijing, China

Corresponding author:

Zhong-Tao Zhang, Department of General Surgery, Beijing Friendship Hospital, Capital Medical University, 95 Yong-an Road, Xi-Cheng District, Beijing 100050, China. Email: zhangzht@ccmu.edu.cn



Introduction

Floating thrombus in the inferior vena cava (IVC) is a critical condition owing to the danger of pulmonary embolism (PE).¹ Many patients have a floating thrombus after receiving a diagnosis of PE. Floating thrombus is not easily diagnosed clinically, but is usually discovered by contrast-enhanced computed tomography (CT) or by implanting an IVC filter for inferior venacavography. We report here four cases of floating thrombus in the IVC.

Case 1

A 52-year-old woman was hospitalized in the Department of Endocrinology because of type 2 diabetes mellitus. On the fourth day, the patient suddenly felt suffocated by hypoxemia. Chest CT showed an embolism in the right pulmonary artery (Figure 1a). The patient developed deep venous thrombosis (DVT) in the lower extremities 4 years previously, but she did not regularly take anti-coagulant drugs. Ultrasound also showed an existing thrombosis with recanalization in the lower extremities. Inferior venacavography showed a floating thrombus at the confluence of the renal vein and IVC. The Tempofilter™ II filter (B. Braun, Melsungen, Germany) was immediately implanted above the thrombus via the right jugular vein for venipuncture (Figure 1d). After surgery, low molecular weight heparin (LMWH) was used for anti-coagulation. Peripheral thrombolytic therapy was performed because the patient's blood pressure and heart rate were normal. Post-surgery abdominal CT showed a floating thrombus in the IVC (Figure 1b) and right renal vein thrombosis (Figure 1c). Through right femoral venipuncture, transcatheter thrombus aspiration was performed on the second day after surgery. A small portion of the thrombus was extracted during surgery, and a

pigtail catheter remained under the thrombus for thrombolytic therapy. Pathological examination of the specimen confirmed a thrombus. Positron emission tomography CT showed no evidence of malignancy. The thrombus in the IVC was greatly reduced (Figure 1e) 7 days after thrombolysis. Therefore, the thrombolytic catheter was removed. A CT re-examination 2 weeks after implantation of the filter showed that the pulmonary artery and IVC thrombosis was greatly reduced and right renal vein thrombosis had disappeared (Figure 1f). The patient's symptoms (e.g., chest distress) had also disappeared and the Tempofilter II filter was removed. After discharge, the patient was prescribed oral warfarin. Six months later, ultrasound showed that the IVC was still patent.

Case 2

A 46-year-old man with sudden syncope for 8 hours was hospitalized. He gradually recovered consciousness after approximately 3 minutes of syncope. The patient presented with wheezing and hypoxemia, and no thrombus was observed on ultrasound of the lower extremities. Contrast-enhanced CT showed a double pulmonary artery embolism (Figure 2a). Immediate inferior venacavography through the right femoral vein was performed as the emergency surgery. The IVC diameter was thin and inferior venacavography through the left femoral vein showed a double IVC with a floating thrombus. The Tempofilter II filter (B. Braun) was implanted via the right jugular vein and the filter was positioned above the double IVC confluence. Pulmonary angiography and pulmonary catheter-directed thrombolysis (CDT) were performed through the right subclavian vein, while CDT was performed through the left femoral vein. LMWH was used for anti-coagulation and urokinase was pumped into a thrombolytic tube after

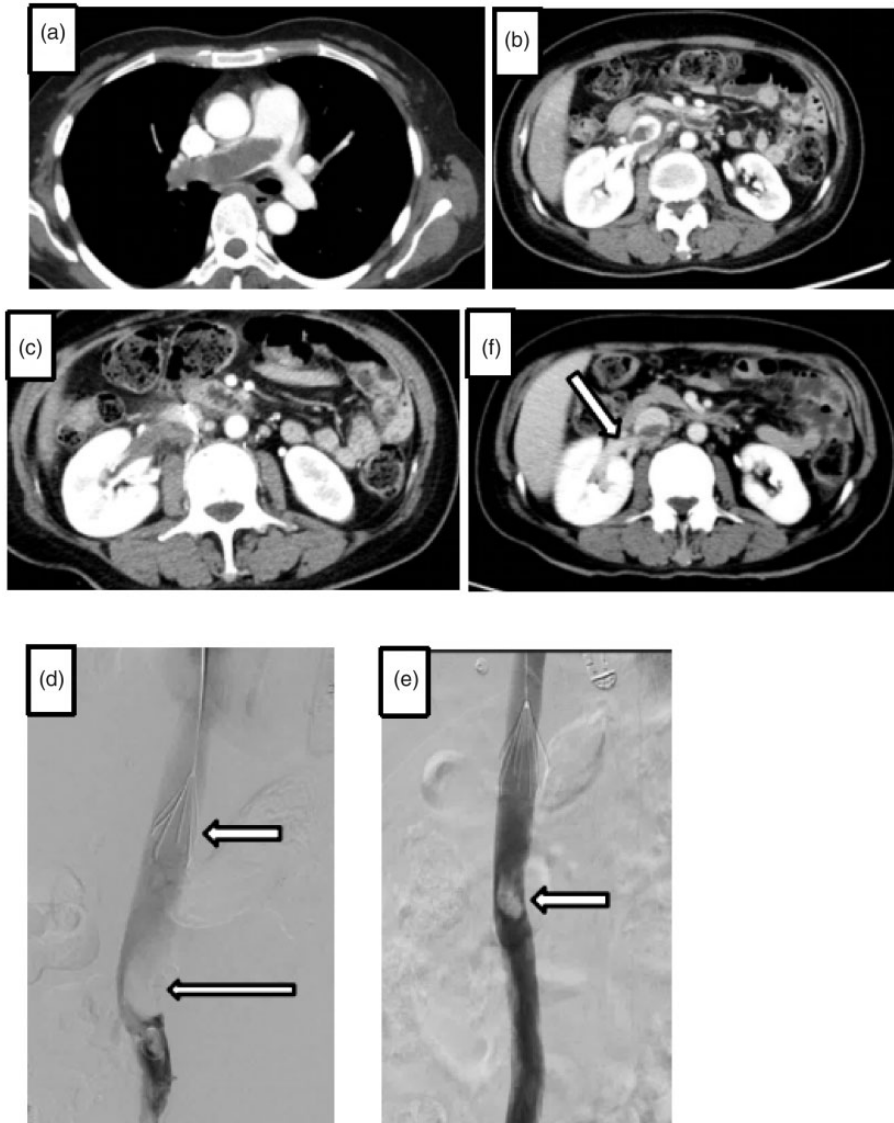


Figure 1. a: Chest computed tomography shows right pulmonary artery embolism. b: Chest computed tomography shows a floating thrombus in the inferior vena cava. c: Inferior vena cava and right renal vein thrombosis. d: Inferior venacavography shows the inferior vena cava and the Tempofilter II filter (arrows). e: The inferior vena cava thrombus (arrow) is decreased after thrombolysis. f: Computed tomography re-examination at 2 weeks shows that the right renal vein thrombus has disappeared (arrow).

surgery. Three days later, the patient underwent another inferior venacavography examination. Pulmonary artery and IVC blood flow was normal and the thrombus

had disappeared. The filter was removed after 1 month. Warfarin was administered orally after discharge. During a follow-up of 2 years, the patient did not present with

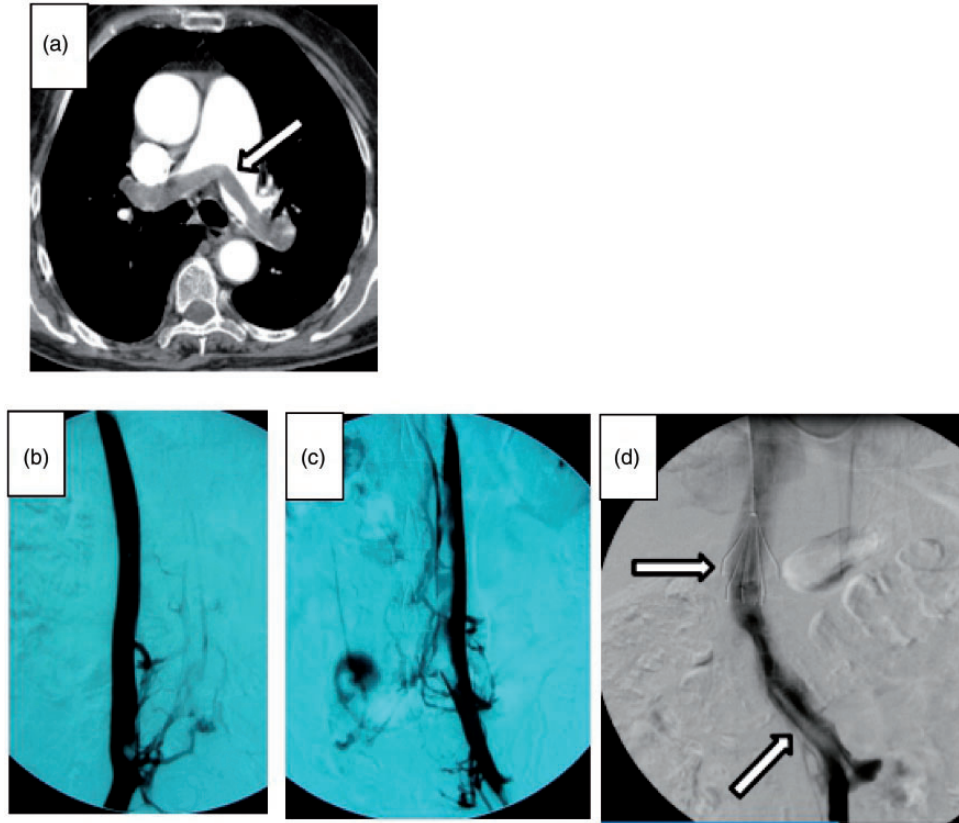


Figure 2. a: Chest computed tomography shows bilateral pulmonary artery emboli (arrow). b: Inferior venacavography of the right femoral vein. c: Inferior venacavography of the left femoral vein. d: Inferior vena cava filter and floating thrombus in the inferior vena cava (arrows).

any signs (e.g., venous insufficiency in the lower extremities) or symptoms (e.g., shortness of breath).

Case 3

A 68-year-old man was admitted to our hospital after 12 hours of sudden syncope lasting for 2 minutes, which was accompanied by suffocating. A CT scan carried out at another hospital showed PE and the patient was transferred to our hospital for treatment. No thrombosis was observed by lower extremity venous ultrasonography. Abdominal contrast-enhanced CT showed

a thrombus in the left common iliac vein, which led to a floating thrombus in the IVC (Figure 3a). The Tempofilter II filter (B. Braun) was immediately implanted through the right jugular vein, and iliac vein CDT was performed via the left femoral vein. After 4 days of angiography, the IVC thrombus disappeared, the left common iliac vein was compressed (Figure 3b), and stent (14 × 60 mm, E-Luminexx; Bard, Karlsruhe, Germany) implantation of the left iliac vein was performed (Figure 3c). The filter was removed 2 weeks after surgery. Oral warfarin as an anti-coagulant therapy was provided when the patient

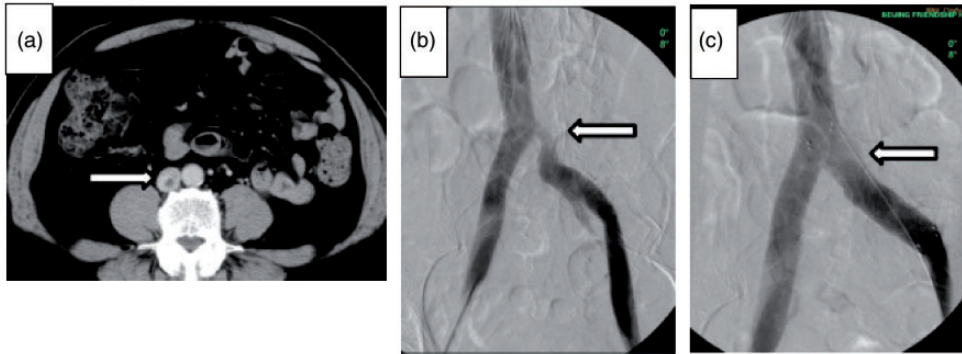


Figure 3. a: A floating thrombus (arrow) in the inferior vena cava and left common iliac vein. b: Angiography shows left common vein stenosis after thrombolysis (arrow). c: Inferior venacavography shows when the left iliac vein stent was implanted (arrow).

was discharged. A review of the patient by CT scan 1 year later showed that the iliac vein stent and IVC blood flow were normal.

Case 4

A 41-year-old man experienced swelling in the lower extremities for 10 days and was admitted to the hospital with aggravated swelling for 2 days. He did not experience suffocation or chest pain. An ultrasound report from another hospital showed DVT in the left lower extremity and the left lower limb had obvious swelling. Percutaneous inferior venacavography through the left femoral vein was performed, which showed a floating thrombus in the IVC (Figure 4a). The thrombus continued to spread from the left common iliac vein. The Tempofilter II filter (B. Braun) was immediately implanted through the right jugular vein, and then percutaneous mechanical thrombectomy was performed with the Aspirex[®]S (Straub Medical, Wangs, Switzerland) through the left femoral vein. The thrombus fell off into the Tempofilter II (Figure 4b) and a thrombolytic catheter was implanted for further thrombolytic therapy. CDT was performed 5 days after surgery. Two weeks later,

angiography showed normal blood flow in the IVC, left iliac vein, and femoral vein. Therefore, the filter was removed. After discharge, the patient took oral rivaroxaban for anti-coagulant therapy. A CT review showed that the IVC remained patent after 7 months.

Discussion

Approximately 30% of patients with thrombus can develop PE.² Voet et al.³ reported that the mortality rate from floating thrombus in the IVC in the lower extremities was 10.2% (4/39) and the incidence of PE was 43.6% (17/39). Three of our patients presented with severe PE and a further examination showed floating thrombus in the IVC. In the fourth case, the thrombus fell off into the filter during mechanical thrombectomy, which suggests that the presence of a floating thrombus is prone to causing PE. The most frequent causes of PE include floating thrombus in the lumen, contraction and expansion of a large IVC, which is affected by breathing and abdominal pressure, and an impacted thrombus by blood flow of large vessel branches, such as the renal veins and iliac veins.

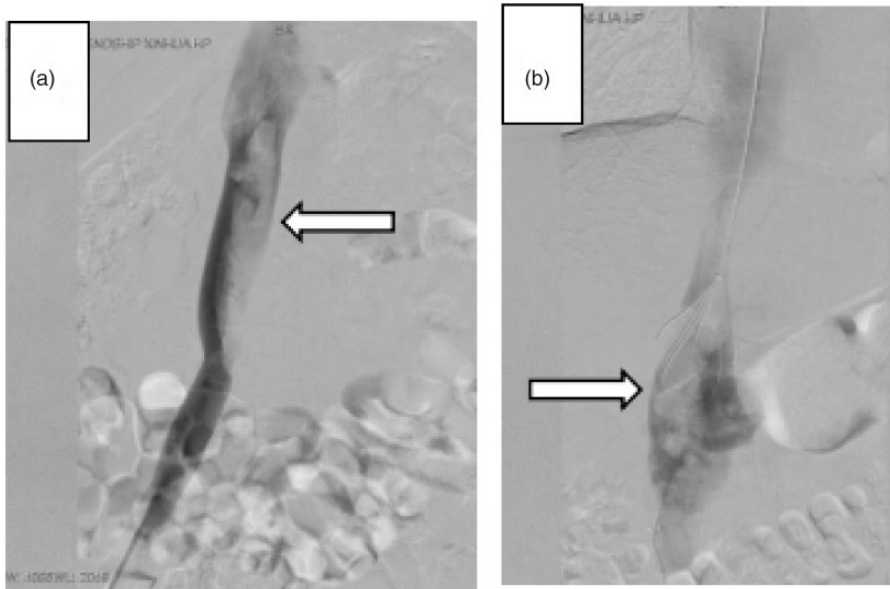


Figure 4. a: Floating thrombus in the inferior vena cava (arrow). b: The thrombus fell off into the Tempofilter II filter (arrow).

At present, there is no recognized diagnostic criterion for a floating thrombus. A floating thrombus is defined as not adhering to the vessel wall completely and floating in the lumen at the proximal part when imaged by CT or angiography. Voet et al.³ described the ultrasonographic features of floating DVT in the lower extremities. However, ultrasound is more accurate for diagnosing venous thrombus in the limbs compared with thrombus in the abdominal/pelvic cavity. This is because there are many interfering factors, which differ greatly between individuals and with different techniques. Angiography can determine the shape of the thrombus by assessing blood flow in the vessel. Venous CT shows the relationship between the thrombus and the venous wall, which is beneficial for diagnosis. Hussein et al.⁴ described the characteristics of a case of a floating thrombus in the IVC. In their case, the thrombus was large and accounted for

70% of the lumen, and there was no clear association with the vessel wall. Johnson et al.⁵ reported a case of floating thrombus above the filter as diagnosed by CT, which clearly showed that the thrombus was floating in the IVC. There was no completely suspended thrombus, which is not in accordance with the hemodynamic principle. A floating thrombus must have an attachment point, and the renal veins and iliac veins are common attachment points. The thrombus in our cases originated from the renal veins or iliac veins. Voet et al.³ found that a floating thrombus in the lower limb vein developed from the proximal end of the previous thrombus. Ovarian venous thrombus can also spread to the IVC.^{6,7} Brodmann et al.⁸ reported a case of internal iliac vein thrombosis that extended to the IVC and formed a floating thrombus. Johnson et al.⁵ reported a case of floating thrombus above the IVC filter and the root of the thrombus was connected to the filter.

This finding indicated that the floating thrombus had an attachment point that resisted the force of blood flow. Although observing a thrombus falling off is difficult, there is a certain course in the time of the fall of the thrombus. Based on findings from previous cases, the conditions for formation of a floating thrombus can be estimated as follows. A proximal thrombus spreads upward, a branch vein enters the vein increasing its thickness, and there is no thrombosis in the branch vein to provide blood flow for the cavity. This in turn forms a floating thrombus. The cases evaluated in this study fit this described pattern.

Stasis, hypercoagulability, and intimal injury are the triad of thrombus formation. Common risks of DVT in the lower extremities can also affect IVC thrombus,⁹ but as a large vein behind the peritoneum, the IVC has a much lower incidence of thrombus compared with limb veins. The annual incidence rate of IVC thrombus in the lower extremities is as high as 48–122/100,000 people, and of these patients, 2.6% to 4% present with IVC thrombus.¹⁰ In this study, two patients had iliac vein thrombus, which continued to the IVC. One patient had a double IVC malformation and one had a history of DVT, and both of these conditions have a high risk of thrombosis. Formation of primary IVC thrombosis is relatively rare and most likely associated with local lesions, such as venous malformations and tumor compression.^{9,11,12} IVC malformation is rare and its incidence rate is approximately 0.3% to 0.6% among healthy people.⁹ Although there is a collateral circulation, IVC malformations can still cause vein backflow obstruction and venous intravenous hypertension, causing venous thrombosis. Young patients with spontaneous bilateral DVT should consider the possibility congenital IVC malformations.^{1,13,14} These patients always have subclinical symptoms. Stasis and intimal injury occur in iliac compression syndrome, which

may cause thrombosis, and in turn may spread along the iliac vein to the IVC.^{2,9,11} Thrombosis in the renal vein can develop because of numerous factors, such as tumors, infections, nephroma, and ovarian venous thrombosis. Renal venous thrombosis can also spread to the IVC.^{7,15}

In the present study, PE was found in two patients, although there was no DVT in the lower extremities. IVC and iliac vein thrombosis were identified by further examinations. Similar cases were also reported by Brodmann et al.⁸ Therefore, if no thrombosis is observed in DVT in the lower extremities, a search for the source of PE needs to be continued, mainly in the IVC and iliac vein.

Floating thrombosis is likely to cause PE. Brodmann et al.⁸ found that a proximal floating thrombosis may be a direct source of PE, causing PE to continue to deteriorate in the early stages. Golowa et al.¹¹ emphasized that filters should be considered when treating thrombus in the IVC because it is generally widespread and may float freely. Therefore, filters should be implanted to treat a floating thrombus in the IVC. How to choose the filter depends on the location of the thrombus in the IVC and on the medical condition of the hospital. The Tempofilter II is implanted via the jugular vein to avoid passing through the thrombus in the IVC, and a filter with a support rod can be placed above the renal vein without fear of displacement.

Anti-coagulation is the main treatment for venous thrombosis.² Anti-coagulation treatment can inhibit formation of a new thrombus, and promote thrombolysis and venous recanalization. There needs to be awareness of the side effects of heparinization, including bleeding, heparin-induced thrombocytopenia, osteoporosis, and elevated transaminase levels. We chose to use LMWH for anticoagulation in our study, instead of unfractionated heparin. The advantages of LMWH for clinical use are

as follows. (1) LMWH has superior pharmacokinetic properties, and therefore, it is typically administered in fixed or weight-adjusted doses for thromboprophylaxis and therapeutic purposes. (2) Monitoring of anti-coagulation is not generally necessary, which offers great convenience. (3) The incidence of side effects of LMWH is significantly lower than that for unfractionated heparin.¹⁶ Methods to reduce venous thrombosis include CDT, catheter aspiration, percutaneous mechanical thrombectomy, and pharmacomechanical CDT.^{11,17} There is continuous blood flow through a floating thrombus when anti-coagulation therapy is used. Therefore, performing CDT combined with other debulking techniques can achieve good results. All three cases of severe PE in this group were effectively treated, and the IVC thrombus disappeared or was greatly reduced. This finding indicates that anti-coagulation therapy and debulking are safe and effective in this situation.

Conclusion

Floating thrombus in the IVC is mostly caused by the spread of a branch vein thrombus, which is likely to cause PE. Anti-coagulation therapy and a debulking operation under the protection of filters can achieve satisfactory clinical results.

Acknowledgement

The authors would like to thank Professor Hai Feng for helpful discussions.

Declaration of conflicting interest

The author(s) declared no potential conflicts of interest with respect to the research, authorship, and/or publication of this article.

Ethics statement

Informed consent was obtained from the patients for publication of this case report.


This study was approved by the Ethics Committee of Beijing Friendship Hospital, Capital Medical University.

Funding

The author(s) disclosed receipt of the following financial support for the research, authorship, and/or publication of this article: This research received no specific grant from any funding agency in the public, commercial, or not-for-profit sectors.

ORCID iDs

Zhi-Wen Zhang  <https://orcid.org/0000-0001-8137-9574>

Zhong-Tao Zhang  <https://orcid.org/0000-0002-4718-6821>

References

1. McAree BJ, O'Donnell ME, Fitzmaurice GJ, et al. Inferior vena cava thrombosis: a review of current practice. *Vasc Med* 2013; 18: 32–43.
2. Alkhouli M, Morad M, Narins CR, et al. Inferior vena cava thrombosis. *JACC Cardiovasc Interv* 2016; 9: 629–643.
3. Voet D and Afschrift M. Floating thrombi: diagnosis and follow-up by duplex ultrasound. *Br J Radiol* 1991; 64: 1010–1014.
4. Hussein R, Alrabyee K, Karrar A, et al. Large floating thrombus in the inferior vena cava. *Int J Health Sci (Qassim)* 2020; 14: 48–51.
5. Johnson AM, Bjarnason H, Shields R, et al. Removal of floating inferior vena cava thrombus with the AngioVac device. *Vasc Med* 2015; 20: 190–192.
6. Sinha D, Yasmin H and Samra JS. Postpartum inferior vena cava and ovarian vein thrombosis – A case report and literature review. *J Obstet Gynaecol* 2005; 25: 312–313.
7. Wysokinska EM, Hodge D and McBane RD. Ovarian vein thrombosis: Incidence of recurrent venous thromboembolism and survival. *Thromb Haemost* 2006; 96: 126–131.
8. Brodmann M, Gary T, Hafner F, et al. Massive pulmonary embolism caused by internal iliac vein thrombosis with free-

- floating thrombus formation in the inferior vena cava. *Ann Vasc Surg* 2012; 26: 420.e5-7.
9. Linnemann B, Schmidt H, Schindewolf M, et al. Etiology and VTE risk factor distribution in patients with inferior vena cava thrombosis. *Thromb Res* 2008; 123: 72–78.
 10. Wagenhäuser MU, Dimopoulos C, Antakyali K, et al. Clinical outcomes after direct and indirect surgical venous thrombectomy for inferior vena cavathrombosis. *J Vasc Surg Venous Lymphat Disord* 2019; 7: 333–343.e2.
 11. Golowa Y, Warhit M, Matsunaga F, et al. Catheter directed interventions for inferior vena cava thrombosis. *Cardiovasc Diagn Ther* 2016; 6: 612–622.
 12. Cornman-Homonoff J, Kishore S, Camacho JC, et al. Intravascular ultrasound-guided extraction of free-floating inferior vena cava tumor thrombus using the ClotTriever mechanical thrombectomy device. *J Vasc Interv Radiol* 2019; 30: 1679–1682.e1.
 13. Spentzouris G, Zandian A, Cesmebasi A, et al. The clinical anatomy of the inferior vena cava: a review of common congenital anomalies and considerations for clinicians. *Clin Anat* 2014; 27: 1234–1243.
 14. Chee YL, Culligan DJ and Watson HG. Inferior vena cava malformation as a risk factor for deep venous thrombosis in the young. *Br J Haematol* 2001; 114: 878–880.
 15. Rottenstreich A, Barzilai M, Da'as N, et al. Active malignancy in patients with renal vein thrombosis: influence upon clinical course and survival. *Clin Exp Nephrol* 2017; 21: 49–54.
 16. Garcia DA, Baglin TP, Weitz JI, et al. Parenteral anticoagulants: Antithrombotic Therapy and Prevention of Thrombosis, 9th ed: American College of Chest Physicians Evidence-Based Clinical Practice Guidelines. *Chest* 2012; 141: e24S–e43S.
 17. Sista AK, Vedantham S, Kaufman JA, et al. Endovascular interventions for acute and chronic lower extremity deep venous disease: state of the art. *Radiology* 2015; 276: 31–53.