

# A Practical Approach to the Diagnosis and Management of Optic Neuritis

Etienne Benard-Seguin<sup>1</sup>, Fiona Costello<sup>1,2</sup>

Departments of <sup>1</sup>Surgery in Ophthalmology and <sup>2</sup>Clinical Neurosciences, University of Calgary, Calgary, AB, Canada

## Abstract

Optic neuritis (ON), as an umbrella term, refers to a spectrum of inflammatory optic neuropathies arising from a myriad of potential causes. In its most common form, “typical” ON presents as a unilateral, painful subacute vision loss event in young Caucasian women. The Optic Neuritis Treatment Trial (ONTT) has historically guided our treatment of ON, and taught us important lessons about the clinical presentation, visual prognosis, and future risk of multiple sclerosis (MS) diagnosis associated with this condition. However, in the decades since the ONTT, several immune-mediated conditions such as neuromyelitis optica spectrum disorder (NMOSD), and myelin-oligodendrocyte glycoprotein IgG associated disease (MOGAD) have been discovered, complicating the clinical approach to ON. Unlike MS, other central nervous system (CNS) inflammatory conditions are associated with ON subtypes that are potentially blinding, and prone to recurrence. Owing to differences in the clinical presentation, serological biomarkers, radiological findings, and prognostic implications associated with MS ON, NMOSD ON, and MOGAD ON subtypes, it is imperative that clinicians be aware of the diagnostic approach and management options for these conditions.

**Keywords:** Myelin-oligodendrocyte glycoprotein, neuromyelitis optica spectrum disorder, optic neuritis, good, multiple sclerosis

## OVERVIEW

Optic neuritis (ON) is an inflammatory optic nerve injury arising from a variety of potential causes. ON may be sporadic in nature or occur in association with primary central nervous system (CNS) disorders, systemic diseases, paraneoplastic syndromes, infections, or drug-related side effects.<sup>[1-3]</sup> Classically, “typical” ON is heralded by painful, subacute onset vision loss, dyschromatopsia, and visual field defects. Unilateral or asymmetric bilateral cases of ON will also have a relative afferent pupillary defect in the affected eye; or in the case of bilateral involvement, the more severely affected eye.<sup>[1]</sup> The fundus examination may reveal a normal or edematous optic nerve in the setting of acute ON, but features of vitreous inflammation, optic disc hemorrhage, a macular star, or severe optic disc swelling are considered to be red flags and should prompt consideration for an alternate diagnosis.<sup>[1]</sup> The Optic Neuritis Treatment Trial (ONTT) characterized the “typical” presentation of ON cases that are idiopathic in origin (sporadic ON) or represent a first demyelinating event in individuals who later develop multiple sclerosis (MS).<sup>[1-4]</sup> In recent years, the discovery of novel serological biomarkers have helped identify cases previously categorized as cryptogenic ON or chronic relapsing inflammatory optic neuropathy (CRION) as manifestations of neuromyelitis optica spectrum disorder (NMOSD) or myelin-oligodendrocyte glycoprotein IgG associated disease (MOGAD). Cases that were previously categorized as cryptogenic ON or chronic relapsing inflammatory ON (CRION) are now recognized as manifestations of neuromyelitis optica spectrum disorder (NMOSD) or myelin-oligodendrocyte glycoprotein IgG associated disease (MOGAD).<sup>[5,6]</sup>

In this review, we will discuss the diagnostic approach to ON, review common ON subtypes that are encountered in clinical practice, and highlight how acute and long-term treatment strategies differ between ON variants. Finally, we will synthesize this information in a simple flowchart illustrating our diagnostic approach to acute ON [Figure 2].

## TYPICAL VERSUS ATYPICAL OPTIC NEURITIS: AVOID THE PERILS OF MISDIAGNOSIS

### Typical optic neuritis

Our understanding about “typical” ON has been derived from the original ONTT and subsequent 15-year follow-up.<sup>[1,4]</sup> This multicenter randomized placebo-controlled study enrolled 457 participants, aged 18–46 years with incident acute unilateral ON within 8 days of onset of vision loss.<sup>[4]</sup> The aim of the study was to determine the safety and the benefits of intravenous methylprednisolone (IVMP) versus oral steroids

**Address for correspondence:** Dr. Fiona Costello,  
7007 14 St SW, Calgary, AB T2V 1P9, Calgary, Alberta, Canada.  
E-mail: Fiona.Costello@albertahealthservices.ca

**Submitted:** 18-Feb-2022 **Accepted:** 19-Mar-2022 **Published:** 21-Jun-2022

This is an open access journal, and articles are distributed under the terms of the Creative Commons Attribution-NonCommercial-ShareAlike 4.0 License, which allows others to remix, tweak, and build upon the work non-commercially, as long as appropriate credit is given and the new creations are licensed under the identical terms.

**For reprints contact:** WKHLRPMedknow\_reprints@wolterskluwer.com

**DOI:** 10.4103/aian.aian\_170\_22

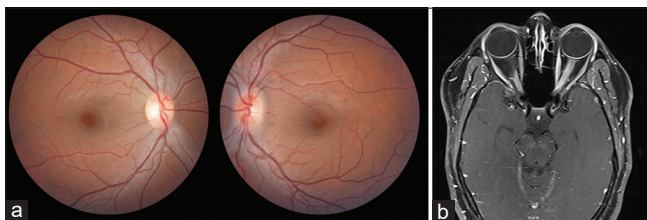
on visual outcomes. Patients were either treated with oral prednisone (1 mg/kg daily for 14 days), IVMP (250 mg every 6 h for 3 days, followed by oral prednisone 1 mg/kg daily for 11 days), or oral placebo. Long-term follow-up showed that the only benefit of corticosteroids was hastened visual recovery within the first 2 weeks.<sup>[4,7]</sup>

The incidence of ON varies from 1.4 to 33 per 100,000 people, depending on diagnostic accuracy, efficiency of case capture, and population demographics.<sup>[6]</sup> Typical ON (see key points box) is heralded by pain with eye movements in 92% of cases that may progress over a week.<sup>[1,3,4]</sup> At the onset of symptom, high contrast visual acuity (HCVA) loss may range from 20/20 to no light perception; in fact, approximately 66% of ONTT patients had HCVA of 20/200 or better at nadir, and only 3% had a visual acuity of no light perception.<sup>[3,4]</sup> Dyschromatopsia, contrast sensitivity loss, and visual field abnormalities are common in the setting of acute ON. Uthoff's phenomenon, namely a transient worsening of vision with heat or exertion, and photopsias are also reported.<sup>[1]</sup> Most patients demonstrate improvement in HCVA by at least a line or two, within 3 weeks, and failure to do so should be considered a "red flag".<sup>[3]</sup> The natural history of typical ON is generally good, with >90% of patients achieving a HCVA of 20/40 or better after a year.<sup>[1,3]</sup>

#### Key Points: Clinical Profile of ONTT Patients

- Young (mean age 31.8 years)
- Caucasian (85%)
- Female (77%)
- Unilateral ON (100%)
- Pain with eye movement (92%)
- Absence of disc edema (65%)

The ONTT participants were predominantly young, white women.<sup>[4]</sup> Serological testing of 177 patients enrolled in the ONTT for AQP4-IgG and MOG-IgG antibodies found only three positive MOG-IgG (1.7%), and no seropositive AQP4-IgG cases.<sup>[8]</sup> All three MOG IgG patients presented with disc edema, and two patients had recurrent ON.<sup>[8]</sup> The observations by Chen and colleagues<sup>[8]</sup> indicate that patients with "typical" ON features are unlikely to ultimately be diagnosed with NMOSD or MOGAD. However, the findings from the ONTT pertaining to treatment effects and prognosis are not extendable to all ON patients, particularly for those who fall outside the inclusion criteria of this study.



**Figure 1:** Patient with bilateral MOGAD ON. (a) Optic disc edema is noted in the left eye. (b) Longitudinally extending enhancement of the left greater than right intraorbital optic nerve is noted

## Atypical ON subtypes

### NMOSD ON

NMOSD is an autoimmune astrocytopathy that is often characterized by recurrent ON and transverse myelitis.<sup>[3]</sup> It was first described by Eugène Devic, in 1894.<sup>[9]</sup> In 2004, Lennon and colleagues identified aquaporin-4 (AQP4) water channels expressed on astrocytic foot processes as the target of NMO-IgG.<sup>[10]</sup> This discovery laid the groundwork for the first NMOSD antibody assay and informed our understanding regarding the pathogenesis of the disease.

NMOSD ON tends to manifest at an older age (mean age 40 years) than MS ON and has a female to male ratio of 9:1.<sup>[3]</sup> Pain is variable; some studies report that as few as 53% of NMOSD ON patients endorse pain at presentation.<sup>[11]</sup> The prevalence of NMOSD increases in non-white patient populations, and NMOSD ON is more likely to affect Asians, and patients of Afro-Caribbean extraction.<sup>[12,13]</sup> Regions of the world with a higher black population such as Martinique have reported a 2.6-fold greater prevalence of NMOSD than predominantly white areas such as Olmsted County in the United States.<sup>[14]</sup> Other studies from Australia and New Zealand have found a three-times higher prevalence in Asian individuals than non-Asian individuals.<sup>[14]</sup>

As per the 2015 diagnostic criteria for NMOSD by Wingerchuk and colleagues, ON that is severe (visual acuities worse than 20/200) at presentation, bilateral in onset, and characterized by altitudinal defects should prompt consideration for NMOSD.<sup>[15]</sup> Magnetic resonance imaging (MRI) views of brain and orbits will often show longitudinal lesions of the posterior intracranial optic nerve segments extending back to involve the chiasm, and sometimes, optic tracts.<sup>[15]</sup>

### MOGAD ON

Previously, MOG-IgG was thought to be involved in CNS demyelination in the context of MS.<sup>[16]</sup> However, it has been shown that MOG-IgG is a biomarker for a distinct demyelination process different than both MS and NMOSD.<sup>[17]</sup> While an antigenic target has remained elusive in MS, autoantibodies are believed to perpetuate optic nerve injury through complement-mediated cytotoxicity, antibody-dependent cell-mediated phagocytosis and cytotoxicity, and antigen presentation in MOGAD.<sup>[6]</sup> From a clinical perspective, MOGAD ON is often associated with pain, bilateral onset, and recurrence. What distinguishes MOGAD ON from NMOSD ON and MS ON is the observation that MOGAD ON patients have more severe optic disc edema [Figure 1].<sup>[18]</sup> Notably, MOGAD ON may affect patients from a wide age range at onset, but this condition may be more common in pediatric patient populations. The Pediatric Eye Disease Investigator Group (PEDIG) published a cohort study of 44 pediatric ON cases and found that 16% of the cohort were positive for MOGAD.<sup>[19]</sup> Moreover, patients from different ethnic backgrounds may be affected by MOGAD.<sup>[12,18]</sup> The MRI features of MOGAD ON include longitudinal lesions of the intra-orbital optic nerve segments, with perineural enhancement [Figure 1].<sup>[18]</sup>

## APPROACH TO OPTIC NEURITIS DIAGNOSIS: ESTABLISHED AND EMERGING TECHNIQUES

The diagnosis of ON can be challenging. In a retrospective cross-sectional study, Stunkel and colleagues evaluated the records of 122 patients referred for evaluation to neuro-ophthalmology.<sup>[20]</sup> Of these, 49 patients (40.2%; 95% CI, 31.4–49.4) were confirmed to have ON, and 73 (59.8%; 95% CI, 50.6–68.6) had an alternative diagnosis, the most

common of which were headache and eye pain, functional visual loss, and other optic neuropathies.<sup>[20]</sup> Overweighting the presence of pain, particularly in the absence of vision loss was a significant cause of error, as was failure to consider alternative diagnoses. Clinical features considered atypical for ON should prompt consideration for an alternative diagnosis [Table 1].

In the current era of biomarkers, anti-aquaporin 4 (AQP4) IgG and myelin oligodendrocyte glycoprotein (MOG) IgG autoantibodies

**Table 1: Clinical Features that May Help Distinguish Typical from Atypical ON Subtypes**

Atypical Features	Clinical Pearls
<b>Patient Related Features</b>	
Age >45 years	ON patients can present at age >45 but consider NMOSD (mean age 40)
Non-white ethnicity	The risk of MOGAD and NMOSD increases in non-white populations
Male gender	A third on ONTT patients were male, but Leber Hereditary Optic Neuropathy (LHON) and MOGAD (less gender bias) should be considered in the right clinical context
<b>Clinical Symptoms</b>	
Bilateral simultaneous ON	Bilateral presentations can occur in MS, but consider NMOSD, MOGAD, LHON
Lack of pain	10% of typical ON patients lack pain, but absence of pain provoked by eye movements should prompt consideration for NMOSD or other optic neuropathies including AION, LHON
Pain persisting for weeks	Pain associated with typical ON generally lasts a week or two and does not persist for weeks to months. Orbital inflammatory syndromes and headache disorders should be considered
Recurrent stereotyped bouts of pain	ON is not typically recurrent, or stereotyped; primary headache disorders should be considered
Persistent positive visual phenomena	ON patients may note transient photopsias, but persistent positive visual phenomena may signify a retinal mimic
<b>Clinical Signs</b>	
Severe vision loss at presentation	Severe vision loss at presentation is more likely to be seen with MOGAD ON and NMOSD ON than MS ON
Progressive vision loss	Vision loss progressing for weeks is atypical for MS ON, MOGAD ON, and/or NMOSD ON and may suggest an infiltrative or compressive lesion
Optic atrophy at presentation	It takes 2–3 weeks for optic disc pallor to manifest. The observation of pallor at presentation may suggest longer standing compressive optic nerve mimic
Absent RAPD	Unilateral ON or asymmetric bilateral ON cases should demonstrate a RAPD. Failure to observe a RAPD at presentation is associated with overdiagnosis of ON
Severe optic disc edema, vitreous inflammation, optic disc hemorrhage	These features were shown to be atypical for ON in the ONTT and carried decreased risk for future MS diagnosis
Proptosis and orbital signs of inflammation	Consider orbital inflammatory/infiltrative syndromes with associated peri-neuritis or ON
Systemic symptoms and signs (fever, night sweats, weight loss, lymphadenopathy)	These symptoms more often occur in the setting of systemic diseases
Protracted hiccups, nausea and vomiting	Features of area postrema syndrome are found in NMOSD and may predate vision loss
No visual recovery at 3–4 weeks	Most ON patients demonstrate a line or two of HCVA by 3-weeks; lack thereof suggests worse potential for recovery which is atypical for ON, but is more often observed in NMOSD
<b>Investigative Findings</b>	
Longitudinal optic nerve lesions	Typical ON tends to be associated with short lesions (<50% of the optic nerve) whereas NMOSD is associated with long intracranial lesions (often involving the posterior optic nerves with chiasmal involvement) and MOGAD is associated with longitudinal intraorbital lesions with perineural enhancement extending into orbital tissues. Although these patterns of optic nerve enhancement can help distinguish different ON subtypes, longitudinal lesions can also occur in MS
MRI brain lesions	Patients at risk of MS will often have ovoid periventricular, juxtacortical, and infratentorial lesions
Spinal MRI lesions	Short spinal lesions occur in MS, with variable enhancement; longitudinal spinal cord lesions are more common in NMOSD and MOGAD
Serum AQP4 IgG antibody	Cell-based AQP4 IgG is positive for NMOSD in at least 80% of cases and included in the diagnostic criteria
Serum MOG IgG antibody	MOG IgG is useful in diagnosing MOGAD
Optical coherence tomography	OCT has limited utility in distinguishing ON subtypes acutely. MS ON, NMOSD ON, and MOGAD ON will have normal to elevated peripapillary RNFL measures acutely, with the earliest signs of neuroaxonal loss manifesting as macular ganglion layer thinning within 2–4 weeks. Overtime, retinal nerve fiber layer and ganglion layer measures will decrease, plateauing after approximately 6 months

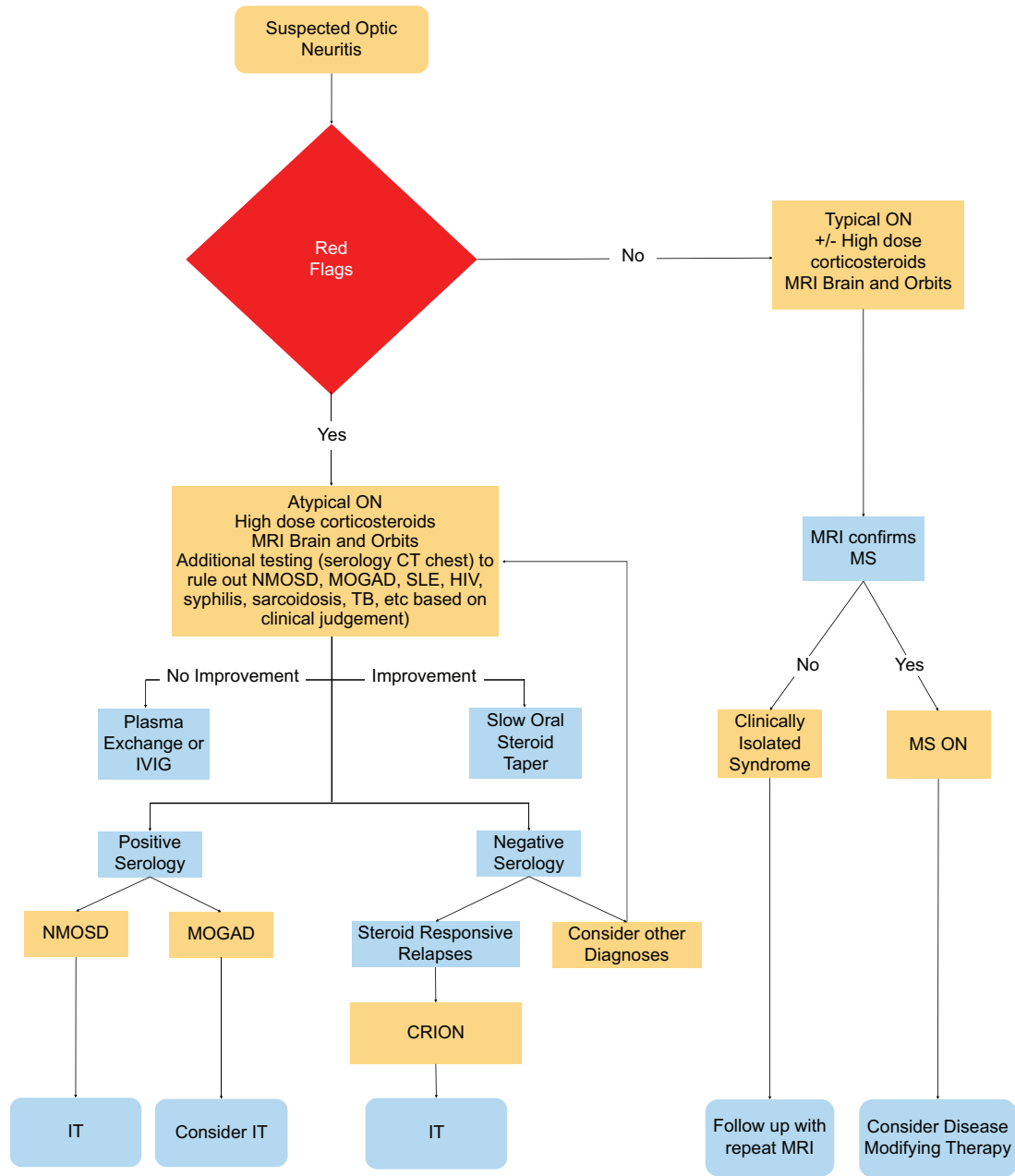


Figure 2: Flow Chart illustrating a common diagnosis and treatment algorithm (IT: Immunotherapy)

Table 2: Clinical Characteristics of NMO, MOGAD and Typical ON

Characteristics	NMO <sup>[27]</sup>	MOGAD <sup>[18]</sup>	MS/Sporadic ON <sup>[4]</sup>
Median age	40-52.5	31-41	32
Percent female	90%	57%	77%
Pain on EOM	53%	86%	92%
Ethnicity	Asian/Afro-Caribbean	White	85% white
Distribution of ON lesions	Bilateral	Bilateral	Unilateral
ON swelling	34%	86%	35%
Visual acuity deficits	Severe	Severe	Mild, moderate or severe
Prognosis for visual recovery	Poor	Good	Good
MRI optic nerve findings	Long intracranial lesions involving the posterior optic nerves and chiasm	Longitudinal intra-orbital lesions with perineural enhancement	Short lesions (<50% of the optic nerve)
Treatment	IV steroids + PLEX	IV steroids	Observation/IV steroids

as determined with cell base assay techniques are pivotal to diagnosing NMOSD and MOGAD, respectively<sup>[12]</sup> [Table 2]. Unfortunately, the results of these assays are seldom available in the acute setting and early treatment decisions must be made using strong clinical acumen and other diagnostic tools [Figure 2].

ON patients should be evaluated with orbital and cranial MRI scans to assist with diagnosis, treatment, and long-term management. Orbital imaging can be helpful to distinguish ON from other common optic neuropathies (compressive optic neuropathy) and help to differentiate ON subtypes within the context of robust clinical characterization. The sensitivity of MRI for acute ON is approximately 80–94% when imaging occurs within 30 days of symptom onset.<sup>[6]</sup> While, patterns of optic nerve enhancement can help distinguish different ON subtypes, these features are not exclusive. For example, longitudinal involvement of intraorbital and intracranial optic nerve segments are not only highly suggestive of MOGAD ON, and NMOSD ON, respectively, but can also occur in MS ON.<sup>[6]</sup> The variability in MRI sensitivity underscores the importance of using history and clinical examination to render diagnoses. Concurrent brain MRI may demonstrate lesions diagnostic (or strongly suspicious) for MS, or suggest alternative inflammatory disorders. Cerebrospinal fluid analysis may also help distinguish ON subtypes. Oligoclonal banding is more commonly seen with MS ON than ON associated with NMOSD or MOGAD.<sup>[12]</sup> Optical coherence tomography findings do not tend to supplant the fundus findings in the evaluation of acute ON,<sup>[6]</sup> and for this reason this ocular imaging technique cannot be used to reliably distinguish ON subtypes at presentation. Most ON patients will manifest variable degrees of optic disc edema with elevated peripapillary retinal nerve fiber layer measures, and normal macular ganglion layer measures at baseline.<sup>[3]</sup> For up to 6 months, peripapillary and macular ganglion layer measures often show progressive thinning, with the latter showing the first detectable signs of neuroaxonal injury caused by ON in the afferent visual pathway.<sup>[3]</sup>

### Treatment

Patients with typical ON will not derive long-term treatment benefits from IVMP, with respect to visual outcomes or future risk of MS diagnosis.<sup>[7]</sup> In the ONTT, patients treated with IVMP recovered vision faster than those in the other groups, although the difference among the three groups by 30 days was insignificant.<sup>[7]</sup> Moreover, a meta-analysis of the two trials comparing placebo with IV corticosteroids >3000 mg total for ON also found no significant improvement in visual acuity, contrast sensitivity, or visual field recovery after 6 months.<sup>[3]</sup> Secondary analyses of the ONTT data suggest that the early benefits of IVMP equated to one to lines of Snellen visual acuity; this modest effect should be discussed in patient informed decision-making models of care for treatment of typical ON.<sup>[7]</sup> Likewise, trials using oral corticosteroids have found no long-term visual benefit.<sup>[3]</sup> Treatment with low-dose oral prednisone was associated with an doubling of the risk of having a recurrence of ON in either eye within 5 years

compared with taking IVMP or oral placebo.<sup>[3,6]</sup> Further clinical trials have demonstrated that a bioequivalent dose of oral prednisone (1250 mg daily) did not increase the rate of recurrence and was similarly effective to IVMP in the acute treatment of ON.<sup>[21]</sup>

For atypical ON cases, particularly when NMOSD is suspected, treatment is essential to prevent further vision loss and attempt to salvage function. A short course of high-dose corticosteroids is likely suboptimal for atypical ON variants, particularly NMOSD ON.<sup>[3,6]</sup> Retrospective studies on the acute treatment of NMOSD ON support the early use of plasma exchange (PLEX) as add-on therapy to stabilize or optimize visual outcomes in these patients.<sup>[3,6,13]</sup> Patients with NMOSD require long-term immunosuppression over time, and three new agents have been approved with this indication, namely eculizumab, satralizumab, and inebilizumab.<sup>[22]</sup> In clinical practice, many clinicians will treat MOGAD ON with steroids (with lesser need for PLEX than NMOSD OD) and determine the need for long-term immunosuppression over time.

### Prognosis

The short- and long-term prognoses for visual recovery vary with ON subtype, and to a lesser extent, patient genetics, gender, and environmental factors.<sup>[3,6]</sup> As mentioned, the natural history of typical ON is generally favorable, with or without treatment. Patients with MOGAD ON also tend to have good visual outcomes. In a recent case series of 87 seropositive MOGAD patients with ON, only 5.7% (5 of 87) had a final HCVA of 20/200 (Snellen equivalent) or worse, whereas the vast majority demonstrated robust visual recovery, with an average HCVA of 20/30 in affected eyes.<sup>[18]</sup> In the setting of NMOSD ON, however, the visual prognosis tends to be poor, and worse outcomes are associated with recurrent attacks.<sup>[3,23,24]</sup> Approximately 20–30% of NMOSD patients will remain functionally blind (HCVA of 20/200 or worse) in their affected eye after ON, and 70% of those with a relapsing disease will manifest HCVA of 20/200 or worse.<sup>[3,6,15,25,26]</sup>

### CONCLUSIONS

ON diagnosis and management have changed significantly in the decades since the ONTT. While the lessons learned from the ONTT remain central to our understanding of typical ON, which is sporadic in nature or a harbinger of future MS diagnosis, other emerging ON subtypes require more aggressive treatment because they may have less favorable recovery. It is imperative that clinicians are comfortable with these emerging ON subtypes entities so they can recognize the clinical associations they herald and manage these cases appropriately.

### Financial support and sponsorship

Nil.

### Conflicts of interest

There are no conflicts of interest.

## REFERENCES

1. Costello F. Inflammatory optic neuropathies. *Continuum (Minneapolis)* 2014;20:816-37.
2. Bennett JL. Optic Neuritis. *Continuum (Minneapolis)* 2019;25:1236-64.
3. Bennett JL, Costello F, Chen JJ, Petzold A, Biousse V, Newman NJ, *et al.* Optic neuritis and autoimmune optic neuropathies. *Lancet Neurol* 2021 (in press).
4. Beck RW, Cleary PA, Anderson MM Jr, Keltner JL, Shults WT, Kaufman DI, *et al.* A randomized, controlled trial of corticosteroids in the treatment of acute optic neuritis. *N Engl J Med* 1992;326:581-8.
5. Lee HJ, Kim B, Waters P, Woodhall M, Irani S, Ahn S, *et al.* Chronic relapsing inflammatory optic neuropathy (CRION): A manifestation of myelin oligodendrocyte glycoprotein antibodies. *J Neuroinflammation* 2018;15:302.
6. de Lott LB, Bennett JL, Costello F. The changing landscape of optic neuritis: A narrative review. *J Neurol* 2021;10.1007/s00415-20-10351-1.
7. de Lott LB, Burke JF, Andrews CA, Costello F, Cornblath WT, Trobe JD, *et al.* Association of individual-level factors with visual outcomes in optic neuritis: Secondary analysis of a randomized clinical trial. *JAMA Netw Open* 2020;3:e204339.
8. Chen JJ, Tobin WO, Majed M, Jitraprakulsan J, Fryer JP, Leavitt JA, *et al.* Prevalence of myelin oligodendrocyte glycoprotein and aquaporin-4-IgG in patients in the optic neuritis treatment trial. *JAMA Ophthalmol* 2018;136:419-22.
9. Devic E. Myélite aiguë compliquée de névrite optique. *Bull Med (Paris)* 1894;8:1033-4.
10. Lennon VA, Kryzer TJ, Pittock SJ, Verkman AS, Hinson SR. IgG marker of optic-spinal multiple sclerosis binds to the aquaporin-4 water channel. *J Exp Med* 2005;202:473-7.
11. Ishikawa H, Kezuka T, Shikishima K, Yamagami A, Hiraoka M, Chuman H, *et al.* Epidemiologic and clinical characteristics of optic neuritis in Japan. *Ophthalmology* 2019;126:1385-98.
12. Flanagan EP. Neuromyelitis optica spectrum disorder and other non-multiple sclerosis central nervous system inflammatory diseases. *Continuum (Minneapolis)* 2019;25:815-44.
13. Costello F. Neuromyelitis optica spectrum disorders: Optimizing diagnosis and management. *Continuum* 2022 (in press).
14. Jarius S, Paul F, Weinshenker BG, Levy M, Kim HJ, Wildemann B. Neuromyelitis optica. *Nat Rev Disease Primers* 2020;6:85.
15. Wingerchuk DM, Banwell B, Bennett JL, Cabre P, Carroll W, Chitnis T, *et al.* International consensus diagnostic criteria for neuromyelitis optica spectrum disorders. *Neurology* 2015;85:177-89.
16. Berger T, Rubner P, Schautzer F, Egg R, Ulmer H, Mayringer I, *et al.* Antimyelin antibodies as a predictor of clinically definite multiple sclerosis after a first demyelinating event. *N Engl J Med* 2003;349:139-84.
17. Pache F, Zimmermann H, Mikolajczak J, Schumacher S, Lacheta A, Oertel FC, *et al.* MOG-IgG in NMO and related disorders: A multicenter study of 50 patients. Part 4: Afferent visual system damage after optic neuritis in MOG-IgG-seropositive versus AQP4-IgG-seropositive patients. *J Neuroinflammation* 2016;13:282.
18. Chen JJ, Flanagan EP, Jitraprakulsan J, López-Chiriboga AS, Fryer JP, Leavitt JA, *et al.* Myelin oligodendrocyte glycoprotein antibody-positive optic neuritis: Clinical characteristics, radiologic clues, and outcome. *Am J Ophthalmol* 2018;195:8-15.
19. Pineles SL, Repka MX, Liu GT, Waldman AT, Borchert MS, Khanna S, *et al.* Assessment of pediatric optic neuritis visual acuity outcomes at 6 months. *JAMA Ophthalmol* 2020;138:1253-61.
20. Stunkel L, Kung NH, Wilson B, McClelland CM, van Stavern GP. Incidence and causes of overdiagnosis of optic neuritis. *JAMA Ophthalmol* 2018;136:76-81.
21. Morrow SA, Alexander Fraser J, Day C, Bowman D, Rosehart H, Kremenchutzky M, *et al.* Effect of treating acute optic neuritis with bioequivalent Oral vs Intravenous corticosteroids a randomized clinical trial. *JAMA Neurol* 2018;75:690-6.
22. Levy M, Fujihara K, Palace J. New therapies for neuromyelitis optica spectrum disorder. *Lancet Neurol* 2021;20:60-7.
23. Ma X, Kermode AG, Hu X, Qiu W. Risk of relapse in patients with neuromyelitis optica spectrum disorder: Recognition and preventive strategy. *Mult Scler Relat Disord* 2020;46:102522.
24. Palace J, Lin DY, Zeng D, Majed M, Elson L, Hamid S, *et al.* Outcome prediction models in AQP4-IgG positive neuromyelitis optica spectrum disorders. *Brain* 2019;142:1310-23.
25. Merle H, Olindo S, Bonnan M, Donnio A, Richer R, Smadja D, *et al.* Natural history of the visual impairment of relapsing neuromyelitis optica. *Ophthalmology* 2007;114:810-5.
26. Wingerchuk DM, Hogancamp WF, O'Brien PC, Weinshenker BG. The clinical course of neuromyelitis optica (Devic's syndrome). *Neurology* 1999;53:1107-14.
27. Ishikawa H, Kezuka T, Shikishima K, Yamagami A, Hiraoka M, Chuman H, *et al.* Epidemiologic and Clinical Characteristics of Optic Neuritis in Japan. *Ophthalmology* 2019;126:1385-98.