




Original Article

Single surgeon experience with minimally invasive supraorbital craniotomy versus bifrontal craniotomy for anterior skull base meningiomas

Scott Christopher Seaman, Muhammad Salman Ali, Anthony Marincovich, Carlos Osorno-Cruz, Jeremy D. W. Greenlee

Department of Neurosurgery, University of Iowa Hospitals and Clinics, Iowa City, United States.

E-mail: Scott Christopher Seaman - scott-seaman@uiowa.edu; Muhammad Salman Ali - muhammad-ali@uiowa.edu; Anthony Marincovich - anthony-marincovich@uiowa.edu; Carlos Osorno-Cruz - carlos-osorno-cruz@uiowa.edu; *Jeremy D. W. Greenlee - jeremy-greenlee@uiowa.edu



*Corresponding author:

Jeremy D.W.Greenlee,
Department of Neurosurgery,
University of Iowa Hospitals
and Clinics, Iowa City, United
States.

jeremy-greenlee@uiowa.edu

Received : 26 October 2020

Accepted : 09 December 2020

Published : 22 December 2020

DOI

10.25259/SNI_767_2020

Quick Response Code:



ABSTRACT

Background: Anterior skull base meningiomas (ASBMs) account for about 10% of meningiomas. Bifrontal craniotomy (BFC) represents the traditional transcranial approach to accessing meningiomas in these locations. Supraorbital craniotomy (SOC) provides a minimally invasive subfrontal corridor in select patients. Here, we present our series of ASBM accessed by SOC and BFC by a single surgeon to review decision-making and compare outcomes in both techniques.

Methods: Thirty-three patients were identified with ASBM. Age, tumor characteristics, presenting symptoms, postoperative complications, and outcomes were analyzed.

Results: Bifrontal and SOC were performed in 13 and 20 patients, respectively. Mean follow-up time was 98.4 months. Patients undergoing SOC had smaller tumor size, located farther from the posterior table of frontal sinus, had less peritumoral edema, and decreased length of stay compared to patients undergoing BFC. Extent of resection was slightly better with BFC (99.8%) compared to SOC (91.8%), although this difference did not reach statistical significance. Recurrence-free survival and rate of re-do surgeries were not different between two groups. BFC was associated with higher rates of postoperative encephalomalacia.

Conclusion: SOC provides an excellent surgical option for ASBMs providing comparable extent of resection, minimal manipulation of brain, and excellent cosmetic outcomes for patients. The patient selection is key to maximize the benefits from this approach.

Keywords: Anterior skull base case series, Bifrontal craniotomy, Keyhole approaches, Meningioma, Supraorbital craniotomy

INTRODUCTION

Meningiomas are the most common primary brain tumor.^[2] About 10% of all meningiomas are located in the anterior skull base, with anterior skull base meningiomas (ASBMs) comprising olfactory groove (OG), planum sphenoidale (PS), and tuberculum sellae (TS).^[1] The goals of surgery are dictated by the presenting symptoms of the patients. Various approaches have been developed to access ASBM and include bifrontal, pterional, subfrontal, and interhemispheric.^[2] All these approaches provide access to the base of the tumor for early devascularization and removal

This is an open-access article distributed under the terms of the Creative Commons Attribution-Non Commercial-Share Alike 4.0 License, which allows others to remix, tweak, and build upon the work non-commercially, as long as the author is credited and the new creations are licensed under the identical terms.

©2020 Published by Scientific Scholar on behalf of Surgical Neurology International

while preserving the critical adjacent neurovascular structures. When neurosurgery as a discipline was in its infancy, large craniotomies were necessary due to lack of high-resolution imaging, neuronavigation, or illuminating and magnifying instruments. Many of these problems were addressed with the use of surgical microscope in neurosurgery.^[18] Development of stereotactic imaging and neuroendoscopy further revolutionized the field and allowed craniotomies to be made smaller and tailored to the specific pathology of the patient.^[7,15] In parallel, understanding of the harmful effects of brain retraction and increased focus on cosmetic results^[14] has led toward the natural evolution of minimally invasive techniques.^[3]

The supraorbital craniotomy (SOC) keyhole approach mitigates many of the unwanted results of large standard craniotomies for access to frontal or subfrontal pathology. Since its development by Krause, it has been further refined and its use expanded.^[15] Its biggest advantages are tumor resection using dynamic rather than fixed brain retraction,^[17] avoidance of brain exposure to nonphysiological environment for extended periods of time including the intense heat of the operating microscope, and excellent cosmetic results.^[8,14]

To assess the application of the supraorbital approach in ASBM and compare it to a traditional subfrontal corridor, we retrospectively reviewed our database and found 33 cases of meningiomas in the anterior skull base resected using either bifrontal craniotomy (BFC) or SOC performed by a single surgeon. We then describe our approach selection criteria with the SOC and BFC.

MATERIALS AND METHODS

Patient selection

A retrospective chart review from January 2005 to January 2020 with appropriate IRB approval was performed. All patients included had procedures performed by the senior author (JDG) and selection criteria included a diagnosis of meningioma and procedural codes consistent with a SOC with or without endoscopic assistance or a bilateral craniotomy. For the BFC group, the preoperative images and operative report were examined to confirm an ASBM and BFC was utilized given the lack of specificity with the diagnostic codes. Basic demographic factors (age, gender, body mass index, symptomology [visual acuity/anopsia deficits], and anosmia), radiographic factors (tumor volume assessed by $[A*B*C]/2$ measurements, tumor location, abnormal adjacent fluid-attenuated inversion recovery [FLAIR] signal to assess for brain adherence and/or infiltration, as well as encephalomalacia, distance from posterior wall of frontal bone), operative features (use of lumbar drain, anticonvulsants), and postoperative outcomes (extent of resection, cerebrospinal fluid [CSF]

leak, recurrence requiring subsequent surgery, postoperative radiation, length of stay, deep venous thrombosis, pulmonary embolism, stroke, seizure, and diabetes insipidus) were collected. Final pathology and time to recurrence were also recorded. In addition, the presence of encephalomalacia on the most recent available follow-up scan was documented.

Statistical analysis

Statistical analysis was conducted with IBM SPSS Statistics for Windows, version 26 (IBM Corp., Armonk, N.Y., USA). Continuous variables were compared using a Student's *t*-test or Welch's *t*-test if Levene's assumption for normality was violated. Categorical variables were compared using a Chi-square test or Fisher's test in cases where one of the matrix groups had a sample less than 5. Kaplan–Meir curves for recurrence between approaches were calculated using the Mantel-Cox log-rank test. Two-way ANOVA with *post hoc* between group analyses with Bonferroni correction for multiple comparisons was used to assess the extent of resection by approach and tumor recurrence necessitating repeat operation.

RESULTS

Demographics and clinical presentation

There were 33 total patients identified, 20 of which were approached through a minimally invasive SOC and 13 approached through a BFC approach. The overall demographics are reported in [Table 1]. In 51% of cases, the patients presented with a visual acuity deficit and 53% of cases anosmia was present. Limited data were available for collection regarding anosmia, but we identified at least 8 patients (24%) who were anosmic on initial evaluation. No cases required a lumbar drain; there was one postoperative CSF leak. Five cases eventually required reoperation for tumor recurrence. A majority of the cases were Grade I. The remainder of the clinical presentation, postoperative outcomes, and radiographic features are reported in [Table 2].

Differences between approaches

Comparing approaches, there was no difference in demographic features or preoperative neurologic deficits [Table 3]. Cases approached with BFC tended to be larger (88.8 cm^3 vs. 8.0 cm^3 , $P = 0.002$) and had an anterior tumor margin closer to the posterior wall of the frontal bone (2.0 mm vs. 27.7 mm , $P < 0.0001$). BFC cases tended to have more preoperative FLAIR signal changes (90.1% vs. 35% , $P = 0.007$) and use of anticonvulsants perioperatively (100% vs. 60% , $P = 0.012$). BFC had a slightly improved extent of resection but was not statistically significant (99.8% vs. 91.8% , $P = 0.078$). SOC cases were on average over an hour

shorter. The length of stay was shorter with SOC compared to BFC (3.4 days vs. 7.2 days, $P = 0.013$).

Association with encephalomalacia

Meningiomas approached with a BFC had more encephalomalacia at last follow-up (84.6% vs. 3.1%, $P < 0.0001$). To evaluate if there was any effect of approach versus initial tumor volume on encephalomalacia, a two-way ANOVA was performed. The mean volume in the BFC without encephalomalacia was 57.3 cm³ (range 47.1–67.6) compared to 94.5 cm³ (range 18.7–291.2) in those who developed encephalomalacia. In the SOC group, those who never developed encephalomalacia had a mean initial volume of 4.6 cm³ (range 0.61–21.2) compared

to 27.3 cm³ (range 7.9–42.6) in those who did develop encephalomalacia [Figure 1]. While initial tumor volume did have an interaction with approach ($P = 0.018$), there was no interaction with those who developed encephalomalacia ($P = 0.222$), though pairwise comparisons showed that the mean difference in tumor volume between encephalomalacia status was 29.9 cm³.

Recurrent cases requiring intervention

Overall, there was no difference between approaches that required subsequent surgery ($P = 0.360$). In addition, Mantel-Cox log-rank test showed no difference in recurrence free survival ($P = 0.102$). Two-way ANOVA testing was performed evaluating recurrent tumors by approach and extent of resection. Single BFC had a mean EOR of 100% versus 98.9% in recurrent BFC cases. In the SOC group, the single surgery cohort had a mean EOR of 92.3% versus 87.6% in the recurrent surgery cohort. There was no difference in EOR by approach ($P = 0.223$) or repeat resection status ($P = 0.711$) [Figure 2].

DISCUSSION

This study shows a single surgeon's experience using minimally invasive SOC is not inferior to standard BFC for midline ASBM. In particular, there was no difference in extent of resection, recurrence, or postoperative neurologic deficits between groups. Moreover, SOC had less incidence of encephalomalacia at follow-up compared to BFC. SOC had shorter operative times on average by 1 h and a length of stay that was significantly shorter than BFC.

Minimizing encephalomalacia

In our study, patients undergoing BFC have higher rate of postoperative encephalomalacia noted on magnetic resonance

Table 1: Overall patient demographics.

Factor	Value
<i>n</i>	33
Mean age (SD)	60.2 (14.2)
Mean body mass index (SD)	31.4 (7.2)
Gender (M/F)	12/21
Supraorbital approach, <i>n</i>	20
Bifrontal approach, <i>n</i>	13
Mean follow-up time (months)	98.4 (82.4)

Table 2: Overall neurologic deficits, imaging features, operative features, and postoperative outcomes.

Factor	<i>n</i> (%)
Preoperative visual acuity deficit	17 (51.5)
Preoperative anopsia	18 (54.5)
Preoperative anosmia	8 (24.2)*
Preoperative adjacent fluid-attenuated inversion recovery signal	14 (42.4)
Lumbar drain	0 (0)
Anticonvulsants	25 (75.7)
Postoperative visual acuity deficit	6 (18.2)
Postoperative anopsia	8 (24.2)
Postoperative anosmia	10 (30.3)
Postoperative seizure	4 (12.1)
Postoperative stroke	4 (12.1)
CSF leak	1 (3.0)
Postoperative diabetes insipidus	0 (0)
Postoperative deep venous thrombosis	0 (0)
Postoperative DWI signal	17 (51.5)
Postoperative fluid-attenuated inversion recovery signal	17 (51.5)
Postoperative radiation	8 (25)
Subsequent surgery for recurrence	5 (15.2)
WHO Grade I	26 (78.8)
WHO Grade II	6 (18.2)
WHO Grade III	1 (3.0)

*Frequency limited by unreported findings in seven cases

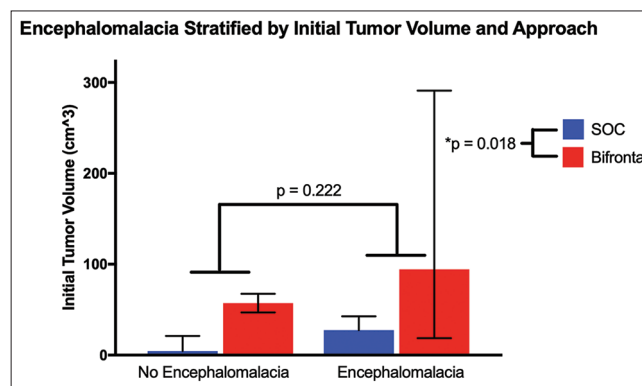


Figure 1: Encephalomalacia analysis evaluating effect of surgical approach and initial tumor volume represented as mean (error bars: range). Tumor volume was significant between surgical approach but not encephalomalacia status.

Table 3: Differences between approaches.

	Factors	Supraorbital	Bifrontal	P-value
Demographics	Number	20	13	-
	Mean age	60.7	59.3	0.792
	Body mass index	30.5	31.2	0.890
	Female gender (%)	75%	86%	0.092
Preoperative features	Distance from frontal sinus (mm)	27.7	2.0	<0.0001
	Tumor volume (cm ³)	8.0	88.8	0.002
	Visual acuity deficit	63%	38.5%	0.169
	Anopsia	68.4%	38.5%	0.093
	Anosmia	25.0%	38.5%	0.420
	Fluid-attenuated inversion recovery change	35%	90.1%	0.007
	Anticonvulsant use	60%	100%	0.012
	Tumor volume (cm ³)	0.12	0.16	0.781
Postoperative features	Extent of resection (%)	91.8%	99.8%	0.078
	Visual acuity deficit	10%	33.3%	0.182
	Anopsia	20.0%	30.8%	0.481
	Anosmia	29%	50%	0.422
	Seizure	15%	7.7%	1.000
	Stroke	15%	7.7%	1.000
	CSF leak	0%	7.7%	0.394
	Mean OR time (SD), minutes	401 (61)	473 (191)	0.212
	Mean length of stay (SD), days	3.4 (0.9)	7.2 (4.7)	0.013
	Fluid-attenuated inversion recovery change	35%	90.1%	0.007
	DWI signal	35%	63.6%	0.125
	Features throughout follow-up	Encephalomalacia	3.1%	84.6%
Subsequent surgery for recurrence		15%	23.1%	0.360
Need for radiation		30%	15.4%	0.431

Statistical significance indicated as bold ($P < 0.05$) and statistical trend as italicized ($P < 0.1$)

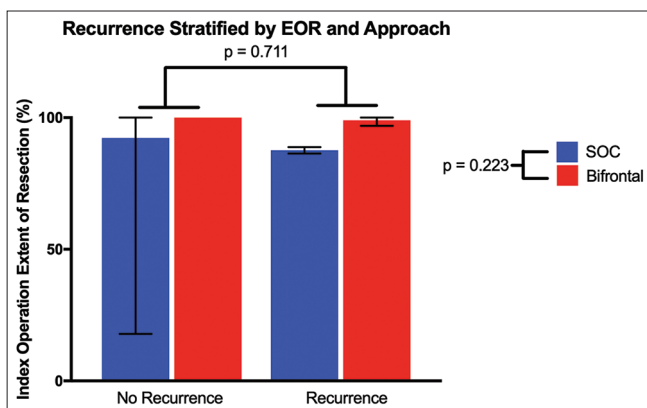


Figure 2: Recurrent tumor analysis evaluating effect of surgical approach and index surgery extent of resection represented as mean (error bars: range). There was no significant difference, indicating the minimally invasive supraorbital craniotomy is an effective option in small- to medium-sized meningiomas.

imaging on last clinic visit compared to SOC. Although postoperative FLAIR signal is higher for BFC, the patients undergoing this approach have much larger tumor size. For the SOC group, those who developed encephalomalacia had a mean volume of 27.3 cm³ compared to 94.5 cm³ in the BFC group. We hypothesized that initial tumor volume

primarily contributes to the formation of encephalomalacia postoperatively; however, the mean volume in the BFC group that did not develop encephalomalacia was 57.3 cm³, far larger than the volume in SOC cases that did develop encephalomalacia at 27.3 cm³. This suggests that tumor volume alone does not contribute to the formation of encephalomalacia and implicates the effects of retraction, as the amount of retraction necessary to remove a 4.6 cm³ tumor through SOC approach differs from a 27.3 cm³ tumor removal.

Perneczky reported in their 10-year experience with SOC that a majority of the meningiomas resected with this approach were between 2.5 and 4.4 cm and gross total resection was achieved in 89% of the cases.^[15] While the use of an endoscope in SOC can minimize brain manipulation, at some point, the vertical extension of the tumor will necessitate brain retraction (whether dynamic or fixed) that may result in encephalomalacia as seen in our series. While encephalomalacia from a prior neurosurgical procedure is a known cause of medically refractory epilepsy that may necessitate subsequent resection for control, other consequences of encephalomalacia are not well understood. The literature would benefit from a comprehensive preoperative and postoperative neurocognitive and quality of life assessment controlled for tumor location and surgical approach.

Minimizing length of stay and use of hospital resources

We found that SOC affords decreased operative time and length of hospital stay compared to BFC. Although the difference in operative time between the two groups was not significant, this is likely limited by our small sample size, as the procedural time was on average shorter by 1 h. Length of stay was shorter by nearly 4 days in our series. Short procedure time and length of stay decrease resource utilization and maximize hospital throughput. In addition, shorter procedure times and length of stay may contribute to better outcomes in elderly patients with meningiomas. As the incidence of meningiomas increases significantly with age,^[6] this will need further study and a larger patient series. Others have reported longer operative times for SOC.^[10] This may be due to variability in tumor characteristics.

Defining tumor characteristics for approach selection

We have reported slightly higher extent of resection with BFC 99.8% versus 91.8% for SOC but did not find any significant difference in recurrence free survival and the need for reoperation for recurrence between the two groups. As we have demonstrated in our series, patients undergoing SOC usually are located more posteriorly in the anterior skull base and involve PS and TS, have a higher percentage of those who are presenting with visual deficits, and are usually smaller in size compared to larger meningiomas found in OG. The goal of surgery for the lesions in PS and TS is improvement of visual symptoms and maximal safe resection of the tumor [Figure 3]. Tumors with subchiasmatal and/or retrochiasmatal extension also limit the extent of resection for SOC. For these residual tumors, we typically observe unless recurrence threatens visual function, in which case radiation or endoscopic endonasal approach for optic nerve decompression is employed. Tumors extending laterally involving neurovascular structures are better suited for standard transcranial approaches.

Regardless of slightly better extent of resection, BFC carries with it significant surgical complications. Morbidity reported from BFC for OG meningiomas has been reported to occur in as much of 30%, mainly consisting of hydrocephalus necessitating temporary or permanent CSF diversion, seizures, CSF fistula, or wound infections,^[11] though we did not see this in our series. The surgical approach typically requires transgression of the frontal sinus with corresponding cranialization that adds operative time and morbidity^[4] and may require ligation of the anterior third of the superior sagittal sinus to provide the appropriate access for tumor removal. Finally, there is the potential for significant frontal lobe retraction that contributes to frontal lobe contusions with subsequent encephalomalacia, increased risk of seizures and/or venous infarct.^[11] However, in cases of large ASBM, these maneuvers are worth the associated risk

and/or morbidity to maximize tumor resection to minimize recurrence and provide symptomatic relief [Figure 4].

Limitations of the SOC

One of the criteria we follow in our decision-making is the tumor size and peritumoral FLAIR signal. As the tumor grows vertically from the anterior skull base, it presents a limitation for SOC, as the surgical corridor in SOC is mostly horizontal; this limitation can be overcome to a degree with the inclusion of an orbital osteotomy with the SOC as a minimally invasive version of the modified orbitozygomatic osteotomy.^[13,16] Furthermore, patients with increased peritumoral FLAIR signal signifies vasogenic edema and puts the patient at higher risk of periprocedural brain edema which can be challenging to control through SOC. Others have reported similar criteria in selecting BFC patients for ASBM resection.^[10] The benefits of SOC are limited with inferior invasion through the cribriform plate. These tumors can be accessed through BFC, which offers exposure bilaterally in the subfrontal plane. Expanded endoscopic endonasal approach (EEEA) also provides an excellent alternative to transcranial approaches for tumors located in

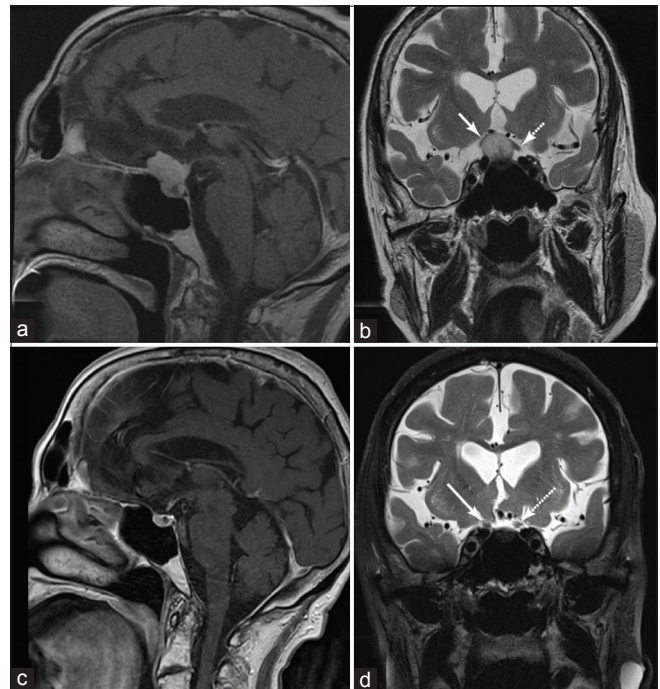


Figure 3: Sagittal postgadolinium-enhanced T1 magnetic resonance imaging (a) depicting a planum/tuberculum meningioma with coronal T2, (b) depicting elevation of the optic nerves bilaterally, right (solid arrow) greater than left (dashed arrow) causing peripheral vision loss. Postoperatively, her vision improved and 3 years after right eyebrow supraorbital craniotomy, sagittal T1 enhanced magnetic resonance imaging shows satisfactory gross total resection (c) with coronal T2 (d) showing resolution of the displaced optic nerves (solid arrow right, dashed arrow left).

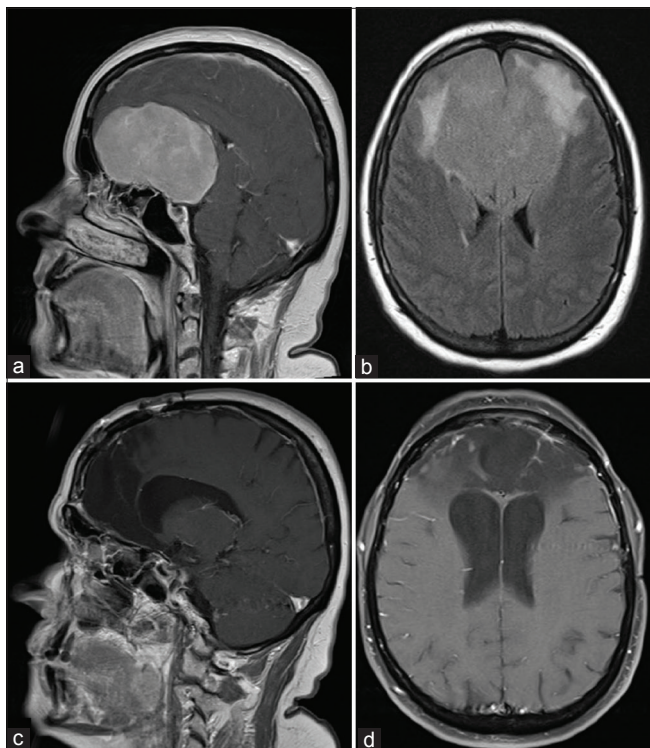


Figure 4: Sagittal postgadolinium-enhanced T1 magnetic resonance imaging depicting a large olfactory groove meningioma spanning the entirety of the anterior skull base from posterior table of the frontal sinuses to suprasellar region (a) with significant mass effect on the lateral horns of the ventricles and associated fluid-attenuated inversion recovery signal change. (b) Eight months after bifrontal craniotomy and tumor resection, sagittal (c) and axial (d) postcontrast views show gross total resection with associated encephalomalacia.

this region,^[9] as does a combination of SOC and EEEA as suggested by others.^[12] It allows a direct access to the tumor, removal of involved bone, and early devascularization. With continued improvement in CSF leak rates with the use of vascularized flaps, EEEA has become a viable alternative and in many cases primary approach for meningiomas located in anterior skull base.^[19]

A recent cadaveric study has suggested limited ability to drill the inferior crista galli and cribriform plate with SOC.^[5] We have demonstrated here that the mean distance between the posterior table of frontal bone and the tumor for SOC approach was 27.7 mm and only 2 mm for BFC. As the tumor approaches and abuts the posterior table of the frontal sinus, the viewing angle from a SOC approach is limited, though using an endoscope with various viewing angles can help access these blind spots. Alternatively, lesions close to the posterior table are best approached by BFC (as demonstrated in our series), EEEA, and combined SOC and EEEA.^[4,5]

We have not noticed any muscle wasting and excellent wound healing in our series, although a formal comparison between

approaches was limited by our observations primarily in clinic evaluation and not in a standardized approach. Increased meningioma incidence among elderly population is also a concern for men with baldness. Cosmetic results have been linked with patient outcomes.^[14]

CONCLUSION

Supraorbital approach provides an excellent corridor to access meningioma in the anterior skull base. We have addressed some of the issues historically linked with SOC, that is, extent of resection, neurovascular injury, tumor recurrence, and requirement of re-do surgery. It provides a safe passage for tumor resection, without injury to brain and neurovascular structures, and excellent cosmetic results in carefully selected patients. As we tailor approaches to each patient according to their own individual needs, mastering SOC, BFC, and EEA approaches and their associated technical nuances and patient selection criteria will allow us to provide a comprehensive approach to our patients.

Declaration of patient consent

Patient's consent not required as patients identity is not disclosed or compromised.

Financial support and sponsorship

Nil.

Conflicts of interest

There are no conflicts of interest.

REFERENCES

- Abbassy M, Woodard TD, Sindwani R, and Recinos PF. An overview of anterior skull base meningiomas and the endoscopic endonasal approach. *Otolaryngol Clin North Am* 2016;49:141-52.
- Almefty GF, Al-Mefty O. Meningioma. In: Youmans and Winn *Neurological Surgery*. 7th ed. Amsterdam: Elsevier; 2016. p. 1107-32.
- Andrews RJ, Bringas JR. A review of brain retraction and recommendations for minimizing intraoperative brain injury. *Neurosurgery* 1993;33:1052-63; discussion 1063-54.
- Banu MA, Mehta A, Ottenhausen M, Fraser JF, Patel KS, Szentirmai O, *et al.* Endoscope-assisted endonasal versus supraorbital keyhole resection of olfactory groove meningiomas: Comparison and combination of 2 minimally invasive approaches. *J Neurosurg* 2016;124:605-20.
- Borghei-Razavi H, Truong HQ, Fernandes-Cabral DT, Celticki E, Chabot JD, Stefkó ST, *et al.* Minimally invasive approaches for anterior skull base meningiomas: Supraorbital eyebrow, endoscopic endonasal, or a combination of both? Anatomic study, limitations, and surgical application. *World*

- Neurosurg 2018;112:e666-74.
6. Chamoun R, Krisht KM, Couldwell WT. Incidental meningiomas. *Neurosurg Focus* 2011;31:E19.
 7. Cohen AR, Perneczky A, Rodziewicz GS, Gingold SI. Endoscope-assisted craniotomy: Approach to the rostral brain stem. *Neurosurgery* 1995;36:1128-9; discussion 1129-30.
 8. Dlouhy BJ, Chae MP, Teo C. The supraorbital eyebrow approach in children: Clinical outcomes, cosmetic results, and complications. *J Neurosurg Pediatr* 2015;15:12-9.
 9. Gardner PA, Kassam AB, Thomas A, Snyderman CH, Carrau RL, Mintz AH, *et al.* Endoscopic endonasal resection of anterior cranial base meningiomas. *Neurosurgery* 2008;63:36-52; discussion 52-4.
 10. Iacoangeli M, Nocchi N, Nasi D, di Rienzo A, Dobran M, Gladi M, *et al.* Minimally invasive supraorbital keyhole approach for the treatment of anterior cranial fossa meningiomas. *Neurol Med Chir (Tokyo)* 2016;56:180-5.
 11. Nakamura M, Struck M, Roser F, Vorkapic P, Samii M. Olfactory groove meningiomas: Clinical outcome and recurrence rates after tumor removal through the frontolateral and bifrontal approach. *Neurosurgery* 2007;60:844-52; discussion 844-52.
 12. Ottenhausen M, Rumalla K, Alalade AF, Nair P, La Corte E, Younus I, *et al.* Decision-making algorithm for minimally invasive approaches to anterior skull base meningiomas. *Neurosurg Focus* 2018;44:E7.
 13. Perneczky A, Reisch R. Basal variation of the supraorbital approach: The supraorbital-orbital craniotomy. In: *Keyhole Approaches in Neurosurgery. Concept and Surgical Technique. Vol. 1.* Lavanttal, Austria: Springer; 2008. p. 83-97.
 14. Reisch R, Marcus HJ, Hugelshofer M, Koechlin NO, Stadie A, Kockro RA. Patients' cosmetic satisfaction, pain, and functional outcomes after supraorbital craniotomy through an eyebrow incision. *J Neurosurg* 2014;121:730-4.
 15. Reisch R, Perneczky A. Ten-year experience with the supraorbital subfrontal approach through an eyebrow skin incision. *Neurosurgery* 2005;57:242-55; discussion 242-55.
 16. Schwartz TH. An eyebrow for an eyebrow and a nose for a nose. *World Neurosurg* 2014;82:e97-9.
 17. Spetzler RF, Sanai N. The quiet revolution: Retractorless surgery for complex vascular and skull base lesions. *J Neurosurg* 2012;116:291-300.
 18. Yaşargil M. *Microneurosurgery.* New York: Georg Thieme Verlag; 1984.
 19. Zoli M, Guaraldi F, Pasquini E, Frank G, Mazzatenta D. The endoscopic endonasal management of anterior skull base meningiomas. *J Neurol Surg B Skull Base* 2018;79:S300-10.

How to cite this article: Seaman SC, Ali MS, Marincovich A, Osorno-Cruz C, Greenlee JD. Single surgeon experience with minimally invasive supraorbital craniotomy versus bifrontal craniotomy for anterior skull base meningiomas. *Surg Neurol Int* 2020;11:458.