

## Vascularity and Angiogenic Signaling in the Dentine-Pulp Complex of Immature and Mature Permanent Teeth

 Ahmad AL-HASSINY,  Haizal HUSSAINI,  Trudy MILNE,  Benedict SEO,  Alison M. RICH,  Lara T. FRIEDLANDER

### ABSTRACT

**Objective:** This study aimed to examine the protein and gene expression of vascular endothelial growth factor (VEGF) and angiopoietins-1 and 2 in tissue from healthy and inflamed dental pulps.

**Methods:** Permanent teeth with pulps diagnosed as healthy or reversible pulpitis were used for immunohistochemistry (IHC) and gene expression experiments. For IHC, a whole pulp tissue was excavated from the pulp chamber, and it was formalin-fixed and processed for routine IHC with angiogenic markers anti-VEGF, anti-Ang1, and anti-Ang2. Staining was visualized with diaminobenzidine (DAB), and examined using light microscopy. The distribution of markers in healthy and inflamed pulps was qualitatively and quantitatively analyzed. Real-time quantitative polymerase chain reaction (RT qPCR) was used to ascertain the gene expression levels of *ANGPT1*, *ANGPT2*, and *TEK* in the presence of inflammation. Statistical analysis was performed using the Mann–Whitney test with the statistical significance level set at 0.05.

**Results:** There was increased protein and mRNA expression of VEGF and Ang-1 markers in inflamed pulp samples as compared with that in the healthy pulp tissue. IHC demonstrated intense expression of the VEGF protein on endothelial cells (EC) and some non-ECs, and there was significantly more staining on ECs associated with inflamed tissue ( $P < 0.001$ ). Ang-1 and Ang-2 were significantly expressed on ECs and non-ECs ( $P < 0.05$ ). RT qPCR did not show significant differences in gene expression between healthy and inflamed samples although similar trends were observed to IHC.

**Conclusion:** The presence of Ang-1, Ang-2, VEGF, and *TEK* gene in healthy and mildly inflamed pulp tissue associated with reversible pulpitis indicates that these angiogenic factors may participate in physiological and pathological angiogenesis and healing. The inflammatory process may regulate Ang-1/Ang2/Tie2 signaling; and together with VEGF, these growth factors have an important role in modulating pulp angiogenesis.

**Keywords:** Angiogenesis, angiopoietins, dental pulp, immunohistochemistry, reversible pulpitis, Tie2, VEGF

### HIGHLIGHTS

- Angiopoietins and VEGF may act synergistically, and they have an important role in modulating angiogenesis.
- Ang-1, Ang-2, VEGF, and *TEK* are expressed in healthy and mildly inflamed dental pulp tissue.
- The Ang-1/Ang-2/Tie2 signaling may be regulated by the inflammatory process.

### INTRODUCTION

The dental pulp has an innate capacity to heal the injury and inflammation resulting from caries or dental trauma. This is a reparative process that is dependent on a vascular supply and angiogenesis (1-3). Angiogenesis involves the sprouting of new blood vessels from the existing vasculature, and is central to development and healing. It involves an integrated

series of events that is regulated by growth factors, their receptors, cytokines, and cells (4). Furthermore, angiogenesis has established roles in the pathogenesis of acute and chronic inflammatory disorders and wound healing suggesting a key role in pulpitis and pulp healing (5, 6).

Following pulp injury, the inflammatory response and tissue hypoxia may result in either reversible pulpitis with healing or irreversible pulp damage with loss of vitality and tissue necrosis (3, 7). Although the pulp has a rich capillary network, there are spatial differences in the vascular distribution the main blood supply via the apical foramen and no collateral supply. A healthy pulp consists of loose connective tissue containing cells, blood vessels, lymphatics, and nerve endings (8). When the pulp is reversibly inflamed, it relies on a blood supply to facilitate healing. Inflamma-

Please cite this article as: Al-Hassiny A, Hussani H, Milne T, Seo B, Rich AM, Friedlander LT. Vascularity and Angiogenic Signaling in the Dentine-Pulp Complex of Immature and Mature Permanent Teeth. *Eur Endod J* 2019; 4: 80-5

From the Sir John Walsh Research Institute, Faculty of Dentistry, University of Otago, New Zealand (A.A.H., H.H., T.M., B.S., A.M.R., L.T.F.)  
✉ lara.friedlander@otago.ac.nz

Received 16 December 2018, last revision received 17 January 2019, accepted 17 January 2019

Published online: April 04 2019  
DOI 10.14744/eej.2019.26349

tory mediators released after pulpal irritation stimulate downstream effects with the release of key angiogenic growth factors, particularly vascular endothelial growth factor (VEGF) (9).

VEGF is a family of growth factors of which VEGF-A (further referred to as VEGF) regulates effects by binding to its primary receptor, vascular endothelial growth factor receptor-2 (VEGFR2). When bound to the receptor, VEGF stimulates endothelial cell (EC) proliferation, increased pulpal blood flow, and capillary hyperpermeability (10). In response to injury, VEGF is mainly secreted by ECs and also pulp fibroblasts and inflammatory cells (11); and elsewhere in the body, the release of VEGF synergistically influences the release of other angiogenic factors including angiopoietins (12, 13).

The angiopoietin family of growth factors (Ang 1–4) exert their effects by binding to tyrosine kinase receptors (14). Angiopoietin-1 (Ang-1) and Angiopoietin-2 (Ang-2) are best characterized, and both mediate their effects by competitively binding to the Tie2 receptor protein that is encoded by the *TEK* (Tyrosine kinase, endothelial) gene (15). Ang-1 is expressed on several cell types, while Ang-2 is predominantly expressed on ECs, and it inhibits Ang-1-Tie2 binding and Tie2 activation of ECs (16). The 140 kD Tie2 receptor is primarily expressed on ECs, but extravascular expression on non-ECs including fibroblasts and inflammatory cells is also recognized (17). Ang-1 and Ang-2 have agonist and antagonist roles when bound to Tie2 (18). Ang-1 suppresses vascular inflammation, and it is involved in EC migration and survival, tubule formation, and vessel maturation following injury (14, 19). Ang-2 is able to antagonize Ang-1 activity, resulting in EC activation, vessel destabilization, and angiogenesis, and it is highly expressed in tissues undergoing vascular remodeling (20). Further, both Ang-1 and Ang-2 are modulated by hypoxia, inflammation, and VEGF (14, 15, 19, 21).

While the involvement of angiopoietins in healing have been identified in other body sites, Ang-1, Ang-2, Tie2 signaling is thought to be tissue specific (22); and little is known about the role of angiopoietins in pulp inflammation, angiogenesis, and healing potential. Therefore, this study aimed to examine the protein and gene expression of angiogenic factors (VEGF, Ang-1 and Ang-2, and *TEK*) in pulp tissue diagnosed clinically and histologically as having reversible pulpitis with the null hypothesis that there would be no significant difference in protein and gene expression between healthy and inflamed samples.

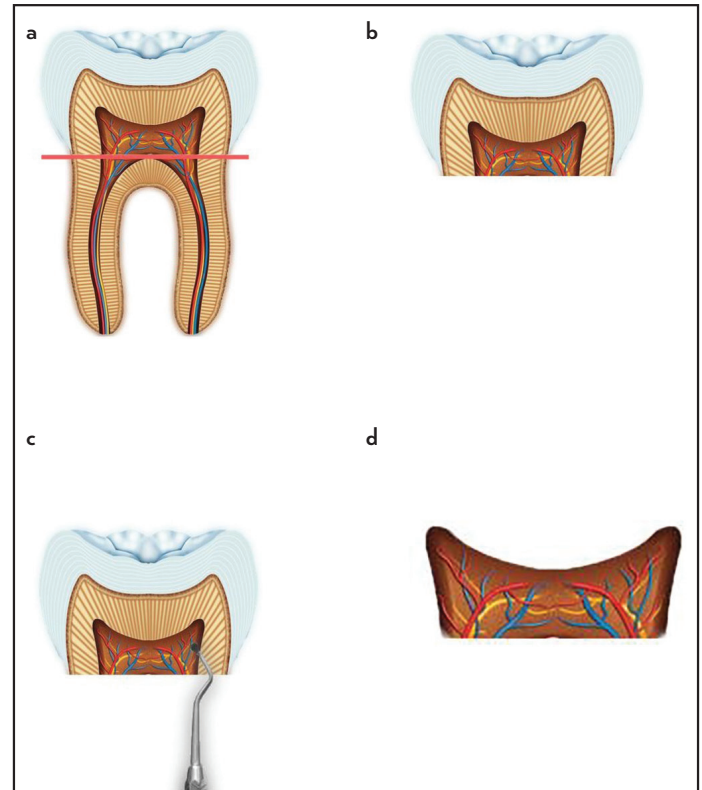
## MATERIALS AND METHODS

### Sample collection

Ethical approval for this study was obtained from the University of Otago, Human Ethics Committee (Health) H15/002. Patients requiring extraction of impacted third molars were recruited from the Oral Surgery Clinic at the Faculty of Dentistry, University of Otago, New Zealand. Participants were provided information about the study, and signed consent was obtained from them. Thirty permanent teeth with mature root development containing healthy ( $n=15$ ) or inflamed ( $n=15$ ) dental pulps were collected from healthy participants aged between 17 and 30 who were non-smokers and were not

taking any regular medications. Teeth that met the inclusion criteria were diagnosed clinically as having (1) healthy pulps or (2) reversible pulpitis. Established radiographic criteria were used. Clinical signs/symptoms and sensibility tests were used to diagnose teeth if applicable. A periapical or panoramic radiographic image showed the pulp chamber was clearly visible to enable sufficient tissue for examination, and there was a zone of dentine between caries (if present) and the pulp (23). Where the clinical examination found the presence of a deep carious lesion, spontaneous dull or throbbing pain, tenderness to palpation and percussion, the tooth was diagnosed as having signs or symptoms of irreversible pulpitis/apical periodontitis, and it was excluded (24). Twenty specimens (ten healthy and ten mildly inflamed) were placed in 10% neutral buffered formalin for immunohistochemistry (IHC) while the remaining ten (five healthy and five inflamed) were kept in RNAlater (Applied Biosystems, Waltham, USA), for gene expression experiments.

A novel technique was developed and piloted during this study to harvest whole pulp tissue from the coronal pulp chamber of extracted teeth (Fig. 1). A radiograph taken prior to extraction was used to ascertain the size of the pulp chamber and level of the pulp chamber floor. The tooth was then horizontally sectioned at the level of the cemento-enamel junction with a tungsten carbide fissure bur (Henry Schein Dental, New Zealand), enabling the coronal pulp tissue to be accessed and removed whole with a small dental excavator (Nordent,



**Figure 1.** Technique used to harvest pulp tissue showing (a) tooth extracted whole, (b) tooth sectioned horizontally at the cemento-enamel junction, (c) excavation of soft pulp tissue from the main pulp chamber, (d) pulp tissue that was placed in either 10% buffered formalin for IHC or RNAlater for RT qPCR

Anterior Spoon Excavator #8 Double ended, Crown Medical & Dental, New Zealand). This technique eliminated the need for tooth decalcification while ensuring there was pulp tissue of sufficient size for examination. Six 4- $\mu\text{m}$  serial sections were cut from each specimen block, and they were used for histology and IHC. To verify the presence or absence of inflammation, the first section of each block was stained with hematoxylin and eosin, and examined by two oral pathologists who were blinded to the study.

### Immunohistochemistry

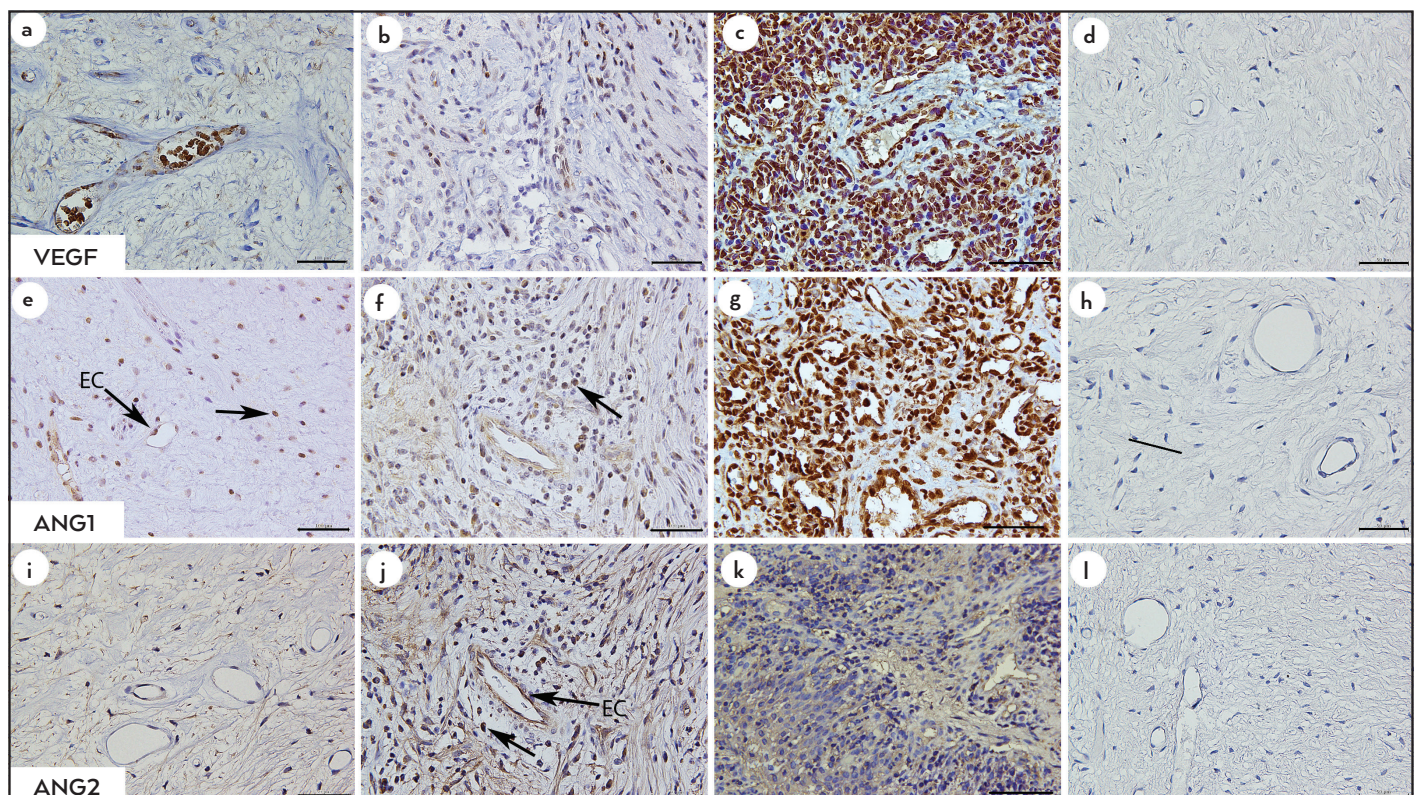
The IHC staining using anti-VEGF, anti-ANG1, and anti-ANG2 antibodies was carried out on the Ventana Benchmark XT Auto Immunostainer (Ventana® Medical Systems, Inc., AZ, USA) using predetermined antigen retrieval steps and optimized antibody concentrations (anti-VEGF mouse monoclonal, 0.4  $\mu\text{g}/\text{mL}$ , Santa Cruz; USA; anti-ANG1, rabbit polyclonal, 1.5  $\mu\text{g}/\text{mL}$ , Abcam; anti-ANG2, rabbit polyclonal, 4.9  $\mu\text{g}/\text{mL}$  Abcam). Antibody titration, end-stage hematoxylin counterstaining, and cover slipping were manually performed. Pyogenic granuloma specimens were used for positive controls for all primary antibodies. Negative control mouse IgG1 (Dako) was used at the same concentration as the primary antibodies.

Tissue sections were examined using light microscopy and photographed. To investigate differences in the expression of the markers, three selected hotspots containing blood vessels were captured at x400 magnification (40 $\times$  objective and 10 $\times$  ocular, 0.255 mm<sup>2</sup> per field) for each specimen. ECs were defined as cells surrounding a vessel lumen. The total number of

cells per unit area was counted, as were the positive stained ECs and non-ECs in the surrounding tissues. The VEGF, ANG1, and ANG2 expression was evaluated as described by Lucarini and colleagues (25) by calculating the percentage of positive ECs and non-ECs among all cells within each of the hotspots. Image J software (MacBiophotonics, Windows 64-bit version) was used for quantitative cell counting in conjunction with the use of a digitally superimposed graticule. Data entry and descriptive analysis was performed using GraphPad Prism (GraphPad Software Inc. USA, Version 6D). The Mann–Whitney test was used to compare the healthy and inflamed pulp specimens with a p-value of <0.05 considered statistically significant.

### Quantitative reverse transcription real-time PCR

The gene expression studies investigated the expression of three angiogenic genes; *ANGPT1* (encodes Ang-1), *ANGPT2* (encodes Ang-2), and *TEK* (encodes Tie2 receptor) in healthy and inflamed pulps. Total RNA was extracted from the tissue specimens, and purified using an Ambion Purelink™ RNA Mini Kit with TRIzol Reagent (Applied Biosystems, Foster City, USA) following manufacturer's recommendations in conjunction with the use of an on-column Purelink DNase™ kit (Ambion, Foster City, USA) to prevent genomic DNA contamination. The purified total RNA quality (eluted in 50  $\mu\text{L}$  in RNase-free water) was spectrometrically assessed using the NanoVue Plus™ (GE Healthcare, Little Chalfont, UK). An absorbance ratio (A260:A280) of 1.7–2.0 was considered to represent good-quality total RNA. Ten microliters each of the RNA samples were reverse transcribed into cDNA using the High-Capacity cDNA Reverse Transcription Kit (Applied Biosystems,



**Figure 2.** Photomicrographs showing IHC with anti-VEGF (a–d), ANG-1 (e–h), and ANG-2 (i–l) and control tissue in healthy and inflamed dental pulp samples showing staining on endothelial cells (EC) and non-endothelial cells (Arrows). Positive controls are pyogenic granuloma specimens. (400 $\times$  magnification. Scale bar=50  $\mu\text{m}$ )

**TABLE 1.** Percentage of mean (SD) VEGF+, ANG-1+, and ANG-2+ stained cells in inflamed and healthy pulp specimens. \*denotes significant difference (p<0.05)

	VEGF+ cells % mean (SD)		ANG-1+ cells % mean (SD)		ANG-2+ cells % mean (SD)	
	Non-Endothelial Cells	Endothelial Cells	Non-Endothelial Cells	Endothelial Cells	Non-Endothelial Cells	Endothelial Cells
Inflamed	53±2	68±2	80±0.1	82±	67±1	76±1
Healthy	46±1	56±2%	71±2	72±2.0	61±2	70±2
p-value	0.008*	<0.001*	<0.001*	<0.001*	0.041*	0.032*

Foster City, USA) following manufacturer guidelines. Between experiments, purified total RNA and the resultant cDNA samples were stored at -20°C. A duplex qRT2-PCR was performed in a reaction mixture with a total volume of 20 µL containing 5 µL of sample cDNA, 10 µL of TaqMan Universal Master Mix, 1 µL of gene of interest (GOI; FAM probe), 1 µL of GAPDH VIC probe (housekeeping gene to normalize cDNA input amount), and 3 µL of nuclease-free H<sub>2</sub>O per well. Template control wells were also included to exclude gDNA contamination. Each sample was run in duplicate. Amplification and detection were carried out in optical-grade-96-well plates in the QuantStudioTM 6 Flex Real-Time PCR system (Applied Biosystems, Foster City, USA). The PCR cycling parameters were 20 s at 95°C, and 40 cycles of 3 s at 95°C and 30 s at 60°C. The data were analyzed using the delta-delta Cq method (26) with GraphPad Prism (GraphPad Software Inc. USA, Version 6D), and the Student's t-test was used calculate p-values. Normalized expression levels (2<sup>-ΔCq</sup>) and fold changes (2<sup>-ΔΔCq</sup>) were calculated, and comparisons were made between the healthy and inflamed samples. A fold change of greater than ±2 and P<0.05 were considered biologically and statistically significant.

**RESULTS**

**Immunohistochemistry**

**Qualitative expression**

VEGF showed intense intracellular expression, and it was highly expressed in ECs within newly formed vessels, particularly in the inflamed pulp tissue. Some VEGF expression was also observed in non-ECs, morphologically identified as mast cells, macrophages, and lymphocytes. Ang-1 and Ang-2 showed intense intracellular expression in ECs and non-ECs in healthy and inflamed pulp tissue (Fig. 2).

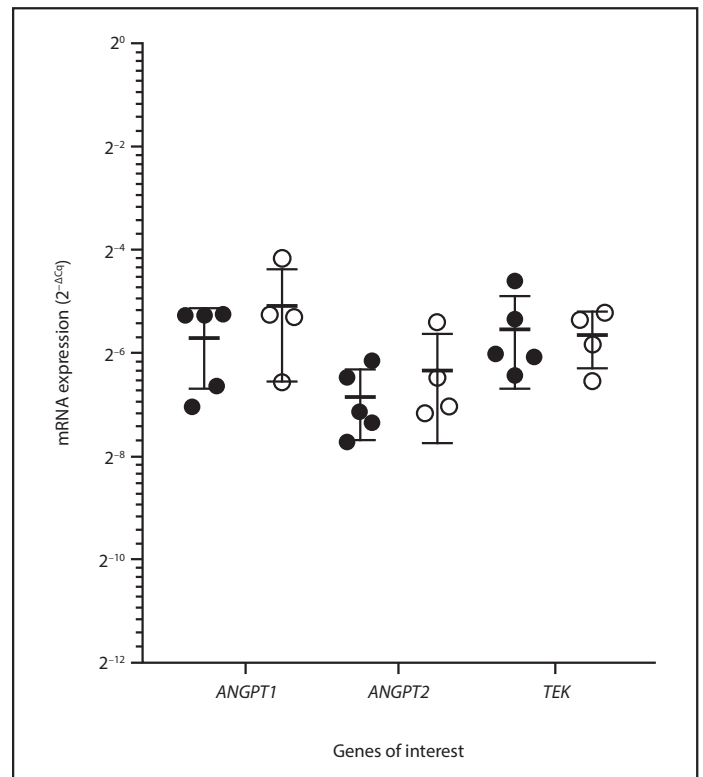
**Quantitative analysis**

The percentage of mean VEGF expressed on ECs significantly increased in the inflamed samples, while ECs and non-ECs had significantly greater Ang-1 and Ang-2 expressions in inflamed pulp tissue compared to healthy pulp tissue (P<0.05) (Table 1).

**Gene expression**

One of the inflamed samples did not meet the RNA quality threshold (A260/A280 1.7<χ<2), so it was not included. The duplex qRT2-PCR was determined to be sensitive with all assays showing an efficiency of <95% and R2 values <0.990.

Calculated fold regulation (2<sup>-ΔΔCq</sup>) for the inflamed pulp group compared with the healthy group showed a slight



**Figure 3.** The ANGPT1, ANGPT2, and TEK mRNA expression levels. Data are expressed as mean (SD) with healthy pulp (n=4, open circles) and inflamed pulp samples (n=5, closed circles) showing

trend toward a higher expression of ANGPT1 [fold regulation (FR)=1.52] and ANGPT2 (FR=1.39); however, these did not reach significance (ANGPT1 p=0.5, ANGPT2 p=0.5) (Fig. 2). In contrast, there was no difference in the TEK expression between healthy and inflamed specimens (P=0.7) (Fig. 3).

**DISCUSSION**

Inflammatory changes associated with reversible pulpitis are accompanied by the release of a variety of chemical mediators and growth factors (9, 27). This study has provided new knowledge related to the role of angiopoietins in the dental pulp. The findings from this study partially reject the null hypothesis. While there were significant differences in ANG-1, ANG-2 and VEGF expressions at protein level there was no significant difference in gene expressions. All factors are expressed in the reversible pulpitis but Ang-1 and VEGF are increased while Ang-2 and TEK remain relatively constant between health and early disease suggesting that changes are tightly regulated in

response to mild inflammation. However, protein and mRNA expression do not always correlate, and so there should be caution in making direct comparison.

Use of a clinical diagnosis is a reliable measure for sample selection of healthy pulps and reversible pulpitis. Ricucci and colleagues (24) demonstrated that a clinical diagnosis of a healthy or reversible pulpitis matched the histological diagnosis in 96.6% of cases; however, we validated the diagnosis with histological by an oral pathologist.

A novel method for examination of the dental pulp was developed that included tooth sectioning and whole excavation of the soft pulp tissue. This technique enabled collection of sufficient quantity of tissue for gene expression experiments and good visualization of the pulp for IHC without the need for hard tissue decalcification. Decalcification preserves the orientation and surrounding morphology of tooth specimens, but takes time and can reduce the antigenicity of the tissues (28). Although the approach used in this study meant there was some loss of tissue orientation and not all odontoblasts were visible, but this did not influence the overall findings.

This study did not examine the radicular pulp, and the reason for this was two-fold. Firstly, the continuous deposition of secondary dentine along the length of mature tooth roots results in a large biological variability between samples, and there is inherent difficulty in extracting quality tissue from tooth roots and avoiding contamination for gene expression experiments (29). Secondly, examination of the coronal pulp provides clinically relevant information related to the local availability of growth factors in the coronal pulp chamber. This is the region of the pulp most commonly accessed for vital pulp therapies following deep caries, pulp exposure, or dental trauma (23).

Similar trends were observed between IHC and gene expression of Ang-1, Ang-2, and VEGF in the healthy and inflamed samples, but there was no direct correlation between VEGF and Ang-1 protein and mRNA in terms of significance. This lack of correlation between protein and mRNA is not uncommon, but it may also reflect the reversible stage of pulpitis. IHC assesses the protein level of genes based on the ability of antibodies to bind proteins expressed by cells in whole tissue sections, while gene expression studies detect the level of mRNA in a sample. Several factors can contribute to differences in outcomes of these techniques. Biological variability between samples is common, and other post-transcriptional mechanisms involved in turning mRNA into protein can also influence findings (30).

Ang-1 regulates EC recruitment of smooth muscle cells. The findings from this study suggest this growth factor has possible roles in healthy and inflamed pulp tissue where it may support vessel stabilization during pulp angiogenesis and healing. Further, Ang-1 has an anti-inflammatory effect and regulates vascularity in a VEGF-dependent manner (12, 22). The abundance of VEGF and upregulation of ANG-1 in the inflamed pulp samples suggest that these growth factors may act synergistically offering a protective effect to promote healing in reversible pulpitis. Further studies with a larger sample size and variable inflammation may provide more insight into

the extent of their downstream effects on angiogenesis and pulp disease.

When total Ang-2 protein expression (ECs and Non-ECs) was considered, it was similarly expressed in healthy and inflamed samples. Ang-2 is upregulated during hypoxia, infection, and with disease severity (20); and so it is reasonable to predict that increased Ang-2 expression is a likely feature of advanced pulp disease where there is irreversible pulpitis or longstanding pulp inflammation accompanied by increased tissue hypoxia and chronic infection. Similar observations have been made following dermal wound healing where there is a moderate level of Ang-2 expression in unwounded skin and only a minimal increase following wounding (19).

Inflammation associated with reversible pulpitis did not influence the expression of the *TEK* gene, encoding Tie2. Similar observations have been made during dermal healing where there were no changes in the Tie2 expression at protein or mRNA level in control skin and during tissue regeneration (31). This suggests that in mildly inflamed pulp tissue, Ang-1 and Ang-2 growth factors may act independent of the receptor, which is in contrast to later stages of inflammation where the Tie2 signaling assumes an adaptive function regulated by Ang-1 and Ang-2, and is reduced to contain infection or inflammation (22). Observation of the Tie2 protein expression using IHC was not performed in this study. Expression of the *TEK* gene in inflamed and healthy specimens, albeit at a similar level, suggests that investigation of the receptor in a larger sample of inflamed tissue may provide further insight into Ang-1/Ang-2/Tie2 signaling.

Among all the proangiogenic factors, VEGF is a key regulator for vasculogenesis, angiogenesis, healing, and disease (10). Given the role of VEGF in tissue inflammation (9), it is not surprising that there was higher expression of VEGF in the pulpitis samples, and it may suggest that VEGF is implicated in the progression of pulpitis.

Angiopoietins may contribute to angiogenesis independently or modulated by VEGF (18). VEGF and Ang-1 are both proangiogenic, but Ang-1 stabilizes vessels and protects them from VEGF-induced plasma leakage (32). The findings of this study tend to support this model in reversible pulpitis. Ang-1 and, to a lesser extent, Ang-2 were upregulated in the inflamed pulp samples indicating that Ang-1 may act synergistically with Ang-2 and other angiogenic growth factors to promote angiogenesis and vascular sprouting during pulp homeostasis, healing, and disease progression.

## CONCLUSION

The presence of Ang-1, Ang-2, VEGF, and Tie2/*TEK* in healthy pulp tissue indicates that these angiogenic factors may be locally produced and are able to participate in immune surveillance, pulp homeostasis, and physiological angiogenesis. The altered expression of VEGF and Ang-1 in reversible pulpitis may suggest that together these factors offer a protective role in early inflammation and the potential to contribute to pulp angiogenesis and healing. The Ang-1/Ang-2/Tie2 signaling appears to be regulated by the progression of inflammation, and VEGF has an important role in modulating downstream effects.

**Disclosures**

**Conflict of interest:** The Authors declare no conflict of interest.

**Ethics Committee Approval:** Ethical approval for this study was obtained from the University of Otago, Human Ethics Committee (Health) H15/002.

**Peer-review:** Externally peer-reviewed.

**Financial Disclosure:** This project was funded by the Immunopathology Research Group, Sir John Walsh Research Institute, University of Otago, New Zealand. No external funding was received for this project.

**Authorship contributions:** Concept – L.F., H.H., A.R.; Design – L.F., A.A., A.R.; Supervision – L.F., A.R., H.H.; Fundings – A.R., L.F., T.M., H.H., B.S.; Materials – L.F., A.R., T.M., H.H., B.S.; Data collection &/or processing – A.A., L.F., H.H.; Analysis and/or interpretation – A.A., L.F., H.H., T.M., B.S.; Literature search – A.A., L.F.; Writing – A.A., L.F.; Critical Review – L.F., A.A., A.R., H.H., T.M., B.S.

**REFERENCES**

- Goldberg M, Njeh A, Uzunoglu E. Is pulp inflammation a prerequisite for pulp healing and regeneration? *Mediators Inflamm* 2015;2015:1-11.
- Ricucci D, Loghin S, Lin LM, et al. Is hard tissue formation in the dental pulp after the death of the primary odontoblasts a regenerative or a reparative process? *J Dent* 2014;42(9):1156-70.
- Cooper PR, Holder MJ, Smith AJ. Inflammation and regeneration in the dentin-pulp complex: A double-edged sword. *J Endod* 2014;40(4):S46-S51.
- Eming SA, Brachvogel B, Odoriso T, Koch M. Regulation of angiogenesis: Wound healing as a model. *Prog Histochem Cytochem* 2007;42(3):115-70.
- Rajashekhar G, Willuweit A, Patterson CE, et al. Continuous endothelial cell activation increases angiogenesis: evidence for the direct role of endothelium linking angiogenesis and inflammation. *J Vasc Res* 2006;43(2):193-204.
- Al-Hassiny A, Friedlander LT, Parachuru VPB, et al. Upregulation of angiogenesis in oral lichen planus. *J Oral Pathol Med* 2018;47(2):173-8.
- Aranha AMF, Zhang Z, Neiva KG, et al. Hypoxia enhances the angiogenic potential of human dental pulp cells. *J Endod* 2010;36(10):1633-7.
- Nanci A. Ten Cate's oral histology : Development, structure, and function. In: *Oral histology*. 9th edition. ed.: Elsevier; 2018. p. 175-83.
- Artese L, Rubini C, Ferrero G, et al. Vascular endothelial growth factor (VEGF) expression in healthy and inflamed human dental pulps. *J Endod* 2002;28(1):20-3.
- Mattuella LG, Bento LW, de Figueiredo JAP, et al. Vascular endothelial growth factor and its relationship with the dental pulp. *J Endod* 2007;33(5):524-30.
- Tran-Hung L, Laurent P, Camps J, About I. Quantification of angiogenic growth factors released by human dental cells after injury. *Arch Oral Biol* 2008;53(1):9-13.
- Zadeh G, Koushan K, Pillo L, et al. Role of Ang1 and its interaction with VEGF-A in astrocytomas. *J Neuropathol Exp Neurol* 2004;63(9):978-89.
- Bhaskar A, Gupta R, Sreenivas V, et al. Synergistic effect of vascular endothelial growth factor and angiopoietin-2 on progression free survival in multiple myeloma. *Leuk Res* 2013;37(4):410-5.
- Brindle NPJ, Saharinen P, Alitalo K. Signalling and functions of Angiopoietin-1 in vascular protection. *Circ Res* 2006;98(8):1014-23.
- Thomas M, Augustin HG. The role of the angiopoietins in vascular morphogenesis. *Angiogenesis* 2009;12(2):125-37.
- Maisonpierre PC, Suri C, Jones PF, et al. Angiopoietin-2, a natural antagonist for Tie2 that disrupts in vivo angiogenesis. *Science* 1997;277(5322):55-60.
- Makinde T, Agrawal DK. Intra and extravascular transmembrane signalling of angiopoietin-1-Tie2 receptor in health and disease. *J Cell Mol Med* 2008;12(3):810-28.
- Thurston G, Daly C. The complex role of Angiopoietin-2 in the Angiopoietin-Tie signaling pathway. *Cold Spring Harb Perspect Med* 2012;2(9):a006650.
- Staton CA, Valluru M, Hoh L, et al. Angiopoietin-1, angiopoietin-2 and Tie-2 receptor expression in human dermal wound repair and scarring. *Br J Dermatol* 2010;163(5):920-7.
- Orfanos SE, Kotanidou A, Glynos C, et al. Angiopoietin-2 is increased in severe sepsis: correlation with inflammatory mediators. *Crit Care Med* 2007;35(1):199-206.
- Peters S, Cree IA, Alexander R, et al. Angiopoietin modulation of vascular endothelial growth factor: Effects on retinal endothelial cell permeability. *Cytokine* 2007;40(2):144-50.
- Parikh SM. Angiopoietins and Tie2 in vascular inflammation. *Curr Opin Hematol* 2017;24(5):432-8.
- Bjørndal L, Fransson H, Bruun G, et al. Randomized Clinical Trials on Deep Carious Lesions: 5-Year Follow-up. *J Dent Res* 2017;96(7):747-53.
- Ricucci D, Loghin S, Siqueira JF. Correlation between clinical and histologic pulp diagnoses. *J Endod* 2014;40(12):1932-9.
- Lucarini G, Tirabassi G, Zizzi A, et al. Uncoupling of vascular endothelial growth factor (VEGF) and inducible nitric oxide synthase (iNOS) in gingival tissue of type 2 diabetic patients. *Inflammation* 2016;39(2):632-42.
- Livak KJ, Schmittgen TD. Analysis of relative gene expression data using real-time quantitative PCR and the 2<sup>-ΔΔCT</sup> method. *Methods* 2001;25(4):402-8.
- El karim IA, Linden GJ, Irwin CR, Lundy FT. Neuropeptides regulate expression of angiogenic growth factors in human dental pulp fibroblasts. *J Endod* 2009;35(6):829-33.
- Liu H, Zhu R, Liu C, et al. Evaluation of decalcification techniques for rat femurs using HE and immunohistochemical staining. *Biomed Res Int* 2017;2017:6.
- Tran-Hung L, Tran-Thi N, Aboudharam G, et al. A new method to extract dental pulp DNA: application to universal detection of bacteria. *PLoS one* 2007;2(10):e1062-e.
- Pascal LE, True LD, Campbell DS, et al. Correlation of mRNA and protein levels: cell type-specific gene expression of cluster designation antigens in the prostate. *BMC Genomics* 2008;9:246-.
- Kämpfer H, Pfeilschifter J, Frank S. Expressional regulation of Angiopoietin-1 and -2 and the Tie-1 and -2 Receptor Tyrosine Kinases during cutaneous wound healing: A comparative study of normal and impaired repair. *Lab Invest* 2001;81:361.
- Gavard J, Patel V, Gutkind JS. Angiopoietin-1 prevents VEGF-induced endothelial permeability by sequestering Src through mDia. *Dev Cell* 2008;14(1):25-36.