



Contents lists available at ScienceDirect

International Journal of Surgery Case Reports

journal homepage: www.casereports.com

Giant Meckel's diverticulum compressing root of mesentery – A rare cause of ileal gangrene – Case report and review of literature



Mohammed Farooq, Aashish Rajesh*

Madras Medical College, No.3 EVR Periyar Salai, Park Town, Chennai 600003, Tamil Nadu, India

ARTICLE INFO

Article history:

Received 7 May 2017

Received in revised form 16 May 2017

Accepted 11 June 2017

Available online 14 July 2017

Keywords:

Meckel's diverticulum

Acute intestinal obstruction

Incidental Meckel's diverticulum

Ileal gangrene

Root of mesentery compression

Case report

ABSTRACT

INTRODUCTION: Meckel's diverticulum (MD) commonly presents as gastrointestinal bleeding in the pediatric population and intestinal obstruction in adults. There is no consensus for surgical excision of an incidentally diagnosed MD. We present a hitherto unreported vascular cause of intestinal gangrene due to MD.

CASE PRESENTATION: A 16 year old boy was referred as an acute abdomen for tertiary hospital management. Clinical examination and CT suggested small bowel obstruction and emergency laparotomy was performed. A giant MD compressing the root of mesentery, causing critical occlusion of the ileal vessels and extensive ileal gangrene was found. The gangrenous bowel was resected and a jejunum-ascending colon anastomosis was done. Postoperative recovery was uneventful.

DISCUSSION: This case report highlights an unrecognized complication of a giant Meckel's diverticulum. There are no clear guidelines on the management of an incidentally discovered MD though certain studies recommend resection of an incidental MD in males and individuals less than 50 years of age or when the MD is larger than 2 cm or contains histologically abnormal tissue. Other meta-analyses do not recommend routine resection. MD has been identified as a high risk region for ileal malignancy and its resection usually has minimal morbidity. A valid consent for opportunistic resection of a Meckel's diverticulum in any laparotomy would be discerning.

CONCLUSION: Appropriate opportunistic resection of an incidental Meckel's diverticulum may prevent extensive surgical morbidity later. This case highlights the need to revisit guidelines for management of incidentally identified MD.

© 2017 The Authors. Published by Elsevier Ltd on behalf of IJS Publishing Group Ltd. This is an open access article under the CC BY-NC-ND license (<http://creativecommons.org/licenses/by-nc-nd/4.0/>).

1. Introduction

Meckel's diverticulum (MD) commonly presents as gastrointestinal bleeding in the pediatric population and as intestinal obstruction in adults. We present an unusual case of ileal gangrene resulting from a giant Meckel's diverticulum due to a hitherto unidentified mechanism.

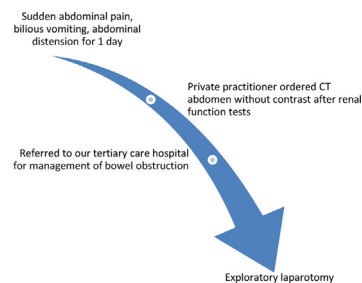
2. Patient information

A 16 year old boy was referred to our emergency from a private practitioner for an acute abdomen. He had complained of sudden onset, unremitting abdominal pain, five to six episodes of bilious vomiting and abdominal distension lasting for a day. He had passed normal stools earlier that day. He had no previous gastrointestinal bleed, cardiovascular disease and no history suggestive of hypercoagulable states. No other relevant medical or surgical history was obtained.

3. Clinical findings

On examination, he was afebrile with a temperature of 97.2 °F, dehydrated and tachypneic (respiratory rate of 23 cycles per minute). His heart rate was 118 beats per minute and blood pressure was 94/70 mm Hg. Femoral pulses were palpable. His abdomen was distended and rigid. Diffuse tenderness was present more so in the periumbilical region. Bowel sounds were absent. Digital rectal examination revealed an empty rectum.

4. Timeline



* Corresponding author at: B1401, The Atlantic, No.3 Montieth Road, Egmore, Chennai, 600008, India.

E-mail address: ashish747raj@gmail.com (A. Rajesh).

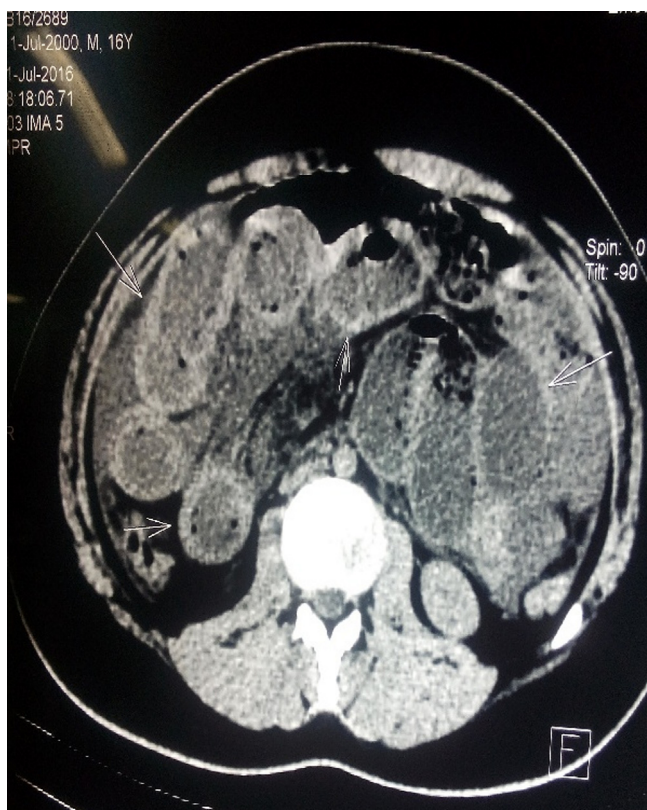


Fig. 1. Pneumatosis intestinalis.

5. Diagnostic assessment

Total white cell count was 10,000 cells/microliter. Renal function tests revealed blood urea nitrogen – 94 mg/dl and serum creatinine of 1.9 mg/dl. Liver function tests were within normal

parameters. Amylase was 228U/L and lipase was 48U/L. ABG was consistent with metabolic acidosis with a pH of 7.29. Serum lactate levels were raised. Blood glucose level was 74 mg/dl and serum calcium was 9.1 mg/dl. CT abdomen revealed dilated bowel loops with pneumatosis intestinalis (Figs. 1 and 2). Contrast had not been used due to elevated renal parameters. A diagnosis of small bowel obstruction with possible intestinal gangrene was made and emergency surgery was scheduled.

6. Therapeutic intervention

After anesthetic clearance, emergency laparotomy was performed under general anesthesia with prophylactic antibiotics. There was extensive ileal gangrene (180 cm) with a transition zone 5 cms proximal to the ileocaecal junction. This was due to a long Meckel's diverticulum (15 cm) that had coiled around the root of the mesentery (Fig. 3) causing a critical occlusion of the ileal vessels. This is a first-in-human reported unusual cause of ileal gangrene from a long Meckel's diverticulum. The compression was released (Fig. 4) and the gangrenous bowel was resected along with the caecum and ascending colon (Fig. 5). A jejunum-ascending colon anastomosis was done. Postoperative recovery was uneventful and the patient was discharged home four days later.

7. Follow-up and outcomes

The patient was followed up as an outpatient 2 weeks after discharge and was well with no further complaints. Another follow-up was done at 3 months.

8. Discussion

This unusual mechanism of a Meckel's diverticulum strangulating the ileal vessels and resulting in gangrene has thus far not been reported in literature. The common cause of ileal gangrene from these diverticula is secondary to intestinal obstruction. Longer Meckel's diverticulum confers more mobility and facilitates

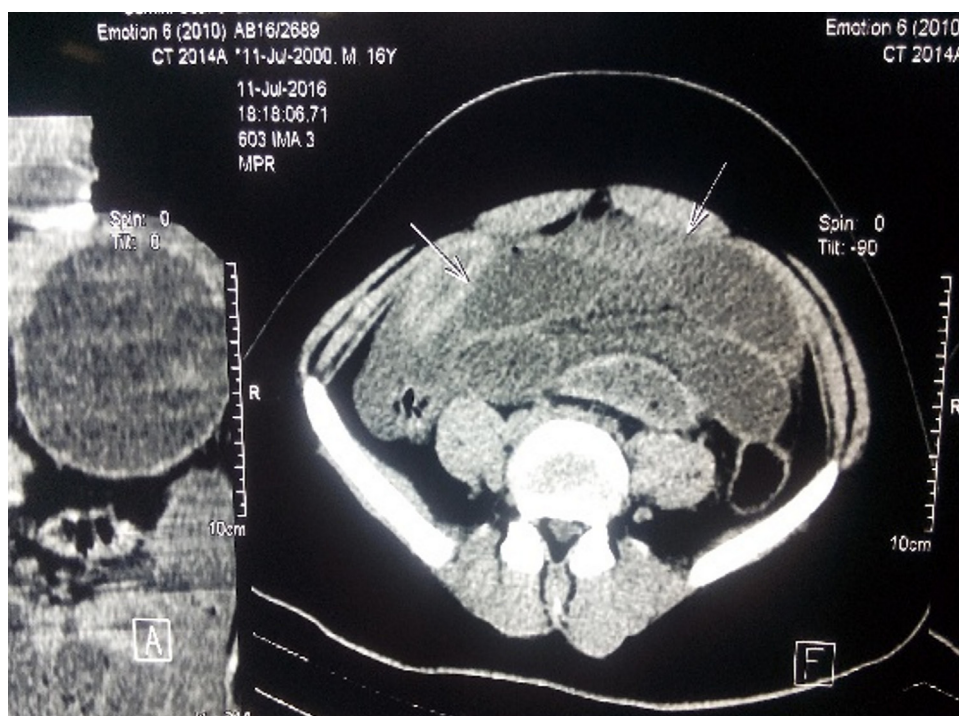


Fig. 2. Non-contrast CT showing degree of dilation of bowel with pneumatosis intestinalis.

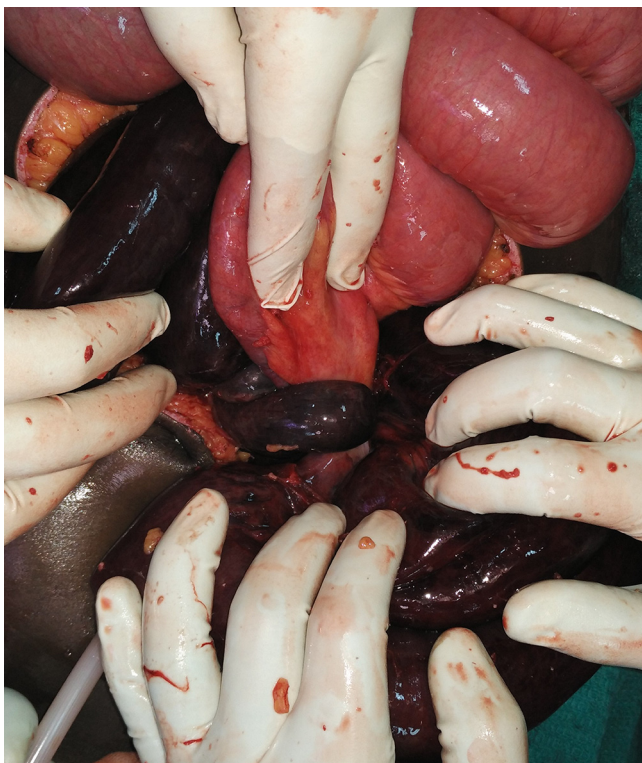

Fig. 3. Meckel's diverticulum compressing root of mesentery seen.

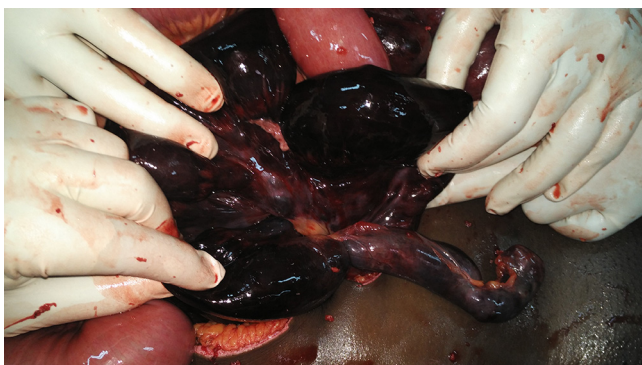


Fig. 4. Intraoperative photograph after releasing the compression.

incidental strangulation and torsion. Meckel's diverticulum (MD), a congenital true diverticulum is an embryonic remnant of the omphalomesenteric duct. Persistence of the omphalomesenteric duct can result in any of the following anomalies – most commonly a MD, vitello-intestinal fistula, umbilical sinus, a fibrous cord, enterocystoma, mesodiverticular band, or a congenital umbilical hernia from contraction of the band [1]. Ectopic tissue is found in up to 55% of Meckel's diverticula [2]. Gastric and pancreatic tissue predominate, with corresponding incidences of 60–85% and 5–16% [3,4]. These may present with ulcerations due to the acidic or alkaline secretions.

The commonest complication of Meckel's diverticulum in the pediatric population is a gastrointestinal bleed due to peptic ulceration of the heterotopic gastric mucosa [5]. In adults, symptomatic Meckel's diverticular pathology frequently presents as an intestinal obstruction. Causative mechanisms for an obstruction include an omphalomesenteric band, internal hernia or volvulus through the vitelline duct remnants, intussusception, incarceration within a hernia sac (Littre's hernia) or a chronic Meckel's diverticulitis

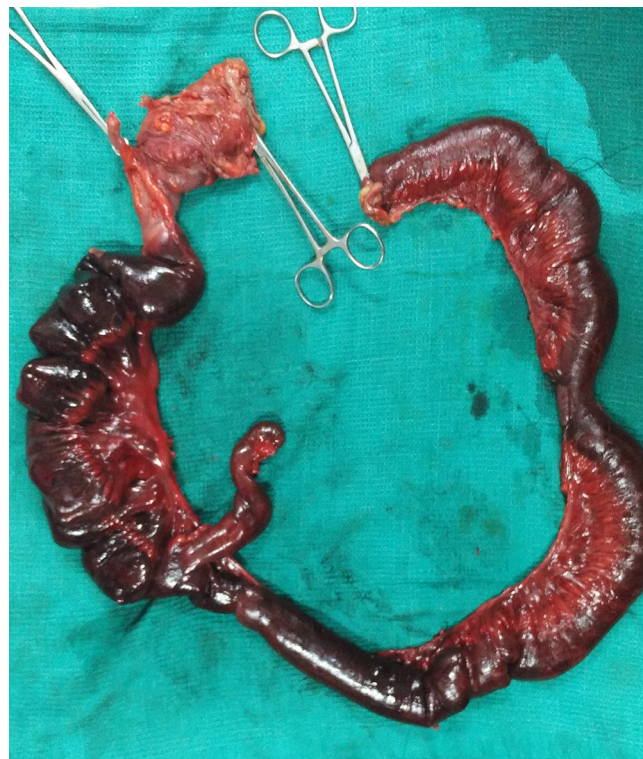

Fig. 5. Extensive ileal gangrene (postoperative specimen).

[6]. Diverticulectomy, with or without limited bowel resection and primary anastomosis is essential in these patients [7].

MD is commonly 2 cms long and if it is longer than 5 centimeters, is termed a giant Meckel's diverticulum. Long Meckel's diverticula have been associated with enteroliths and are hence prone for obstruction. Symptomatic MD warrants surgical resection, though preoperative diagnosis of MD related pathology is rare. Asymptomatic incidentally discovered Meckel's diverticulum has been a subject of intense debate. Only 4% of those with MD would require MD-related hospital admission and 2.9% (number needed to treat for prevention = 34) would require surgery [8]. Park et al. in their analysis of 1476 patients with MD showed no complications or deaths with diverticulectomy. They suggested that incidental discovery of a MD along with any of the following four factors – age less than 50 years, male sex, length greater than 2 cm or histologically abnormal tissue warrants resection as these are associated with MD producing complications [9].

Zani et al. in their meta-analysis concluded that 758 patients with incidental MD would need resection to prevent 1 death from MD related complications. They showed that the morbidity due to the resection of an incidental MD was substantially higher than leaving it in situ (5.3% in the resected compared with 1.3% in the non-resected MD ($P < 0.0001$)) [10]. However the follow up period was variable in the studies and there was no evaluation of a malignancy in the MD later. Since then, surgical procedures and postoperative care has improved substantially.

Thirunavukarasu et al. found the risk of ileal malignancy in MD was 70 times higher than for any other ileal site. Interestingly their study identified an increase in Meckel's diverticular cancer (MDC) in patients more than 50 years of age and especially in women over the last few decades. Histologically, abnormal tissue in an asymptomatic MD may only be palpable in 38% of patients though it is present in 60% of MD [8]. Furthermore as MD cancer is usually localized, with a high potential for curative resection and negli-

gible operative complications [9,10] they advocated resection of incidentally detected MD during surgery for other pathology [11].

Incidental Meckel's diverticulectomy during any laparotomy would reduce the differential diagnosis confounders for any obscure abdominal pain. Moreover morbidity associated with emergency MD surgery was much higher than resection of an asymptomatic MD [4].

Surgical treatment of an omphalomesenteric anomaly with a narrow base is by amputation and closure of the defect. A simple diverticulectomy usually suffices in an asymptomatic MD. If there is presence of ectopic tissue and inflammatory process in adjacent bowel, it needs resection of that part of the intestine with anastomosis. Tumors in MD require wide intestinal resection along lymphatic pathways. If the base of the MD is edematous or perforated, ileal resection should be done [12]. Hence incidental MD resection may minimize morbidity due to sudden MD pathology.

Given Thirunavukarasu's finding, the current longevity of the average human life span, the finding by Cullen et al. that complications due to MD do not reduce with age and the minimal morbidity of incidental resection, there seems to be a role for all incidentally diagnosed MD during laparotomy or laparoscopy to be resected. Further studies and consensus are however needed to validate this recommendation. Till then, a giant MD definitely suggests a clear cut resection even if asymptomatic. This case report has been reported in line with the SCARE criteria [13].

Patient perspective

The patient had enormous symptomatic relief after the procedure. He was able to return to his routine after four days.

Conflicts of interest

No conflict of interest.

Funding

This report received no funding.

Ethical committee approval

Not applicable.

Consent

Written informed consent has been obtained.

Author contribution

Mohammed Farooq – Data collection and analysis, revision of manuscript, approval of final version.

Aashish Rajesh – Drafting the manuscript, revision, approval of final version.

Guarantor

Aashish Rajesh.

References

- [1] A.A. Malik, Shams-ul-Bari, K.A. Wani, A.R. Khaja, Meckel's diverticulum—revisited, *Saudi J. Gastroenterol.* 16 (1) (2010) 3–7, <http://dx.doi.org/10.4103/1319-3767.58760>.
- [2] W.S. Haubrich, F. Schaffner, J.E. Berk, H.L. Bockus, *Gastroenterology*, vol. 2, 5th ed., Saunders, Philadelphia, 1995, pp. 912–914.
- [3] W.C. Mackey, P. Dineen, A fifty-year experience with Meckel's diverticulum, *Surg. Gynecol. Obstet.* 156 (1983) 56–64.
- [4] J.J. Cullen, K.A. Kelly, C.R. Moir, D.O. Hodge, A.R. Zinsmeister, L.J. Melton 3rd, Surgical management of Meckel's diverticulum. An epidemiologic, population-based study, *Ann. Surg.* 220 (1994) 564–569.
- [5] D. St-Vil, M.L. Brandt, S. Panic, et al., Meckel's diverticulum in children: a 20-year review, *J. Pediatr. Surg.* 26 (1991) 1289–1292.
- [6] R.T. Prall, M.O. Bannon, A.E. Bharucha, Meckel's diverticulum causing intestinal obstruction, *Am. J. Gastroenterol.* 96 (2001) 3246–3247.
- [7] V.T. Tiong, T. Shimpi, S. Shikhare, L.R. Chong, Axial torsion of Meckel's diverticulum, *ANZ J. Surg.* (February) (2017), <http://dx.doi.org/10.1111/ans.13889> (Epub ahead of print).
- [8] A. Zani, S. Eaton, C.M. Rees, A. Pierro, Incidentally detected Meckel diverticulum: to resect or not to resect? *Ann. Surg.* 247 (2008) 276–281.
- [9] J.J. Park, B.G. Wolff, M.K. Tollefson, et al., Meckel diverticulum: the Mayo clinic experience with 1476 patients (1950–2002), *Ann. Surg.* 241 (2005) 529–533.
- [10] B. Zulfikaroglu, N. Ozalp, E. Zulfikaroglu, et al., Is incidental Meckel's diverticulum resected safely? *N. Z. Med. J.* 121 (2008) 39–44.
- [11] P. Thirunavukarasu, M. Sathaiah, S. Sukumar, et al., Meckel's diverticulum: a high-risk region for malignancy in the ileum, *Ann. Surg.* 253 (2011) 223–230.
- [12] R.L. Varcoe, S.W. Wong, C.F. Taylor, G.L. Newstead, Diverticulectomy is inadequate treatment for short Meckel's diverticulum with heterotopic mucosa, *ANZ J. Surg.* 74 (2004) 869–872.
- [13] R.A. Agha, A.J. Fowler, A. Saetta, I. Barai, S. Rajmohan, D.P. Orgill, The SCARE Group, The SCARE Statement: consensus-based surgical case report guidelines, *Int. J. Surg.* 34 (2016) 180–186.

Open Access

This article is published Open Access at sciedirect.com. It is distributed under the [IJSCR Supplemental terms and conditions](#), which permits unrestricted non commercial use, distribution, and reproduction in any medium, provided the original authors and source are credited.