

Spontaneous Anterior Lens Capsule Rupture Of a Patient with Alport Syndrome - A Case Report

Kalina Trifonova¹, George Jordanoff¹, Valentin Stoyanov¹, Kiril Slaveykov^{2*}

¹Trakijski Universitet Stara Zagora, Meditsinski fakultet, Otorhinolaryngology, Stara Zagora, Bulgaria; ²Trakijski Universitet Stara Zagora, Meditsinski fakultet, General Medicine, Armeiska 11, Stara Zagora 6000, Bulgaria

Abstract

Citation: Trifonova K, Jordanoff G, Stoyanov V, Slaveykov K. Spontaneous Anterior Lens Capsule Rupture Of a Patient with Alport Syndrome - A Case Report. Open Access Maced J Med Sci. 2017 Dec 15; 5(7):974-977. <https://doi.org/10.3889/oamjms.2017.219>

Keywords: Alport syndrome; Genetic disease; Lens; Capsule rupture; Phacoaspiration

***Correspondence:** Kiril Slaveykov, Trakijski Universitet Stara Zagora Meditsinski fakultet, General Medicine, Armeiska 11, Stara Zagora 6000, Bulgaria. E-mail: kirilslaveykov@gmail.com

Received: 31-Aug-2017; **Revised:** 01-Oct-2017; **Accepted:** 16-Oct-2017; **Online first:** 11-Dec-2017

Copyright: © 2017 Kalina Trifonova, George Jordanoff, Valentin Stoyanov, Kiril Slaveykov. This is an open-access article distributed under the terms of the Creative Commons Attribution-NonCommercial 4.0 International License (CC BY-NC 4.0).

Funding: This research did not receive any financial support.

Competing Interests: The authors have declared that no competing interests exist.

BACKGROUND: Alport syndrome is a progressive genetic disease which is characterised by glomerulonephritis, sensorineural deafness and ocular abnormalities. We aimed to present a clinical case of a patient with Alport syndrome with spontaneous anterior lens capsule rupture.

CASE REPORT: A 16-year-old male with histologically proven Alport syndrome was hospitalised in the Department of Ophthalmology, University Hospital „Prof. Stoyan Kirkovich“, Stara Zagora with low vision, pain, redness, high IOP and rupture of the anterior lenticular capsule of the right eye. Phacoaspiration was successfully performed (Millenium, Bausch& Lomb, Rochester, New York, USA) with the bimanual irrigation-aspiration system (Geuder AG, Heidelberg, Germany) with excellent visual results.

CONCLUSION: As the syndrome is quite rare and can lead to diagnostic difficulties for the ophthalmologist complications such as spontaneous or traumatic rupture of the capsule are not uncommon. In such cases, phacoaspiration is an efficient method for clear lens extraction after ruptures of the anterior lenticular capsule of young patients with Alport syndrome.

Introduction

Alport syndrome is a common cause of inherited kidney failure but often goes unrecognised [1]. It is a progressive hereditary disease, characterised by glomerulonephritis /hematuria and proteinuria, leading to renal failure, sensorineural deafness and ocular abnormalities [2]. Alport syndrome has a prevalence of 1/5000, and 85% of patients have the X-linked form, where affected males develop renal failure and usually have a high-tone sensorineural deafness by the age of 20 [3].

Autosomal dominant and autosomal recessive inheritance has also been reported. [4] The disease is the cause of about 2% of end-stage renal disease in Europe and the United States. Alport syndrome is clinically and genetically heterogeneous.

It is related to mutations in the genes encoding one of three chains, $\alpha 3$, $\alpha 4$ $\alpha 5$ of type IV collagen, the main component of basement membranes, expressed in the glomerular basement membrane. COL4A5 mutations are associated with X-linked Alport syndrome, which represents 80 to 85% of cases and is more severe in boys than in girls [5]. This protein is probably common to the basement membranes of the glomerulus, cochlea, retina, lens capsule, and cornea. However, the alpha 3(IV) and 4(IV), as well as the alpha 5(IV) collagen chains, are usually absent from the affected basement membranes, because the abnormal alpha 5(IV) molecule interferes with the stability of all three. The loss of these collagen molecules from the affected basement membranes results in an abnormal ultrastructural appearance. Mutations in COL4A3 or COL4A4 are associated with autosomal Alport syndrome [3].

Ocular changes are uncommon and subtle in

young patients with Alport syndrome and suggest that the signs increase in frequency and severity with age [6]. The types of ocular defects mostly involve the lens, the retina and more rarely the cornea [7]. The typical ocular associations are a dot-and-fleck retinopathy which occurs in about 85% of affected adult males, anterior lenticonus which occurs in about 25%, and the rare posterior polymorphous corneal dystrophy. The retinopathy and anterior lenticonus are not usually demonstrated in childhood, but worsen with time so that the retinal lesion is often present at the onset of renal failure, and the anterior lenticonus, later [3]. Retinal abnormalities include a perimacular dot-and-fleck retinopathy and a peripheral fleck retinopathy, which might occur independently of each other; a 'dull macular reflex' or 'lozenge', when the perimacular flecks are confluent; and, rarely, a macular hole caused by retinal thinning [1].

Giant macular holes are one possible retinal complication of Alport syndrome. Their pathogenesis differs from idiopathic macular holes and may result from the combination of collagen type IV abnormalities in the basement membranes of both Bruch's membrane and the internal limiting membrane, along with anomalous vitreoretinal adhesion [8]. Additional ocular features described in X-linked Alport syndrome include other corneal dystrophies, microcornea, arcus, iris atrophy, cataracts, spontaneous lens rupture, spherophakia, posterior lenticonus, a poor macular reflex, fluorescein angiogram hyperfluorescence, electrooculogram and electroretinogram abnormalities, and retinal pigmentation [3]. Anterior lens capsule rupture is a rare complication in adolescence as we found only 3 reported cases in the literature [4, 9, 10].

The histopathologic findings of patients with Alport syndrome examined by transmission electron microscopy show that the thickness of the anterior lens capsules is decreased (4-13 micron) and that there are many vascular dehiscences localised at the inner part of the lens capsule. There are large numbers of capsular dehiscences containing fibrillar materials and vacuoles. The anterior capsules are fragile in this disease, forming the basis for the progressive lenticonus and anterior polar cataract [2, 11, 12, 13]. It can also explain the cases of spontaneous anterior lens capsule ruptures

We aimed to present a clinical case of a patient with Alport syndrome with spontaneous anterior lens capsule rupture.

Case report

A 16-year-old male patient checked in the Emergency Department of the University Hospital

„Prof. Stoyan Kirkovich“ in the afternoon on the 15th of June 2015, with complaints of pain, redness and low vision of his right eye. He was urgently admitted to the Ophthalmology Department on the same evening. The patient did not report sustaining any injury to his eye or head and did not remember any such trauma in the recent past, though admitting to often rubbing his eyes. He was uncertain when the complaints had first appeared, but this was the first time this had happened. Up until this point, he had never been examined by an ophthalmologist. The examination provided us with the following findings:

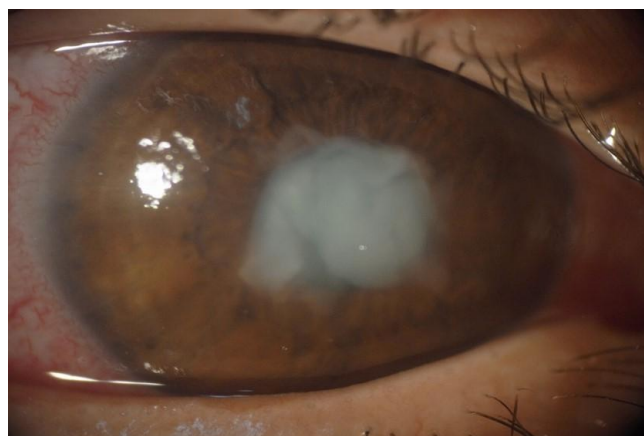

Figure 1: Anterior lens capsule rupture on diffuse light

Right eye: Vision was light perception and projection due to the opacified lens particles. Conjunctival congestive hyperemia and corneal subepithelial cystoid oedema were present, with decreased transparency. The pupil was narrow and did not respond to mydriatics and light; the anterior chamber was shallow. IOP was increased (49 mmHg) because of the lens-induced secondary glaucoma. The anterior capsule was ruptured with swollen and opacified lens particles (Fig. 1, 2). The posterior segment could not be examined.

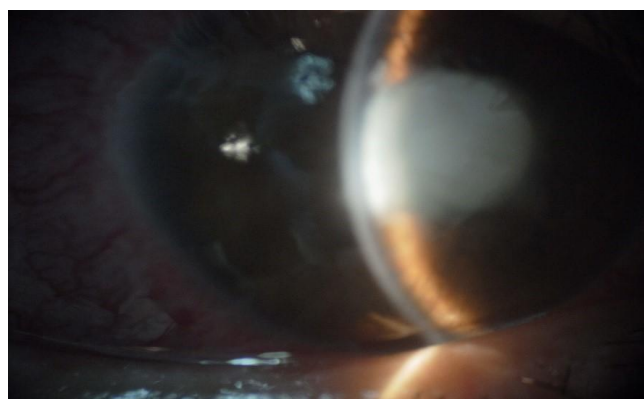


Figure 2: Anterior lens capsule rupture on slit examination

Left eye: Vision was low due to amblyopia and anterior polar cataract - 0,3/0,4 with +3,00 Dpt

Sph. /+8.00 Dpt from autorefractometer data/ (Fig. 3, 4). No other pathological findings were present.

The admitting ophthalmologist considered trauma or tumour of the right eye as a possible etiological factor at first. The performed CT - scan of the orbit showed no visible abnormalities. Before appointing additional examinations, the mother of the patient mentioned that he had been diagnosed with Alport syndrome in June 2014.




Figure 3: Anterior polar cataract on slit lamp examination of left eye

The mother had a complicated pregnancy with proteinuria and peripheral oedema. She had a C-section at 36 g.w. And the baby weighed 1700 g. He has been in an incubator for 1.5 months on O₂ therapy. The patient has normal intellectual and physical development at the moment. The first symptoms of the disease started at age 7, with proteinuria, hematuria and hearing loss. He was followed for two months, and no further investigations were made. After a seven-year period, he admitted again for proteinuria, hematuria, hypoproteinemia and hypocalcemia in January 2014. During his stay sensorineural deafness was diagnosed by an ENT specialist. The mother refused a renal biopsy to be performed at this time, but she agreed on June the same year. Alport syndrome was confirmed histologically. According to the records, no ophthalmological problems were found at the time.

The only medication the patient takes is Enalapril for his hypertension and proteinuria.

His ten-year-old sister also has hematuria and proteinuria, while his grandfather on the mother side is on haemodialysis because of glomerulonephritis.

Urine test showed the following results: +++ protein, a large number of granulocytes, hyalin and erythrocytes, lots of leucocytes, ketone bodies (-),

glucose (-), urobilinogen – not increased.

Blood test results showed: total protein - 49 g/l, albumin - 30 g/l, Urea - 6.5 mmol/l, creatinin -84, Na- 141 mmol/l, K – 4.0 mmol/l, Hgb -159, Ery – 5.29 x10¹²/L, Leu – 8.5 10⁹/L, Ptl -263 10⁹/L.

The patient was prepared for operation by lowering his IOP with Azopt 3 x 1 drops, Cusimolol 2 x 1 drops, Acetazolamide 2 x 250 mg, Glycerine 30% 1000 mg 3 x 3.4 spoons and anti-inflammatory therapy with Uniclophen 3 x 1 and Dextobrin 5 x 1 drops. IOP dropped to 37 mmHg after the therapy.

The operation was performed under general anaesthesia with unsatisfactory mydriasis. Side port and main incision were made, and the lens particles in the anterior chamber were evacuated with the bimanual irrigation-aspiration system (Geuder AG, Heidelberg, Germany) followed by aspiration of those left in the capsular sac. Due to the insufficient visualisation through the undilated iris and lack of proper capsulorhexis extraction through the rupture was arduous. After the pieces of the anterior capsule were sufficiently visualised a foldable acrylic IOL was placed in the remaining capsular sac.

On the next day, the IOP was 11.5 mmHg. The visual acuity was still low 0.1 with IOL in place. The cornea was mildly edematous, with the fibrinous membrane in the pupil which was medically dilated. There were lens particles in 12 and 1 o'clock.

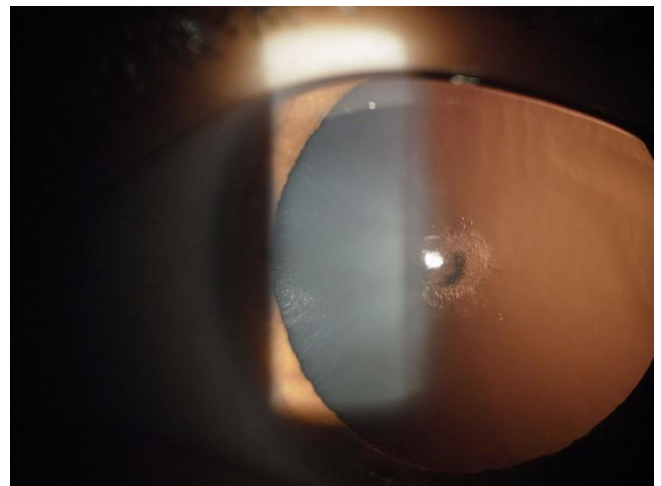


Figure 4: Anterior polar cataract on slit lamp examination of left eye on retroillumination

Potassium iodide 2 x 1, Oftaquix 5 x 1, Maxidex 5 x 1 and Yellox 3 x 1 drop were prescribed for home treatment. On the 10th-day control examination, visual acuity had improved – 0.4/0.5 suggesting this was his dominant eye before the incident and the fibrinous membrane almost completely resorbed. At day 30 visual acuity was 0.8 with 0.5 D cyl 90° with no remnants of lens particles or the fibrinous membrane. There were no visible changes of the fundus.

Discussion

Taking good care of a patient with Alport syndrome needs the interprofessional collaboration of nephrologists, ENT doctors and ophthalmologists. A timely consultation with an ophthalmologist needs to be considered every time a patient is diagnosed with the disease to avoid the wrong diagnosis of unexpected complications.

As the anterior cataract and lenticonus are a frequent ocular complication of Alport syndrome, the surgeon must keep in mind the fragile anterior capsule when trying to perform phacoaspiration.

Phacoaspiration and implantation of IOL can be successfully performed in patients with Alport syndrome with spontaneous and traumatic rupture.

References

1. Savige J, Colville D. Opinion: Ocular features aid the diagnosis of Alport syndrome. *Nat Rev Nephrol.* 2009; 5(6):356-60. <https://doi.org/10.1038/nrneph.2009.65> PMID:19474829
2. Choi Jh, Na Ks, Bae Sh, Roh Gh. Anterior lens capsule abnormalities in Alport syndrome. *Korean J Ophthalmol.* 2005; 19(1):84-9. <https://doi.org/10.3341/kjo.2005.19.1.84> PMID:15929494
3. Colville DJ, Savige J. Alport syndrome. A review of the ocular manifestations. *Ophthalmic Genet.* 1997;18(4):161-73. <https://doi.org/10.3109/13816819709041431> PMID:9457747
4. Olitsky SE, Waz WR, Wilson ME. Rupture of the anterior lens capsule in Alport syndrome. *J AAPOS.* 1999; 3(6):381-2. [https://doi.org/10.1016/S1091-8531\(99\)70051-0](https://doi.org/10.1016/S1091-8531(99)70051-0)
5. Heidet L, Gubler MC. [Alport syndrome: Hereditary nephropathy associated with mutations in genes coding for type IV collagen chains]. *Nephrol Ther.* 2016; 12(7):544-551. <https://doi.org/10.1016/j.nephro.2016.09.001> PMID:27816395
6. Jacobs M, Jeffrey B, Kriss A, Taylor D, Sa G, Barratt TM. Ophthalmologic assessment of young patients with Alport syndrome. *Ophthalmology.* 1992; 99(7):1039-44. [https://doi.org/10.1016/S0161-6420\(92\)31853-6](https://doi.org/10.1016/S0161-6420(92)31853-6)
7. Hentati N, Sellami D, Makni K, Kharrat M, Hachicha J, Hammadi A, Feki J. Ocular findings in Alport syndrome: 32 case studies. *J Fr Ophthalmol.* 2008;31(6 Pt 1):597-604. [https://doi.org/10.1016/S0181-5512\(08\)75461-5](https://doi.org/10.1016/S0181-5512(08)75461-5)
8. Mercé E, Korobelnik JF, Delyfer MN, Rougier MB. A new case of giant macular hole in a patient with Alport syndrome. *J Fr Ophthalmol.* 2012; 35(8):573-9. <https://doi.org/10.1016/j.jfo.2011.12.007> PMID:22695059
9. Pelit A, Oto S, Yilmaz G, Akova YA. Spontaneous rupture of the anterior lens capsule combined with macular hole in a child with Alport's syndrome. *J Pediatr Ophthalmol Strabismus.* 2004;41(1):59-61. PMID:14974838
10. Wilson ME Jr, Trivedi RH, Biber JM, Golub R. Anterior capsule rupture and subsequent cataract formation in Alport syndrome. *J Pediatr Ophthalmol Strabismus.* 2004;41(1):59-61.
11. Streeten BW, Robinson MR, Wallace R, Jones DB. Lens capsule abnormalities in Alport's syndrome. *Arch Ophthalmol.* 1987; 105(12):1693-7. <https://doi.org/10.1001/archophth.1987.01060120091033> PMID:3689194
12. Kato T, Watanabe Y, Nakayasu K, Kanai A, Yajima Y. The ultrastructure of the lens capsule abnormalities in Alport's syndrome. *J Ophthalmol.* 1998; 42(5):401-5. [https://doi.org/10.1016/S0021-5155\(98\)00031-8](https://doi.org/10.1016/S0021-5155(98)00031-8)
13. Citirik M, Batman C, Men G, Tuncel M, Zilelioglu O. Electron microscopic examination of the anterior lens capsule in a case of Alport's syndrome. *Clin Exp Ophtalm.* 2007; 90(5):367-70. <https://doi.org/10.1111/j.1444-0938.2007.00134.x> PMID:17697183