

Case Report

# Transanal Endoscopic-Assisted Pull-Through Colectomy for Children with High Intestinal Aganglionosis

Ulrike Metzger \*, Armin-Johannes Michel, Mircia-Aurel Ardelean and Roman Patrick Metzger

Department of Pediatric and Adolescent Surgery, Paracelsus Medical University Hospital, 5020 Salzburg, Austria; a.michel@salk.at (A.-J.M.); m.ardelean@salk.at (M.-A.A.); r.metzger@salk.at (R.P.M.)

\* Correspondence: u.metzger@salk.at

**Abstract:** Intestinal aganglionosis in children is a common cause of neonatal and infantile obstruction or ileus. Diagnosis is based on a histologically proven absence of enteric ganglion cells in deep biopsies of the gut wall. Therapeutic goal is a one-stage repair with a resection of the affected segment. The endorectal pull-through (ERP) can be performed entirely transanally in a lot of the cases. In patients with difficult preparation or a high aganglionosis ERP often needs to be assisted by laparoscopy or laparotomy. We present two cases with a technical modification performing a totally transanal pull-through colectomy without any trocars other than an umbilical camera trocar. The procedure starts with a classical endorectal technique. Usually, the transanal preparation is limited by reaching the colon descendens. A camera trocar is inserted and under laparoscopic vision the preparation is completed placing the instruments directly via the opened anus. After reaching the healthy colon segment, the pull-through is completed transanally. One of the main advantages of ERP is the sparing dissection. Our modification combines advantages of laparoscopy and ERP. The umbilical camera allows an excellent view while the instruments for dissection are used like with ERP without any further trocar or traction of the anal sphincter. The dispensation of any transanal trocar allows a higher grade of freedom in preparation and possibly a smaller trauma on the distal anal channel.

**Keywords:** intestinal aganglionosis; endoscopic assisted; endorectal pull-through; Hirschsprung's disease



**Citation:** Metzger, U.; Michel, A.-J.; Ardelean, M.-A.; Metzger, R.P. Transanal Endoscopic-Assisted Pull-Through Colectomy for Children with High Intestinal Aganglionosis. *Children* **2022**, *9*, 588. <https://doi.org/10.3390/children9050588>

Academic Editors: Robert Bergholz and Thomas Franz Krebs

Received: 20 February 2022

Accepted: 31 March 2022

Published: 21 April 2022

**Publisher's Note:** MDPI stays neutral with regard to jurisdictional claims in published maps and institutional affiliations.



**Copyright:** © 2022 by the authors. Licensee MDPI, Basel, Switzerland. This article is an open access article distributed under the terms and conditions of the Creative Commons Attribution (CC BY) license (<https://creativecommons.org/licenses/by/4.0/>).

## 1. Introduction

Intestinal aganglionosis, so called Hirschsprung's disease (HSCR), in children is a sporadic disease. About 1:5000 newborns in Europe shows this neural crest disease. Classically HSCR is diagnosed in the neonatal period. Symptoms include abdominal distension, vomiting and failure to pass meconium during the first day of life. HSCR needs to be excluded in neonatal and infantile obstruction of the gut and should be considered as a differential diagnosis in children with chronic constipation. About 80 percent of the children with diagnosed HSCR present with a so called "short aganglionosis", that involves solely the rectosigmoidal gut.

Associated malformations are quite common, 20 percent of the children show additional congenital anomalies. Genetic analysis may be necessary, particularly in patients with additional congenital abnormalities [1]. Diagnosis is based on rectal biopsies. There are limitations to visualize ganglion cells in neonates and premature infants. This should be considered, and biopsies might be repeated [1–7]. Additionally, most centers perform a contrast enema to identify the level of the transition zone, also accuracy of this technique is discussed on [8]. Anal manometry may also add information [9].

Preoperative management includes the applications of saline rectal irrigations to decompress the affected bowel. The early involvement of the parents in the application of the rectal irrigations as well as a nutritional counseling enables the parents and eases the long-term management of HSCR patients [1,4,5]. Since the beginning of the operative

management in the early 1940's, medical handling of this complex and rare disease gained a lot of improvement in the diagnosis and the surgical management. In nowadays a colostomy is rarely needed because of early diagnosis and consequent preoperative bowel management [6,10].

The surgical goal is a one-stage repair with resection of the affected segment, the transanal pull-through and an anastomosis in the anal canal. The most common techniques are transanal endorectal pull-through (ERP) with or without laparoscopic assistance and the Duhamel procedure. Both techniques show equal results in long-term continence outcomes and in the number of the most common complications like impairment of bowel function and enterocolitis [2,6,11–14]. Minimally invasive surgery has been used for intestinal aganglionosis since more than 20 years [14–16].

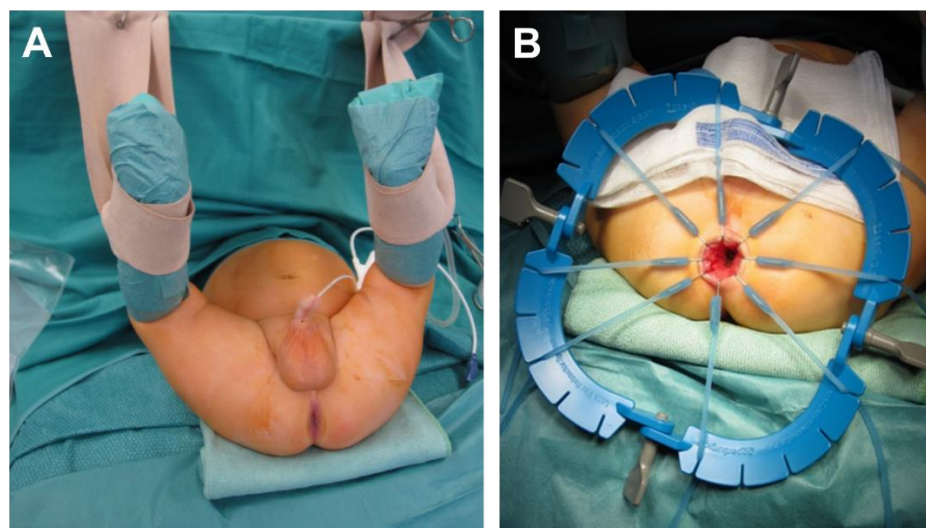
Since then, technical modifications of the classical laparoscopic approach like single trocar laparoscopic assisted pull-through (SILEP) ([17–22] or other laparoendoscopic single-site surgery (LESS) [22–25] and Natural Orifice Translumenal Endoscopic Surgery (NOTES) [25,26] have been published. In SILEP by now mostly a special designed port like the TriPort+™ is used, which allows to use a camera and at least two instruments via one trocar. For NOTES™ the use of cannulas through the muscular cuff [26] or an access through the sigmoid vascular pedicle can be found [27]. Combining NOTES™ and LESS Vadhad et al. describe the use of a TriPort+™ transanally [23–25].

The transanal pull-through as published by de La Torre is our preferred technique. In cases of difficult preparation or high-level transition zone we introduced a modified technique based on NOTES™.

## 2. Method

Usually in our department the classical de La Torre technique is performed.

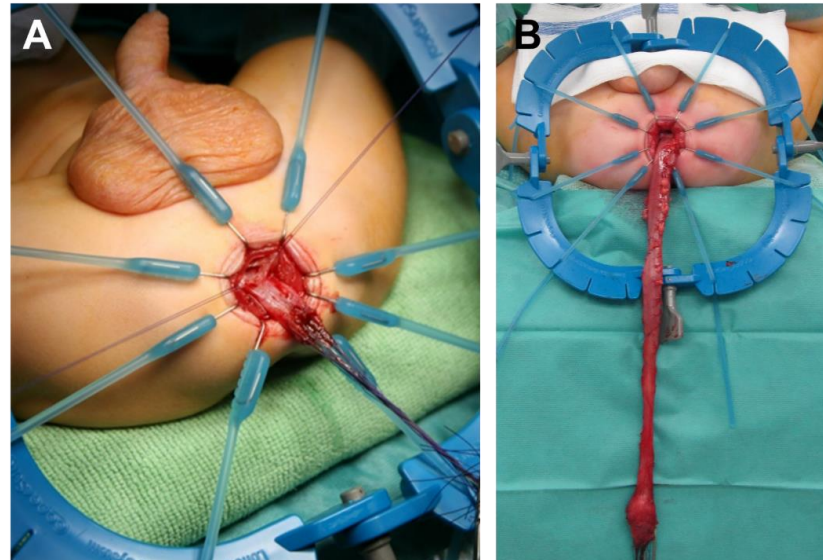
The patient is positioned in supine position with a slightly elevated pelvis. The anal canal is exposed using a lone star retractor. At 0.5 to 1.0 cm above the dentate line the rectal mucosa is incised circumferentially (Figure 1).



**Figure 1.** Setting of operation (A) and placement of the retractor (B), starting classical transanal pull-through.

Dissection of the rectal mucosa is performed with a long muscular cuff, up to the level of peritoneal reflection. Now the muscular cuff is divided entering the peritoneal cavity. When the free intraperitoneal plane is achieved, the muscular cuff is divided circumferentially, converting the submucosal dissection into a full-thickness dissection [28].

Incision of the posterior wall of the muscular cuff down to the cranial border of the anal sphincter muscle is carried out. The rectum is pulled down and the perirectal and perisigmoid dissection is advanced cranially (Figure 2).

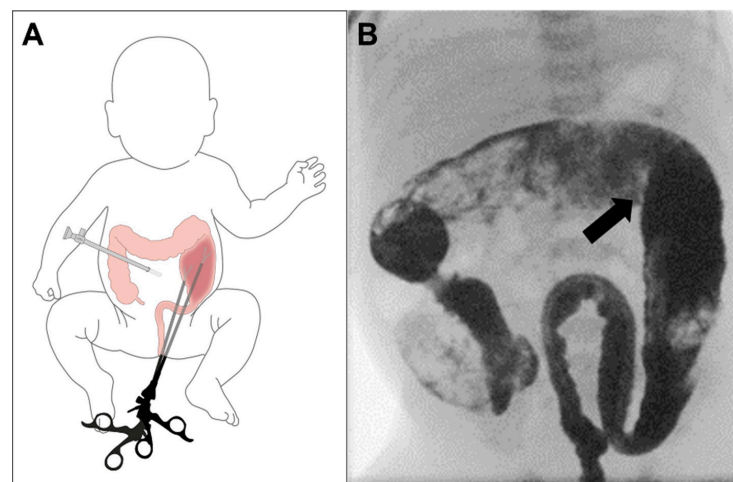


**Figure 2.** Submucosal preparation (A) and full-thickness dissection without entering the transition zone (B). This is continued until the transition zone is reached. Full-thickness frozen biopsies are taken immediately cranial to this segment to confirm ganglion cells.

Liberation of the normal colon is proceeded until it reaches the proposed anastomotic line without tension, followed by colectomy of the aganglionic segment. At the end anastomosis is accomplished in the anal canal [28].

In some cases of difficult preparation or a long aganglionic segment we expand the standard technique using our modification as follows:

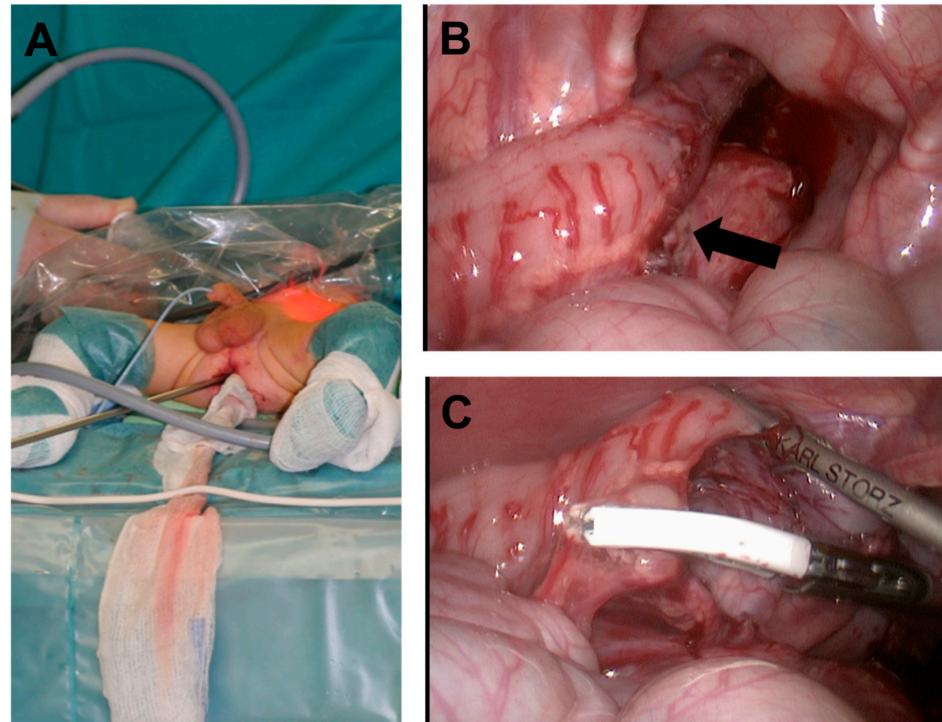
An umbilical camera trocar is inserted. Pneumoperitoneum is applied with 8 mmHg and a flow of 2 liters. This permits an excellent overview of the abdominal cavity. Then the laparoscopic instruments are inserted in the space between the resected colon and the muscular sleeve without any additional manipulation on the tissue (Figure 3).



**Figure 3.** An umbilical camera port is placed, and full-thickness dissection is continued by transanal instrumentation entering the transition zone (A). The preoperative abdominal X-ray shows the transition zone (arrow) at the left colonic flexure (B).

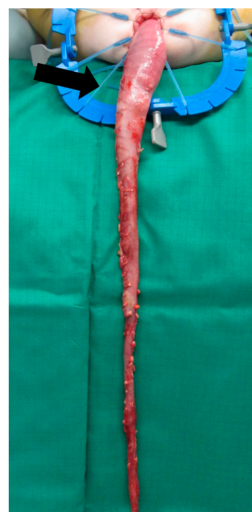

This allows to continue the mobilization in the right layer as described by de La Torre. We use 3- and 5-mm laparoscopic instruments. Instruments like a grasper, but also a 5 mm stapler (JustRight 5 mm stapler, Justright Surgical, LLC, Boulder, CO, USA) or the MiSeal™ (MiSeal™, model 452-131D; Microline, Beverly, MA, USA) are used. The MiSeal™ ensures dissection with minimal thermic harm to the surrounding tissue [29]. If necessary percutaneous application of a 3 mm grasper is possible. (Figure 4).



**Figure 4.** Umbilical camera port is placed, giving an excellent abdominal view (A). The transition zone (arrow) is visible now (B). Full-thickness dissection is continued by transanal instrumentation entering the transition zone (C).

Mobilization of the colon is continued as far as needed to reach the healthy segment. This segment is then freed using the excellent camera view to preserve the important vessels (Figure 5).



**Figure 5.** Mobilization of the colon is completed until the transition zone is developed transanally (arrow).

Performing the anal anastomosis, the camera allows the control of the correct positioning of the colon.

The postoperative management and follow up are performed according to the guidelines of ERNICA (European Reference Network for rare Inherited and Congenital (digestive and gastrointestinal) Anomalies) [1].

### 3. Results

#### 3.1. Case 1

The male newborn was transferred to us at age of 6 days with symptoms of an ileus. Clinical findings and plane radiography confirmed the suspected diagnosis of intestinal aganglionosis. Implementation of bowel management led to fast improvement. Intestinal aganglionosis was proven by repeated biopsies due to initial inconclusive histological findings. Contrast enema showed the suspected transition zone. The newborn was discharged after teaching bowel management to the parents. Informed consent was achieved including laparoscopic assisted pull-through or open surgery.

The transanal endoscopic assisted pull-through colectomy as described above was performed at the age of 5 months. Intraoperatively mobilization was done as far as visually identified transition zone, fresh frozen section biopsies were taken and revealed normal ganglionic colon at about sixty centimeters above the anus. Afterwards ano-descendostomy was conducted. Postoperative course was uncomplicated, and the child could be discharged after 12 days with regular stooling. Calibration started 3 weeks postoperatively and was ended with Charrière (Ch) 12 at about one year of age.

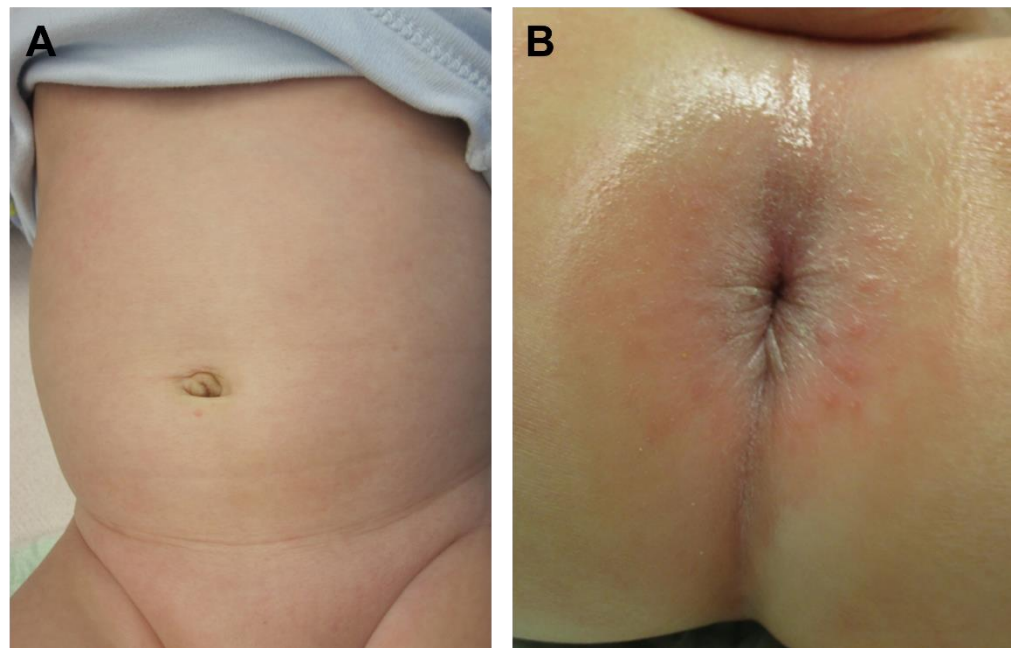
Follow up was performed regularly; this included the involvement of our gastrointestinal pediatricians, ultrasound, and nutritional counseling. By now the boy is 7.5 years old. His bowel function was always regular, and no complications occurred. Cosmetic results are excellent.

#### 3.2. Case 2

Another male newborn was transferred to us at age of 3 days with symptoms of an ileus, vomiting and insufficient meconium defecations. Clinical course was like case 1, after beginning of the bowel management fast improvement was reached and the newborn could be fed with breast milk. Intestinal aganglionosis was proven by biopsies. Also, in this patient contrast enema showed the suspected transition zone. The newborn was discharged after teaching of the bowel management to the parents.

The transanal endoscopic assisted pull-through colectomy was planned at the age of 3 months. Informed consent was achieved including laparoscopic assisted pull-through or open surgery. Normal ganglionic colon was reached at about forty-five centimeters above the anus. Postoperative course was uncomplicated, and the child could be discharged after 9 days with regular stooling. Calibration was started 3 weeks postoperatively and was realized until about one year of age with Ch 12 in the maximum.

Follow up of the now 4.5 years old boy was performed regularly, this included the involvement of our gastrointestinal pediatricians, ultrasound, and nutritional counseling. Bowel function was always regular, but the patient complained of flatulence and repeated soft stool. Intolerance of fructose was diagnosed. The patient is now free of symptoms under the implemented diet. Cosmetic results are excellent (Figure 6).



**Figure 6.** The cosmetic and functional outcome is excellent (A). The anal inspection is inconspicuous (B).

#### 4. Discussion

The positive effects as well as the limits of minimally invasive surgery in neonates and infants have been addressed in several papers [30–36]. One of the goals is to reduce the number of incisions for better cosmetics. But also, the length of hospital stays, the perioperative morbidity and the costs are affected positively, if the limitations of the minimal access are respected [30–36]. In repair of HSCR laparoscopic assisted pull-through is introduced since more than 20 years. The completely transanal performance of the pull-through as a modification of the SOAVE technique was first published in the late 1990s by de La Torre [28,37]. All minimal invasive techniques have been pushed forward and a lot of additionally ideas like SILEP or NOTES<sup>TM</sup> [22–26] have been published in short series or experimental studies. This extensive menu of surgical treatments all show nearly the same results in long term outcome as well as in hospital stay and complications [2,21,32,38].

The SILEP technique allows a laparoscopic assisted mobilization, it permits the surgeon to take biopsies at all needed levels. The affected bowel can be mobilized in nearly the same manner like in classical laparoscopic assisted ERP. It was described initially as an application of more than one trocar or additional instruments via the umbilicus, nowadays primary especially designed ports like TriPort+<sup>TM</sup> are used. Using an additional trocar is described as H-SILEP [22]. Main limitation is the angle of the instruments which is limited and results in a restriction of freedom of the instruments. The TriPort+<sup>TM</sup> is already quite big in diameter and usually needs incision beyond the navel, but also the application of more than one trocar in the umbilicus may result in traction stress to the tissue. Industrial modifications of the ports trying to solve the limit of the angles has resulted in even bigger ports, which are mostly not feasible for small patients. H-SILEP solves the problem of the angles while having an additional scar and the possibly disadvantages of another abdominal access. Reported results don't report any difference in the quality or complications compared to classical laparoscopic assisted approach with a benefit for [17–22].

The modifications using the anal channel with a port as described by Vahdad et al. is reported as a safe method. Access site complications are not reported in the short case series as well as in the performed animal study. The results reported in the case series are only followed up until six months postoperatively. Since functional problems may occur later in follow up there remains the concern, that the maximum stretch to the anal channel may results in an injury of the sphincter muscle [23–25].

Using cannulas applied through the muscular sleeve results in a direct injury of the distal sleeve. Since scarring is one of the complications of tissue injury, any additional impact on the distal sleeve should be avoided to prevent complications like constipation due to anastomotic narrowness [26]. Another reported case used NOTES<sup>TM</sup> with an access via the sigmoid vascular pedicle to perform the dissection. This injury of the sigma may result in bacterial translocation to the abdominal cavity and loss of pressure [27].

Main advantage of our modification is the same angle of the instruments likely to de La Torre procedure which allows a close dissection at the aganglionic colon and the release of the ganglionic colon with special focus on the feeding vessels. Additionally, the umbilical camera view adds an excellent abdominal overview and allows dissection with a different angle to the instruments. This enables a safe and high dissection of the colon and ensures a correct positioning of the colon while performing the anastomosis. At least by using the same access as in classical de La Torre procedure, we have no additional manipulation in the anastomotic region. Loss of pneumoperitoneum hasn't been a problem, since the intact already mobilized colon seals the pneumoperitoneum in the anal channel.

The modification is limited due to the length and angle of the laparoscopic instruments. This limits the scope from below and may lead to the necessity of additional instrumentation like in laparoscopic assisted transanal pull-through. However, conversion to conventional laparoscopic assisted transanal pull-through is easy to perform.

We regularly perform contrast enema in our patients preoperatively. The limited accuracy as published by Haikal, et al. [8] hasn't been a problem so far since our technique is easy to apply and easy to be converted. The healthy colon is always proven by Fresh frozen biopsies.

The Management of Hirschsprung's disease is a complex task which involves not only the pediatric surgeon but the whole center of pediatric health care including experts in histopathology and radiology. Repair is usually possible in a one stage operation. There is more than one comparable option for the surgical repair. As reported before, the main task is maximizing the quality of the performance of the surgical repair and minimizing its complications [38].

## 5. Conclusions

All published technical modifications didn't led to a change of the gold standard of operating high intestinal aganglionosis using laparoscopic assisted pull-through techniques.

Our modification emerged from the need of a higher, but still safe dissection while being convinced that the technique of de La Torre is preferable. One of the main advantages of his technique is the dissection as near as possible to the affected bowel. The classical laparoscopic approaches as well as the techniques using an additional abdominal approach for dissection lack this possibility. On the other side, abdominal overview is best using an umbilical camera trocar. The combination of laparoscopic instruments and the different camera angle results in a technique which allows a lot of freedom for the instruments while keeping a perfect overview of the operated area. The technique is easy to schedule since regular laparoscopic instruments and a plain camera trocar are used. But this technique depends on a high expertise not only in the classically transanal pull-through technique but also in laparoscopic techniques. Also, there might be the need to select patients due to the possible feasibility. This wasn't needed in our cases since all patients undergo ERP as first line treatment. If dissection cannot be performed easily and free of tension, our technical modification is applied. This could be performed in two patients without any intra- or postoperative complications or the need to convert to standard laparoscopic technique. The presented two boys have excellent cosmetic results and a normal bowel movement with an unsuspecting anastomotic region in ultrasound after more than 4 respectively more than 7 years.

The modified technique therefore seems to be a feasible additional tool for transanal pull-through of de La Torre allowing highest quality in dissection at least until the transverse colon. Anyhow further research needs to be done in this to prove safety and feasibility.



**Author Contributions:** All authors have read and agreed to the published version of the manuscript.

**Funding:** This research received no external funding.

**Informed Consent Statement:** Written informed consent has been obtained from the patient(s) to publish this paper.

**Conflicts of Interest:** The authors declare no conflict of interest.

## References

1. Kyrklund, K.; Sloots, C.E.; de Blaauw, I.; Bjørnland, K.; Rolle, U.; Cavalieri, D.; Francalanci, P.; Fusaro, F.; Lemli, A.; Schwarzer, N.; et al. ERNICA guidelines for the management of rectosigmoid Hirschsprung's disease. *Orphanet J. Rare Dis.* **2020**, *15*, 164. [[CrossRef](#)] [[PubMed](#)]
2. Zani, A.; Eaton, S.; Morini, F.; Puri, P.; Rintala, R.; Van Heurn, E.; Lukac, M.; Bagolan, P.; Kuebler, J.F.; Friedmacher, F. European Paediatric Surgeons' Association Survey on the Management of Hirschsprung Disease. *Eur. J. Pediatric Surg.* **2017**, *27*, 96–101. [[CrossRef](#)] [[PubMed](#)]
3. Reding, R.; De Goyet, J.D.V.; Gosseye, S.; Clapuyt, P.; Sokal, E.; Buts, J.P.; Gibbs, P.; Otte, J.B. Hirschsprung's disease: A 20-year experience. *J. Pediatric Surg.* **1997**, *32*, 1221–1225. [[CrossRef](#)]
4. Metzger, R. Morbus Hirschsprung. *Mon. Kinderheilkd.* **2017**, *165*, 347–362. [[CrossRef](#)]
5. Heuckeroth, R.O. Hirschsprung disease—Integrating basic science and clinical medicine to improve outcomes. *Nat. Rev. Gastroenterol. Hepatol.* **2018**, *15*, 152–167. [[CrossRef](#)]
6. Haricharan, R.N.; Georgeson, K.E. Hirschsprung disease. *Semin. Pediatric Surg.* **2008**, *17*, 266–275. [[CrossRef](#)]
7. Das, K.; Mohanty, S. Hirschsprung Disease—Current Diagnosis and Management. *Indian J. Pediatrics* **2017**, *84*, 618–623. [[CrossRef](#)]
8. Haikal, Z.; Dwihantoro, A.; Gunarti, H.; Gunadi. Accuracy of transition zone in contrast enema to predict intraoperative aganglionosis level in patients with Hirschsprung disease. *BMC Res. Notes.* **2020**, *13*, 104. [[CrossRef](#)]
9. Till, H.; Heinrich, M.; Schuster, T.; V Schweinitz, D. Is the anorectal sphincter damaged during a transanal endorectal pull-through (TERPT) for Hirschsprung's disease? A 3-dimensional, vector manometric investigation. *Eur. J. Pediatric Surg.* **2006**, *16*, 188–191. [[CrossRef](#)]
10. Teitelbaum, D.H.; Coran, A.G. Hirschsprung disease. In *Operative Pediatric Surgery*, 7th ed.; Spitz, L.W., Coran, A.G., Teitelbaum, D.H., Eds.; CRC Press: Boca Raton, FL, USA, 2013; pp. 549–572.
11. El-Sawaf, M.I.; Drongowski, R.A.; Chamberlain, J.N.; Coran, A.G.; Teitelbaum, D.H. Are the long-term results of the transanal pull-through equal to those of the transabdominal pull-through? A comparison of the 2 approaches for Hirschsprung disease. *J. Pediatric Surg.* **2007**, *42*, 41–47; discussion 47. [[CrossRef](#)]
12. Nasr, A.; Haricharan, R.N.; Gamarnik, J.; Langer, J.C. Transanal pullthrough for Hirschsprung disease: Matched case-control comparison of Soave and Swenson techniques. *J. Pediatric Surg.* **2014**, *49*, 774–776. [[CrossRef](#)]
13. Sapin, E.; Centonze, A.; Moog, R.; Borgnon, J.; Becmeur, F. Transanal coloanal anastomosis for Hirschsprung's disease: Comparison between endorectal and perirectal pull-through procedures. *Eur. J. Pediatric Surg.* **2006**, *16*, 312–317. [[CrossRef](#)]
14. Tang, S.T.; Wang, G.B.; Cao, G.Q.; Wang, Y.; Mao, Y.Z.; Li, S.; Yang, Y.; Yang, J.; Yang, L. 10 years of experience with laparoscopic-assisted endorectal Soave pull-through. *J. Laparoendosc. Adv. Surg. Tech.* **2012**, *22*, 280–284. [[CrossRef](#)]
15. Georgeson, K.E.; Robertson, D.J. Laparoscopic-assisted approaches for the definitive surgery for Hirschsprung's disease. *Semin. Pediatric Surg.* **2004**, *13*, 256–262. [[CrossRef](#)]
16. Ishihara, M.; Yamataka, A.; Kaneyama, K.; Koga, H.; Kobayashi, H.; Lane, G.J.; Miyano, T. Prospective analysis of primary modified Georgeson's laparoscopy-assisted endorectal pull-through for Hirschsprung's disease: Short- to mid-term results. *Pediatr Surg Int.* **2005**, *21*, 878–882. [[CrossRef](#)]
17. Aubdoollah, T.H.; Tang, S.-T.; Yang, L.; Li, S.; Lei, H.-Y.; Zhang, X. Hybrid Single-Incision Laparoscopic Approaches for Endorectal Pull-Through in Hirschsprung's Disease. *J. Laparoendosc. Adv. Surg. Tech. Part A* **2015**, *25*, 595–598. [[CrossRef](#)]
18. Muensterer, O.J.; Chong, A.; Hansen, E.N.; Georgeson, K.E. Single-incision laparoscopic endorectal pull-through (SILEP) for Hirschsprung disease. *J. Gastrointest. Surg. Off. J. Soc. Surg. Aliment. Tract* **2010**, *14*, 1950–1954. [[CrossRef](#)]
19. Nguyen, L.T.; Nguyen, A.T.; Nguyen, Q.T.; Tran, Q.A.; Bui, H.D.; Pham, H.D. Suspension sutures facilitate single-incision laparoscopic-assisted rectal pull-through for Hirschsprung disease. *BMC Surg.* **2021**, *21*, 274. [[CrossRef](#)]
20. Rothenberg, S.S.; Shipman, K.; Yoder, S. Experience with modified single-port laparoscopic procedures in children. *J. Laparoendosc. Adv. Surg. Tech.* **2009**, *19*, 695–698. [[CrossRef](#)]
21. Tang, S.T.; Yang, Y.; Li, S.W.; Cao, G.Q.; Yang, L.; Huang, X.; Shuai, L.; Wang, G.-B. Single-incision laparoscopic versus conventional laparoscopic endorectal pull-through for Hirschsprung's disease: A comparison of short-term surgical results. *J. Pediatric Surg.* **2013**, *48*, 1919–1923. [[CrossRef](#)]
22. Aubdoollah, T.H.; Li, K.; Zhang, X.; Li, S.; Yang, L.; Lei, H.-Y.; Dolo, P.R.; Xiang, X.-C.; Cao, G.-Q.; Wang, G.-B.; et al. Clinical outcomes and ergonomics analysis of three laparoscopic techniques for Hirschsprung's disease. *World J. Gastroenterol.* **2015**, *21*, 8903–8911. [[CrossRef](#)]



23. Vahdad, M.R.; Cernaianu, G.; Semaan, A.; Klein, T.; Faran, S.; Zemon, H.; Boemers, T.; Foroutan, H.R. An experimental study in six fresh human cadavers using a novel approach to avoid abdominal wall incisions in total colectomy: Totally transanal laparoendoscopic single-site pull-through colectomy with J-pouch creation. *Surg. Endosc.* **2016**, *30*, 3107–3113. [[CrossRef](#)]
24. Vahdad, M.R.; Foroutan, A.; Najafi, S.M.; Cernaianu, G.; Tröbs, R.B.; Banani, S.A.; Foroutan, H.R. Totally transanal LESS pull-through colectomy: A novel approach for avoiding abdominal wall incision in children with long-segment intestinal aganglionosis. *J. Laparoendosc. Adv. Surg. Tech. Part A* **2013**, *23*, 276–280. [[CrossRef](#)]
25. Vahdad, M.R.; Rahmanian, E.; Moslemi, S.; Najafi, S.M.; Foroutan, H.R. Totally Transanal Laparo-Endoscopic Single-Site ProctoColectomy-Ileoanal J-Pouch (TLPC-J): An Experimental Study of a Novel Approach. *Iran. J. Med. Sci.* **2015**, *40*, 425–429.
26. Li, N.; Zhang, W.; Yu, D.; Sun, X.; Wei, M.; Weng, Y.; Feng, J. Notes for surgical treatment of long-segment Hirschsprung's disease: Report of three cases. *J. Laparoendosc. Adv. Surg. Tech. Part A* **2013**, *23*, 1020–1023. [[CrossRef](#)]
27. Velhote, M.C.P.; Velhote, C.E.P. A NOTES modification of the transanal pull-through. *J. Laparoendosc. Adv. Surg. Tech. Part A* **2009**, *19*, 255–257. [[CrossRef](#)]
28. De la Torre-Mondragon, L.; Ortega-Salgado, J.A. Transanal endorectal pull-through for Hirschsprung's disease. *J. Pediatric Surg.* **1998**, *33*, 1283–1286. [[CrossRef](#)]
29. Pogorelić, Z.; Katić, J.; Mrklič, I.; Jerončić, A.; Šušnjar, T.; Jukić, M.; Vilović, K.; Perko, Z. Lateral thermal damage of mesoappendix and appendiceal base during laparoscopic appendectomy in children: Comparison of the harmonic scalpel (Ultracision), bipolar coagulation (LigaSure), and thermal fusion technology (MiSeal). *J. Surg. Res.* **2017**, *212*, 101–107. [[CrossRef](#)]
30. Al-Qahtani, A.R.; Almaramhi, H. Minimal access surgery in neonates and infants. *J. Pediatric Surg.* **2006**, *41*, 910–913. [[CrossRef](#)]
31. Harres, A.E. Minimally invasive neonatal surgery. *J. Perinat. Neonat. Nurs.* **2007**, *21*, 39–49. [[CrossRef](#)]
32. Iacusso, C.; Leonelli, L.; Valfrè, L.; Conforti, A.; Fusaro, F.; Iacobelli, B.D.; Bozza, P.; Morini, F.; Mattioli, G.; Bagolan, P. Minimally Invasive Techniques for Hirschsprung Disease. *J. Laparoendosc. Adv. Surg. Tech.* **2019**, *29*, 1605–1608. [[CrossRef](#)] [[PubMed](#)]
33. Lacher, M.; Kuebler, J.F.; Dingemann, J.; Ure, B.M. Minimal invasive surgery in the newborn: Current status and evidence. *Semin. Pediatric Surg.* **2014**, *23*, 249–256. [[CrossRef](#)] [[PubMed](#)]
34. Metzelder, M.L.; Ure, B.M. Minimal-invasive Kinderchirurgie. *Der Chirurg* **2010**, *81*, 71–80; quiz 81–82. [[CrossRef](#)] [[PubMed](#)]
35. Yamataka, A.; Miyano, G.; Takeda, M. Minimally Invasive Neonatal Surgery: Hirschsprung Disease. *Clin. Perinatol.* **2017**, *44*, 851–864. [[CrossRef](#)]
36. Zitsman, J.L. Pediatric minimal-access surgery: Update 2006. *Pediatrics* **2006**, *118*, 304–308. [[CrossRef](#)]
37. De La Torre, L.; Langer, J.C. Transanal endorectal pull-through for Hirschsprung disease: Technique, controversies, pearls, pitfalls, and an organized approach to the management of postoperative obstructive symptoms. *Semin. Pediatric Surg.* **2010**, *19*, 96–106. [[CrossRef](#)]
38. Nah, S.A.; de Coppi, P.; Kiely, E.M.; Curry, J.I.; Drake, D.P.; Cross, K.; Spitz, L.; Eaton, S.; Pierro, A. Duhamel pull-through for Hirschsprung disease: A comparison of open and laparoscopic techniques. *J. Pediatric Surg.* **2012**, *47*, 308–312. [[CrossRef](#)]
39. De La Torre, L.; Wehrli, L.A. Error traps and culture of safety in Hirschsprung disease. *Semin. Pediatric Surg.* **2019**, *28*, 151–159. [[CrossRef](#)]