

# Acute progression of electrophysiologically affected fellow eye in unilaterally symptomatic acute zonal occult outer retinopathy

Kayo Kure  
Ryo Obata  
Yuji Inoue  
Aya Iriyama  
Yasuo Yanagi

Department of Ophthalmology,  
University of Tokyo School  
of Medicine, Tokyo, Japan

**Abstract:** Some patients with acute zonal occult outer retinopathy (AZOOR) show symptomatic acute visual impairment in one eye only, but electrophysiological abnormalities in both eyes. A 46-year-old female who had noticed paracentral scotoma of her right eye six months previously was referred to our hospital. At initial examination, her best-corrected visual acuity was 0.7 in the right eye and 1.2 in the left. Whereas the full-field rod electroretinogram (ERG) was normal in both eyes, the cone response was nonrecordable in the right eye and showed a significant decrease in amplitude in the left eye. The 30 Hz flicker ERG showed similar results. Multifocal ERG was nonrecordable in the right eye and showed a residual response in only the central part of the left. Fourteen months after the first visit, the patient presented complaining of acute visual acuity loss in the left eye. Visual acuity in her left eye had decreased to 0.01. The multifocal ERG was nonrecordable. Although the patient chose oral prednisolone therapy, only limited recovery was observed in the patient. Even if only the ERG shows changes and there are no other symptoms, ophthalmologists should continue observation in view of the possibility of an acute exacerbation.

**Keywords:** acute zonal occult outer retinopathy, electroretinogram, scotoma

## Introduction

Acute zonal occult outer retinopathy (AZOOR) is a syndrome characterized by rapid loss of one or more zones of outer retinal function.<sup>1</sup> Patients are predominantly young women and frequently present with photopsia and visual field defects. Electrophysiological testing is useful for diagnosis. Some patients with AZOOR show symptomatic acute visual impairment in one eye, but electrophysiological abnormalities in both eyes.<sup>2,3</sup> However, to the best of the authors' knowledge, there have been no follow-up reports of the electrophysiologically affected asymptomatic eye, and it is not well established whether the functionally affected eye will progress and the patient will develop clinical symptoms.

## Case report

A 46-year-old female who had noticed paracentral scotoma of her right eye six months previously was referred to our hospital. At initial examination, her best-corrected visual acuity was 0.7 in the right eye and 1.2 in the left. Intraocular pressure, anterior segment, ocular media and fundus, including fluorescein angiographic examination showed no abnormalities (Figure 1). The cone response was nonrecordable in the right eye and showed a significant decrease in amplitude in the left eye. The 30 Hz flicker ERG showed similar results, and the maximal response was abnormal, with

Correspondence: Yasuo Yanagi  
Department of Ophthalmology,  
University of Tokyo School of  
Medicine, 7-3-1 Hongo, Bunkyo-ku,  
Tokyo 113-8655, Japan  
Tel +813 5800 8660  
Fax +813 3817 0798  
Email yanagi-tky@umin.ac.jp

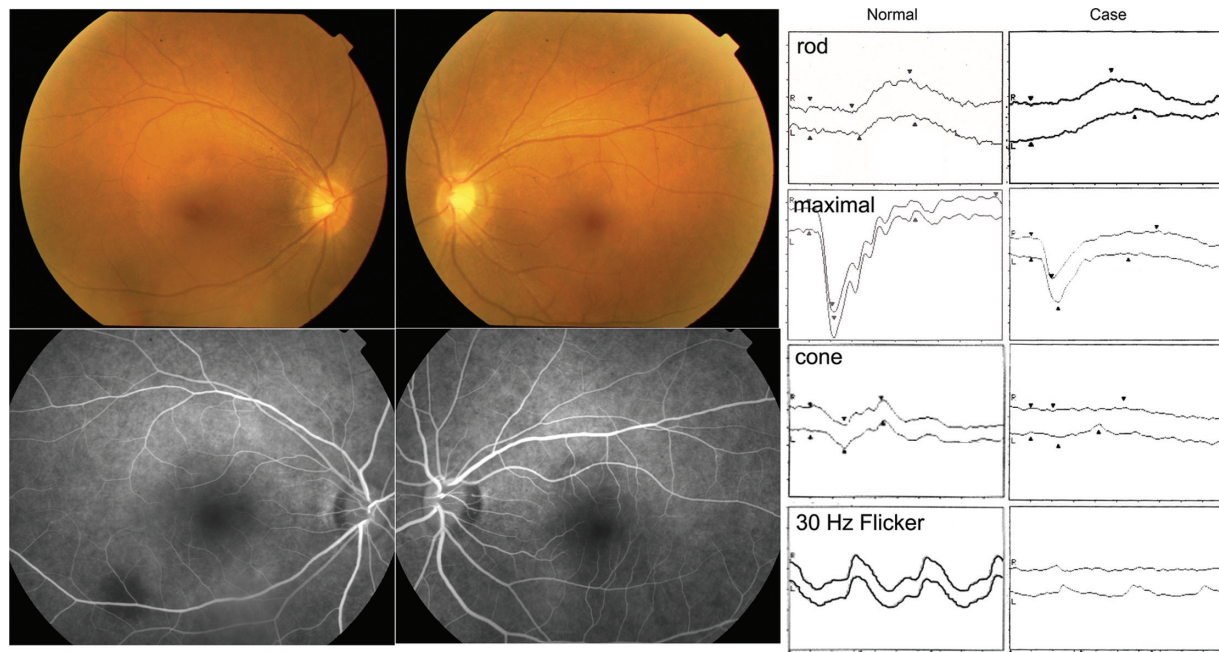


Figure 1 Fundus photograph and fluorescein angiography appears normal (left panels). Electroretinogram shows marked loss of cone function in both eyes (right panels).

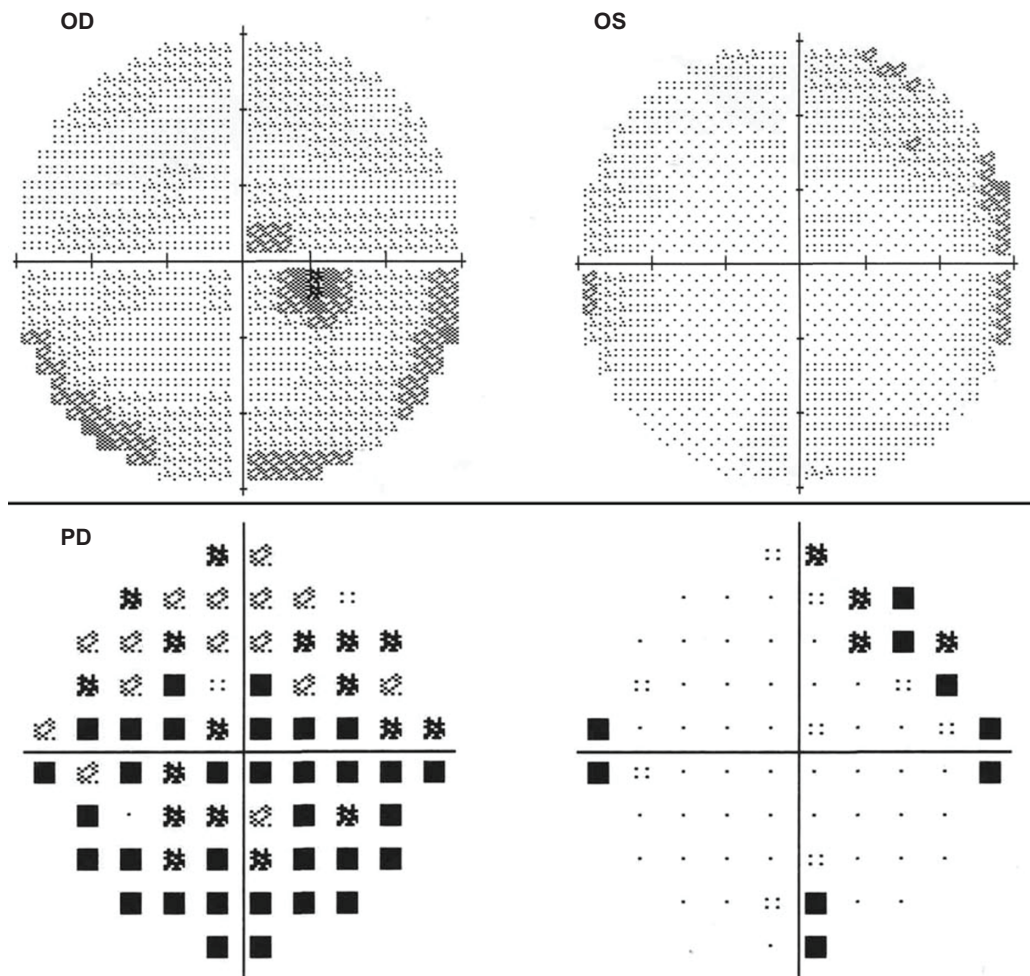
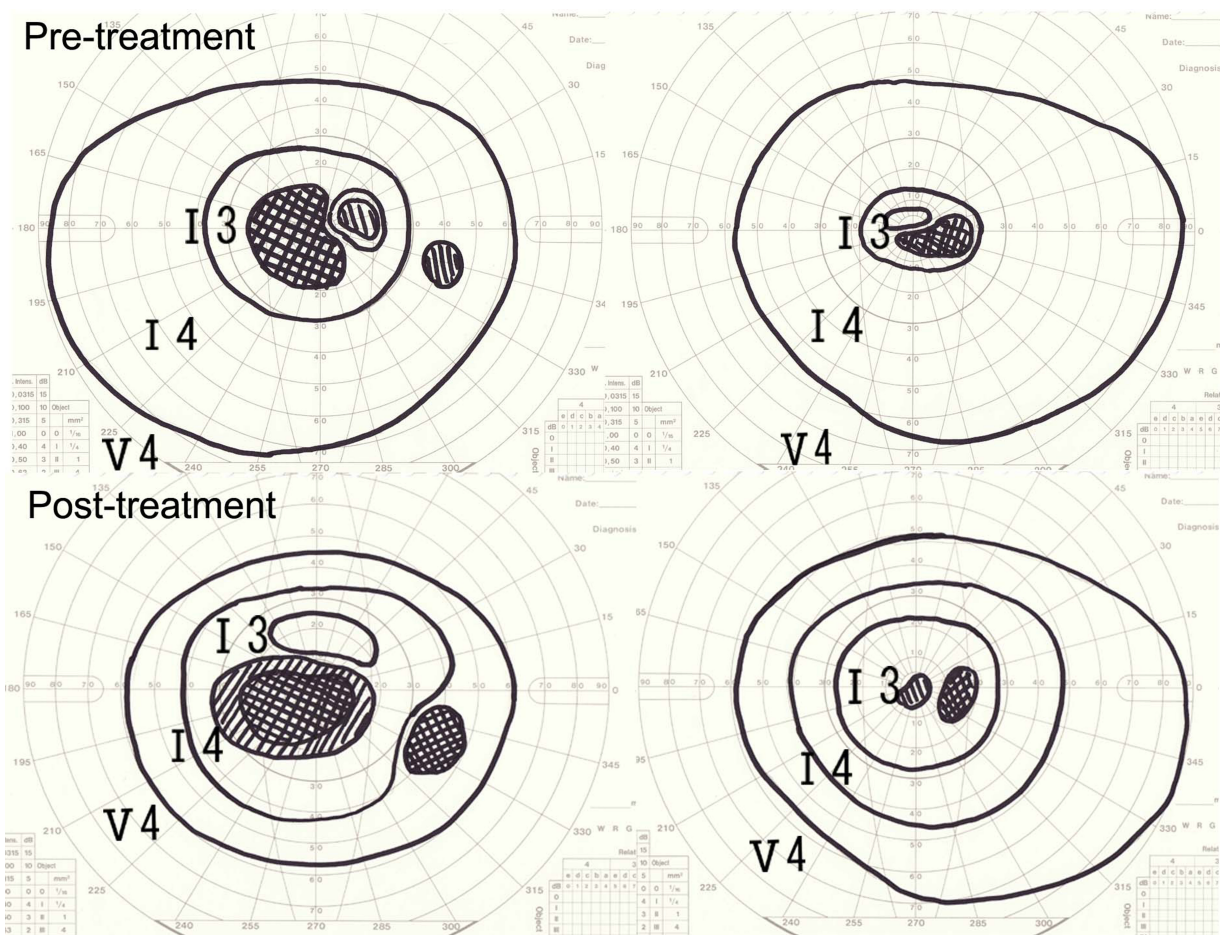


Figure 2 Static perimetry (full threshold 10-2 Humphrey visual field examination) shows central scotoma of right eye.



**Figure 3** Fifteen months after initial visit. Goldmann perimetry showed limited recovery after oral prednisolone administration.

reduced a-wave and b-wave amplitudes as well as oscillatory potentials (Figure 1). Multifocal ERG was nonrecordable in the right eye and showed a residual response only in the central part of the left. Static perimetry (full threshold 10-2 Humphrey visual field examination) showed relative central scotoma of the right eye (Figure 2). The clinical findings were compatible with a diagnosis of AZOOR,<sup>1</sup> and careful observation was recommended.

Fourteen months after the first visit, the patient presented complaining of acute visual acuity loss in the left eye. Visual acuity in her left eye had decreased to 0.01, while the right eye was 0.7. A full-field ERG showed cone function impairment. The residual response in the multifocal ERG in the central part was nonrecordable. The patient was informed that there is no established treatment for AZOOR and that oral prednisolone has been tested with moderate efficacy according to case reports.<sup>2</sup> The patient opted for oral prednisolone therapy 30 mg daily. One month thereafter, limited recovery was observed in the patient as revealed by Goldmann perimetry (Figure 3).

## Discussion

Gass et al<sup>2</sup> and Francis et al<sup>3</sup> reported that AZOOR was present in one eye in 61% and 46% cases, respectively, at the first visit, 61% and 14% of patients with unilateral AZOOR subsequently developed symptoms suggestive of AZOOR in the fellow eye, and electrophysiological abnormalities were observed in both eyes in 25% and 18% of patients at their first visit, respectively. However, there was no mention of whether such patients subsequently developed clinical symptoms. In the current case, there was a discrepancy in the results between the ERG and static visual field testing in the left eye at initial presentation. It is possible that kinetic visual field testing could have revealed a visual field abnormality at the initial visit. As this case report shows, when a patient is diagnosed with AZOOR, it should be determined whether AZOOR is unilateral or bilateral in consideration of ERG results. Even if only the ERG shows changes and there are no other symptoms, ophthalmologists should continue observation in view of the possibility of an acute exacerbation.



## Disclosure

The authors report no conflicts of interest in this work.

## References

1. Gass JD. *Stereoscopic Atlas of Macular Diseases: Diagnosis and Treatment*. 4th ed. St. Louis, MO: Mosby; 1996.
2. Gass JD, Agarwal A, Scott IU. Acute zonal occult outer retinopathy: a long-term follow-up study. *Am J Ophthalmol*. 2002;134:329–339.
3. Francis PJ, Marinescu A, Fitzke FW, Bird AC, Holder GE. Acute zonal occult outer retinopathy: towards a set of diagnostic criteria. *Br J Ophthalmol*. 2005;89:70–73.

### Clinical Ophthalmology

Dovepress

### Publish your work in this journal

Clinical Ophthalmology is an international, peer-reviewed journal covering all subspecialties within ophthalmology. Key topics include: Optometry; Visual science; Pharmacology and drug therapy in eye diseases; Basic Sciences; Primary and Secondary eye care; Patient Safety and Quality of Care Improvements. This journal is indexed on

Submit your manuscript here: <http://www.dovepress.com/clinical-ophthalmology-journal>

PubMed Central and CAS, and is the official journal of The Society of Clinical Ophthalmology (SCO). The manuscript management system is completely online and includes a very quick and fair peer-review system, which is all easy to use. Visit <http://www.dovepress.com/testimonials.php> to read real quotes from published authors.