

# On Postoperative Day Balloon Angioplasty for Salvage of Newly-Placed, Flow-Limiting Native Arteriovenous Fistula

Jae Young Park and Chang Hyun Yoo

Busan Vascular Clinic, Busan, Korea

**Purpose:** To report result and usefulness of immediate postoperative balloon angioplasty of de novo arteriovenous fistula (AVF) with limited flow just after creation.

**Materials and Methods:** From January 1, 2012 to March 31, 2014, 1,270 patients received native AVF creations in a single vascular clinic. In twenty-four patients (1.9% of total AVF creation), immediate postoperative balloon angioplasty was performed because of limited flow on palpation (only pulsation or no thrill) just after AVF creation. Medical records were reviewed retrospectively; technical success (restoration of AVF flow)/clinical success (growing as functional AVF) rate, maturation time, primary patency rate and fistula survival outcome were analyzed during a mean 10.8 months of follow-up.

**Results:** Technical/clinical success rate was 95.8% (23/24 cases); AVF flow was restored after balloon angioplasty, and all the flow-restored AVFs grew as functional AVFs with mean±standard deviation, 4.5±1.5 weeks of maturation time. In seven (30.4%) patients, a secondary balloon angioplasty was needed to enhance maturation. The overall primary patency after immediate postoperative balloon angioplasty was 69.6% at 1 and 6 months and 59.0% at 12 months. There was 1 complication (operation site hematoma).

**Conclusion:** Immediate postoperative balloon angioplasty for salvage of newly-placed, flow-limiting native AVF is a useful, effective and safe procedure.

**Key Words:** Arteriovenous fistula, Angioplasty, Vascular patency

Received February 11, 2015

Revised March 2, 2015

Accepted March 9, 2015

**Corresponding author:** Chang Hyun Yoo  
Busan Vascular Clinic, 402, 4th Floor,  
Trump World Centum, 9 Centum dong-  
ro, Haeundae-gu, Busan, Korea  
Tel: 82-51-747-0400  
Fax: 82-51-747-7090  
E-mail: microsurgical@yahoo.com  
Conflict of interest: None.

This article was presented at the congress of  
Asian Society for Vascular Surgery 2014.

Copyright © 2015, The Korean Society for Vascular Surgery

This is an Open Access article distributed under the terms of the Creative Commons Attribution Non-Commercial License (<http://creativecommons.org/licenses/by-nc/3.0>) which permits unrestricted non-commercial use, distribution, and reproduction in any medium, provided the original work is properly cited.

Vasc Spec Int 2015;31(1):20-24 • <http://dx.doi.org/10.5758/vsi.2015.31.1.20>

## INTRODUCTION

Native arteriovenous fistula (AVF) is recommended as a first AV access in end stage renal disease patients who need hemodialysis [1]. Many reports have shown variable postoperative results [2,3], and early failure rates are considerable in some reports [4,5]. Postoperative palpable thrill suggests successful native AVF creation [6] and practitioners wait several weeks for maturation to occur.

However in some cases, postoperative thrill may be very weak or absent, with or without pulsation. In this case, the operator chooses one of following methods. First, reopen the wound and explore the created AVF. Second, wait several days with no further manipulation. Third, create a new AVF proximally or at the other arm. Fourth, perform angiography and immediate postoperative balloon angioplasty (IPBA); the latter is a less commonly used method that we would like to mention in this paper.

We reviewed cases of IPBA which was performed when postoperative AVF flow was threatened (newly-created AVF with no thrill) and effectiveness, safety and usefulness of IPBA were evaluated.

## MATERIALS AND METHODS

From January 1, 2012 to March 31, 2014, 1,270 patients received autogenous AVF creations in a single vascular clinic. Among these patients, 24 patients (24/1,270 patients, 1.9%) were selected retrospectively who underwent IPBA after AVF creation and had a follow-up period of more than 3 months.

Arm veins and arteries were examined by physical examination and duplex scan preoperatively. In 24 patients, postoperative AVF flow was poor even with preoperative tests. If newly-created AVF flow did not get better by physical examination after 30 minutes of observation, we checked the operation site with direct angiography and IPBA was done. IPBA was initiated with puncture of the distal artery from the anastomosis. In every case, a 5-French sheath was inserted. We checked for flow-limiting lesions (significant stenosis over 60% by angiography) and the lesions were ballooned. Flow restoration was confirmed by palpation with or without duplex scan. After IPBA, we checked the AV access maturation with regular surveillance; 2, 4, 8 and every 12 weeks. If needed, secondary balloon angioplasty was done to enhance access maturation.

Technical success was defined as restoration of AVF flow; meaning the presence of good thrill with relieved stenosis after ballooning during angiography. Clinical success was defined as successful maturation of the flow-limiting, newly-created native AVF to become functional for use during hemodialysis after several weeks of maturation time. Maturation time refers to the required time from native AVF formation to first use as access for hemodialysis. Primary patency rate and fistula survival outcome were

**Table 1.** Patient characteristics (total number of patient=24)

Characteristic	Value
Age (y)	62.0±12.7
Gender (male:female)	15:9
Location of access	
Wrist	16 (66.7)
Forearm	4 (16.7)
Elbow	4 (16.7)
Anastomosis type	
Radiocephalic	20 (83.3)
Brachiocephalic	4 (16.7)

Values are presented as mean±standard deviation or number (%).

analyzed during the follow-up period. IBM SPSS Statistics 19.0 (IBM Co., Armonk, NY, USA) was used for statistical analysis.

## RESULTS

In 24 cases of IPBA, most of the initial operations were wrist or forearm radiocephalic AVFs (Table 1). In preoperative duplex scan, vein diameters were less than 2.5 mm in 62.5% and artery diameters were less than 2 mm in 62.5% of the cases (Table 2). Postoperative angiography was performed via wrist radial artery puncture, except in 1 case of elbow brachial artery puncture. Most of the flow-limiting lesions were vein stenoses and plain balloon catheters with 4 mm diameter were used in 66.7% (16/24) of the patients.

Threatened AVF flow was restored successfully in 23 patients, except in 1 case of guide-wiring passage failure (23/24 patients, 95.8% of technical success rate). In the single failed case, proximal re-anastomosis was done. In 23 patients with successful IPBA, all AVFs matured to functional AVFs with mean±standard deviation, 4.5±1.5 weeks of maturation time. In seven patients (7/23 patients, 30.4%), secondary balloon angioplasty was performed to enhance maturation (Table 3).

The overall primary patency after IPBA was 69.6% at 1 and 6 months and 59.0% at 12 months (Fig. 1). There was 1 case of operation site hematoma after immediate

**Table 2.** Vessel characteristics (total number of patient=24)

Characteristic	Value
Vein diameter (mm) <sup>a</sup>	
≥2.5	9 (37.6)
1.5-2.5	11 (45.8)
<1.5	4 (16.7)
Artery diameter (mm) <sup>a</sup>	
≥2.5	9 (37.6)
1.5-2.5	14 (58.3)
<1.5	1 (4.2)
Location of flow-limiting lesion <sup>b</sup>	
Vein, only	19 (79.2)
Artery, only	3 (12.5)
Combined (artery and vein)	2 (8.3)
Type of flow-limiting lesion <sup>b</sup>	
Stenosis	19 (79.2)
Thrombosis	4 (16.7)
Vessel spasm	1 (4.2)

Values are presented as number (%).

<sup>a</sup>Preoperative ultrasonographic finding, <sup>b</sup>postoperative angiographic finding.

**Table 3.** Details of procedure

Technical aspect	Value
Approach (access)	24
Radial artery	23 (95.8)
Brachial artery	1 (4.2)
Retrograde (cephalic vein)	0
Diameter of used sheath (in all cases, Fr)	5
Size of used balloon (mm)	
3	3 (12.5)
4	16 (66.7)
5	5 (20.8)
Technical success rate <sup>a</sup>	23/24 (95.8)
Secondary balloon angioplasty (patient no.) <sup>b</sup>	7/23 (30.4)
Maturation time (wk)	4.5±1.5
Clinical success rate <sup>c</sup>	23/24 (95.8)

Values are presented as patient number (%) or mean±standard deviation.

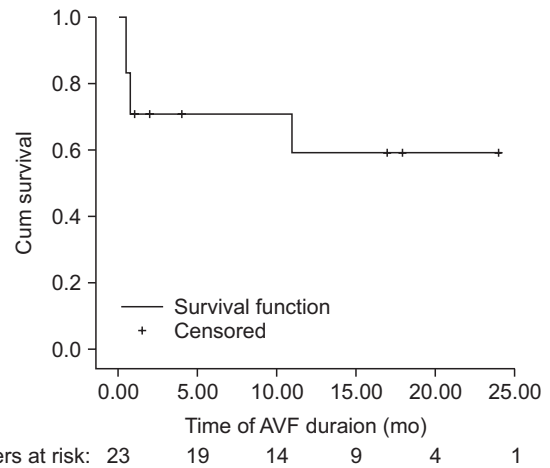
<sup>a</sup>Rate of successful arteriovenous fistula flow restoration after immediate postoperative balloon angioplasty, <sup>b</sup>balloon angioplasty for enhancing maturation, <sup>c</sup>rate of successful growth as a functional arteriovenous access.

postoperative PTA, and the hematoma was evacuated with preserved AVF flow.

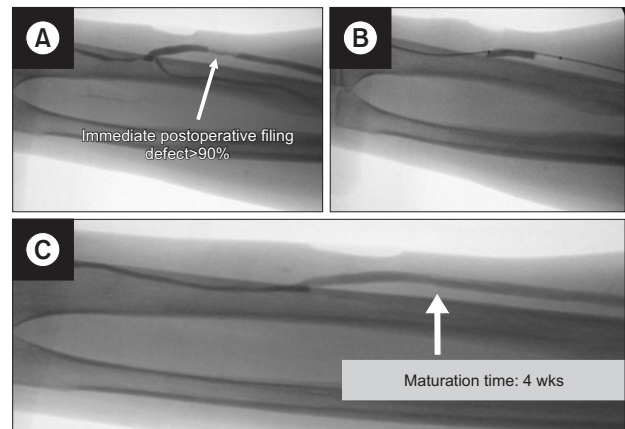
## DISCUSSION

Operators are caught up with a dilemma when postoperative native AVF's thrill is absent or unsatisfactory, because presence of on table thrill and bruit are indicators of successful AVF creation. In other words, absence of on table thrill predicts early failure of AVF [7], and revision or intervention is not easy in failed native AVFs. For this reason, in every patient with newly-created AVFs with no thrill, our protocol was to perform fistulograms and immediate intervention (reason why we have no control group in our center).

In most of our cases, anatomical lesions rather than anastomosis technique itself was the main problem, such as the presence of very short stenotic venous or arterial lesions, non-distensible veins, kinked outflow with surrounding soft tissue and vasospasm. Unexpected venous stenosis was the main cause of flow-limitation in newly created AVFs (Fig. 2). Sometimes, combined lesions (artery and vein) were found (Fig. 3). There was a single case of arterial spasm (Fig. 4). The flow-limiting lesion was resolved except in 1 case of wiring failure, with a satisfactory technical success rate of 95.8%. Moreover, once AVF flow was restored, all the accesses grew up as a functional hemodialysis access, even though about one third of them needed a secondary



**Fig. 1.** Primary patency rate after immediate postoperative balloon angioplasty. AVF, arteriovenous fistula.

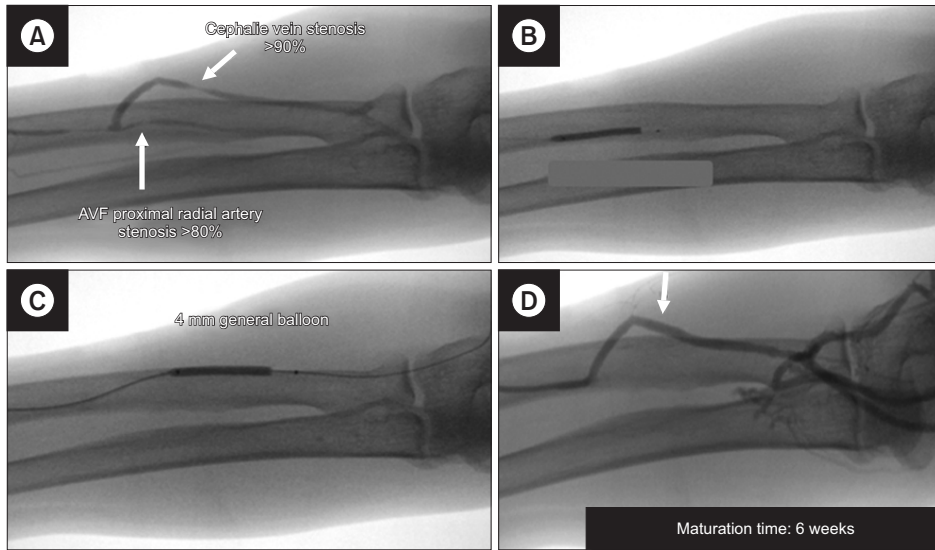


**Fig. 2.** (A) Immediate postoperative balloon angioplasty; focal vein stenosis. (B) Conventional 4 mm-sized balloon was used. (C) Post-ballooning angiography showed resolved venous stenosis. Arteriovenous access was matured after 4 weeks.

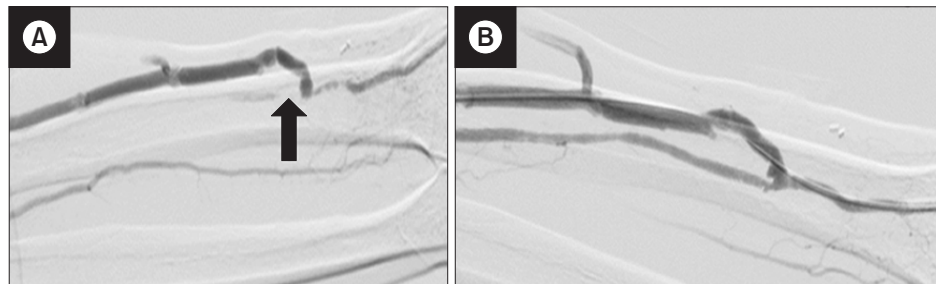
balloon angioplasty.

Short vein lesions can be skipped in preoperative duplex scan [8,9]. Moreover, postoperative flow-limiting lesions may be hidden preoperatively, because it is difficult to evaluate the distensibility and elasticity of vessels with duplex scan [10,11]. Focal vessel wall scars and mural thrombi may be present from previous vessel injury such as prolonged indwelling catheterization and frequent venous blood sampling. Focal stiff vessel lesions may lead to postoperative AVF flow limitation, because after AVF creation, the lesion does not distend as the other segments.

A major concern of IPBA is the stability of the anastomosis site and the possibility of anastomosis rupture. However, in our experience, there was no case of rupture.



**Fig. 3.** (A) Immediate postoperative balloon angioplasty; combined artery and vein lesions. (B) Conventional 3 mm-sized balloon was used for the arterial stenosis and (C) 4 mm balloon for the venous lesion. (D) Post-ballooning angiography showed resolved stenosis. (D) Arteriovenous fistula (AVF) flow was restored and arteriovenous access was matured after 6 weeks.



**Fig. 4.** (A) Immediate postoperative balloon angioplasty; radial artery spasm (arrow). (B) Arterial spasm was not relieved after waiting for a few minutes, thus the spastic radial artery was ballooned (3 mm) to improve radial artery inflow. Arteriovenous fistula flow was restored and arteriovenous access was matured after 3 weeks.

There was only one case of operation site hematoma but was not related with the anastomosis. In our experience, IPBA is an effective and safe procedure.

There are several reports about intraoperative intervention during native AVF creation. The intervention includes balloon pre-dilatation of small sized veins [12] or dilatation of vein with vessel probes [3]. However, to our knowledge, there is no report that shows the salvage effect of IPBA for newly created AVF with threatened flow (AVF with no thrill).

From our experience, IPBA can be summarized as follows: First, IPBA can be used as a salvage procedure in newly-created, flow-limiting AVFs. Second, with this salvage procedure, the success rate of native AVF creation can be improved. Third, IPBA has an educational effect

in that the operators can look back their technique with immediate postoperative angiography. Fourth, IPBA can be used in challenging cases with short vessel lesions. If the operator keeps IPBA in mind and gets used to it, the ideal native wrist AVF can be created rather than upper arm AVF or artificial graft, even in the presence of focal vein stenosis or thrombus. These are the reasons why we have adopted this practice in our institute.

## CONCLUSION

IPBA is a useful, effective and safe procedure for salvage of newly-placed, flow-limiting native AVF in our experience.

## REFERENCES

- 1) National Kidney Foundation. National Kidney Foundation Kidney Disease Outcomes and Quality Initiative (K/DOQI), 2006 update. New York: National Kidney Foundation Inc.; 2006.
- 2) Pantelias K, Grapsa E. Vascular access today. *World J Nephrol* 2012;1:69-78.
- 3) Veroux P, Giaquinta A, Tallarita T, Sinagra N, Virgilio C, Zerbo D, et al. Primary balloon angioplasty of small ( $\leq 2$  mm) cephalic veins improves primary patency of arteriovenous fistulae and decreases reintervention rates. *J Vasc Surg* 2013;57:131-136.
- 4) Tordoir JH, Rooyens P, Dammers R, van der Sande FM, de Haan M, Yotl. Prospective evaluation of failure modes in autogenous radiocephalic wrist access for haemodialysis. *Nephrol Dial Transplant* 2003;18:378-383.
- 5) Roy-Chaudhury P, Spergel LM, Besarab A, Asif A, Ravani P. Biology of arteriovenous fistula failure. *J Nephrol* 2007;20:150-163.
- 6) Whittier WL. Surveillance of hemodialysis vascular access. *Semin Intervent Radiol* 2009;26:130-138.
- 7) Sahasrabudhe P, Dighe T, Panse N, Deshpande S, Jadhav A, Londhe S. Prospective long-term study of patency and outcomes of 505 arteriovenous fistulas in patients with chronic renal failure: Authors experience and review of literature. *Indian J Plast Surg* 2014;47:362-369.
- 8) Malovrh M. Native arteriovenous fistula: preoperative evaluation. *Am J Kidney Dis* 2002;39:1218-1225.
- 9) Korten E, Toonder IM, Schrama YC, Hop WC, van der Ham AC, Wittens CH. Dialysis fistulae patency and preoperative diameter ultrasound measurements. *Eur J Vasc Endovasc Surg* 2007;33:467-471.
- 10) Kheda MF, Brenner LE, Patel MJ, Wynn JJ, White JJ, Prisant LM, et al. Influence of arterial elasticity and vessel dilatation on arteriovenous fistula maturation: a prospective cohort study. *Nephrol Dial Transplant* 2010;25:525-531.
- 11) Peterson WJ, Barker J, Allon M. Disparities in fistula maturation persist despite preoperative vascular mapping. *Clin J Am Soc Nephrol* 2008;3:437-441.
- 12) Fila B, Lovčić V, Sonicki Z, Magaš S, Sudar-Magaš Z, Malovrh M. Vein diameter after intraoperative dilatation with vessel probes as a predictor of success of hemodialysis arteriovenous fistulas. *Med Sci Monit* 2014;20:191-198.